

## Efficacy and Complications of Mitrofanoff Continent Urinary Diversion in Adults with Complex Urethral Strictures: A Single-Center Experience

Amir Reza Abedi<sup>1</sup>, Jalil Hosseini<sup>1</sup>, Seyyed Ali Hojjati<sup>2</sup>, Amir Alinejad Khorram<sup>2\*</sup>

Raziyeh Nikmaram<sup>2</sup>, Fatemeh Fakhar<sup>2</sup>

**Purpose:** The management of complicated and irreparable urethral strictures can be challenging, and continent urinary diversion has emerged as a viable option. This study aims to investigate the complications associated with continent urinary diversion using the Mitrofanoff principle in patients with complex urethral strictures that cannot be corrected through urethroplasty surgery.

**Materials and Methods:** A total of 22 patients were included in this study, who underwent continent urinary diversion surgery using the Mitrofanoff technique. The patients were monitored for post-surgical complications over an average follow-up period of 28.36±14.26 months. Surgical failure was defined as the inability to completely and regularly empty urine from the new urinary tract.

**Results:** Half of the patients experienced surgical complications, with only one case resulting in surgery failure. The most common complication observed was stoma stenosis. Two patients reported slight urinary leakage from the stoma site. Notably, all patients except one, regained control over their urine after the procedure. Early therapeutic interventions were classified according to the Clavien-Dindo grading system, showed that none of the patients experienced severe complications (grade 4 or 5).

**Conclusion:** The study examines the outcomes of continent urinary diversion using the Mitrofanoff technique in adults with complex urethral strictures, providing realistic expectations of complications. Overall, the study shows that this approach is a viable option with a high success rate and manageable complication for individuals with complex urethral strictures that cannot be corrected through urethroplasty surgery.

**Keywords:** Cystostomy; urethral stricture; urinary diversion

### INTRODUCTION

Urethral stricture is a common complication of various etiologies, including intraurethral procedures and catheterizations, as well as inflammation, infection, post-prostate surgery complications, and congenital malformations<sup>(1)</sup>. Trauma is another significant cause of urethral strictures, with studies suggesting that urethral injuries occur in 4-19% of male and 6% of female pelvic trauma cases<sup>(2)</sup>. In patients with competent bladder neck whose urethral strictures can be adequately compensated, urethroplasty is often the treatment of choice<sup>(3-6)</sup>. However, those who do not meet these criteria and have complex urethral strictures may require continent urinary diversion (CUD) surgeries to manage their condition. Two widely used techniques for urinary diversion in patients with irreparable urethral strictures are appendicovesicostomy (Mitrofanoff) and Monti surgery<sup>(7)</sup>.

Mitrofanoff first described a technique in 1980 that utilizes the appendix to create a continent urinary diversion which has since become widely used<sup>(8)</sup>. Based on this approach, the proximal part of the appendix is anastomosed to the skin, while the distal part is con-

nected to the bladder, allowing for bladder catheterization through a tunnel<sup>(9)</sup>. This method offers several advantages, including improved quality of life, high patient satisfaction, favorable cosmetic outcomes, painless catheterization, and a low complication rate<sup>(10)</sup>. However, in cases where the appendix is not suitable for urinary diversion or in patients with a history of previous appendectomy, the Monti technique is often used instead. In Monti's procedure, a tunnel is created between the bladder and skin using a segment of ileum<sup>(11)</sup>. There is a dearth of studies focused on the follow-up of adult patients who have undergone the Mitrofanoff Procedure, specifically regarding complications and outcomes. This lack of research highlights the need for further investigation into the short-term and long-term consequences of this surgery in adult patients with irreparable urethral strictures. To address this gap, we conducted a study to follow up 22 adult patients with irreparable urethral strictures who underwent Mitrofanoff surgery, assessing the potential complications and success rates associated with this procedure.

<sup>1</sup>Men's Health and Reproductive Health Research Center, Shahid Beheshti University of Medical Sciences, Tehran, Iran.

<sup>2</sup>Urology Department, Shohada-e-Tajrish Hospital, Shahid Beheshti University of Medical Sciences, Tehran, Iran.

\*Correspondence: Urology Department, Shohada-e-Tajrish Hospital, Shahid Beheshti University of Medical Sciences, Tehran, Iran.

Tel: +989124486467. Email: Amir.alinejad1992@gmail.com.

Received March 2024 & Accepted August 2024

**Table 1.** Patients characteristics. BMI: Body Mass Index, PFUI: Pelvic Fracture Urethral Injury, TURP: Trans Urethral Resection of the Prostate.

Age (Mean ± SD)	40.72 ± 24.20 (years)
BMI (Mean ± SD)	26.6 ± 2.5 (kg/m <sup>2</sup> )
Gender	Male: 20 patients (91 %) Female: 2 patients (9 %)
Etiology of urethral Strictures	PFUI: 15 patients (68 %) Urethritis: 2 patients (9 %) Iatrogenic: 4 patients (18.18%) After TURP: 2 patients (9 %) After radical prostatectomy: 2 patients (9 %)
Urinary diversion indication	Fournier's gangrene: 1 patient (4 %) Irreparable urethral Stricture length: 16 patients (73 %) Non-competent bladder neck: 4 patients (18 %) Repeated failure in previous urethroplasty: 2 patients (9 %)

## MATERIALS AND METHODS

### Patients selection

This study analyzed 22 patients who were candidates for CUD surgery between April 2016 and April 2023. To be eligible for Mitrofanoff surgery, which is the primary focus of this research, patients were selected who could not undergo urethroplasty due to reasons such as non-competent bladder neck or Irreparable urethral Stricture length. All patients in our study were referred to our team from the Department of Reconstructive Urology at Shohada-e-Tajrish Hospital. This department, with an impressive track record of over 5000 successful urethroplasty surgeries in the last two decades, has extensive experience in identifying suitable patients with irreparable urethral defects for urinary diversion procedures. This collaboration ensures that patients receive expert care and guidance in selecting the most appropriate treatment options for their specific conditions. By performing up and down cystoscopy (which involves flexible cystoscopy from both the meatus and cystostomy tract), as well as retrograde urethrogram (RUG) and voiding cystourethrogram (VCUG), the exact anatomy of the urethra of each patient was determined.

To ensure the accuracy and comprehensiveness of the study's findings, a strict set of inclusion and exclusion criteria were established. Patients with incomplete records or those who could not be adequately followed up were excluded from the analysis to maintain the study's integrity.

Inclusion criteria include:

- The Presence of a urethral stricture that cannot be properly repaired by urethroplasty
- A high probability of urinary incontinence in the event of urethroplasty due to incompetence of the bladder neck and urethral sphincter mechanism.
- Failure of previous urethroplasty and unwillingness of the patient to undergo repeat urethroplasty

Exclusion criteria include:

- Mental incapacity of the patient to manage a urinary stoma, perform clean intermittent catheteriza-

tion (CIC) regularly, and follow medical recommendations

- History of previous appendectomy
- The possibility of correcting the urethral stricture through alternative methods, such as direct visual internal urethrotomy, urethroplasty, or urethral dilatation, without requiring urinary diversion
- Patients with active sepsis or active infections in the urinary tract or abdominal wall
- History of inflammatory bowel disease or advanced gastrointestinal cancer

### Surgical Technique

The surgical procedure began with an incision made along the lower midline of the abdomen, providing access to the bladder, ileocecal junction, and appendix. Upon identification of the appendix, it was carefully dissected from the cecum while preserving its mesentery. Subsequently, an opening was created at the blind end of the appendix, appendix was then thoroughly rinsed. To confirm patency, a 10F catheter was inserted through the appendix and its lumen was inspected (**Figure 1**).

The appendix was then implanted into the bladder via a submucosal tunnel with a minimum length of 4 cm to prevent involuntary urinary leakage. The appendix was securely fastened to the bladder muscle and mucosa using absorbable sutures. VQZ plasty technique was employed at the stoma site.

In obese adults, when the distance between the bladder and the anterior abdominal wall makes it impossible to use the appendix or in patients with a short appendix, a tubularized bladder flap was employed to bring the appendix to the skin in a tension-free manner (**Figure 2**). During the surgery, a 10F catheter was placed in the path of appendicovesicostomy and fixed. To enhance patient safety, a cystostomy tube was inserted in all cases.

During the procedure, a 10F catheter was placed in the path of appendicovesicostomy and secured in place. To enhance patient safety, a cystostomy tube was inserted in all cases

**Table 2.** Post-operative complications during the follow-up period

short-term postoperative complications (< 1 month)	Detachment of appendix: 1 patient (4 %) Surgical site infection: 1 patient (4 %) Testis abscess: 1 patient (4 %)
long-term postoperative complications (> 1 month)	partial bowel obstruction: 1 patient (4 %) Detachment of appendix: 1 patient (4 %) Stenosis of the appendix stoma: 2 patients (9 %) Involuntary leakage of urine: 2 patients (9 %) Recurrent cystitis: 1 patient (4 %) Vesicocutaneous fistula: 1 patient (4 %)

**Table 3.** Clavien-Dindo classification of early therapeutic interventions.

	Number of patients (%)
Grade 1	1 (4 %)
Grade 2	2 (9 %)
Grade 3 a	2 (9 %)
Grade 3 b	3 (14 %)
Grade 4 a	0 (0%)
Grade 4 b	0 (0%)
Grade 5 0	0 (0%)

**Follow-Up**

Following a three-week period, the Mitrofanoff catheter was successfully removed, and the suprapubic catheter was securely clamped. During this interim period, patients underwent comprehensive training in clean intermittent catheterization (CIC) using a 12 or 14 French Nelaton catheter, performed every three hours.

Subsequently, the cystostomy tube was eliminated and patients continued practicing CIC through the Mitrofanoff stoma. A regular follow-up schedule was maintained, with patients attending scheduled evaluations at 3, 6, 18, and 24 months.

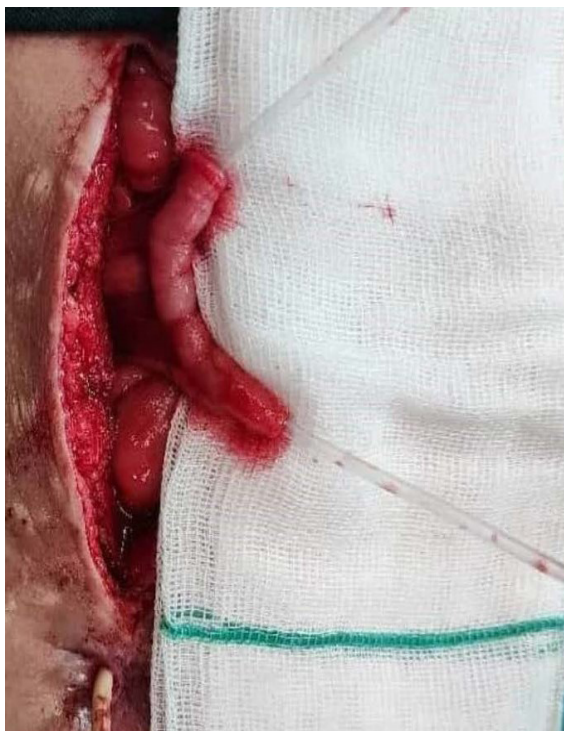These assessments involved a thorough examination of the stoma, upper urinary tract ultrasonography, measurement of post-catheterization urine residue, and monitoring of serum creatinine levels.

**Data Collection**

A comprehensive set of variables was recorded for each patient, including age, body mass index (BMI), gender, etiology of urethral strictures, and indication for urinary diversion.

Postoperatively, patients were scheduled for regular follow-up appointments at the designated intervals. During these visits, patients were queried regarding their frequency of performing CIC and the ease with which they performed the procedure.

Additionally, patients were asked about the occurrence of involuntary leakage of urine from the stoma site, and were asked to provide a subjective assessment of the severity of this symptom, measured in terms of the number of pads used per day.

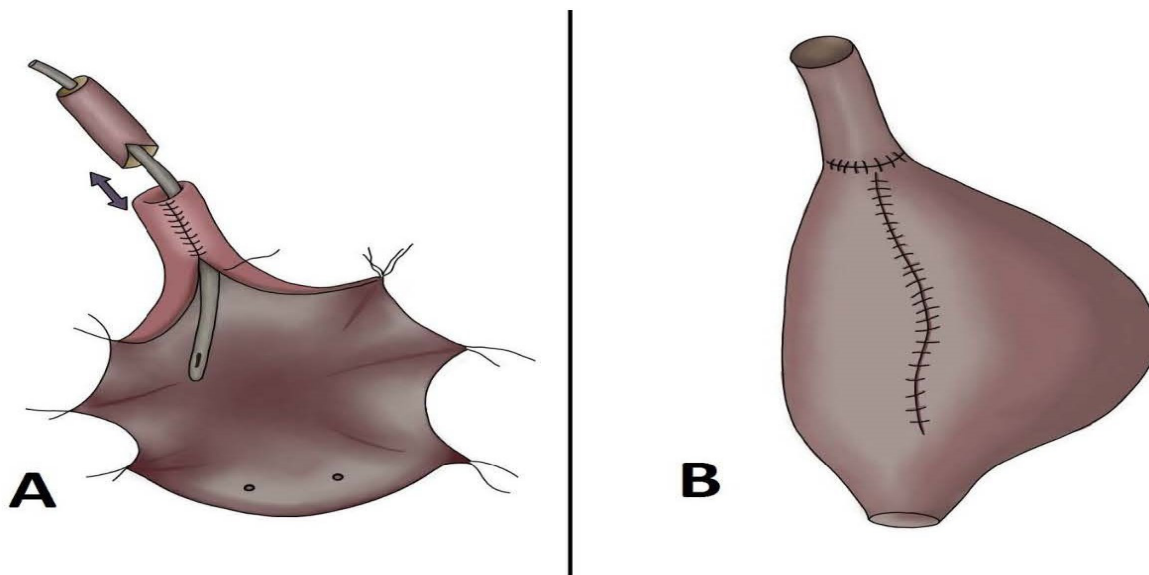


**Figure 1.** Appendix patency with the 10F catheter.

Urinary diversion patency was evaluated using a Nelaton catheter at each follow-up visit. The surgical incision site and previous suprapubic cystostomy site were carefully examined to assess any potential complications or issues.

Six months postoperatively, all patients underwent ultrasound examination to assess urinary residual volume and rule out silent urinary obstruction. Surgical failure was defined as the inability to completely and regularly empty urine from the new urinary tract.

The results of these examinations were meticulously recorded and categorized for further analysis.



**Figure 2.** Schematic image of Boari flap technique to bring the appendix to the skin in a tension-free state. Appendix implantation into tubularized flap (A), External view after closing the bladder (B).

**Ethical statement**

The study received approval from the Ethics Committee of Shahid Beheshti University of Medical Sciences (Ethical code No. IR.SBMU.RETECH.REC.1402.122). Before any intervention, all participants provided written informed consent.

**RESULTS**

The study included 22 patients who underwent appendicovesicostomy surgery for various indications. The patients were followed up regularly for an average duration of  $28.36 \pm 14.26$  months.

The patient population had a wide age range, spanning from 18 to 83 years. The majority of patients were male (91%), with only 2 patients (9%) being female.

The shortest follow-up period was 5 months, while the longest was 52 months. The most common etiology of urethral stenosis or disruption was Pelvic Fracture Urethral Injury (PFUI), accounting for 68% of the cases. The demographic and clinical characteristics of the patients are summarized in **Table 1**.

The analysis revealed that the short-term complications (<1 month post-surgery) were less prevalent than the long-term complications. The most common complication observed was stoma stenosis, affecting 9% of patients, which was successfully managed through serial stomal dilation. A further 9% of patients experienced slight urinary leakage from the stoma site.

It is noteworthy that stoma stenosis did not occur in any of the patients who underwent appendicovesicostomy using a bladder flap. Additionally, the average rate of urine leakage from the stoma site during the day was found to be less than half a pad per day, which decreased over time.

One patient experienced a postoperative complication, contracting COVID-19 during his hospital stay. This infection led to respiratory symptoms, including coughing, which ultimately resulted in wound dehiscence and detachment of the appendix from the skin. Once the patient's condition stabilized, a surgical intervention was necessary to address the complications. This involved appendectomy, closure of the wound, and insertion of a suprapubic cystostomy. As a consequence, the appendicovesicostomy procedure was unsuccessful in this particular patient.

In another case, patient experienced a complication six months post-surgery, in which the appendix detached from the skin. The patient's symptoms included an inability to empty any urine from the stoma, with the urine being difficult to pass through the urethra. A scheduled surgical correction was planned, but during the procedure, an unexpected complication arose due to extensive adhesions. Specifically, an ileal perforation occurred, necessitating the resection of 20 centimeters of the ileum and the performance of an ileoileal anastomosis. The appendix was successfully re-anastomosed to the skin, and the patient has not reported any issues since.

Partial bowel obstruction occurred in a 28-year-old patient one month after surgery. A conservative approach was employed, resulting in a successful resolution of the issue.

Additionally, two patients experienced distinct complications: one developed a testicular abscess, requiring a right orchiectomy, while another patient presented with a vesicocutaneous fistula at the cystostomy scar site,

which was subsequently repaired (**Table 2**).

The Clavien-Dindo classification system was utilized to evaluate the early therapeutic interventions for patients. According to the Clavien-Dindo classification, the early therapeutic interventions were as follows: one patient, requiring the use of an anti-nausea medication (grade 1). Two patients required blood transfusion and medical treatment (grade 2). Two patients required radiological and endoscopic intervention under local anesthesia (grade 3a) while three patients required interventions under general anesthesia (grade 3b). None of the patients were classified as having grade 4 or 5 complications. The highest rate of complications was observed in grade 3b (**Table 3**).

**DISCUSSION**

The Mitrofanoff procedure is a surgical technique used to address a range of pathologic and structural issues, including continence problems, neurogenic bladder dysfunction accompanied by incontinence, irreparable urethral strictures, and various urogenital defects or congenital anomalies. This procedure can be combined with bladder augmentation techniques for patients with low compliance bladders<sup>(12-14)</sup>.

The Mitrofanoff procedure has been extensively studied in pediatric patients, but despite fewer studies in adults, it is used to create continent urinary diversion across all age groups<sup>(11)</sup>. Notably, there have been reports of successful use of this method in patients with urogenital tumors<sup>(15,16)</sup>. A notable example is a 2005 study by Kobayashi et al., which described the cases of a 58-year-old man and a 77-year-old woman who underwent Mitrofanoff procedure as a result of genitourinary cancer. long-term follow-up showed the success of the surgery in both patients<sup>(16)</sup>.

The Mitrofanoff procedure offers several advantages, including complete continence and easy catheterization. In carefully selected adult patients, creating a continent urinary channel can significantly improve quality of life and minimize complications associated with complex urethral strictures or neurogenic bladder<sup>(11,17)</sup>. A study by Smith et al. investigated the quality of life in 19 adult patients who underwent the Mitrofanoff procedure. Their findings showed that physical function, vitality, social functioning, emotional role, and mental health all improved significantly after the procedure<sup>(18)</sup>. Despite the high success rate of the Mitrofanoff procedure, rare but potential complications can occur. According to the literature, the overall post-procedural complication rate is reported to be 6.2%<sup>(13)</sup>. In our study, we propose that the relatively high rate of surgical complications among patients could be attributed to the fact that all participants were adults with thick abdominal walls, as opposed to previous studies that primarily focused on pediatric patients with thinner wall thickness. Consistent with previous studies, obesity was identified as a significant factor contributing to complications after continent urinary diversion surgeries<sup>(1,19,20)</sup>.

In our study, we encountered challenges during surgeries involving short appendixes, thick abdominal walls, and obesity among patients. To address these difficulties, we explored three potential solutions: employing the Boari flap technique, performing cecum lengthening, or conducting the Monti procedure. After careful consideration, we elected to employ the Boari flap technique, which allowed us to successfully bring the

appendix to the skin surface in patients with short appendixes or obesity.

Some studies have reported the occurrence of postoperative stenosis in 10-23% of cases, urinary incontinence in 2-7%, and the need for stoma revision in 16-20%<sup>(16, 21,22)</sup>. In 2021, Zann et al. compared different methods of creating a continent catheterizable urinary channel (23). The study divided patients into three groups: one group used the Monti method, one group used the intact appendix, and the third group used the split appendix. The authors found that the Split appendix Mitrofanoff technique was associated with a higher risk of complications compared to other methods. Most complications in this study were mild and correctable, with stenosis of the diversion tract being the primary reason for surgical revision<sup>(23)</sup>. Similarly, in our study, most complications were mild and manageable, and two patients experienced stoma stenosis, which was successfully managed. The Mitrofanoff procedure is a continent urinary diversion technique, where patients are expected to empty their bladder at scheduled intervals through CIC. Ideally, there should be no leakage between CIC sessions. Any involuntary leakage from the stoma site is defined as urinary incontinence<sup>(24,25)</sup>. Kroll et al.'s 2017 study found that 95% of children (59 out of 62) who underwent the Mitrofanoff procedure achieved urinary continence<sup>(25)</sup>. In our study, two patients experienced brief urinary leakage, which is expected to diminish or resolve over time with performing scheduled CIC. These findings support the effectiveness of the Mitrofanoff procedure in maintaining urinary continence.

Notwithstanding the significant complications encountered during this surgical procedure, it is striking that the incidence of serious complications leading to surgery failure is relatively low. Among the 22 patients participating in the study, only one surgery ultimately failed, while the majority of patients successfully managed to control their urine. This outcome suggests that, despite the challenges associated with this approach, the surgical technique has demonstrated a high level of efficacy for most patients.

This study has several limitations, including the small sample size, the absence of a control group, and the lack of a direct comparison with other continent urinary diversion (CUD) surgical methods. Furthermore, the subjective nature of assessing some complications may also be a limitation. The limited number of patients included in this study restricts the generalizability of the findings. Future studies should aim to conduct larger, randomized controlled clinical trials with sufficient sample sizes to increase the robustness and applicability of the results.

## CONCLUSIONS

This study provides valuable insights into the outcomes of continent urinary diversion using the Mitrofanoff technique in adults with irreparable and complex urethral strictures, providing realistic expectations of complications.

In addition, this study proposes the Boari flap technique as a solution to perform this procedure with minimal complications in patients with insufficient appendix length, especially obese people with increased abdominal thickness.

Our long-term follow-up of a patient cohort, demonstrates that continent urinary diversion using the Mitrofanoff

principle is a viable option with a high success rate and manageable complications for individuals with complex urethral strictures that cannot be corrected through urethroplasty surgery.

## ACKNOWLEDGEMENTS

The authors would like to thank the staff of Shohada-e-Tajrish Hospital for their care and sacrifices in the patients' treatment.

## CONFLICT OF INTEREST

The authors declare no conflict of interest.

## REFERENCES

1. Tritschler S, Roosen A, Füllhase C, Stief CG, Rübber H. Urethral stricture: etiology, investigation and treatments. *Dtsch Arztebl Int.* 2013;110:220.
2. Kong JP, Bultitude MF, Royce P, Gruen RL, Cato A, Corcoran NM. Lower urinary tract injuries following blunt trauma: a review of contemporary management. *Rev Urol.* 2011;13:119.
3. Koraitim MM. Pelvic fracture urethral injuries: evaluation of various methods of management. *J Urol.* 1996;156:1288-91.
4. Mathur R, Nayak D, Aggarwal G, Shukla A, Khan F, Odiya S. A retrospective analysis of urethral strictures and their management at a tertiary care center. *Nephrourol Mon.* 2011;3:109-13.
5. Hwang EC, De Fazio A, Hamilton K, Bakker C, Pariser JJ, Dahm P. A systematic review of randomized controlled trials comparing buccal mucosal graft harvest site non-closure versus closure in patients undergoing urethral reconstruction. *World J Mens Health.* 2022;40:116.
6. Kulkarni S, Joshi PM, Bhadravar S. Advances in urethroplasty. *Med J Armed Forces India.* 2023;79:6-12.
7. Abedi AR, Ghiasy S, Fallah-Karkan M, Hojjati SA, Hosseini J. Appendicovesicostomy as an alternative procedure for patients with complex urethral distraction defect. *Urol J.* 2020;17:386.
8. Mitrofanoff P. Trans-appendicular continent cystostomy in the management of the neurogenic bladder. *Chir Pediatr.* 1980;21:297-305.
9. Lemelle J, Simo AK, Schmitt M. Comparative study of the Yang-Monti channel and appendix for continent diversion in the Mitrofanoff and Malone principles. *J Urol.* 2004;172:1907-10.
10. O'Connor EM, Foley C, Taylor C, Malde S, Raja L, Wood DN, et al. Appendix or Ileum—Which is the Best Material for Mitrofanoff Channel Formation in Adults? *J Urol.* 2019;202:757-62.
11. Levy ME, Elliott SP. Reconstructive techniques for creation of catheterizable channels: tunneled and nipple valve channels. *Transl Androl Urol.* 2016;5:136.
12. Turner-Warwick R. Prevention of complications resulting from pelvic fracture urethral injuries—and from their

- surgical management. *Urol Clin North Am.* 1989;16:335-58.
13. Filipas, Fisch, Leißner, Hohenfellner, Thüroff. Urinary diversion in childhood: indications for different techniques. *BJU Int.* 1999;84:897-904.
  14. Lecoanet P, Pascal G, Khaddad A, Hubert N, Lemelle J-L, Berte N, et al. Robot-assisted continent urinary diversion according to the Mitrofanoff principle: results of a bicentric study. *World J Urol.* 2021;39:2073-9.
  15. Chen S, Wu Y, Zhang P, Li Z, Li X, Li Z, et al. Laparoscopic continent cutaneous urinary diversion using a modified Yang-Monti technique in an adult: A case report including 5-year follow-up. *Curr Urol.* 2022;10:1097.
  16. Kobayashi M, Nomura M, Yamada Y, Fujimoto N, Matsumoto T. Bladder-sparing surgery and continent urinary diversion using the appendix (Mitrofanoff procedure) for urethral cancer. *Int J Urol.* 2005;12:581-4.
  17. Harris CF, Cooper CS, Hutcheson JC, Snyder HM. Appendicovesicostomy: the Mitrofanoff procedure—a 15-year perspective. *J Urol.* 2000;163:1922-6.
  18. Smith G, Carroll D, Mukherjee S, Aldridge R, Jayakumar S, McCarthy L, et al. Health-related quality of life in patients reliant upon mitrofanoff catheterisation. *Eur J Pediatr Surg.* 2011;263-5.
  19. Hebert KJ, Matta R, Myers JB. Patient Selection and Outcomes of Urinary Diversion. *Urol Clin North Am.* 2022;49:533-51.
  20. Redshaw JD, Elliott SP, Rosenstein DI, Erickson BA, Presson AP, Conti SL, et al. Procedures needed to maintain functionality of adult continent catheterizable channels: a comparison of continent cutaneous ileal cecocystoplasty with tunneled catheterizable channels. *J Urol.* 2014;192:821-6.
  21. Hakenberg OW, Ebermayer J, Manseck A, Wirth MP. Application of the Mitrofanoff principle for intermittent self-catheterization in quadriplegic patients. *Urology.* 2001;58:38-42.
  22. Veeratterapillay R, Morton H, Thorpe AC, Harding C. Reconstructing the lower urinary tract: The Mitrofanoff principle. *Indian J Urol.* 2013;29:316.
  23. Zann A, Sebastiao Y, Ching CC, Fuchs M, Jayanthi VR, Wood RJ, et al. Split appendix Mitrofanoffs have higher risk of complication than intact appendix or monti channels. *J Pediatr Urol.* 2021;17:700. e1-. e6.
  24. Harper L, Dunand O, Dobremez E. The fallow mitrofanoff. *J Pediatr Urol.* 2019;15:261. e1-. e4.
  25. Kroll P, Gajewska E, Zachwieja J, Ostalska-Nowicka D, Micker M, Jankowski A. Continent catheterizable conduits in pediatric urology: One-center experience. *Adv Clin Exp Med.* 2017;26:1107-12.