

Three-Dimensional Virtual Reconstruction Method versus Standard Fluoroscopy as a Guiding Tool for an Optimal Puncture Rout in Patients Undergoing Percutaneous Nephrolithotomy: A Randomized Trial Study

Seyed Reza Hosseini^{1*}, Elham Tehranipour¹, Aliakbar Khadem², Sayed Mohammed Jawad Alwedaie³

Purpose: Three-Dimensional (3D) could help for planning and creating an optimal access route in percutaneous nephrolithotomy (PCNL) procedure by achieving a more accurate approach to the renal collecting system and stone treatment while decreasing the risk of complications. The aim of our study is to compare the efficacy of 3D imaging technique with standard fluoroscopy method as a guiding tool for renal stone location while striving to reduce intra-operative X-ray exposure in the former method.

Materials and Methods: This randomised clinical trial enrolled 48 PCNL candidates who were referred to Sina Hospital (Tehran, Iran). Participants were divided into two equal groups of intervention (3D virtual reconstruction) and control, using block randomization method. Age, sex, stone type and location, X-ray exposure during the procedure, stone access accuracy rate and the necessity of blood transfusion during surgery were taken into account.

Results: The Mean age of participants (n = 48) was 46.4 ± 4.8 years, 34 (70.8%) were male, 27 (56.3%) had partial staghorn stones and all participants had stones within the lower calyx. The radiation exposure time, stone access time and stone size were 2.99 ± 1.81 seconds, 272.3 ± 108.9 seconds and 23.06 ± 2.28 mm, respectively. In the intervention group, the accuracy rate for lower calyceal stone access was 91.5%. Also, X-ray exposure and time to stone access were significantly lower in the intervention group compared to the controls ($P < 0.001$).

Conclusion: We concluded that the utilization of 3D technology in the pre-operative location of renal calculi in PCNL candidates may result in a significant improvement in the accuracy and time to access the renal calculi, as well as reduction in X-ray exposure.

Keywords: 3-Dimensional (3D) technology; percutaneous nephrolithotomy; renal stone; X ray; lithotripsy

INTRODUCTION

Urolithiasis is a frequently occurring condition, observed in 5-50% of the adult population depending on anthropometric and clinical values such as gender, race and region.⁽¹⁾ With regards to composition, the majority (70-80%) of the renal calculi are comprised of calcium oxalate, followed by calcium phosphate, uric acid and cysteine stones.⁽²⁾

Although supportive care is the primary method of approach in treating urolithiasis and acute renal colic, the size and location of the calculi may require more invasive methods of intervention, such as surgery.⁽³⁾ The more primary methods of surgical intervention included open surgery which has been replaced by extracorporeal shock wave lithotripsy, ureteroscopy and percutaneous nephrolithotomy (PCNL) in recent decades.⁽⁴⁾ PCNL is a minimally invasive procedure which involves the location of renal calculi with the aid of a fluoroscopy X-ray-guided needle and subsequent extraction of the stone using a nephroscope. The usual indications for PCNL include stones larger than 20mm, staghorn or partial staghorn calculi and stones situated in the lower poles. High levels of exposure to ionizing radiation is a major disadvantage to conventional PCNL and has prompted the search for more accurate and less

harmful methods.⁽⁵⁾ A novel approach involves the utilization of reconstructive 3-dimensional (3D) technology to accurately locate renal calculi and their relation to other anatomical structures and landmarks. This is in part indebted to the advances in fluoroscopy imaging techniques, such as rapid spiral acquisition and reconstructive software.^(6,7)

Establishing the percutaneous tract is the initial and most important step in PCNL surgery. Choosing the perfect tract, position, and direction is highly dependent on surgical experience, and the ability to understand the renal and peri-renal anatomy. In general, a good CT scan of the abdomen and pelvis, and a well-experienced surgeon in enough, but we appreciate any system that can add information. In this study, we evaluated if the 3D technology can help the surgeon in doing the optimal tract, compared to preoperative regular X-ray Fluoroscopy, while striving to reduce intra-operative X-ray exposure in the former method.

MATERIALS AND METHODS

Study population

In this randomized clinical trial, 48 patients undergoing PCNL in Sina University Hospital were enrolled. Participants were comprehensively informed of the

¹Department of Urology, Sina Hospital, Tehran University of Medical Sciences, Tehran, Iran.

²Islamic Azad University, Central Department, Tehran, Iran.

³Department of Internal Medicine, Royal College of Surgeons in Ireland and Medical University of Bahrain.

*Correspondence: Professor of Urology, Sina Hospital, Tehran University of Medical Sciences, Tehran, Iran.

Tel: 0098-21-6312000. E mail: srhosseini@tums.ac.ir Or srhosseini@tums.ac.ir.

Received October 2022 & Accepted June 2023

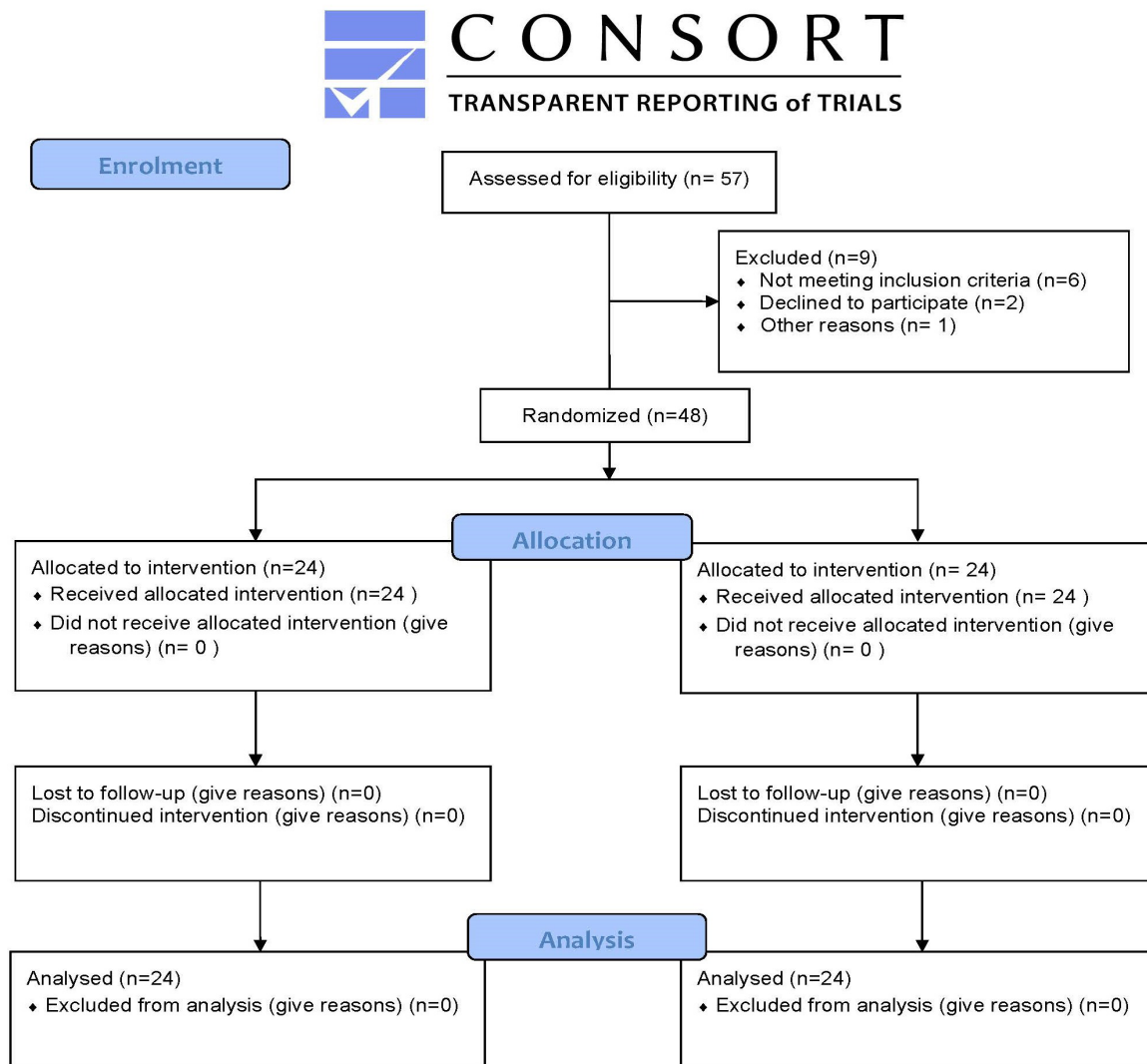


Figure 1: All participants' enrolment summary is represented based on the CONSORT (Consolidated Standards of Reporting Trials) 2010 checklist

goals and procedure of the study and were required to provide a written informed consent prior to entry. Participants reserved the right to withdraw at any stage of the study. This study adhered to the guidelines of the Helsinki declaration, was approved by the Ethics committee of Tehran University of Medical Sciences and was registered in the Iranian Registry of Clinical Trials (IRCT20200905048625N1).

The inclusion criteria consisted of patients aged between 18 to 80 who had the indications for PCNL procedure. In our department, PCNL is performed in patients with kidney stones more than 2 cm in diameter, stones refractory to extracorporeal shock wave lithotripsy, proximal ureteral stones larger than 1.5 cm in diameter, diverticular stones, and stones producing distal obstruction. The exclusion criteria were medium to high cardiovascular risk, coagulation disorder, renal failure, hepatic failure, diabetes mellitus, and hypothyroidism. Patients' enrolment algorithm is illustrated in **Figure 1**.

Study design

For the purpose of randomization, all PCNL candidates

were randomly divided into two groups using block randomization method. The randomization process was performed using the Random Function in Excel software. For randomization, the balanced block randomization method is used to generate four blocks. Intervention group A and control group B have been determined. Quadruple blocks (A or B) were placed in envelopes. After the arrival of the first patient with the inclusion criteria, the envelopes were randomly selected and the type of patient group was informed to the research team through a trained technician. Patient were placed in PCNL surgery using 3D technology or in X-ray Fluoroscopy group based on the randomly selected envelope. All the collected data for statistical analysis were coded and the statistician was not aware of the allocated interventions.

Surgical Technique

In both groups, CT-scan were performed in the prone position. The scan was performed before and after contrast administration. Non contrast CT-scan (NCCT) was used for stone location, the contrast phase was used to visualize collecting system. In the intervention group,

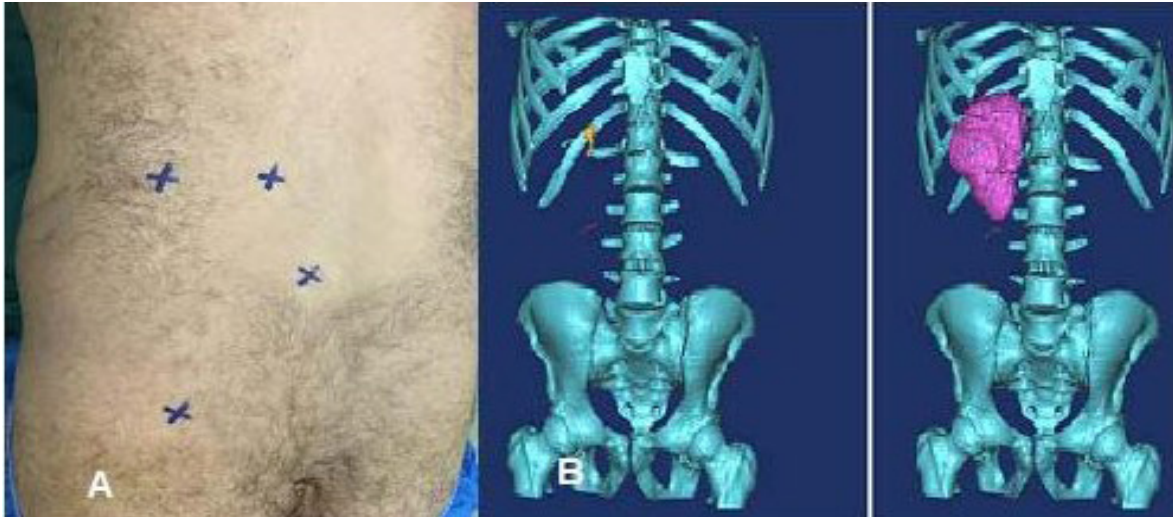


Figure 2: A. Anatomical sites which marked; second lumbar vertebra, PCNL access point of entry and the costovertebral angle (CVA) and the iliac crest. B. Marked point in 3D reconstructed image

the following anatomical sites were marked using a CT-scan appropriate marker: second lumbar vertebra, the costovertebral angle (CVA), posterior axillary line and the iliac crest (**Figure 2A**). Prior to imaging, patients were positioned in prone position and were asked to fully inhale and hold their breath for duration of ten seconds. This position was later replicated at the time of surgery with the help of an artificial inspiration to minimise movement and possible relocation of the calculi. Obtained images were reconstructed using the Materialise Mimics 3D reconstruction software (Leuven,

Belgium) (**Figure 2B**). Based on this reconstruction, the Solid works software (Premium 2019 x64 Edition SP.1) was then employed to reconstruct the exact shape of the stone based on the measurements and distances between the calculi and the pre-marked landmarks on the sagittal, coronal and axial plains (**Figure 3**). The resulting images were provided to the operators for an accurate location of the calculi and operative planning (**Figure 4A, B, C, D**). All images were obtained with the aid and supervision of a single radiology technician, 12-24 hours prior to the surgical procedure. The result-

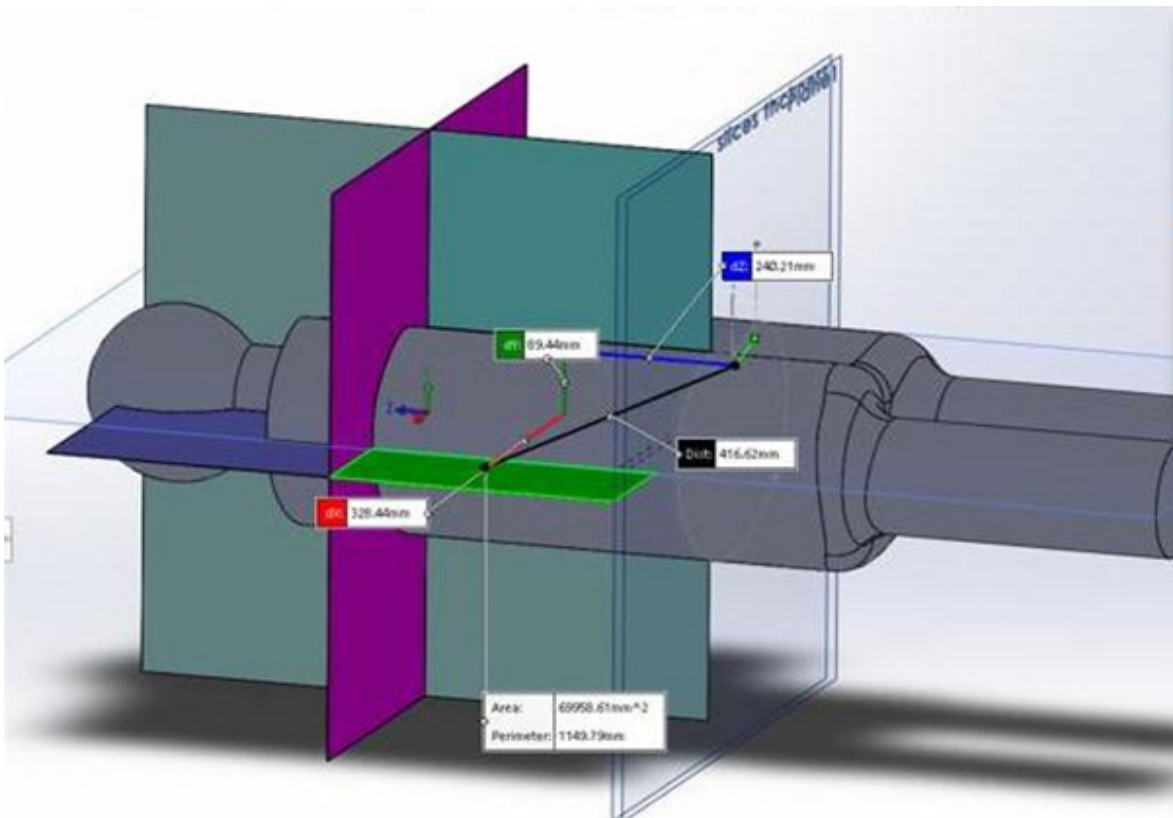


Figure 3: Sagittal, coronal and axial plains in Solid Works software

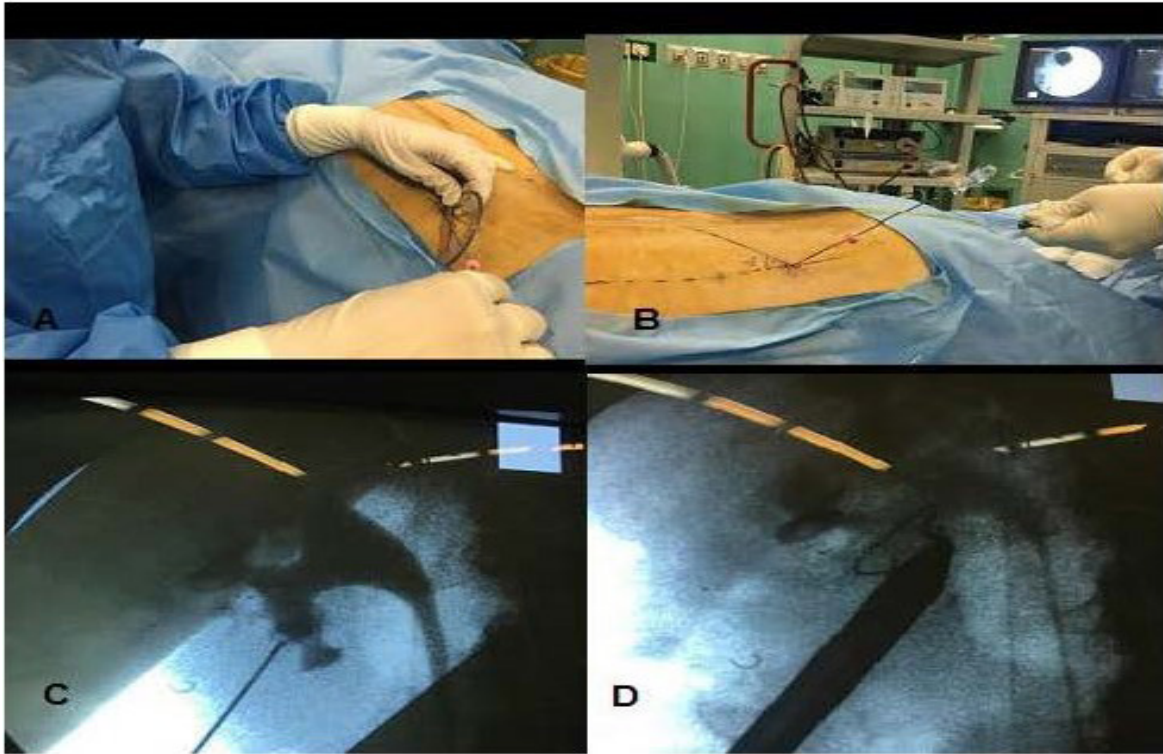

Figure 4: A. Measuring the access angles according to preoperative data from Solidworks software by surgeon. B. Fluoroscopy checking after entry according calculated angles. C. Checked fluoroscopy image after trying one's hand at accessing to stone. D. Access sheet on accurate point after using reconstructive 3-dimensional (3D) technology.

ing images were provided to the operators for an accurate location of the calculi and pre-operative planning. The durations of radiation exposure were measured by a single person via stopwatch.

PCNL was performed under general anaesthesia in the prone position. In both groups, a dye was injected through the lower urinary tract, in order to visualize the anatomy of renal collecting system with the help of fluoroscopy. In the intervention group, puncture was rechecked under pulsed fluoroscopy control. All the procedures were performed by using a 26 Fr nephroscope. Whenever clear withdrawal of urine was observed, stone access was confirmed and tract was dilated up to 30 Fr Amplatz sheath. The entire procedures were performed by two highly experienced (more than 18 years) operators in PCNL.

Statistical Analysis

Statistical analyses were performed using SPSS version 20 (SPSS Inc., Chicago, Illinois, USA). Quantitative variables are expressed as mean \pm Standard Deviation (SD), while qualitative data are presented as frequencies and regarded percentages. The relationships between qualitative data were investigated using the Chi-square and Fishers' exact test, while the comparison of quantitative data was performed using the student t-test or Mann-Whitney test for non-parametric conditions. The P -value < 0.05 is considered as statistically significant.

RESULTS

In this study, 48 patients ($n=24$, each group) were evaluated. The mean age of the participants was 46.4 ± 4.8 (ranging 38-57) years and 34 (70.8%) were male (Table 1). The two groups were similar with regards to the

distribution of age and sex ($P = 1$). The mean kidney stone access time was 272 ± 109 seconds and a significantly shorter access time was observed in the intervention group in comparison to the control group (168.9 ± 26.3 and 375.6 ± 35.3 seconds respectively, $P = .0001$). The mean radiation exposure time in patients assessed 2.99 ± 1.81 seconds and the mean time was significantly lower in the intervention group rather than those in the control group (1.25 ± 0.37 and 4.73 ± 0.5 seconds, respectively, $P = .0001$).

The mean size of the kidney stone was 23.06 mm with no observable difference between the two groups ($P = .21$). The majority (56.3%) of the extracted stones were found to be partial staghorn calculi and, although statistically insignificant, these calculi were more frequently observed in the intervention group compared to those in controls. Lower calyceal calculi were observed in all the participants.

In overall, the mean duration of surgery was 44.2 ± 5.6 minutes. However, this duration was lower in the intervention group compared to the control group but was not statistically significant (41.9 ± 4.1 and 46.5 ± 6 minutes respectively, ($P = .09$)). Among the intervention group, in 22 (91.5%) patients the lower calyceal stone access was obtained in the first try. On the other side, the same parameter in the control group was obtained in 21 (87.5%) patients. The complications such as fever, bleeding, urinary leakage, and changes in hemoglobin and creatinine were not statistically significant.

DISCUSSION

When considering a PCNL procedure, surgeons are very cautious regarding one crucial step which is the

exact point in which the intended renal calyx should be punctured. Up to the present time, the radiological methods of ultrasound and fluoroscopy guidance have been combined to assist the surgeon in this purpose. The introduction of 3D virtual reconstructive imaging technology is able to resolve such issues through providing a better understanding of the location and position of renal calculi in relation with the adjunct anatomical structures. The use of such techniques has been associated with higher accuracy in the location of renal calculi, as well as a significant reduction in operational adverse effects.⁽⁸⁾

Porpiglia et al. reviewed the application of 3D reconstructive technologies in the field of urology. They concluded that despite its sporadic use and lack of comprehensive data in the meantime, such methods could prove to be of great aid in accurate surgical planning. In another report, they evaluated the use of 3D reconstructive imaging technology in robot-assisted radical prostatectomy and minimally invasive partial nephrectomy in a subjective manner. They reported a significant utility of 3D reconstructed printed models in surgical planning, anatomical representation and the role of technology in surgical training, as well as favourable feedbacks by the patients regarding the use of this technology in the process of their surgery.⁽⁷⁾

In another study by Porpiglia et al., the use of three-dimensional technique for partial nephrectomy in 21 patients, achieved successful results in 90% of the cases, in whom pre-operation expectations closely matched those of post-operation outcomes.⁽⁹⁾ According to their findings, the use of such a technique could potentially decrease the risk of post-operative renal ischemia. Toshitaka et al. reported excellent post-operative results in a study of four high-risk prostate cancer patients with a 1mm surgical margin, as determined under the guide of 3D reconstructive technology and evidenced by negative involvement of margins in the final pathology reports.⁽¹⁰⁾ Zhang et al. also reported that the use of 3D reconstructive techniques may be of practical use in the setting of T1N0M0 renal tumours in the hands of experienced surgeons.⁽¹¹⁾ One recent study introduced i-pad assisted navigation as a technique that uses pre-operation CT-scan in conjunction with an augmented reality (AR) feature in order to visualize the desired structures such as kidneys, ureters and prostate, in addition to their surrounding boundaries.⁽⁸⁾ An experimental study on animal models demonstrated a minute superiority of ultrasound guided renal puncture over i-Pad assisted and fluoroscopic-guided puncture in term of timing, as it was shown to be faster than its rival techniques.⁽¹²⁾

Although our study was unique in a global scale in terms of methodology and objectives, some of its aspects are comparable to several similar studies. In a study conducted by Linda Ce Lee et al., the sample size and the mean age of participants were found to be higher than our study.⁽¹³⁾ The percentage of patients who needed blood transfusion in the mentioned study was 0.6%, in contrast to the present study where no patient required any form of transfusion.

In a study of 118 PCNL candidates, Xu et al. compared the surgical measures of outcome between conventional ultrasound with fused 3D virtual reconstruction and ultrasound guided location of calculi. In line to our findings, they reported a significant improvement in accuracy, time to puncture, overall duration of surgery

and haemoglobin loss in the fused US and 3D reconstruction group (P -values < 0.001). In another study by Christiansen et al., evaluated the effectiveness of five different advanced imaging modalities during a complex renal surgical procedure. They reported that the 3D print model was helpful in providing a tangible model of the complex kidney with its insight into the location of the kidney stones and renal vasculature.⁽¹⁴⁾ In a recent similar study conducted by Tan et al.,⁽¹⁵⁾ the authors investigated the feasibility of 3D reconstruction method in PCNL for complex renal calculi treatment. The findings mirrored the results of our study in terms of shorter duration of surgery and higher first-time puncture success rate with significantly lower radiation exposure time among the intervention group compared to the controls.

The study's limitation is the small sample size. However, it could be viewed as a pilot study, and more study could be done to better understand this technique.

CONCLUSIONS

We conclude that the use of 3D reconstructive technology is an effective method in improving accuracy and time to access. More importantly, the application of this technique resulted in a significant reduction in the exposure to ionizing radiation during surgery. Larger sample sizes and in-depth analysis of clinical and demographic characteristics are necessary to further consolidate the finds of this study.

REFERENCES

1. Khan A. Prevalence, pathophysiological mechanisms and factors affecting urolithiasis. *Int Urol Nephrol*.2018; 50:799-806.
2. Lieske JC, Rule AD, Krambeck AE, et al. Stone composition as a function of age and sex. *Clin J Am Soc Nephrol*. 2014; 9:2141-6.
3. Bahmani M, Baharvand-Ahmadi B, et al. Identification of medicinal plants for the treatment of kidney and urinary stones. *J Renal Inj Prev*. 2016; 5:129-33.
4. Miller NL, Lingeman JE. Management of kidney stones. *BMJ*.2007;334:468-72.
5. de la Rosette JJ, Opondo D, Daels FP, et al. Categorisation of complications and validation of the Clavien score for percutaneous nephrolithotomy. *Eur Urol*. 2012; 62:246-55.
6. Autorino R, Porpiglia F, Dasgupta P. Precision surgery and genitourinary cancers. *Eur J Surg Oncol*. 2017; 43:893-908.
7. Porpiglia F, Amparore D, Checcucci E, et al. Current Use of Three-dimensional Model Technology in Urology: A Road Map for Personalised Surgical Planning. *Eur Urol Focus*. 2018;4:652-6.
8. Rassweiler-Seyfried MC, Rassweiler JJ, Weiss C, et al. iPad-assisted percutaneous nephrolithotomy (PCNL): a matched pair analysis compared to standard PCNL. *World J Urol*. 2020;38:447-53.
9. Porpiglia F, Bertolo R, Checcucci E, et al. Development and validation of 3D printed virtual models for robot-assisted radical prostatectomy and partial nephrectomy: urologists' and patients' perception. *World J Urol*.2018; 36:201-7.

10. Shin T, Ukimura O, Gill IS. Three-dimensional Printed Model of Prostate Anatomy and Targeted Biopsy-proven Index Tumor to Facilitate Nerve-sparing Prostatectomy. *Eur Urol.*2016; 69:377-9.
11. Zhang Y, Ge HW, Li NC, et al. Evaluation of three-dimensional printing for laparoscopic partial nephrectomy of renal tumors: a preliminary report. *World J Urol.*2016; 34:533-7.
12. Klein JT, Rassweiler J, Rassweiler-Seyfried MC. Validation of a Novel Cost Effective Easy to Produce and Durable In Vitro Model for Kidney-Puncture and Percutaneous Nephrolitholapaxy-Simulation. *J Endourol.*2018; 32:871-6.
13. Lee LC, Violette PD, Tailly T, et al. A comparison of outcomes after percutaneous nephrolithotomy in children and adults: a matched cohort study. *J Pediatr Urol.*2015; 11:250.1-6.
14. Christiansen AR, Shorti RM, Smith CD, Prows WC, Bishoff JT. Intraoperative utilization of advanced imaging modalities in a complex kidney stone case: a pilot case study. *World J Urol.*2018; 36:733-43.
15. Tan H, Xie Y, Zhang X, et al. Assessment of Three-Dimensional Reconstruction in Percutaneous Nephrolithotomy for Complex Renal Calculi Treatment. *Front Surg.* 2021;8:701207.