

## Endoscopic Resection Improved High-Intensity Focused Ultrasound Ablation Outcomes for Prostate Cancer: A Meta-Analysis of Comparative Studies

Yang Pan<sup>1#</sup>, Shangren Wang<sup>1#</sup>, Hang Zhou<sup>1#</sup>, Shuai Niu<sup>1</sup>, Xiaoqiang Liu<sup>1\*</sup>

**Purpose:** High-intensity focused ultrasound ablation (HIFU) is emerging as more data on its efficacy arises for prostate cancer (PCa). However, it is indefinite whether to combine endoscopic resection and uncertain to say who the ideal candidates are for the combined treatment. Therefore, we aimed to conduct a meta-analysis to compare outcomes of sole HIFU therapy with that of HIFU in combination with endoscopic resection in patients with localized PCa.

**Materials and Methods:** Electronic databases were searched following the PRISMA guidelines and PICOS formats. The inclusion criteria were as follows: 1) studies on HIFU for PCa patients; 2) comparative studies on HIFU in combination with endoscopic resection for localized PCa men. Exclusion criteria include non-comparative studies and salvage HIFU therapy. Meta-analysis results were mainly present using forest plots. Sensitivity analysis and Egger's test were adopted to determine the stability and assess the publication bias.

**Results:** Six comparative studies with 767 patients were eligible, including 487 cases in the combination therapy group and 280 cases in the monotherapy group. There was no statistical difference in age, preoperative PSA levels, and prostate volume between two groups. No statistical difference was found in postoperative PSA nadir (MD = -0.02, 95%CI: -0.35 to 0.31,  $P = 0.90$ ), disease-free survival rate (RR = 0.95, 95%CI: 0.83 to 1.09,  $P = 0.47$ ), and preoperative IPSS score (MD = -0.69, 95%CI: -1.63 to 0.26,  $P = 0.15$ ;  $I^2 = 8\%$ ) between two groups. The combination therapy group had significantly lower postoperative IPSS score (MD = -5.49, 95%CI: -6.47 to -4.51,  $P < 0.001$ ) and shorter catheterization time (MD = -13.70, 95%CI: -19.24 to -8.16,  $P < 0.001$ ) than the monotherapy group. The rates of urinary incontinence (7.4% vs. 13.9%, RR = 0.45, 95%CI: 0.29 to 0.70,  $P = 0.0004$ ;  $I^2 = 4\%$ ), acute urinary retention (6.8% vs. 10.5%, RR = 0.36, 95%CI: 0.14 to 0.89,  $P = 0.03$ ;  $I^2 = 0\%$ ), urinary tract infection (10% vs. 33%, RR = 0.27, 95% CI: 0.18 to 0.4,  $P < 0.001$ ;  $I^2 = 0\%$ ), epididymitis (1.2% vs. 15.7%, RR = 0.11, 95% CI: 0.02 to 0.59,  $P = 0.01$ ;  $I^2 = 0\%$ ), and urethral stricture (7.1% vs. 23.2%, RR = 0.3, 95%CI: 0.18 to 0.51,  $P < 0.001$ ;  $I^2 = 0\%$ ) in the combination therapy group were all significantly lower than that in the monotherapy group. Sensitivity analysis revealed findings were convincing and no publication bias ( $P = 0.62$ ) was observed using Egger's test.

**Conclusion:** It appears that the addition of endoscopic resection to the HIFU operation might not impact oncologic outcomes and could show better functional outcomes compared to the HIFU monotherapy in localized PCa patients.

**Keywords:** prostate cancer; high-intensity focused ultrasound ablation; endoscopic resections; meta-analysis

### INTRODUCTION

Prostate cancer (PCa) is a common urological disease in males, with the prevalence being extremely relevant to age, which was approximately 155 per 100,000 in 55-59 years old, 510 per 100,000 in 65-69 years old, and 751 per 100,000 in 75-79 years old, respectively<sup>(1)</sup>. A lot of localized PCa usually expand tardily and might not result in destructive impacts throughout PCa patients' lifetime. However, some comorbidities like urinary tract obstruction and ache of bone metastases may result from clinically significant cancers. Over the past many years, prostate-specific antigen (PSA) exams and prostate biopsy were two main methods applied for the diagnosis of PCa. In recent years, some new techniques

like multiparameter magnetic resonance imaging and genetic testing have been increasingly utilized as well<sup>(2)</sup>. Treatments of PCa are based on lesion position and disease stage. Active surveillance could avoid excessive clinical management and not impact the chance of cure<sup>(3)</sup>; however, it is an observational treatment for patients with low risk disease<sup>(4)</sup>. The objective of radical prostatectomy is the extermination of carcinoma and preservation of urinary function and erectile function. Outcomes after radical prostatectomy are associated with both surgeon's experience and the overall strength of the hospital<sup>(5,6)</sup>.

In current clinical practice, ablation therapy represents a more recent concept among active surveillance, radi-

<sup>1</sup>Department of Urology, Tianjin Medical University General Hospital, Tianjin, China.

<sup>#</sup>Contributed equally

\*Correspondence: Department of Urology, Tianjin Medical University General Hospital, Tianjin, China.

E-mail: xiaoqiangliu1@163.com

Received July 2022 & Accepted June 2023

**Table 1.** The definition of “subjective” and “objective” cure rate of the included studies

Author	Year	Study Country	Study design	Study duration	Anesthesia	Ablation Type	NOS Score	Quality assessment <sup>a</sup>
Sumitomo et al.	2010	Japan	Case-control study	Apr. 2002-Mar. 2010	NR	NR	Whole-gland 8	High-quality
Chaussy et al.	2003	Germany	Case-control study	NR	Spinal Anesthesia	Whole-gland 8	High-quality	High-quality
Poissonnier et al.	2007	France	Cross-sectional study	1993-2003	NR	NR	Whole-gland 8	High-quality
Otsuki et al.	2008	Japan	Case-control study	Apr. 2015-Aug. 2006	NR	Whole-gland 4	Moderate-quality	Moderate-quality
Baumunk et al.	2013	Germany	Case-control study	2005-2009	NR	Whole-gland 7	High-quality	High-quality
Horiuchi et al.	2016	Japan	Case-control study	Nov. 2006-Apr. 2010	General anesthesia	Whole-gland 6	Moderate-quality	Moderate-quality

**Abbreviations:** HIFU, High-intensity focused ultrasound ablation; NOS, Newcastle-Ottawa quality assessment scale; NR, Not reported.  
<sup>a</sup>Quality was evaluated by Newcastle-Ottawa quality assessment scale.

ation, and definitive radical treatments. Ablation therapy can target the most aggressive lesions of PCa and preserve the function of non-invasive prostate tissue; thus, ablation therapies may minimize treatment toxicity and could provide relatively better equilibriums among functional and oncological outcomes<sup>(7)</sup>. A previous consensus meeting reported that ablation therapy could be identified as the coagulative necrosis of index lesions<sup>(8)</sup>. The distinguishing characteristic of ablation therapy is to directionally destroy PCa lesions and protect adjacent normal tissue. Common ablation therapies are mainly made up of focal laser ablation, cryotherapy ablation, and high-intensity focused ultrasound ablation (HIFU)<sup>(9)</sup>. These treatment methods use individual templates including index lesion ablation, gland Hemi-ablation, and whole-gland ablation<sup>(10)</sup>.

Among available alternative therapeutic options for PCa, HIFU represents a promising technique. Ultrasound waves had been first used to focus on and treat lesion tissues about 80 years ago<sup>(11)</sup>. HIFU can directly focus ultrasound waves on cancer tissue, which can heat the tissue and lead to coagulative necrosis<sup>(12)</sup>. Plenty of diseases such as uterine fibroids, liver tumors, and breast tumors have been managed by HIFU and showed considerable efficacy and safety<sup>(13-15)</sup>. In regards to urological diseases, HIFU is regarded as an available treatment for localized PCa patients, or regarded as a salvage treatment in failure cases after radiation treatment currently<sup>(16)</sup>. Panzone et al. reported that HIFU was proved as an effective and feasible management for patients having localized PCa with satisfying oncologic control and function preservation in the short term<sup>(17)</sup>. Schmid et al. also reported that ablation of PCa diseased tissue using HIFU therapy was feasible and presented a satisfactory incidence of perioperative adverse events<sup>(18)</sup>.

HIFU is emerging as more data on its efficacy arises<sup>(19)</sup>. When HIFU is performed independently and not combined with other additional procedures, a frequent complication is the occurrence of urinary tract obstruction resulting from edema or fibering<sup>(20)</sup>. Subsequently, patients could be painful because urinary catheter was required to retain longer time for avoiding the occurrence of acute urinary retention (AUR) or other serious complications. Thus, an obvious downside is that the urinary catheter has to be indwelled for 2-3 weeks after HIFU operation. The catheterization for a long time could result in urinary tract infections (UTIs), urethral stenosis, and other comorbidities. Many prior articles revealed a relatively high urethral stenosis rate after HIFU. Thus, experts advocate new opinions and ways in order to reduce postoperative urinary catheter indwelling time.

Some studies have reported that performing HIFU combined with endoscopic resection could significantly decrease the incidence of prolonged catheterization retention significantly and result in a more favorable evolution in the international prostate symptom score (IPSS)<sup>(21-28)</sup>. However, it is indefinite whether to combine endoscopic resection. Therefore, our meta-analysis aimed to analyze functional and oncologic outcomes and evaluate the feasibility and efficacy of HIFU combined with endoscopic resection compared to sole HIFU therapy in patients with localized PCa. In doing so, our study could illustrate who the ideal candidates are for the treatment, such as smaller gland, no LUTS and so on.

## MATERIALS AND METHODS

### Search strategy

The present systematic review and meta-analysis were performed as per the PRISMA guidelines. The research question was based on the PICOS rule: population (patients with PCa), intervention (endoscopic resection in combination with HIFU), comparison (sole HIFU therapy), outcomes (treatments outcomes and follow-up outcomes), and study design (the type of studies in terms of their methods).

PubMed, Embase, and Cochrane Library were systematically retrieved. The retrieval time range was set up to July 10, 2022. The searching keywords included: (“prostate cancer”) AND (“high-intensity focused ultrasound ablation”) AND (“endoscopic resection” OR “bladder neck incision” OR “urethrotomy” OR “transurethral resection of prostate” OR “holmium laser enucleation of the prostate”). All patients included in the results must be an adult. Sole HIFU therapy was defined as only HIFU operation for PCa and not using other surgeries. HIFU with endoscopic resection meant that HIFU operation and other endoscopic resection surgeries such as HoLEP were both applied for managing PCa. All identified studies were then reviewed for eligibility. The reference lists and citations from key studies were also reviewed for additional eligible studies associated with our topic.

### Inclusion and exclusion criteria

The inclusion criteria were as follows: 1) study types: prospective or retrospective comparative studies; 2) studies on HIFU for PCa cases; 3) comparative studies on HIFU in combination with endoscopic resection for localized PCa men. Besides, the exclusion criteria were set according to the following items: 1) non-comparative studies; 2) salvage HIFU therapy; 3) comment; 4) case report; 5) review; 6) repeated publication.

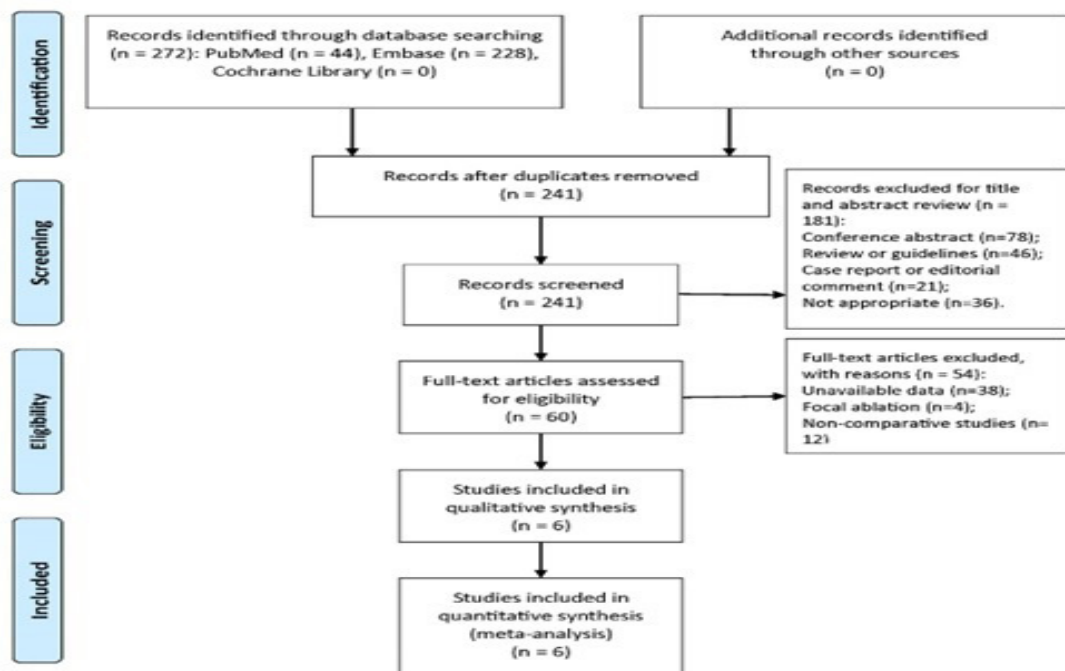


Figure 1. Flow diagram of identification and screening of eligible studies (PRISMA flow diagram).

### Data extraction and outcome measurement

All available data in each eligible study were extracted, respectively, by two separate authors and next verified one another. If there was any controversy, a third author would participate in and debate with the previous two authors to make an agreement. Meanwhile, we tried our best to get in touch with the authors of each included study to demand complete data. We considered that the complete oncologic, functional, and other detailed data were extremely beneficial to better analyze relevant results of HIFU combined with endoscopic resection for localized PCa.

Functional outcomes included preoperative IPSS score, postoperative IPSS scores in 6 months, the urinary catheter indwelling time, urinary incontinence rate, and erectile dysfunction (ED). Partial urinary symptoms were assessed using IPSS score and then identified as mild symptoms (0-7 scores), moderate symptoms (8-19 scores), and severe symptoms (20-35 scores). Partial sexual potency was assessed using the International Index of Erectile Function (IIEF-5) score scale and then classified as severe ED (5-7 scores), moderate ED (8-11 scores), mild to moderate ED (12-16 scores), mild ED (17-21 scores), and no ED (22-25 scores). Oncologic outcomes included postoperative PSA nadir, average month to achieve PSA nadir level, and 2-year disease-free survival rate (DFSFR) after HIFU operation.

### Quality assessment

The quality of eligible articles was evaluated, respectively, by two separate authors and then verified each other. Newcastle-Ottawa scale (NOS) was applied for evaluating the quality of non-randomized controlled studies<sup>(29)</sup>. The quality was evaluated using the total scores of 3 sections in the NOS scale, which were comprised of subject selection, group comparability, and ascertainment of exposure or outcome. The assessed

study was identified as low-quality (0-3 scores), moderate-quality (4-6 scores), and high-quality (7-9 scores).

### Statistical analysis

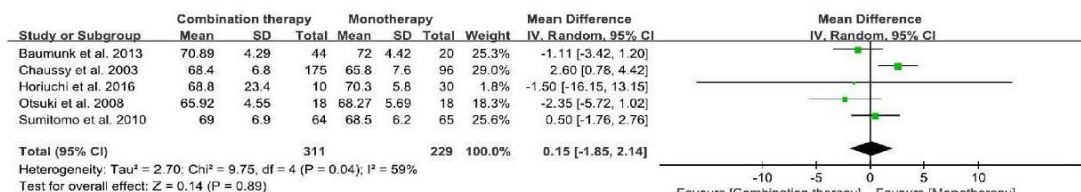
Categorical variables were present in the form of N (%). The mean difference (MD) with their 95% confidence interval (CI) was used to assess the outcomes of pooling different measures in meta-analysis to yield a summary estimate. The risk ratios (RR) with 95%CI were used to compare dichotomous variables. The heterogeneity was analyzed using Cochrane Q test and Higgins I<sup>2</sup> value. The fixed-effects model was performed if the heterogeneity was acceptable (I<sup>2</sup> < 50%), and the random-effects model was conducted if obvious heterogeneity existed (I<sup>2</sup> ≥ 50%). Moreover, we have accounted for some confounding covariates in our analysis, such as age, PSA, and prostate volume. Sensitivity analysis was applied for identifying the reliability of outcomes through excluding one study each time. Egger's test was performed to analyze the publication bias. All statistical analysis was performed using Review Manager 5.4 and STATA 15.1 software. The p-value of < .05 was considered statistically significant.

## RESULTS

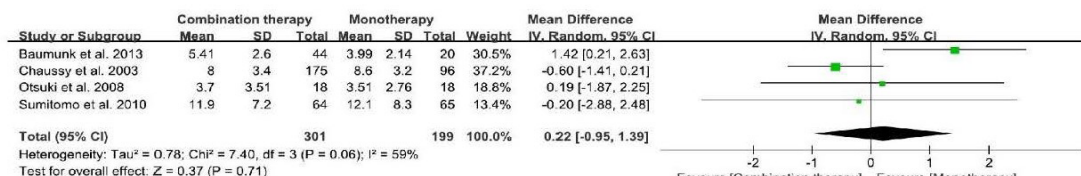
A PRISMA flow chart of screening articles was shown in Figure 1. Overall, 272 relevant studies were retrieved through PubMed, Embase, and Cochrane Library. There were 60 remaining studies eligible for reading full text. Eventually, six comparative studies were included in quantitative synthesis<sup>(30-35)</sup>. According to NOS scale, 4 studies were identified as high-quality and 2 study was identified as moderate-quality. There was no low-quality study included in our review. The detailed results of quality assessment using NOS scale were listed in **Table 1**.

Most studies mentioned that endoscopic resection had

A



B



C

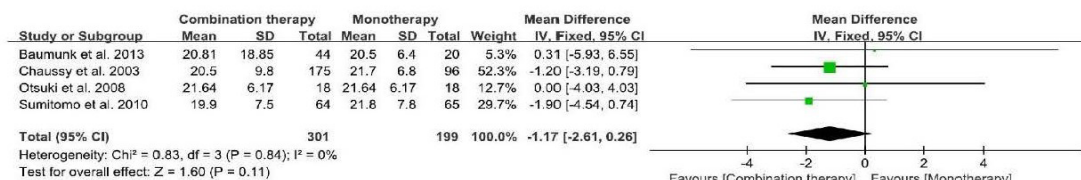
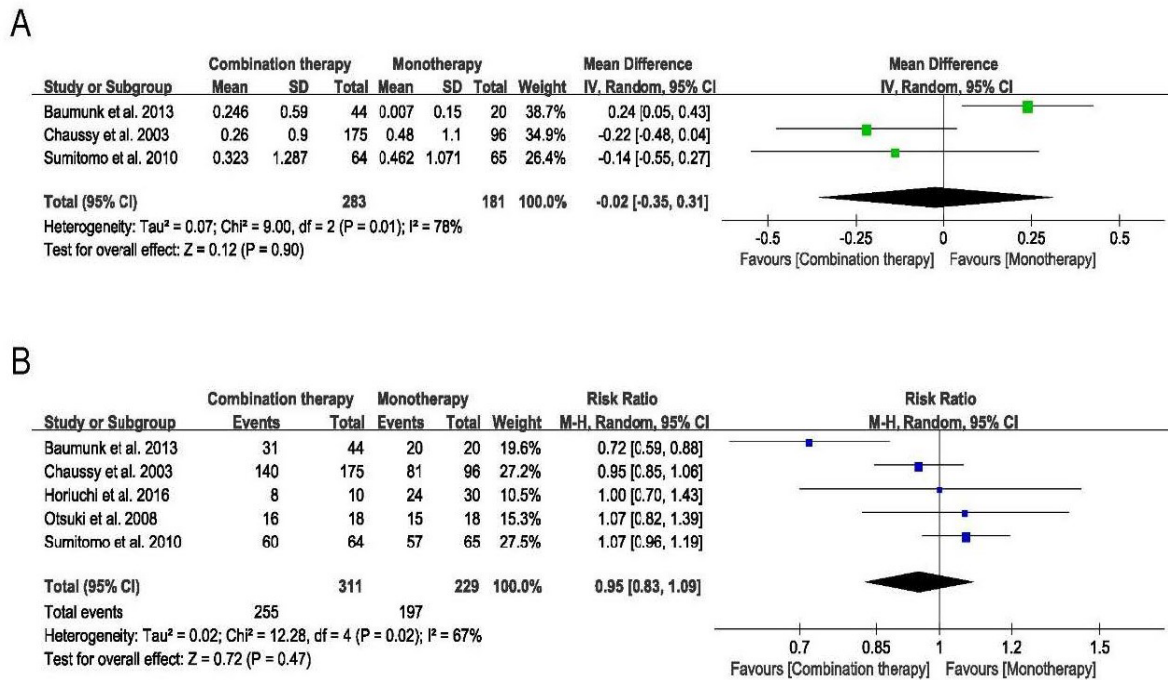


Figure 2. Forest plots of age (A), preoperative PSA levels (B), and preoperative prostate volume (C) between the combination therapy group and the monotherapy group.

been undergone in order to decrease prostatic volume or to manage patients complain of obstructive symptoms. Some studies mentioned that when prostatic volume before HIFU therapy was relatively small and less than 40 cc, endoscopic resection and HIFU treatment were usually conducted in single session; when prostatic volume before HIFU therapy was large and more than 40 cc, HIFU would be performed after 2-4weeks of endoscopic resection. The type of HIFU ablation in all whole-gland ablation in all included studies. Totally, 767 PCa men were involved, including 487 cases in the combination therapy group and 280 cases in the monotherapy group. According to D'Amico criteria, 4 studies revealed that they used HIFU to manage low, intermediate, and high-risk PCa patients. Even though high-risk PCa cases had been treated by HIFU, the proportion of these high-risk cases in the overall population was still relatively low (74/767, 9.6%). Average age of all included cases distributed between 65.8 and 72.8 years old. Meta-analysis results showed that no statistical difference was found in age between both groups (MD = 0.15, 95% CI: -1.85 to 2.14, P = 0.89; I<sup>2</sup> = 59%; **Figure 2A**). Moreover, the mean PSA levels before HIFU were distributed between 3.99 and 12.1 ng/mL in all included studies. Meta-analysis results showed that no statistical difference was found in PSA levels before HIFU between both groups (MD = 0.22, 95% CI: -0.95 to 1.39, P = 0.71; I<sup>2</sup> = 59%; **Figure 2B**). Similarly, the mean prostate volume before HIFU was distributed between 19.9 and 38.9 mL in all included studies. Meta-analysis results also showed that no statistical difference was found in prostate volume before HIFU between both groups (MD = -1.17, 95% CI: -2.61 to 0.26, P = 0.11; I<sup>2</sup> = 0%; **Figure 2C**). Most studies provided follow-up serum PSA levels and

either the postoperative PSA nadir level or latest PSA level. Average postoperative PSA nadir was distributed between 0.007 and 0.846 ng/mL in all included studies, while mean months to PSA nadir ranged from 3.5 to 15.1 months postoperatively. Meta-analysis results showed that no statistical difference was found in postoperative PSA nadir between both groups (MD = -0.02, 95% CI: -0.35 to 0.31, P = 0.90; **Figure 3A**). However, significant heterogeneity was reported (P = 0.01, I<sup>2</sup> = 78%, **Figure 3A**). Five studies reported the DFSR after HIFU in the two groups, respectively. The DFSR in the short term was 82% (255/311) in the combination therapy group and 86% (197/229) in the monotherapy group. Meta-analysis results showed that no statistical difference was found in the DFSR after HIFU between both groups (RR = 0.95, 95% CI: 0.83 to 1.09, P = 0.47; **Figure 3B**). Some comparative studies reported preoperative and postoperative IPSS score between both groups. Meta-analysis results revealed that no statistical difference was found in preoperative IPSS score (MD = -0.69, 95% CI: -1.63 to 0.26, P = 0.15; I<sup>2</sup> = 8%; **Figure 4A**). However, meta-analysis results revealed that the combination therapy group had a significantly lower postoperative IPSS score than the monotherapy group (MD = -5.49, 95% CI: -6.47 to -4.51, P < 0.001; I<sup>2</sup> = 78%; **Figure 4B**). Four comparative studies that reported the postoperative urinary catheter indwelling time between both groups. Meta-analysis results revealed that the combination therapy group also had a significantly shorter time than the monotherapy group (MD = -13.70, 95% CI: -19.24 to -8.16, P < 0.001; I<sup>2</sup> = 95%; **Figure 4C**). Five comparative studies reported the rate of urinary incontinence. The rates of urinary incontinence were





**Figure 3.** Forest plots of postoperative PSA nadir (A) and disease-free survival rate (B) between the combination therapy group and the monotherapy group.

7.4% (32/433) and 13.9% (32/230) in the two groups, respectively. Meta-analysis results revealed that the rate of urinary incontinence in the combination therapy group was significantly lower than that in the monotherapy group (RR = 0.45, 95% CI: 0.29 to 0.70, *P* = 0.0004; I<sup>2</sup> = 4%; **Figure 5A**).

The rates of de novo ED postoperatively were 39.4% in the combination therapy group and 41.7% in the monotherapy group. Meta-analysis results showed that no statistical difference was found in the postoperative ED rate between both groups (RR = 1.09, 95% CI: 0.59 to 2.02, *P* = 0.78; I<sup>2</sup> = 83%; **Figure 5B**).

All included studies reported the rates of postoperative complications. The rates of AUR (6.8% vs. 10.5%, RR = 0.36, 95% CI: 0.14 to 0.89, *P* = 0.03; I<sup>2</sup> = 0%; **Figure 6A**), UTIs (10% vs. 33%, RR = 0.27, 95% CI: 0.18 to 0.4, *P* < 0.001; I<sup>2</sup> = 0%; **Figure 6B**), epididymitis (1.2% vs. 15.7%, RR = 0.11, 95% CI: 0.02 to 0.59, *P* = 0.01; I<sup>2</sup> = 0%; **Figure 6C**), and urethral stricture (7.1% vs. 23.2%, RR = 0.3, 95% CI: 0.18 to 0.51, *P* < 0.001; I<sup>2</sup> = 0%; **Figure 6D**) in the combination therapy group were all significantly lower than that in the monotherapy group.

When removing the study by Baumunk et al., 12 of postoperative PSA nadir decreased from 78% to 0%. It indicated this research was the main reason for heterogeneity of postoperative PSA nadir. Heterogeneities of other outcomes were small and steady, while 1 or 2 studies were removed each time. Thus, sensitivity analysis revealed our outcomes were reliable. Moreover, no publication bias on outcomes such as the postoperative urinary catheter indwelling time (*P* = 0.109, **Figure 7A**) and the rate of urethral stricture (*P* = 0.62, **Figure 7B**) was observed with the Egger’s test.

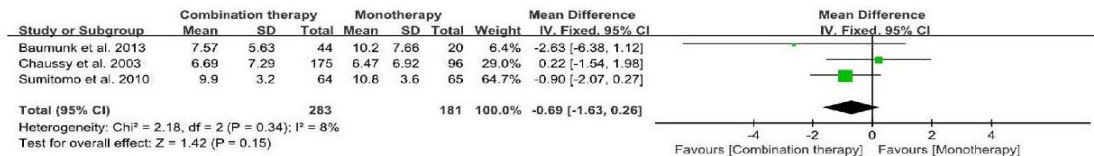
**DISCUSSION**

This study innovatively compared outcomes of HIFU

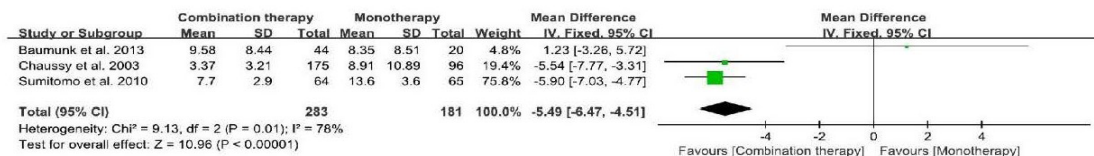
combined with endoscopic resection with that of sole HIFU therapy in localized PCa patients. Meta-analysis of comparative studies revealed that the combination of endoscopic resection with HIFU treatment might not impact postoperative PSA nadir and DFSR. Furthermore, we found that the combination therapy could 1) shorten postoperative urinary catheter indwelling time; 2) decrease the rates of postoperative urinary incontinence, AUR, UTIs, epididymitis, and urethral stricture; and 3) improve postoperative urinary symptoms significantly. Therefore, the addition of endoscopic resection to the HIFU treatment appeared not to impact oncologic outcomes and could show better functional results in localized PCa men compared to the HIFU monotherapy. Moreover, patients with large prostate volume or LUTS might be ideal candidates to choose the combined resection therapy.

According to previous experience, the urinary catheter was usually indwelled for approximately fourteen to twenty-one days after HIFU operation<sup>(36,37)</sup>. Furthermore, there were nearly a third of the patients needed additional treatments such as urethrotomy to treat obstruction postoperatively. To avoid the risk of prolonged urinary retention associated with post-HIFU edema and the risk of urinary obstruction, endoscopic resection was performed preoperatively in many institutions. EAU guidelines mention that the resection of the prostate or the bipolar enucleation could be proposed as the first choice for the operative treatment of relatively large prostatic volumes<sup>(38)</sup>. The combination of endoscopic resection with HIFU showed many benefits. Calcifications on the prostatic transitional zone might influence the focus and efficacy of HIFU surgery. Endoscopic resection could eliminate these calcifications and subsequently reduce the operating time of HIFU. Moreover, endoscopic resection can decrease the diameter of anterior-posterior zone in the prostate with a rel-

A



B



C

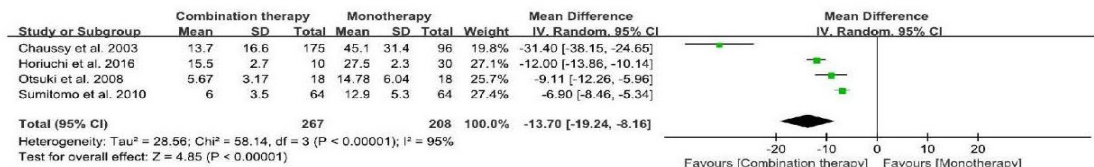
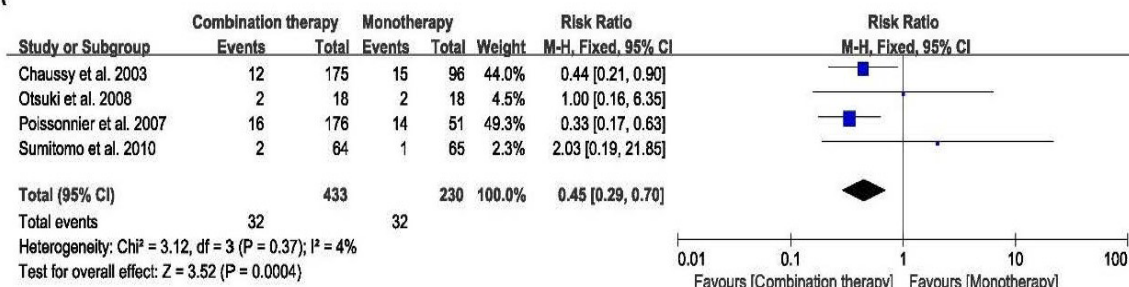


Figure 4. Forest plots of preoperative IPSS score (A), postoperative IPSS score (B), and postoperative urinary catheter indwelling time (C) between the combination therapy group and the monotherapy group.

atively large volume, so using single-session HIFU to manage PCa in the peripheral zone could come true<sup>(35)</sup>. Two significant functional outcomes included urinary incontinence and ED after the HIFU procedure. He et al. found that the overall incidences of urinary incontinence and ED post HIFU ablation operation were 10%

and 44%, respectively<sup>(39)</sup>. Our study revealed similar rates of incontinence and ED post HIFU ablation operation in localized PCa with previous studies. Moreover, we showed similar ED rates between the combination therapy group and the monotherapy group. However, the combination therapy group had a significantly low-

A



B

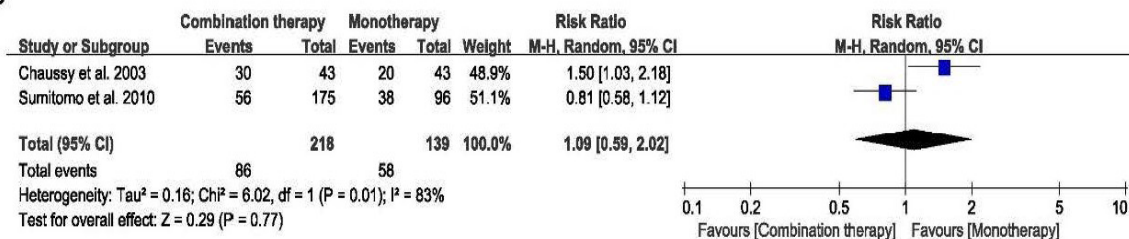


Figure 5. Forest plots of urinary incontinence (A) and erectile dysfunction (B) between the combination therapy group and the monotherapy group.

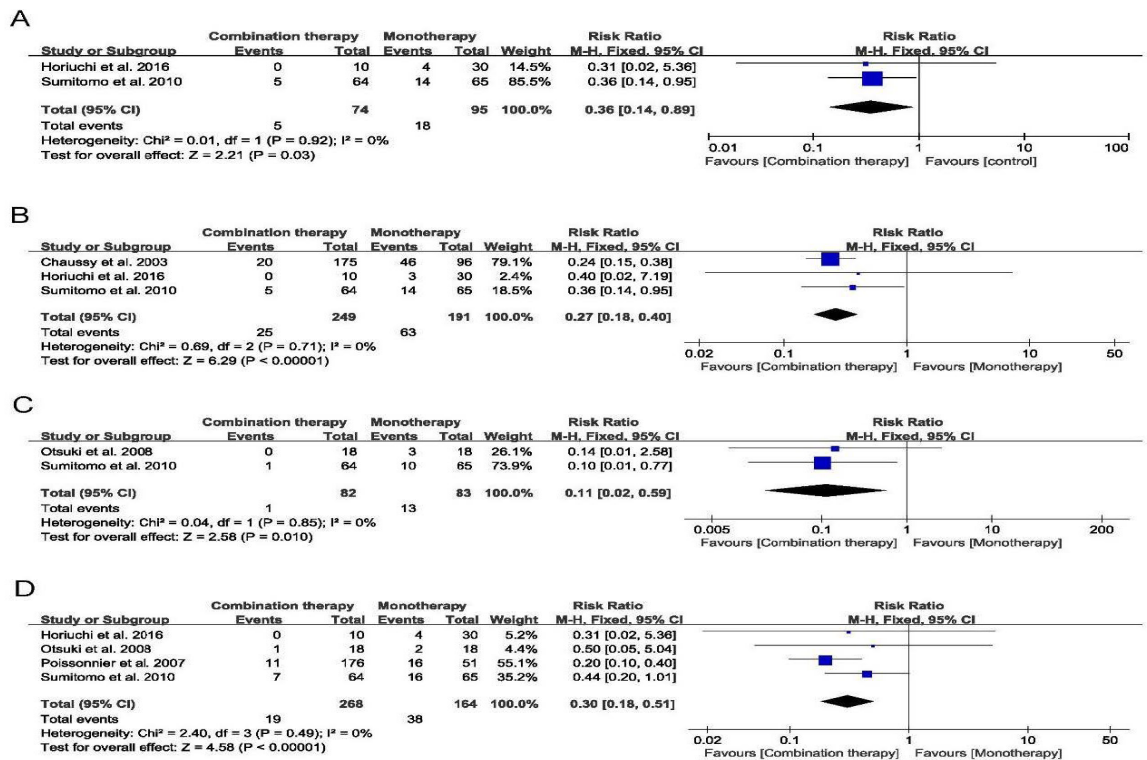


Figure 6. Forest plots of acute urinary retention (A), urinary tract infection (B), epididymitis (C), and urethral stricture (D) between the combination therapy group and the monotherapy group.

er rate of urinary incontinence in comparison with the monotherapy group  
Ripert et al. conducted large-scale research to deter-

mine oncologic outcomes after HIFU treatment without a combined endoscopic resection in localized PCa men and revealed that the range of postoperative PSA nadir value was 0.01-14 ng/mL<sup>(40)</sup>. Similarly, Ganzer et al. also completed a single-center study on 538 PCa men to assess oncologic results in a long period using HIFU without a combined endoscopic resection for localized PCa. They found that the exact rate of biochemical failure was 19 and 39% at postoperative five and ten years, respectively<sup>(41)</sup>. Our study found that the DFSR was almost consistent with these previous studies and no obvious difference was found in the DFSR between both groups. It seems that oncologic outcomes had not been impacted by the addition of endoscopic resection to the HIFU operation.

There were no comparative studies that reported the results of partial-gland HIFU and endoscopic resection therapy. Therefore, we did not analyze the therapeutic results using partial-gland HIFU ablation in combination with endoscopic resection in the present study. Whole-gland HIFU ablation and partial-gland HIFU ablation have their special advantages. Regardless of the types of HIFU ablation (whole-gland ablation, or partial-gland HIFU ablation), when HIFU is performed independently, the disadvantages such as large volume prostate or calcifications on the prostate could still exist. Thus, HIFU combined with endoscopic resection might still be beneficial for patients using partial-gland HIFU ablation. More prospective trials are also required to validate the exact differences between the partial-gland HIFU ablation combined with endoscopic resection and the sole partial-gland HIFU ablation therapy in localized PCa patients.

Some limitations might exist in the present study. One of main limitations is that the published articles about

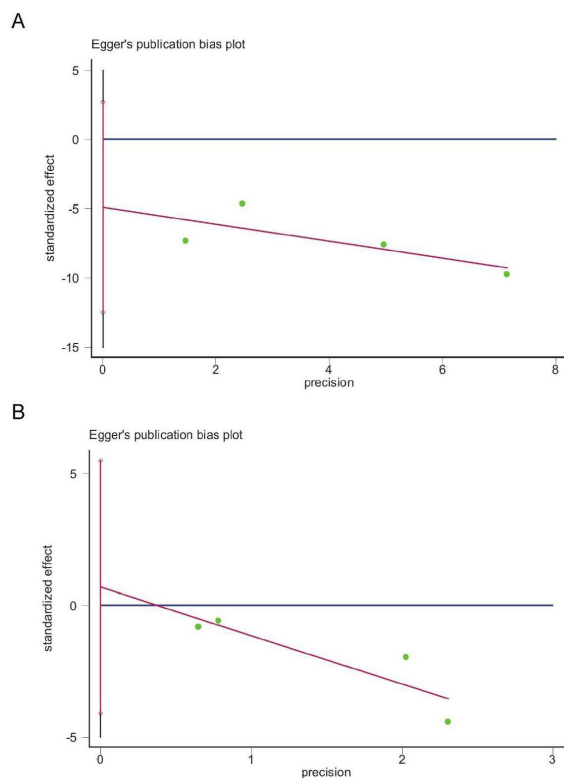


Figure 7. Egger's plots for the postoperative urinary catheter indwelling time (A) and the rate of urethral stricture (B).



HIFU ablation and endoscopic resection for localized PCa might exist potential heterogeneity. Even though some international consensuses have attempted to promote terminology and follow-up of ablative treatment standards, outcomes reported by different HIFU centers might still show potential variation<sup>(42-44)</sup>. The methods of reporting outcomes of survey questionnaires and complications might also exist partial differences, even though the majority of studies used the validated survey questionnaires to obtain the postoperative outcomes. However, sensitivity analysis indicated the findings were relatively reliable and no obvious publication bias existed according to Egger's test. Therefore, our study might still be helpful for providing some important information on HIFU therapy in localized PCa patients with a relatively high level of evidence.

## CONCLUSIONS

It appears that the addition of endoscopic resection to the HIFU operation might not impact oncologic outcomes and can improve localized PCa men compared to HIFU monotherapy. The endoscopic resection with HIFU treatment might reduce prostate volume, shorten catheterization time, decrease postoperative urinary incontinence, AUR, UTIs, epididymitis, and urethral stricture rates, and improve urinary symptoms in comparison with HIFU treatment solely. Proper case inclusion, experienced surgeons with excellent HIFU experience, and a multicentric prospective randomized controlled trial with longer follow-up durations are required to confirm and validate our findings in the future.

## ACKNOWLEDGEMENT

Our study was funded by National Natural Science Foundation of China (No. 82171594).

## CONFLICT OF INTEREST

The authors report no conflict of interest.

## REFERENCES

- Grozescu T, Popa F. Prostate cancer between prognosis and adequate/proper therapy. *J Med Life*. 2017;10:5-12.
- Drost FH, Osses DF, Nieboer D, Steyerberg EW, Bangma CH, Roobol MJ, et al. Prostate MRI, with or without MRI-targeted biopsy, and systematic biopsy for detecting prostate cancer. *Cochrane Database Syst Rev*. 2019;4:Cd012663.
- Mottet N, van den Bergh RCN, Briers E, Van den Broeck T, Cumberbatch MG, De Santis M, et al. EAU-EANM-ESTRO-ESUR-SIOG Guidelines on Prostate Cancer-2020 Update. Part 1: Screening, Diagnosis, and Local Treatment with Curative Intent. *Eur Urol*. 2021;79:243-62.
- Cooperberg MR, Lin DW, Morgan TM, Chapin BF, Chen RC, Eggener SE. Active Surveillance: Very Much "Preferred" for Low-Risk Prostate Cancer. *J Urol*. 2022;207:262-4.
- Begg CB, Riedel ER, Bach PB, Kattan MW, Schrag D, Warren JL, et al. Variations in morbidity after radical prostatectomy. *N Engl J Med*. 2002;346:1138-44.
- Gershman B, Meier SK, Jeffery MM, Moreira DM, Tollefson MK, Kim SP, et al. Redefining and Contextualizing the Hospital Volume-Outcome Relationship for Robot-Assisted Radical Prostatectomy: Implications for Centralization of Care. *J Urol*. 2017;198:92-9.
- Polascik TJ, Mouraviev V. Focal therapy for prostate cancer is a reasonable treatment option in properly selected patients. *Urology*. 2009;74:726-30.
- Donaldson IA, Alonzi R, Barratt D, Barret E, Berge V, Bott S, et al. Focal therapy: patients, interventions, and outcomes--a report from a consensus meeting. *Eur Urol*. 2015;67:771-7.
- Valerio M, Cerantola Y, Eggener SE, Lepor H, Polascik TJ, Villers A, et al. New and Established Technology in Focal Ablation of the Prostate: A Systematic Review. *Eur Urol*. 2017;71:17-34.
- Ward JF, Nakanishi H, Pisters L, Babaian RJ, Troncoso P. Cancer ablation with regional templates applied to prostatectomy specimens from men who were eligible for focal therapy. *BJU Int*. 2009;104:490-7.
- Fry FJ, Ades HW, Fry WJ. Production of reversible changes in the central nervous system by ultrasound. *Science*. 1958;127:83-4.
- Heidenreich A, Bellmunt J, Bolla M, Joniau S, Mason M, Matveev V, et al. EAU guidelines on prostate cancer. Part 1: screening, diagnosis, and treatment of clinically localised disease. *Eur Urol*. 2011;59:61-71.
- Dababou S, Marrocchio C, Scipione R, Erasmus HP, Ghanouni P, Anzidei M, et al. High-Intensity Focused Ultrasound for Pain Management in Patients with Cancer. *Radiographics*. 2018;38:603-23.
- Arrigoni F, Napoli A, Bazzocchi A, Zugaro L, Scipione R, Bruno F, et al. Magnetic-resonance-guided focused ultrasound treatment of non-spinal osteoid osteoma in children: multicentre experience. *Pediatr Radiol*. 2019;49:1209-16.
- Verpalen IM, Anneveldt KJ, Nijholt IM, Schutte JM, Dijkstra JR, Franx A, et al. Magnetic resonance-high intensity focused ultrasound (MR-HIFU) therapy of symptomatic uterine fibroids with unrestrictive treatment protocols: A systematic review and meta-analysis. *Eur J Radiol*. 2019;120:108700.
- Maestroni U, Tafuri A, Dinale F, Campobasso D, Antonelli A, Ziglioli F. Oncologic outcome of salvage high-intensity focused ultrasound (HIFU) in radiorecurrent prostate cancer. A systematic review. *Acta Biomed*. 2021;92:e2021191.
- Panzone J, Byler T, Bratslavsky G, Goldberg H. Transrectal Ultrasound in Prostate Cancer: Current Utilization, Integration with mpMRI, HIFU and Other Emerging Applications. *Cancer Manag Res*. 2022;14:1209-28.
- Schmid FA, Schindele D, Mortezaei A, Spitznagel T, Sulser T, Schostak M, et al. Prospective multicentre study using high intensity focused ultrasound (HIFU) for the



- focal treatment of prostate cancer: Safety outcomes and complications. *Urol Oncol.* 2020;38:225-30.
19. Mottet N, Bellmunt J, Bolla M, Briers E, Cumberbatch MG, De Santis M, et al. EAU-ESTRO-SIOG Guidelines on Prostate Cancer. Part 1: Screening, Diagnosis, and Local Treatment with Curative Intent. *Eur Urol.* 2017;71:618-29.
  20. Blana A, Hierl J, Rogenhofer S, Lunz JC, Wieland WF, Walter B, et al. Factors Predicting for Formation of Bladder Outlet Obstruction After High-Intensity Focused Ultrasound in Treatment of Localized Prostate Cancer. *Urology.* 2008;71:863-7.
  21. Hong SK, Lee H. Outcomes of partial gland ablation using high intensity focused ultrasound for prostate cancer. *Urol Oncol.* 2022.
  22. Nair SM, Hatiboglu G, Relle J, Hetou K, Hafron J, Harle C, et al. Magnetic resonance imaging-guided transurethral ultrasound ablation in patients with localised prostate cancer: 3-year outcomes of a prospective Phase I study. *BJU Int.* 2021;127:544-52.
  23. Klotz L, Pavlovich CP, Chin J, Hatiboglu G, Koch M, Penson D, et al. Magnetic Resonance Imaging-Guided Transurethral Ultrasound Ablation of Prostate Cancer. *J Urol.* 2021;205:769-79.
  24. Rebillard X, Soulié M, Chartier-Kastler E, Davin JL, Mignard JP, Moreau JL, et al. High-intensity focused ultrasound in prostate cancer; a systematic literature review of the French Association of Urology. *BJU Int.* 2008;101:1205-13.
  25. Chaussy C, Thueroff S. Local radical tumor ablation through combined transurethral resection and transrectal high intensity focused ultrasound: A valid therapy to treat high risk prostate cancer? *Journal of Urology.* 2016;195:e201-e2.
  26. Christian C, Stefan T. Transurethral prostate resection (TURP) before high intensity focused ultrasound (HIFU) therapy of prostate cancer (PCA) is there an advantage in immediate or delayed HIFU treatment. *Journal of Endourology.* 2011;25:A2-A3.
  27. Thueroff S, Neumayr A, Bosl M, Kiel H, Steil W, Chaussy C. Modified transurethral resection before high intensity focused ultrasound (rHIFU) efficacy and side effects: Experience and analysis of 1.000 cases. *Journal of Endourology.* 2009;23:A13.
  28. Thueroff S, Chaussy C. Impact of Transurethral Resection (TUR) before Robotic High Intensity Focused Ultrasound (RHIFU) therapy in prostate cancer. *Urology.* 2009;74:S134.
  29. Stang A. Critical evaluation of the Newcastle-Ottawa scale for the assessment of the quality of nonrandomized studies in meta-analyses. *Eur J Epidemiol.* 2010;25:603-5.
  30. Baumunk D, Andersen C, Heile U, Ebbing J, Cash H, Porsch M, et al. [High-intensity focussed ultrasound in low-risk prostate cancer - oncological outcome and postinterventional quality of life of an inexperienced therapy centre in comparison with an experienced therapy centre]. *Aktuelle Urol.* 2013;44:285-92.
  31. Sumitomo M, Asakuma J, Sato A, Ito K, Nagakura K, Asano T. Transurethral resection of the prostate immediately after high-intensity focused ultrasound treatment for prostate cancer. *Int J Urol.* 2010;17:924-30.
  32. Otsuki H, Sumitomo M, Umeda S, Shirotake S, Tobe M, Ito K, et al. Transurethral resection of prostate just following high intensity focused ultrasound in localized prostate cancer -Trial for early removal of the urethral catheter. *Acta Urologica Japonica.* 2008;54:189-95.
  33. Poissonnier L, Chapelon JY, Rouvière O, Curiel L, Bouvier R, Martin X, et al. Control of prostate cancer by transrectal HIFU in 227 patients. *Eur Urol.* 2007;51:381-7.
  34. Chaussy C, Thüroff S. The status of high-intensity focused ultrasound in the treatment of localized prostate cancer and the impact of a combined resection. *Current Urology Reports.* 2003;4:248-52.
  35. Horiuchi A, Muto S, Horie S. Holmium laser enucleation of the prostate followed by high-intensity focused ultrasound treatment for patients with huge prostate adenoma and localized prostate cancer: 5-Year follow-up. *Prostate International.* 2016;4:49-53.
  36. Hopstaken JS, Bomers JGR, Sedelaar MJP, Valerio M, Fütterer JJ, Rovers MM. An Updated Systematic Review on Focal Therapy in Localized Prostate Cancer: What Has Changed over the Past 5 Years? *European Urology.* 2022;81:5-33.
  37. Uchida T, Shoji S, Nakano M, Hongo S, Nitta M, Murota A, et al. Transrectal high-intensity focused ultrasound for the treatment of localized prostate cancer: eight-year experience. *Int J Urol.* 2009;16:881-6.
  38. Gratzke C, Bachmann A, Descazeaud A, Drake MJ, Madersbacher S, Mamoulakis C, et al. EAU Guidelines on the Assessment of Non-neurogenic Male Lower Urinary Tract Symptoms including Benign Prostatic Obstruction. *Eur Urol.* 2015;67:1099-109.
  39. He Y, Tan P, He M, Hu L, Ai J, Yang L, et al. The primary treatment of prostate cancer with high-intensity focused ultrasound: A systematic review and meta-analysis. *Medicine (Baltimore).* 2020;99:e22610.
  40. Ripert T, Azémar MD, Ménard J, Barbe C, Messaoudi R, Bayoud Y, et al. Six years' experience with high-intensity focused ultrasonography for prostate cancer: oncological outcomes using the new 'Stuttgart' definition for biochemical failure. *BJU Int.* 2011;107:1899-905.
  41. Ganzer R, Fritsche HM, Brandtner A, Bründl J, Koch D, Wieland WF, et al. Fourteen-year oncological and functional outcomes of high-intensity focused ultrasound in localized prostate cancer. *BJU Int.* 2013;112:322-9.
  42. Muller BG, van den Bos W, Brausi M,

- Fütterer JJ, Ghai S, Pinto PA, et al. Follow-up modalities in focal therapy for prostate cancer: results from a Delphi consensus project. *World J Urol.* 2015;33:1503-9.
43. Postema AW, De Reijke TM, Ukimura O, Van den Bos W, Azzouzi AR, Barret E, et al. Standardization of definitions in focal therapy of prostate cancer: report from a Delphi consensus project. *World J Urol.* 2016;34:1373-82.
44. Scheltema MJ, Tay KJ, Postema AW, de Bruin DM, Feller J, Fütterer JJ, et al. Utilization of multiparametric prostate magnetic resonance imaging in clinical practice and focal therapy: report from a Delphi consensus project. *World J Urol.* 2017;35:695-701.