

A Case of Bladder and Rectal Injury Due to Dislodgement of Leg Brace During Ureteroscopic Lithotripsy

Chunhong Yu¹, Junjiang Liu², Qingle Xu², Helong Xiao², Bo Gao², Liuxiong Guo², Shoubin Li^{2*}

Dear Editor:

The lithotomy position is commonly used in urological surgery. Dislodgement of the leg brace can lead to accidental injury to patient or surgical staff. If the displacement happened during the operation, it can lead to more serious consequences. Bladder and rectal injury due to leg brace dislodgement has not been reported. How to deal with this situation is a challenge for surgeons.

A 66-year-old man admitted to the hospital due to "intermittent pain in the left lumbar region for more than 30 days". CT scan showed a calculus in the upper left ureter, measuring about 15 (long diameter) × 9 (transverse diameter) mm. Holmium laser lithotripsy was performed after routine perioperative preparation. The right leg brace suddenly fell off during the operation, and the patient's body slid down consequently, which caused the front end of the ureteroscope pierced the posterior wall of the bladder and the anterior wall of the rectum. The treatment plan was formulated after multidisciplinary discussion during the operation, that is, enteroscopy and enteroscopic closure of rectal perforation after ureteral stent placement and catheterization. A perforation with a diameter of about 3mm was observed in the anterior rectal wall nearly 10 cm from the anus (Figure 1). No damage was found in other sites. several titanium clips were used to close the rectal perforation under enteroscope. The patient fasted for 2 days after operation and was given a broad-spectrum antibiotic (meropenem). Haematological analysis revealed mild leukocytosis (white blood cell count: $9.56 \times 10^9/L$), which returned to normal on postoperative day 3. Postoperative pelvic CT examination did not show any significant signs of peritonitis (Figure 2). A liquid diet was started on postoperative day 3. The patient was discharged after the urinary catheter was removed two weeks after surgery. Rectal injury is mostly caused by nosocomial factors, such as colonoscopy,⁽¹⁾ and bladder perforation usually occurs in case of medical injuries or traumas.⁽²⁾ If the injury is lower than the peritoneal reflex, it will lead to severe perirectal infection without peritonitis symptoms or vesicorectal fistula, and may be life-threatening. While, there is a lack of consensus on the optimal treatment protocol for rectal injury by now. The traditional treatment is colostomy and colon diversion, and the colon is reduced after the rectal perforation heals.⁽³⁾ With the development of enteroscopic techniques, small clean perforations in return can be treated with enteroscopic titanium clip closure.⁽²⁾ In the present case, no bowel preparation was performed preoperatively, which posed a great challenge to deal with the rectal perforation. We finally treated the rectal perforation with titanium clip closure and bladder perforation

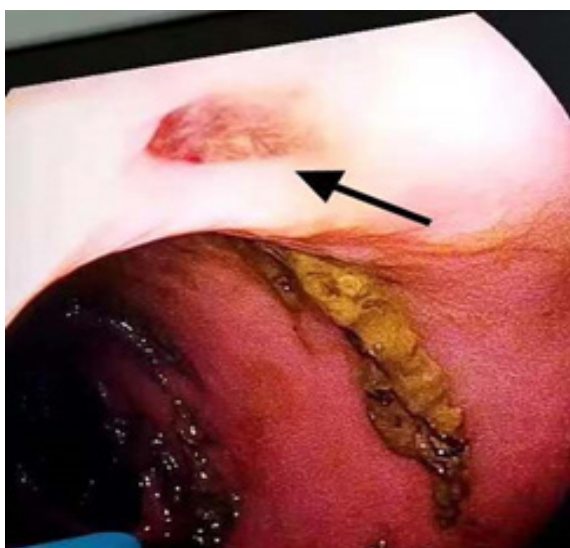


Figure 1. A perforation with a diameter of about 3mm was observed in the anterior rectal wall (indicated by an arrow) under colonoscopy.

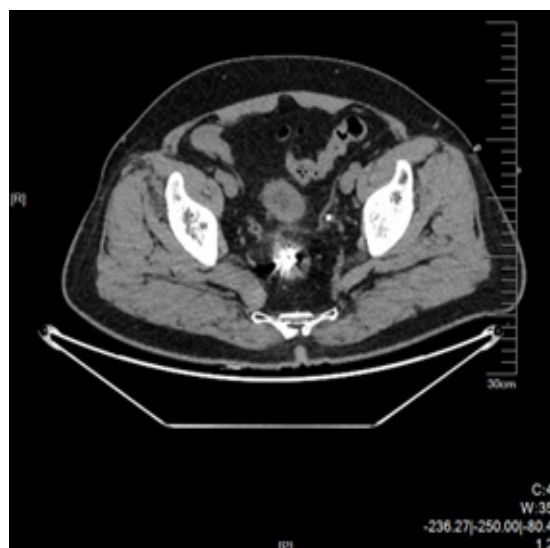

Figure 2. CT scan shows a nodular high-density shadow (titanium clips) in the rectal cavity, without fluid or gas accumulation around the rectum.

¹Department of Health Examination Center, Hebei General Hospital, Shijiazhuang, Hebei 050051, China.

²Department of Urology, Hebei General Hospital, Shijiazhuang, Hebei 050051, China.

*Correspondence: Department of Urology, Hebei General Hospital, Shijiazhuang, Hebei 050051, China.

Tel: +86 0311 85988751, E-mail: hbghurology@163.com

with indwelling catheter. This situation and corresponding treatment measures has not been reported before, and this reminds us that small perforations, even in the absence of bowel preparation, can be considered for a one-stage colonoscopic management of the perforation to avoid more invasive management.

There are several reasons for the successful management of this rare case. Firstly, early detection and timely treatment is the key point. According to literature reports, the intestinal perforation found within 24 hours after colonoscopy is tends to be repaired by one-stage intestine neoplasty. While, the perforation found 24 hours later is more likely to be operated by enterostomy.⁽⁴⁾ Secondly, the perforation caused by ureteroscopy is small, which makes it possible to seal it with titanium clip under enteroscope. Finally, the rectal injury is non pyrogenic. If it is a pyrogenic injury, it will lead to tissue degeneration and difficult wound healing.

In conclusion, intraoperative emergency is an uncommon but serious event. Routine checking the relevant equipments should be mandatory to ensure the safety of patients and medical staffs. Proper treatment plan is beneficial to the rehabilitation of patient and can avoid doctor-patient disputes.

REFERENCES

1. Kones O, Akarsu C, Acar T, Alis H. Endoscopic repair of rectal perforation due to colonoscopy with a clamp method. *J Turk Surg.* 2018;34:80-82.
2. Matlock KA, Tyroch AH, Kronfol ZN, McLean SF, Pirela-Cruz MA. Blunt traumatic bladder rupture: a 10-year perspective. *J Am Surg.* 2013;79:589-593.
3. Benjelloun EB, Ahallal Y, Khatala K, Souiki T, Kamaoui I, Taleb KA. Rectal impalement with bladder perforation: A review from a single institution. *J Urol Ann.* 2013;5:249-254.
4. Iqbal CW, Cullinane DC, Schiller HJ, Sawyer MD, Zietlow SP, Farley DR. Surgical management and outcomes of 165 colonoscopic perforations from a single institution. *Arch Surg.* 2008;143(7):701-6.