

Multi-Detector Computed Tomography Angiography of a Ruptured Giant Renal Angiomyolipoma with Pseudoaneurysm and Associated Saccular Dilatation of Left Renal Artery

Umesh C. Parashari, Sachin Khanduri, Samarjit Bhadury, Gaurav Singh

Department Radio Diagnosis, Era's
Lucknow Medical College, Lucknow,
India

Keywords: angiomyolipoma; tomography; X-ray computed; rupture; embolism; laparoscopy; magnetic resonance imaging.

INTRODUCTION

Angiomyolipoma (AML) is a neoplastic lesion consisting of mature blood vessels, smooth muscle cells and fat tissue. Its most common site is kidney. The common complication is rupture with intrarenal or peri lesional hemorrhage depending on size of the tumor. The treatment depends on the size and clinical features of the tumor, usually being embolization.

CASE REPORT

A 55-year old female presented with history of acute abdominal pain, localized to the left flank following a minor trauma after a fall. Lab investigations revealed low hemoglobin count and hematuria. On ultrasonography, a heterogenous mass measuring approximately $15 \times 20 \times 13$ cm in the left renal area arising from the upper and mid pole region being visible. A provisional diagnosis of renal mass with possible hemorrhage was made. On contrast enhanced computed tomography (CT) scan there was evidence of a large exophytic heterogeneous mass measuring approximately $13.2 \times 10.8 \times 19.0$ cm having predominantly fat attenuation (Figure 1). Mass lesion is in anterolateral cortex of upper and middle pole of left kidney displacing and compressing residual renal parenchyma posteromedially and lower pole anteromedially. CT angiography was done in the same setting. On angiography dilated tortuous left renal artery was seen with mild dilation of its branches supplying the mass lesion. There was evidence of a large lobulated vascular sac like lesion of approximate size

Corresponding author:

Umesh Chandra Parashari, MD
Department Radio Diagnosis, Era's
Lucknow Medical College, Lucknow,
India

Tel: +94 150 88926

E-mail: id-drumesh.rd@gmail.com

Received June 2011

Accepted September 2011

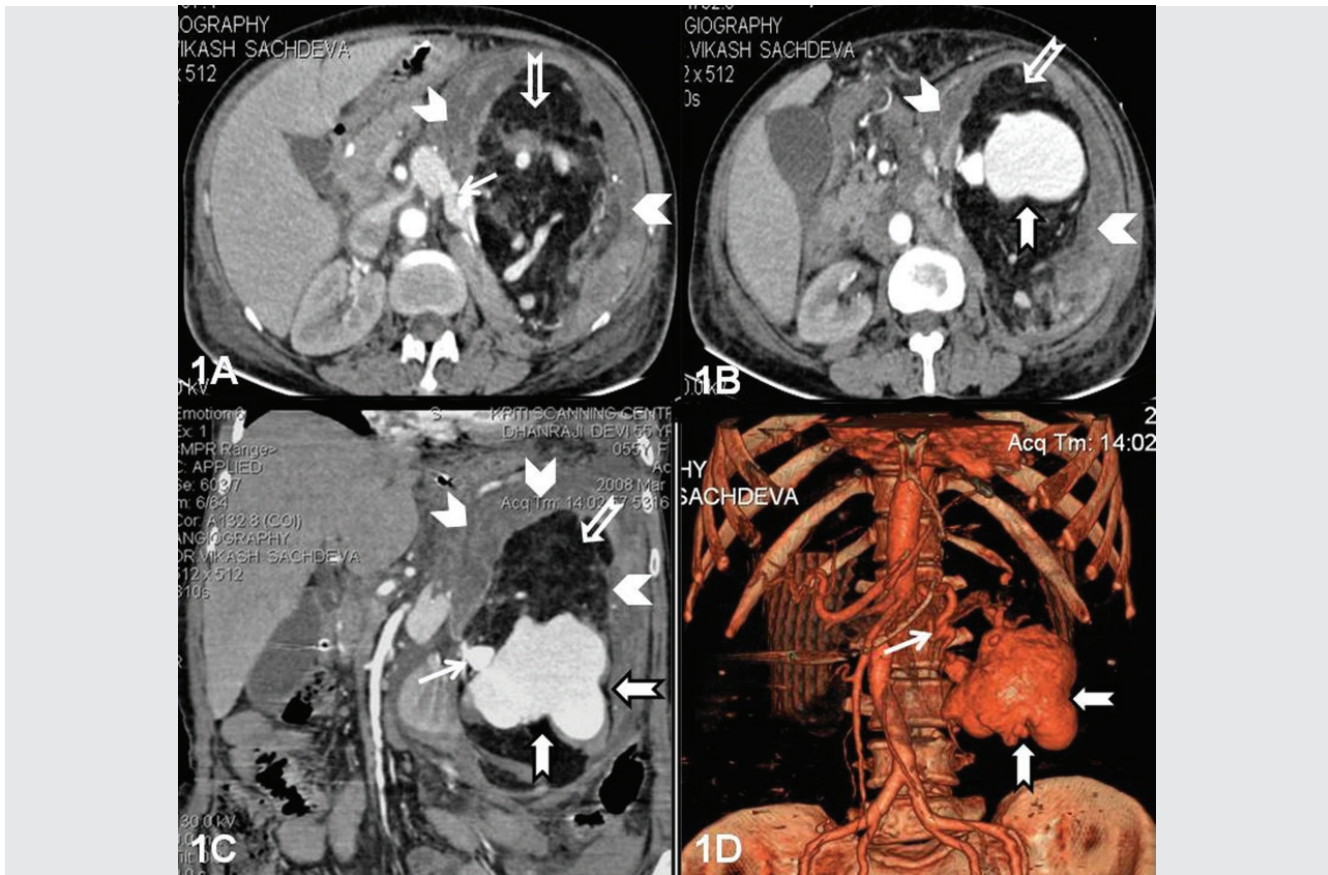


Figure 1. Axial On contrast enhanced computed tomography (1A and 1B) and coronal reformation (1C) showing a large exophytic heterogeneous left renal mass having predominantly fat attenuation (open white arrow) arising anterolateral cortex of upper and middle pole of left kidney with a thick rim of hyperdense hematoma (white arrow head). A large lobulated vascular sac like lesion is seen in the center of the mass (thick white arrow). Volume rendered coronal image (1D) during angiography phase showing dilated tortuous left renal artery (thin white arrow) with a large lobulated pseudoaneurysm in center of the mass (thick white arrow).

7.4 × 4.8 × 7.0 cm in center of the lesion which showed homogenous filling in arterial phase and persistent filling in portal venous phase. Multiple small saccular dilatations of renal artery branches were also seen (Figure 2). A diagnosis of large AML on left side with multiple saccular aneurysmal dilatations of branches of left renal artery was made. Patient was immediately taken for surgery and a partial nephrectomy was performed along with embolization of the pseudoaneurysm. The operated tumor tissue was sent for histopathology which confirmed our diagnosis of AML.

DISCUSSION

There are two types of AML: classic renal AML containing smooth muscle, vascular, and fat tissue, and very rarely

infiltrating perirenal tissue; and a second type of AML containing a large fourth component, perivascular epithelioid cells, making it more aggressive.^(1,2,3) AML either occur in isolation or as multiple lesions associated with tuberous sclerosis in 20% of cases.⁽⁴⁾ The AMLs are caused by mutations in either the tuberous sclerosis complex (TSC1) or TSC2 genes, which govern cell growth and proliferation.⁽⁵⁾ The classic symptoms includes flank pain, a palpable tender mass or signs of internal bleeding caused by intracapsular or retroperitoneal hemorrhage.^(1,6) Few present with shock following hemorrhage due to rupture of blood vessels. Wunderlich's syndrome, a spontaneous retroperitoneal hemorrhage of non-traumatic origin occurs in up to 50% of patients with tumors less than 40 mm.⁽⁶⁾ Abdominal CT

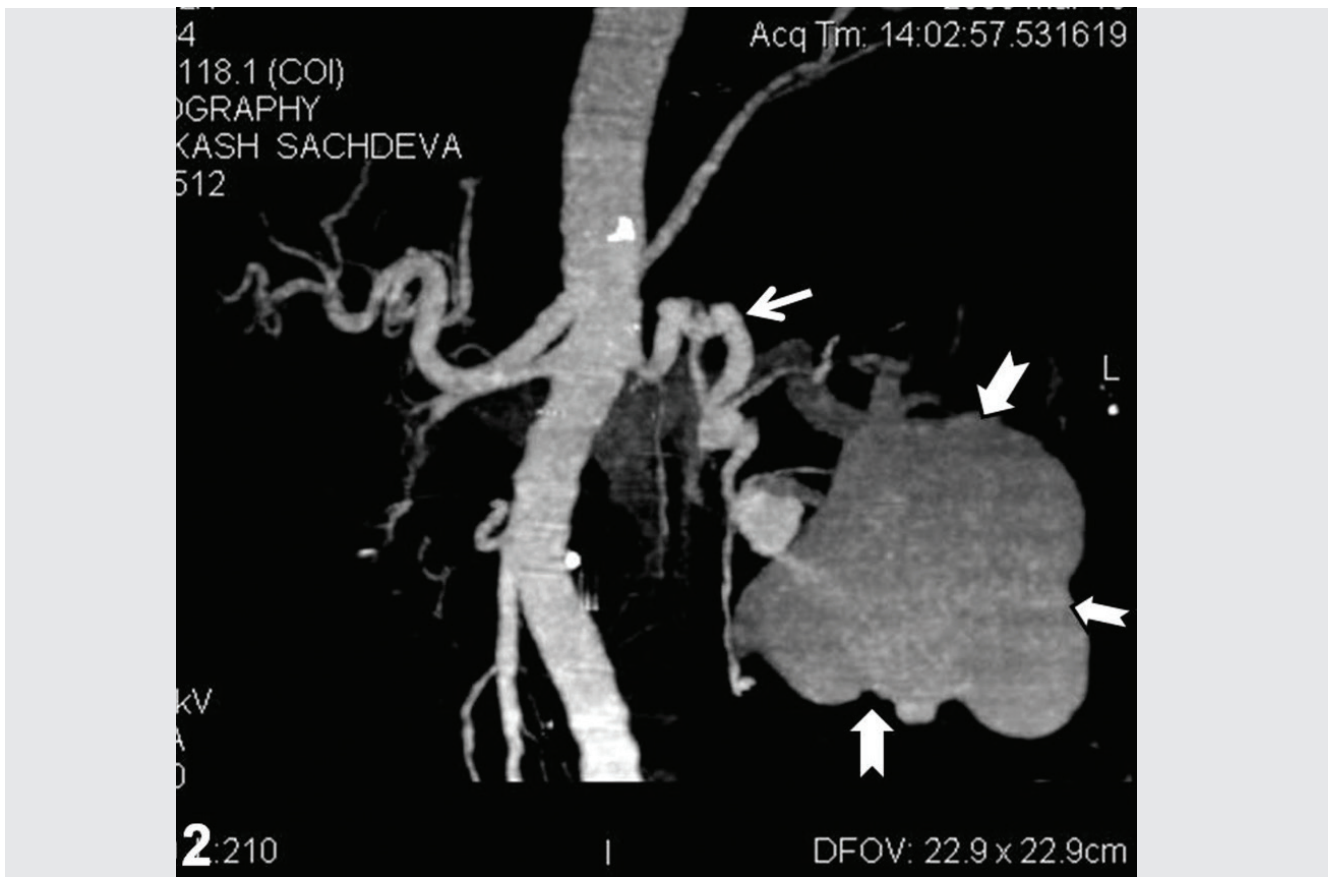


Figure 2. Computed tomography angiography MIP (maximum intensity projection) image shows dilated tortuous left renal artery (thin white arrow) and a large intra-lesion pseudoaneurysm on left side (thick white arrow).

scanning is the diagnostic tool of choice to diagnose and differentiate between various causes of a renal mass, and assess the size of the AML and the extent of hemorrhage.^(1,3) Fat density within a non-calcified renal mass remains the most important diagnostic finding of AML. On magnetic resonance imaging (MRI) sequences the tumor appears hyperintense on T1 weighted and T2 weighted sequences due to presence of fat. Recent advances in CT and MR angiography may improve the detection of aneurysm formation in these tumors.^(7,8) Various treatment modalities available for AML depend upon its size. Embolization and partial or total nephrectomy are usually done. Larger lesions require treatment such as surgical excision or embolization. Medium sized lesions need monitoring and follow up.⁽⁹⁾ Embo-

lization is the preferred therapy and appears to be the most successful nephron sparing procedure or to reduce the size or to stop bleeding during acute situations. Life threatening complications can be avoided if diagnostic tests and therapeutic interventions are readily available.

CONFLICT OF INTEREST

None declared.

REFERENCES

1. Bissler JJ, Kingswood JC. Renal angiomyolipomata. *Kidney Int.* 2004;66:924-34.
2. Oesterling JE, Fishman EK, Goldman SM, Marshall FF. The management of renal angiomyolipoma. *J Urol.* 1986;135:1121-4.

3. Pruijm M T, Falke T H, Peltenburg H G. [Retroperitoneal bleeding caused by renal angiomyolipoma] *Ned Tijdschr Geneeskd.* 2003;147:1696-9.
4. Casper KA, Donnelly LF, Chen B, Bissler JJ. Tuberous sclerosis complex: renal imaging findings. *Radiology.* 2002;225:451-6.
5. Bissler JJ, Henske EP. Renal Manifestations of Tuberous Sclerosis Complex. In: *Tuberous Sclerosis Complex: From Genes to Therapeutics.* In: Kwiatkowski DJ, Thiele EA, Whittemore V, editors. Weinheim, Germany: Wiley-Blackwell; 2010. p. 321-325.
6. Albi G, del Campo L, Tagarro D. Wunderlich's syndrome: causes, diagnosis and radiological management. *Clin Radiol.* 2002;57:840-5.
7. Joarder R, Gedroyc WM. Magnetic resonance angiography: the state of the art. *Eur Radiol.* 2001;11:446-453.
8. Hayashi H, Kawamata H, Ishio M, Kumazaki T. Multiple renal artery aneurysms diagnosed by three-dimensional CT angiography. *Clin Imaging.* 2000;24:221-23.
9. Dickinson M, Ruckle H, Beagler M, Hadley HR. Renal angiomyolipoma: optimal treatment based on size and symptoms. *Clin Nephrol.* 1998;49:281-6.