

Presurgical Orthodontics in Class III Patients: Extraction versus Non-Extraction

Reza Tabrizi^{a*}, Hosein Behnia^a, Zeinab Behroozi^b, Zahra Javanmardi^b

^aDepartment of Oral and Maxillofacial Surgery, Dental School, Shahid Beheshti University of Medical Sciences, Tehran, Iran; ^b Department of Orthodontic Dentistry, Shiraz University of Medical Sciences, Shiraz, Iran

*Corresponding author: Reza Tabrizi, Department of Oral and Maxillofacial Surgery, Shahid Beheshti University of Medical Sciences, Daneshjou Blvd., Evin Ave., Chamran Expressway, Tehran, Iran. *E-mail:* Tabmed@gmail.com; *Tel:* +98-912 5850829

Submitted: 2016-03-18; Accepted: 2016-04-25

Introduction: Matching dental discrepancy (DD) with skeletal discrepancy (SD) in pre-surgical orthodontic preparation is crucial for obtaining a desirable surgical outcomes. The aim of the present study was to compare DD to SD in class III patients with and without extraction of the maxillary second premolars. **Materials and Methods:** This retrospective cohort study assessed subjects in two groups: the 1st group included individuals who were afflicted by class III skeletal and underwent non-extraction orthodontic treatment prior to the surgery; the 2nd group, included: patients who suffered from class III skeletal malocclusion and underwent tooth-extraction orthodontic treatment prior to the surgery. The Wits analysis was applied to establish the apical base relationship between the maxillary and the mandibular arches as measured along the Jacobson occlusal plane. Two angles were applied to determine the upper and lower incisors position to the skeletal base: IMPA (the lower incisor teeth to the mandibular plane) and the upper 1 to SN. The horizontal distance between the upper and lower incisors+2 mm was considered as the dental discrepancy. **Results:** Forty-six individuals were studied in the 1st group and 31 patients included in the 2nd group. The mean for DD was 7.39±3.40 mm in the 1st group and 9.65±2.57 mm in the 2nd group. The mean was 11.59±4.9 mm in group 1 and 8.48±2.35 mm in group 2. Pearson's correlation did not show any significant correlation between dental discrepancy and the skeletal discrepancy in the 1st group ($P>0.05$). A positive correlation was obtained between dental discrepancy and the skeletal discrepancy in the 2nd group ($P<0.001$). **Conclusion:** It was magnificently attained that extraction of the second premolars of the maxilla could be a better match for DD and SD in the pre-surgical preparation in class III patients with an excessive SD.

Keywords: Orthodontic treatment ;Class III skeletal; Skeletal discrepancy; Osteotomy

Introduction

The cephalometric radiography has been a routine in orthodontics diagnosis and treatment planning. In orthognathic surgery, cephalometric records play a key role for maxillofacial surgeons to predict and plan treatment prior to the surgeries. However, facial aesthetics and a proper occlusion are the main concerns for the surgeon (1).

According to the statistics, class III patients are a large population of patients who seek surgical-orthodontic treatment. Nearly all the population with Class III malocclusions have dentoalveolar and skeletal problems; nonetheless, not sever cases can often get treated with only orthodontic treatments. However, patients with significant Class III skeletal discrepancies are often treated with mandibular, maxillary or bimaxillary orthognathic surgery in conjunction with orthodontic appliances (2).

The main purpose of pre-surgical orthodontic treatment is adjustment of the skeletal discrepancy with the dental discrepancy to provide the maximal aesthetic outcomes after the surgery. To achieve the mentioned goal, a precise analysis of patient's records,

cephalometric radiographs, casts, and photographs are required (3). The second maxillary premolar extraction has been recognized as an acceptable approach, for decompensation and preparation, before orthognathic surgery in class III patients (4). It is believed that extraction treatment could make incisor decompensation intact; therefore, the mandible can retrude into a more desirable position (5) and there is lack of data on comparison of skeletal discrepancy with the dental discrepancy in patients right before the surgery in extraction and non-extraction orthodontics.

Materials and Methods

This retrospective cohort study assessed the population of subjects who referred to the Department of Oral and Maxillofacial Surgery from September 1, 2011 to September 31, 2016 at Chamran hospital, Shiraz, Iran. The research was approved by the ethics committee at Shahid beheshti University of Medical Sciences. Subjects eligible for inclusion included patients with class III skeletal problems who had underwent orthodontic treatment for

Table 1. Definition of cephalometric points and indexes

Cephalometric points and angles	Definitions
A POINT	The innermost point on the contour of the premaxilla between anterior nasal spine and the incisor.
B POINT	The innermost point on the contour of the mandible between incisor tooth and the bony chin.
NA POINT(NASION)	The anterior point of the intersection between the nasal and frontal bones.
S POINT	The midpoint of the cavity of sellatursica.
GO POINT(GONION)	The midpoint of the contour connecting the ramus and body of the mandible.
GN POINT(GNATHION)	The center of the inferior point on the mandibular symphysis.
OCCLUSAL PLANE	A plane formed by the occlusal surfaces of the first molar and first premolars when the jaw is closed.
MANDIBULAR PLANE:	The line draw from GO point to GN point.
ANB ANGLE	The angle between N_A line and N_B line.
Upper 1 to S-N ANGLE	The angle between the long axis of upper central and S-N plane.
IMPA	The angle between the long axis of lower central and mandibular plane.

Table 2. Correlation of DD with SD in the two groups

Groups	Skeletal discrepancy (mm)	Dental discrepancy (mm)	Pearson's Correlation
Group1	11.59±4.9	7.39± 3.40	$P>0.05$
Group 2	8.48±2.35	9.65±2.57	$P<0.001$

Table 3. Comparison of the angle of the anterior teeth to the skeletal base and ANB angle between the two groups

Variables	Group 1	Group 2	Independent t-test
IMPA	87.24±6.14	88.71±2.47	$P>0.05$
U1 to SN	104.15±5.97	98.74± 3.36	$P<0.001$
ANB angle	4.15±6.30	2.84±1.03	$P<0.05$
Crowding (mm)	5.17±1.23	4.87±1.24	$P>0.05$

orthognathic surgery; in addition, they had cephalometric and clinical records just before the surgery. Subjects were excluded from the study if they did not have pre-surgical orthodontic treatment or had moderate to severe crowding before the orthodontic treatment, asymmetry, history of maxillofacial trauma, or were partially edentulous. The entire subjects underwent bimaxillary osteotomy. Subjects were divided into two groups: the first group included, individuals with class III skeletal relationship and underwent non-extraction orthodontic treatment; the 2nd group experienced class III skeletal relationship and underwent tooth-extraction orthodontic treatment. In group two, the second maxillary premolars were removed during pre-operation orthodontic treatment.

Crowding was defined as a difference between the available arch length and space required. The available arch length was measured by using a brass wire between the first molars on casts; the pace required was calculated by sums of the mesiodistal width of exact 12 teeth between the first molars. The amount of crowding was measured in each group.

Dental discrepancy was measured in each subject by using

a ruler. The horizontal distance of the upper and lower incisors + 2 mm was considered as the dental discrepancy.

Cephalometric technique

The individuals were positioned in the cephalostat (Orthoceph; Siemens AG, Munich, Germany), then the head holder was adjusted until the ear rods could be positioned into the ears without moving the patient. All radiographs were taken in the NHP with teeth together and lips in repose and with a metric ruler in front of the midfacial vertical line and no occipital supplement was used. According to the cephalometric standards, a film distance to the X-ray tube was fixed at 150 cm and the film distance to the midsagittal plane of the patient's head, at 18 cm.

Tracing technique

All the cephalograms were traced by a single operator on Garware matted acetate tracing paper 0.003" thickness and with 3 H microlead pencil. Cephalometric landmarks were located, identified, and marked indeed.



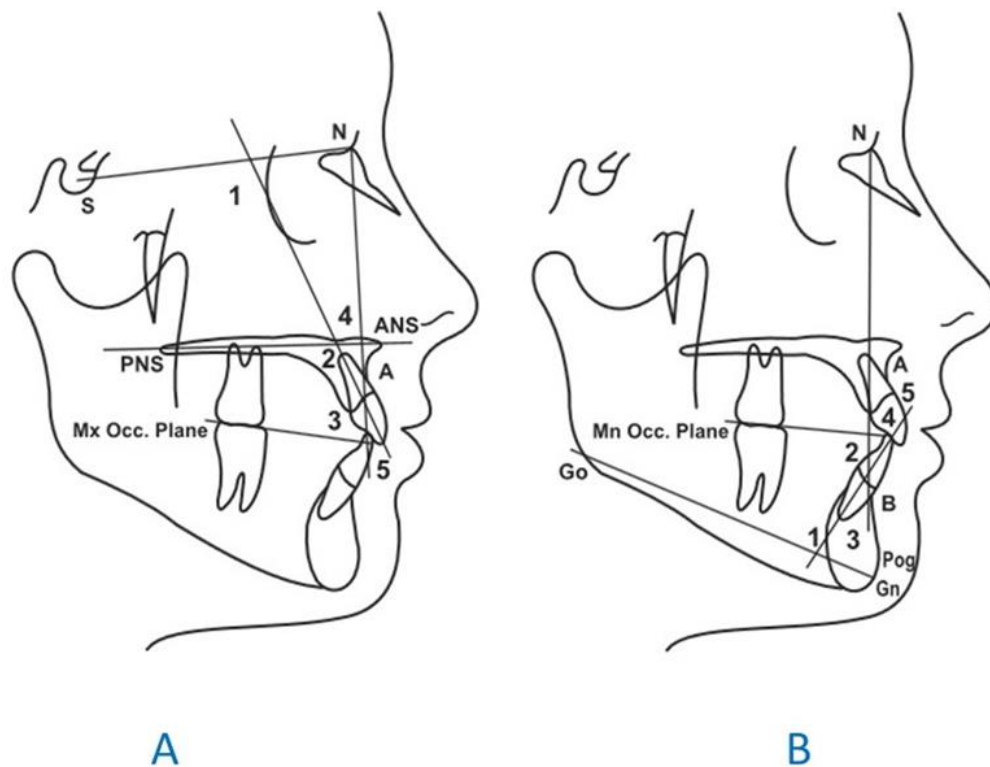


Figure 1. Wits analysis to determine skeletal relationship of the maxilla and mandible; (A) A tracing of a lateral cephalometric radiograph showing the measurements used to evaluate the upper incisors inclination; (B) A tracing of a lateral cephalometric radiograph showing the measurements used to evaluate the lower incisors inclination

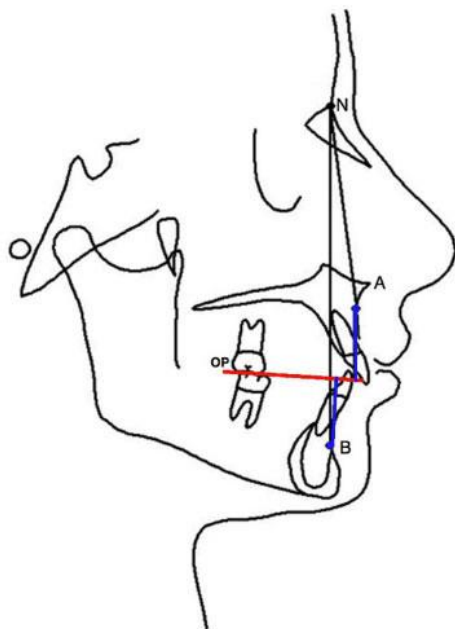


Figure 2. Wits analysis to determine skeletal relationship of the maxilla and mandible

Skeletal discrepancy was measured by using Wits analysis and ANB angle (Figure 1). Wits analysis was applied to establish the apical base relationship between the maxillary and the mandibular arches as measured along the Jacobson occlusal plane. The Wits measurement was established by drawing a line from point A and point B, proceeding perpendicular to the Jacobson occlusal plane. Therefore, if point B line intersected the occlusal plane posterior to the point A line, the Wits measurement could be positive. If the B point line intersected the occlusal plane anterior to the A point line, the Wits measurement could be negative. The distance between the lines was according to the Wits measurement. Two angles were applied to determine the upper and lower incisors position to the skeletal base: IMPA (the lower incisor teeth to the mandibular plane) and the upper 1 to SN (Figure 2) (Table 1).

Statistical Analysis

The statistical analyses was performed by using the statistical package SPSS for PC, version 19 (IBM, USA). Pearson's Correlation was applied for finding the correlation between the dental and skeletal indices on the cephalogram for the two experimental groups. Independent -t-test was utilized to compare crowding, IMPA, and U1 to SN angle in our groups.

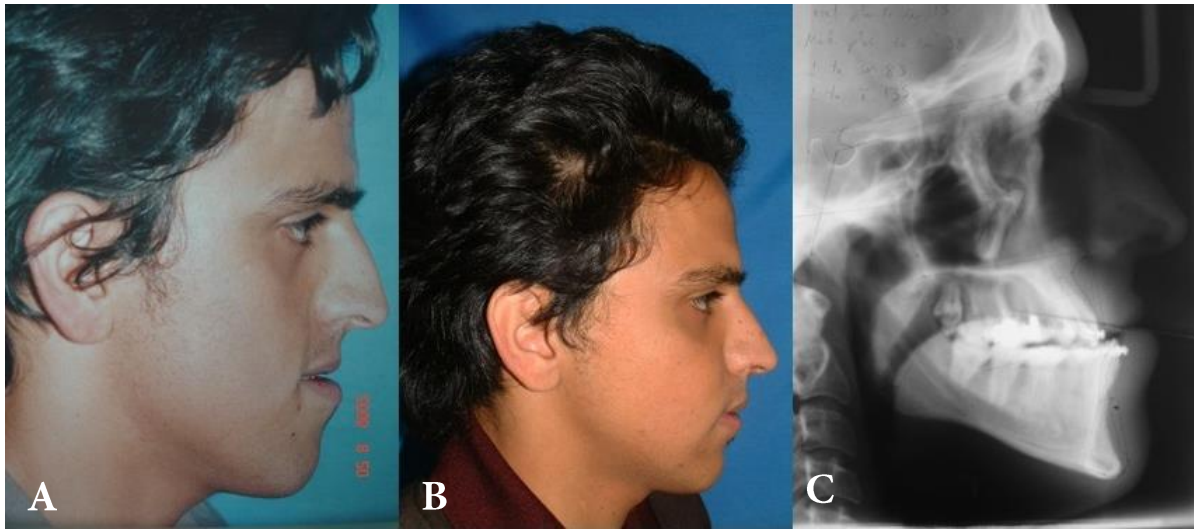

Figure 3. A case of the second maxillary premolars were removed during pre-surgical orthodontic preparation shows an acceptable decompensation

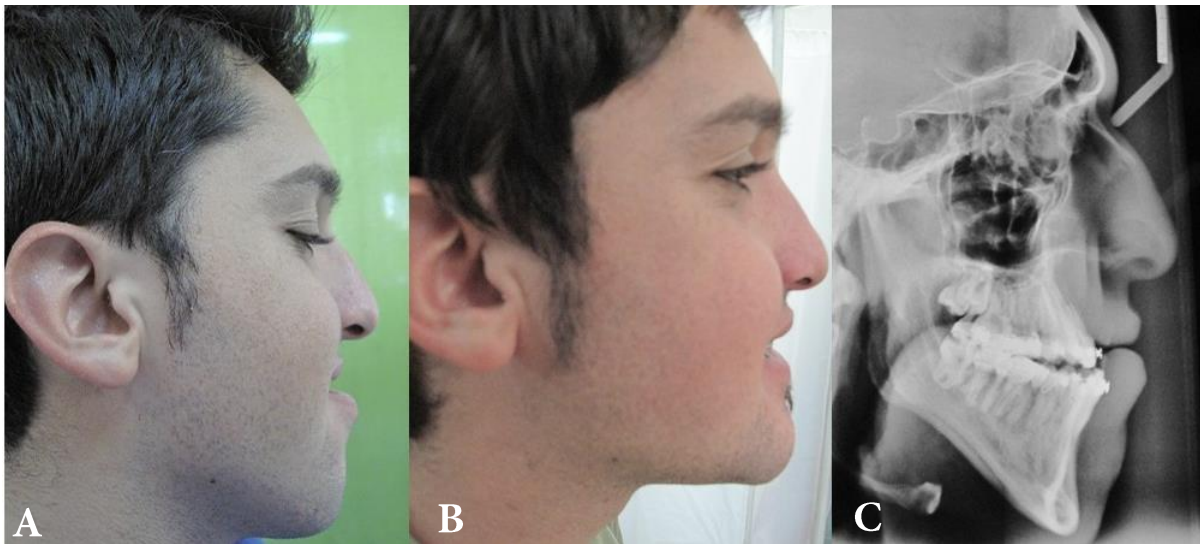

Figure 4. A case of non-extracted the second maxillary premolars during pre-surgical orthodontic preparation shows incomplete decompensation with an excessive difference of the dental discrepancy and the skeletal discrepancy

Results

Forty-six subjects (16 males and 30 females) were included in the 1st group and 31 individuals (13 males and 18 females) were included in the 2nd group. The mean dental discrepancy (DD) was 7.39 ± 3.40 mm in the 1st group and 9.65 ± 2.57 mm in the 2nd group. The mean skeletal discrepancy was 11.59 ± 4.9 mm in group 1 and 8.48 ± 2.35 mm in group 2. The mean ANB angle was 4.15 ± 6.30 in group 1 and 2.84 ± 1.03 in group 2. The mean U1 to SN was 104.15 ± 5.97 in group 1 and 98.74 ± 3.36 in group 2. The mean IMPA was 87.24 ± 6.14 in group 1 and 88.71 ± 2.47 in group

2. The mean of crowding was 5.17 ± 1.23 mm in group 1 and 4.87 ± 1.24 mm in group 2.

Pearson's correlation test did not present any correlation between dental discrepancy and the skeletal discrepancy in group 1 ($P > 0.05$, Table 2). There was no correlation between ANB angle and dental discrepancy ($P > 0.05$).

Pearson's correlation test demonstrated a significant correlation between dental discrepancy and skeletal discrepancy in the 2nd group ($P < 0.001$, Table 2). There was no significant correlation between ANB angle and the dental discrepancy in the 2nd group as well ($P > 0.05$).

Comparison of IMPA in the 1st and 2nd groups did not manifest any significant differences. There was a significant difference between the two groups for U1 to SN ($P<0.001$) distinctly. A significant difference was found between the two groups for ANB angle ($P<0.05$) transparently. The data analysis did not show a significant difference for crowding between the two groups indeed. ($P>0.05$, Table 3).

Discussion

The aim of the surgical-orthodontic treatment is to normalize the main skeletal and dental relationships; in addition, cephalometric analysis allows scientific analysis of these relationships (2). Presurgical orthodontic management includes leveling and aligning of the arches; besides, relieving crowding and creating proper inclination of incisors (decompensation), for by coordinating upper and lower arches, and removing occlusal interferences precisely (5-7).

Transparently, in the skeletal class III patients, the lower incisors are normally retroclined and crowded; whereby, the maxillary incisors are frequently flared out. Distinctly, one of the mentionable purposes of pre-surgical orthodontics would be placing incisors in a proper angle into the bone of jaw; therefore, the surgeon can settle the jaw bones in the maximum position (7). As a matter of fact, extraction or non-extraction of the second maxillary premolars are useful approaches for pre-surgical orthodontic treatment to decompensate the maxillary teeth in a retruded position conspicuously. Figure 3 and 4 choosing each option can affect dental discrepancy which should be matched with the skeletal discrepancy. Evidently, under or over-correction of the dental discrepancy may lead to unpleasant surgical outcomes.

Troy *et al.* reported that the outcomes of the surgical correction was limited by the inadequate pre-surgical orthodontic incisor decompensation; furthermore, orthodontic compensation of incisors occurred post-surgically to achieve an optimal occlusal result (8). There has been a tendency to prepare class III patients via a non-extraction approach (9). Avoiding extraction of the second premolars in the maxilla during pre-surgical orthodontic treatment provides a wider arch; along with, a wide smile line consequently. Moreover, it might cause a limitation in proper decompensation and create inadequate dental discrepancy in orthognathic surgery. Molar distalization was suggested as an alternative approach to gain adequate dental discrepancy in class III patients before orthognathic surgery (10). Our study indicates that the maxillary incisor teeth were more retruded in extraction group than non-extraction group. Thus, dental discrepancy in extraction group had a correlation with skeletal discrepancy in the extraction group.

As a matter of fact, for making a decision either to perform the surgery or not in class III skeletal patients, the

surgeon takes in consideration the followings: the size of the anteroposterior discrepancy, the inclination of the mandibular incisors, and the appearance of the soft tissue profile. In contrast, the vertical dimensions (e.g., gonial angle or Y-axis) influences the least the treatment decision (11). A reduced cranial base occurs frequently; however, it is not specifically associated with a Class III malocclusion. Nonetheless, no particular significant difference in the anterior cranial base length was observed in children with Class III malocclusions and in those with normal occlusions (12). On the other hand, the limitations of multivariate cephalometric analysis model must be taken into consideration: the perception to classifying the patients was based on the clinical records and the cephalometric analysis disregarding to the transverse components and the facial esthetics (3). The index of complexity, outcome, and need (ICON) scoring system has been applied to evaluate the difficulty of orthodontic treatment (13). Maxillary arch crowding could be considered as an essential factor for prediction of ICON and also deciding on extraction of the second premolar for pre-surgical orthodontic treatments (14). Minimal pre-surgical orthodontics in non-extraction group in class III individuals had similar result with conventional pre-surgical orthodontics in soft and hard tissue cephalometric indices. Indeed, the study did not compare extraction and non-extraction groups (14).

The soft tissue and clinical profile of class III patients is quite an important concern which should be considered by orthodontists and surgeons. The soft tissue profile varies owing to the underlying fat, fascia, and muscle, which could change in quantity and/or distribution under different conditions, consisting of age, individual characteristics, and nutrition. Surgeons should consider the preoperative soft tissue characteristics of individual patients to anticipate how the soft tissue changes (15). A report presented a significant change occurred between soft and hard tissue in class III patients after bimaxillary surgery. Therefore, significant correlations were found between facial convexity to SNB, ANB, and NAPg. In addition, the significant correlations were demonstrated between lower lip length and SNB, ANB, and NAPg (16). Correlations of hard and soft tissue movements between pre- and postoperative corresponding landmarks in the horizontal and vertical planes presented a significance for both cephalometry and 2-D photogrammetry in class II and III patients (14). Prediction of soft to hard tissue movement ratios must be evaluated on an individual basis; to some extends, they depend, on the experience of the surgeon in his or her repositioning of the maxilla during bimaxillary surgery. Furthermore, various types of operations-as well as, the morphology of the anatomic structures-must be considered in predicting the outcome of facial surgery (17).



Conclusion

In spite of this, it is peculiar that extraction of the second premolars of the maxilla could improve the match for DD and SD in pre-surgical preparation of class III patients with an excessive SD.

Conflict of Interest: 'None declared'.

References

1. Frapier L, Garcia C, Pic E, Morant F, Belguendouz S, Gauthier A, *et al.* Successful orthodontic-surgical treatment: aiming for esthetics and function. Analysis of some clinical cases. *Int Orthod.* 2013;11(4):357-88.
2. Johnston C, Burden D, Kennedy D, Harradine N, Stevenson M. Class III surgical-orthodontic treatment: a cephalometric study. *Am J Orthod Dentofacial Orthop.* 2006;130(3):300-9.
3. Stellzig-Eisenhauer A, Lux CJ, Schuster G. Treatment decision in adult patients with Class III malocclusion: orthodontic therapy or orthognathic surgery? *Am J Orthod Dentofacial Orthop.* 2002;122(1):27-37; discussion -8.
4. Kim DK, Baek SH. Change in maxillary incisor inclination during surgical-orthodontic treatment of skeletal Class III malocclusion: comparison of extraction and nonextraction of the maxillary first premolars. *Am J Orthod Dentofacial Orthop.* 2013;143(3):324-35.
5. Xu B, Qin K. [The effect of extraction and non-extraction decompensation to bimaxillary orthognathic surgery in skeletal class III malocclusion]. *Hua Xi Kou Qiang Yi Xue Za Zhi.* 2012;30(2):143-7.
6. Yu CC, Chen PH, Liou EJ, Huang CS, Chen YR. A Surgery-first approach in surgical-orthodontic treatment of mandibular prognathism--a case report. *Chang Gung Med J.* 2010;33(6):699-705.
7. Proffit WR, Raymond P. White, and David M. Sarver. Contemporary treatment of dentofacial deformity. St Louis: Mo: Mosby; 2003.
8. Troy BA, Shanker S, Fields HW, Vig K, Johnston W. Comparison of incisor inclination in patients with Class III malocclusion treated with orthognathic surgery or orthodontic camouflage. *Am J Orthod Dentofacial Orthop.* 2009;135(2):146.e1-9; discussion -7.
9. Aymach Z, Sugawara J, Goto S, Nagasaka H, Nanda R. Nonextraction "surgery first" treatment of a skeletal Class III patient with severe maxillary crowding. *J Clin Orthod.* 2013;47(5):297-304; quiz 27-8.
10. Gonzalez B. Non-extraction treatment of a Class III skeletal case. *Int J Orthod Milwaukee.* 2009;20(2):15-21.
11. Kerr WJ, Miller S, Dawber JE. Class III malocclusion: surgery or orthodontics? *Br J Orthod.* 1992;19(1):21-4.
12. Battagel JM. The aetiological factors in Class III malocclusion. *Eur J Orthod.* 1993;15(5):347-70.
13. Daniels C, Richmond S. The development of the index of complexity, outcome and need (ICON). *J Orthod.* 2000;27(2):149-62.
14. Joh B, Bayome M, Park JH, Park JU, Kim Y, Kook YA. Evaluation of minimal versus conventional presurgical orthodontics in skeletal class III patients treated with two-jaw surgery. *J Oral Maxillofac Surg.* 2013;71(10):1733-41.
15. Aydil B, Ozer N, Marsan G. Bimaxillary surgery in Class III malocclusion: soft and hard tissue changes. *J Craniomaxillofac Surg.* 2013;41(3):254-7.
16. Rustemeyer J, Martin A. Soft tissue response in orthognathic surgery patients treated by bimaxillary osteotomy: cephalometry compared with 2-D photogrammetry. *Oral Maxillofac Surg.* 2013;17(1):33-41.
17. Marsan G, Cura N, Emekli U. Soft and hard tissue changes after bimaxillary surgery in Turkish female Class III patients. *J Craniomaxillofac Surg.* 2009;37(1):8-17.

Please cite this paper as: Tabrizi R, Behnia H, Behroozi Z, Javanmardi Z. Presurgical Orthodontics in Class III Patients: Extraction versus Non-Extraction. *Regen Reconstr Restor.* 2016;1(3):133-138.

