

Ancient Schwannoma of the Hard Palate Accompanied by Hyponatremia: A Unique Case Report

Nima Nikafshar¹  | Mojde Masoudi²  | Siavash Vadaye Kheiri^{2*}  | Maryam Johari³ 

1. Department of Oral Medicine, Babol University of Medical Sciences, Babol, Iran.

2. Student Research Committee, Babol University of Medical Sciences, Babol, Iran.

3. Oral Health Research Center, Health Research Institute, Babol University of Medical Sciences, Babol, Iran.

Article Info

Received: 25 July, 2025

Accepted: 21 August, 2025

Published: 3 November, 2025

*Corresponding Author

Siavash Vadaye Kheiri, Student Research Committee, Babol University of Medical Sciences, Babol, Iran.

Email: siavash1374@gmail.com

Abstract

Schwannoma is a benign neurogenic neoplasm originating from the Schwann cells within the peripheral nervous system. Its incidence is documented at about 25-45%, yet its occurrence in the oral cavity is less than 12%. Given that neurogenic neoplasms are a well-documented but uncommon reason for hyponatremia, this is a case report of an ancient schwannoma of the palate, perforating the nasal floor, in an 80-year-old female, along with hyponatremia.

An 80-year-old female presented with painful swelling in the anterior maxilla and the nasal floor. She had a history of hyponatremia, high blood pressure, tachycardia, and hypothyroidism. Clinical examination revealed apparent swelling in the buccal vestibule and the midline of the hard palate; the lesion had perforated the palate to the nasal cavity. cone beam computed tomography revealed swelling of the soft tissue and erosion of the underlying bone. An excisional biopsy surgery was performed by laser. Microscopic examination showed spindle cell neoplasm composed of cellular areas (Antoni A), nuclear palisading (verocay bodies), and pauci-cellular microcystic areas (Antoni B). Some tumoral cells showed nuclear atypia including nuclear enlargement with hyperchromasia with irregular border. Given that, the definitive diagnosis was an ancient Schwannoma.

The present case is a unique type of schwannoma, placed in an uncommon location. It presented pain and, more importantly, perforated the hard palate to the nasal cavity.

Keywords: Neurilemmoma, Hyponatremia, Mouth neoplasms.

Please cite this paper as:

Nikafshar N, Masoudi M, Vadaye Kheiri S, Johari M. Ancient Schwannoma of the Hard Palate Accompanied by Hyponatremia: A Unique Case Report. Journal of "Regeneration, Reconstruction & Restoration" (Triple R). 2025; Volume 10: e18. Doi: 10.22037/rrr.v10.49262

1. Introduction

Schwannoma or neurilemmoma is an uncommon neurogenic neoplasm originating from Schwann cells within the nervous system. This tumor shows a strong affinity for head and neck. Also, its incidence is documented at about 25-45% (1). Yet its occurrence in the oral cavity is less than 12% (2). Schwannoma is the most frequent tumor of the peripheral nerve sheath. They are also benign, almost asymptomatic, and well-circumscribed tumors that grow slowly with the peripheral nerves. Moreover, they are commonly solitary tumors (3) on the floor of the mouth or tongue, but their presence in the hard palate is relatively rare (2).

Ancient schwannoma was first described by Ackermann and Taylor as a persistent Schwannoma with degenerative

diversions like calcification, cystic formation, tissue necrosis, xanthomatous alterations, vascular hyalinization matrices, and noticeable nuclear atypia, attributed to the tumor growing (4,5). Besides the ancient type, there are other types such as plexiform, cellular, and epithelioid (6). Immunohistological examinations can be useful in the differential diagnosis of schwannoma from other mimicking lesions (3).

Hyponatremia is the most frequent electrolyte disorder and happens when serum sodium concentration is less than 135 mmol/L. Neurogenic neoplasms are a well-documented but uncommon reason for this disorder (7). Although there is no direct evidence linking ancient schwannoma to hyponatremia, there has been reports of mediastinal schwannoma, intrasellar schwannoma that suggest schwannoma in certain locations can be associated with hyponatremia (7,8,9). Here we present

rare a case of an 80-year-old female diagnosed with ancient schwannoma of the hard palate, perforating the nasal floor, along with hyponatremia which resolved after tumor excision.

2. Case presentation

An 80-year-old woman came to an oral medicine specialist in 2023 with the chief complaint of pain in the anterior maxilla and the nasal floor. She had a history of hyponatremia (sodium level of 125 mmol/l), high blood pressure, tachycardia, and hypothyroidism.

In the extra-oral clinical examination, swelling was observed in the soft tissue of the anterior maxilla and the floor of the nasal cavity (Figure 1). Intraoral examination revealed an apparent swelling in the buccal vestibule as well as the midline of the hard palate (Figure 2). This lesion was 4*4 mm, lobular, and had a rubber consistency. In the periapical radiograph of the edentulous area (Figure 3), no obvious pathology was seen inside the bone.

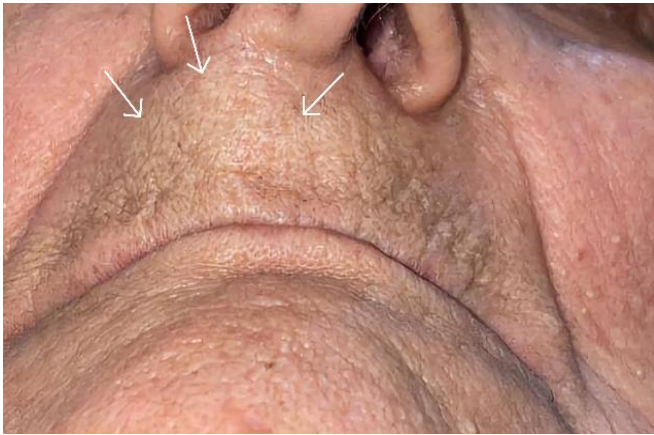

Figure 1. Swelling in the soft tissue of anterior maxilla and the floor of the nasal cavity.

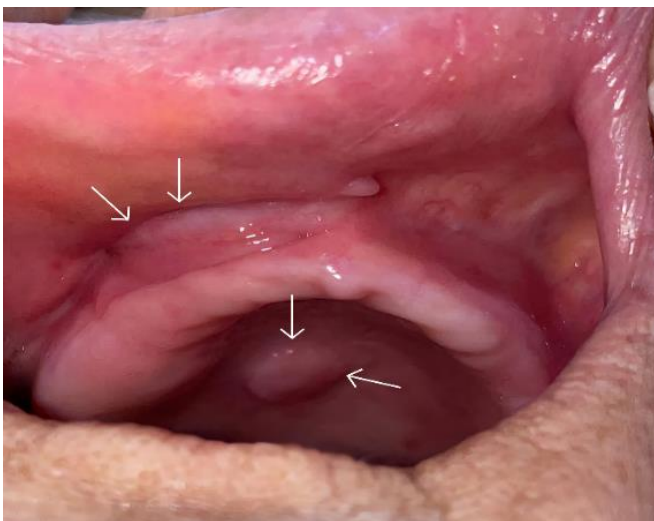


Figure 2. Swelling in the buccal vestibule and the midline of the hard palate.

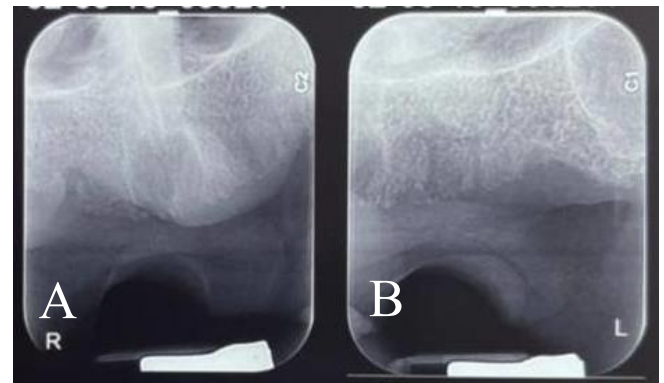


Figure 3. A) Periapical radiograph from right anterior ridge of maxilla, B) Periapical radiograph from left anterior ridge of maxilla.

Therefore, a Cone Beam Computed Tomography (CBCT) was prepared from the target area for further investigation. In the CBCT images in different plans, the alveolar bone of the anterior maxilla was sound and intact, but the swelling in the soft tissue of the nasal cavity floor was clear (Figure 4). In the area of the hard palate, swelling of the soft tissue was seen along with erosion in the underlying bone (Figure 5). This lesion perforated the palate to the nasal cavity. According to the radiographic appearance and use of removable complete dentures by the patient, the diagnostic hypothesis was irritating fibroma for the lesion of the hard palate and nasolabial cyst for the anterior maxilla lesion. An excisional biopsy of the lesion was performed using CO₂ laser (Lightsapel LS-1005, USA), and the specimen was placed in formalin and sent for pathological examination.

The received specimen consisted of 2 pieces of creamy tissue measuring 2*1*1cm and 0.7*0.7cm, and a rhomboid piece of skin tissue 1*0.7cm. Microscopic examination of the received specimen showed spindle cell neoplasm composed of cellular areas (Antoni A), showing nuclear palisading (verocay bodies) and pauci-cellular microcystic areas (Antoni B). Mitotic activity was not appreciated. Some tumoral cells showed nuclear atypia including nuclear enlargement with axilla hyperchromasia with irregular border. No necrosis was noted (Figure 6).

Immunohistochemistry analysis was performed, and the following markers were evaluated: S100 and SOX10 were diffusely positive, CD34 was positive in a few cells, SMA and DESMIN were negative, and analysis of Ki67 showed a low proliferative index.

Therefore, the definitive hypothesis was ancient schwannoma. Based on the review of articles in which the association of schwannoma in the mediastinal area and hyponatremia was observed, neurology consultation and brain CT were prescribed. On the three-month follow-up, the hyponatremia was resolved (sodium level 137 mmol/l), and the one-year follow-up showed no recurrence (Figure 7).

3. Differential Diagnosis

Differential diagnosis for the present lesion could include a

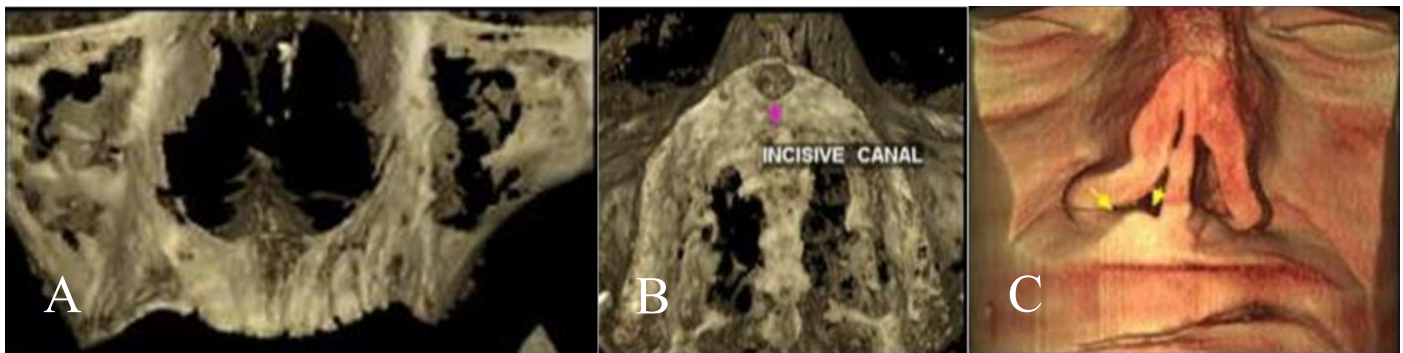


Figure 4. The alveolar bone of anterior maxilla was sound and intact. A) CBCT bone window 3D maxilla coronal view. B) CBCT bone window 3D axial view. C) Swelling in the soft tissue of the nasal cavity floor was seen in CBCT soft tissue window.

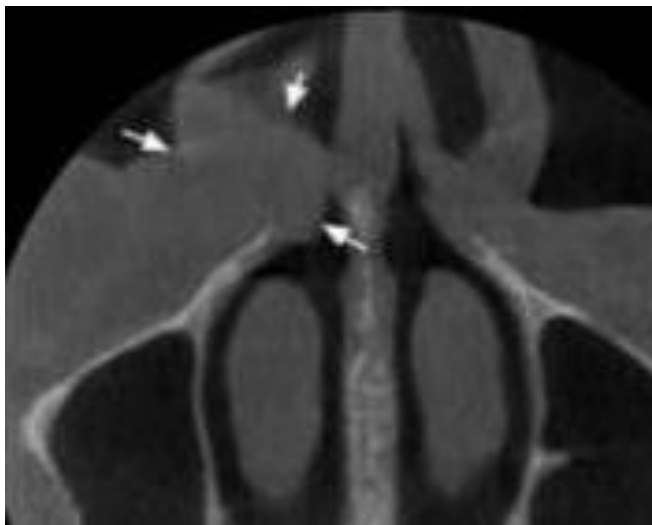


Figure 5. Swelling of the soft tissue was seen along with erosion in the underlying bone. A) axial plan, B) sagittal plan.

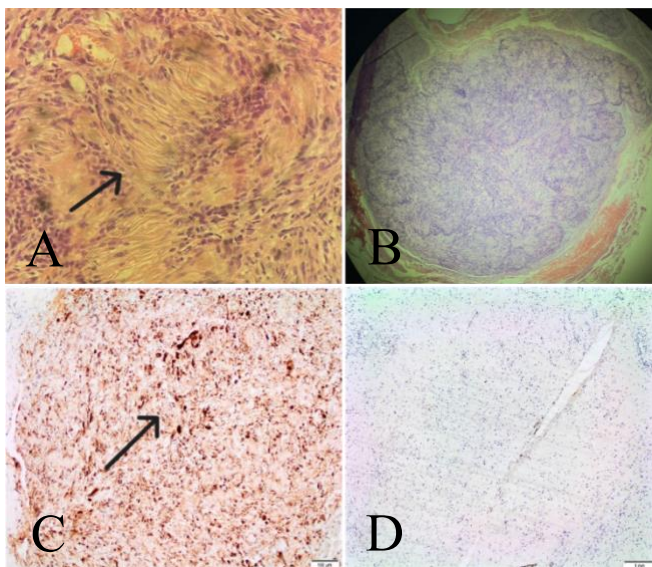


Figure 6. A,B) Antoni A, verocay bodies, C,D) Antoni B, nuclear atypia including nuclear enlargement and hyperchromasia and irregular border.

number of benign neoplasms. The most likely diagnosis could be benign tumors of salivary glands, such as adenoma. Fibroma and lipoma are other possibilities, which are respectively benign tumors of connective tissue and adipose tissue. Residual cystic lesions could appear similarly. malignant neoplasms such as oral squamous cell carcinoma of the bone and salivary gland carcinoma, could rarely show benign manifestations (10). There are so many systemic conditions associated with hyponatremia that can cause oral lesions as well. Congestive heart failure can lead to hyponatremia and fluid overload that can cause edema in the face and oral cavity potentially mimicking an oral mass. Hypothyroidism is also associated with hyponatremia due to impaired water excretion which can lead to myxedema. On the other hand, patients with hypothyroidism have an increased risk of developing benign tumors in the oral cavity. Adrenal insufficiency can lead to electrolyte imbalances and various oral manifestations and hyperpigmentation of the oral mucosa which might be mistaken for an oral mass (11).

4. Discussion

As discussed, schwannoma is benign and usually asymptomatic, but its etiology is still unknown (12). Moreover, schwannoma of the oral cavity is most commonly found in the soft tissue, especially the tongue, and intraosseous tumor is the rarest location for it (13). Given that the current case is located in the hard palate and perforated the nasal floor, it is almost unique. Ancient schwannoma can be presented in all ages, but it is more common between the ages of 10 - 40 years old, affecting women slightly more (2). In this case, the lesion occurred in an 80-year-old female, which is somehow noticeable. The presence of pain or other discomforts is not common but related to the location of the nerve or the size of the lesion. The absence of symptoms can be a reason for the transformation to the ancient type (2). In this case, pain was a chief complaint, unlike the usual ancient type cases. Song et al. (7) reported the resolution of hyponatremia after the removal of schwannoma, as was observed in the current study. In this study, the patient is suffering from ancient schwannoma along with hyponatremia; as a result, the possibility of an association between these two conditions

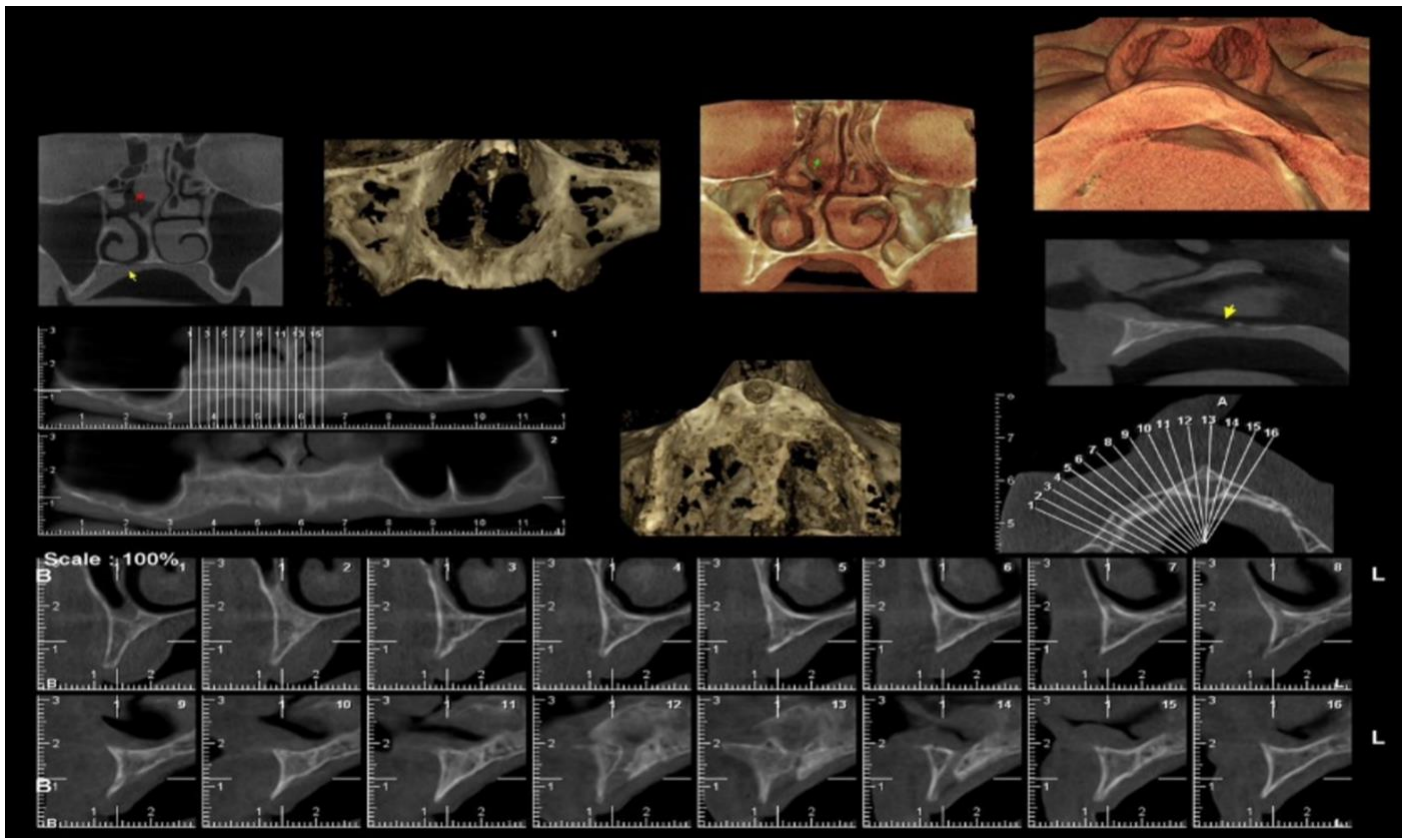


Figure 7. CBCT radiograph after one year. No recurrence is noticed.

should be investigated in future studies.

From the histopathological aspect, this tumor is composed of spindle cells along with eosinophilic cytoplasm and a round to oval nucleus noticeable in cellular areas, as Antoni A, and myxoid with hypocellular areas as Antoni B. Verocay bodies are also eosinophilic formations as a characteristic mark in the Antoni A fields (2,14). Antoni A, Antoni B, and verocay bodies were obvious in this case, like many other cases. Also, nuclear atypia, including nuclear enlargement, hyperchromasia, and irregular border, was another noteworthy finding of this case. Thus, immunohistochemistry analysis was performed to avoid misdiagnosis.

Immunohistochemical analysis is a valuable approach to confirm the diagnosis. In this case, S100 was diffusely positive, similar to the case in the study by Kardouni Khoozestani et al. (4), as a marker of focal spindle-shaped cells. They also recognized CD68 as a marker of histiocytes. Moreover, according to the Gainza-Cirauqui et al. report (2), the CD34 marker is usually negative, in contrast to this case. The gold standard treatment for this tumor is complete excision surgery (2). According to Kardouni Khoozestani et al., no ancient schwannoma of the oral cavity has been shown to undergo malignant transformation (2), as was the case in this study.

5. Conclusion

Ancient schwannoma is usually a benign tumor; thus, the presence of pain as well as nasal perforation in this case is noteworthy and indicates the importance of timely diagnosis and appropriate treatment. Given that ancient schwannoma, especially in this location, is uncommon and also considering the manifestation of pain, the necessity of careful investigation of similar cases is felt so that surgical intervention can be performed at the right time and possible complications can be avoided.

Acknowledgements

This research project was approved by Babol University of Medical Sciences and conducted at Babol University of Oral Health Research Center. The authors would like to express their gratitude to all those who sincerely participated in the conduct of this study. And special thanks to Authorea to publish our preprint on their platform. DOI: [10.22541/au.173809113.38515018/v1](https://doi.org/10.22541/au.173809113.38515018/v1)

Ethics

Informed consent was obtained from the participants, which was conducted in accordance with the Declaration of Helsinki and the national guidelines and regulations.

Using Artificial Intelligence (AI)

It is declared by the authors of this manuscript that no generative artificial intelligence (AI) or AI-assisted

technologies were used to generate content, ideas, or theories during the writing process of this work.

Author contribution

Nima Nikafshar: Conceptualization, Methodology, Writing - Review & editing

Mozhdeh Masoudi: Visualization Writing - Review & editing

Siavash Vadaye Kheiri: Project administration, Writing - Original draft

Maryam Johari: Supervision, Resources, Writing - Review & editing

Conflict of interest

The authors declare no conflict of interest.

Funding

None.

References

1. Venkatasamy R, Singh ASM, Arasu K, Husain S, Mianxin C. Nasal Septal Ancient Schwannoma: Ancient and Rare. *Cureus*. 2023;15(8).
2. Gainza-Cirauqui ML, Eguía-Del Valle A, Martínez-Conde R, Coca-Meneses JC, Aguirre-Urizar JM. Ancient schwannoma of the hard palate. An uncommon case report and review. *Journal of clinical and experimental dentistry*. 2013;5(1):e62.
3. Eroglu YM, Emre IE. Ancient schwannoma of the nose: Case report and literature review. *Journal of Oral and Maxillofacial Surgery, Medicine, and Pathology*. 2018;30(6):508-14.
4. Kardouni Khoozestani N, Motiee-Langroudi M, Salehi A, Ranji P. Intraosseous ancient Schwannoma: A rare case in the mandible and a literature review. *Rare Tumors*. 2021;13:20363613211026480.
5. Choudry HA, Nikfarjam M, Liang JJ, Kimchi ET, Conter R, Gusani NJ, et al. Diagnosis and management of retroperitoneal ancient schwannomas. *World Journal of Surgical Oncology*. 2009;7:1-5.
6. Kodama S, Okamoto T, Suzuki M. Ancient schwannoma of the nasal septum associated with sphenoid sinus mucocele. *Auris Nasus Larynx*. 2010;37(4):522-5.
7. Song SH, Sim GA, Baek SH, Seo JW, Shim JW, Koo JR. Syndrome of inappropriate antidiuretic hormone secretion (SIADH) associated with mediastinal schwannoma. *Electrolytes & Blood Pressure*. 2017;15(2):42-6.
8. Bernreuther C, Flitsch J, Lüdecke DK, Hagel C. OCTOBER 2007 CASE 2: A 61-YEAR-OLD MAN WITH HYPONATREMIA. *Brain Pathology*. 2008;18(2):283.
9. Pitale SU, Lee JM, Origitano T, Emanuele NV. An unusual pituitary mass presenting with panhypopituitarism and hyponatraemia. *Postgraduate Medical Journal*. 2001 Aug;77(910):530-1.
10. Fonseca Raymond J D, Eric R. Carlson D, MD, FACS, Gregory M. Ness D, FACS. *ORAL AND MAXILLOFACIAL SURGERY*. third ed. Fonseca RJ D, editor: ELSEVIER; 2017. 989 p.
11. Miller C, Rhodus NL, Treister NS, Stoopler ET, Kerr AR. *Little and Falace's Dental Management of the Medically Compromised Patient-E-Book: Little and Falace's Dental Management of the Medically Compromised Patient-E-Book: Elsevier Health Sciences; 2023.*
12. Shilpa B. Ancient schwannoma-a rare case. *Ethiop J Health Sci*. 2012;22(3):215-8.
13. Gainza-Cirauqui ML, Eguía-Del Valle A, Martínez-Conde R, Coca-Meneses JC, Aguirre-Urizar JM. Ancient Schwannoma of the hard palate. An uncommon case report and review. *J Clin Exp Dent*. 2013;5(1):e62-5.
14. Lopez J, Ballestin C. Intraoral schwannoma. A clinicopathologic and immunohistochemical study of nine cases. *Archives d'anatomie et de cytologie pathologiques*. 1993;41(1):18-23.