

Clinical Pearls in Treatment of Zygomaticomaxillary Complex Fractures

Mehnoush Momeni ^a, Mahboube Hasheminasab ^b, Neda Afsar ^{a*}

^aDepartment of Oral and Maxillofacial Surgery, Tehran University of Medical Sciences, Tehran, Iran; ^bCraniofacial Research Center, Department of Oral and Maxillofacial Surgery, Tehran University of Medical Sciences, Tehran, Iran.

*Corresponding authors: Neda Afsar, Department of Oral and Maxillofacial Surgery, Tehran University of Medical Sciences, Tehran, Iran. **E-mail:** nedaafsar@yahoo.com; **Tel:** +98-912 3799810

Submitted: 2020-06-07; **Accepted:** 2020-08-10; **Published Online:** 2020-08-25; **DOI:** 10.22037/rrr.v5i1.29335

Zygomaticomaxillary complex (ZMC) fractures are common facial injuries that can significantly change the structure, function and esthetics of the midface. Proper and timely management of these fractures can reduce the rate of late complications. In this paper, we review the current literature regarding ZMC fracture treatment and discuss our experience from surgical treatment of multiple ZMC fractures in the course of 10 years.

Keywords: Cone-Beam Computed Tomography; Endodontic Surgery; Mandible; Premolar

Introduction

The zygomaticomaxillary complex plays a key role in the function and esthetics of the face. Zygoma is the most prominent bony structure of the midface and has an important role in protecting the orbital contents. Its fracture might lead to cosmetic deformities as well as mastication and ocular problems and could significantly reduce patient's quality of life (1). It has been postulated that ZMC fractures comprise about 40 % of all facial fractures (2). In multiple studies, ZMC fractures have been the second most common fractures in facial skeleton (3, 4). The most common etiologic factors involved in these fractures include interpersonal violence, traffic accidents, stumblings and falls, and sports injuries (5).

The complexity of these types of fracture poses a challenge to maxillofacial surgeons especially in developing countries where the prevalence and severity of these fractures are higher (6). It is always surgeons' priority to minimize post-surgical complications and residual deformities. Accurate diagnosis, proper reduction, fixation, and meticulous postoperative follow up are the main keys to a successful treatment. Multiple new techniques have been proposed by surgeons to increase the surgical accuracy and precision and to optimize the surgical

outcomes. These new techniques include computer assisted surgery (7) and surgical navigation (8) which have resulted in more post-operative symmetry.

Despite the high prevalence of ZMC fractures, there is no consensus available showing the best approach for managing these fractures especially the old ones. In this paper, we will share our experience in treatment of numerous ZMC fractures in the course of ten years. The aim of this study is to guide maxillofacial surgeons to better treat ZMC fractures, both old and new ones.

Preoperative evaluation

A precise evaluation of all fracture lines and three-dimensional relationships of all fractured segments in a crucial step in facial fracture treatment (9). CT scan is now the standard of care for evaluating maxillofacial skeleton (9). Fine cut high-resolution 3D CT scans are essential tools in both detecting and evaluating midface fractures. In a study, Markiewicz *et al.*, (10) quoted that coronal views are preferred for evaluating the integrity of the orbital floor with or without associated tissue herniation to the maxillary sinus and possible extraocular muscle entrapment. They also added that, axial images are considered for assessing the malar projection and status of the zygomatic arch (10). From

our point of view, sagittal views are particularly helpful in evaluating the orbital floor and the accurate position of orbital implants in the postoperative setting (Figure 1).

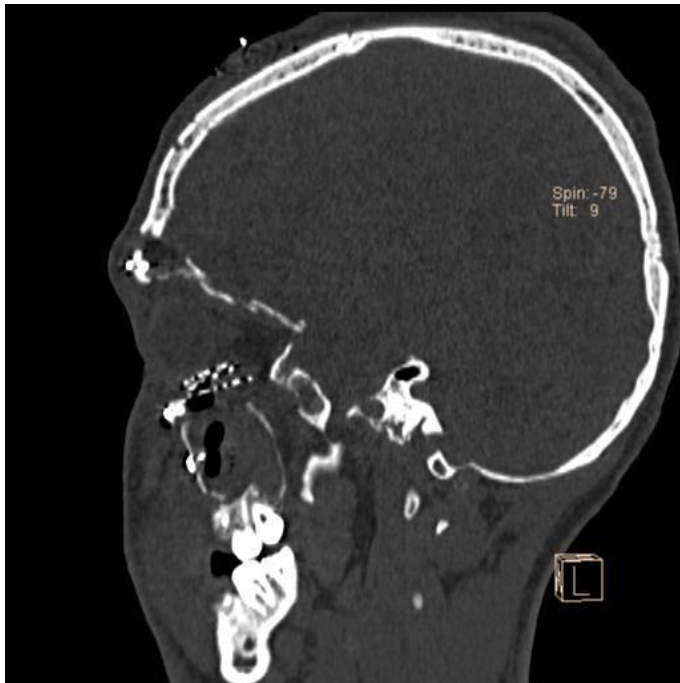


Figure 1. Sagittal view is helpful in evaluating the orbital floor

It is recommended that all fracture lines, even greenstick or non-displaced ones, should be noticed and marked on CT scan since they may not be obvious or stand out most of the times. This is especially important for novice surgeons (Figure 2,3).

It is quite important to keep in mind that clinical examinations and radiographic signs should be evaluated concomitantly since some 3D CT scan signs might be illusive to the naked eye due to the nature of the scans themselves (Figure 4). Generally, it is

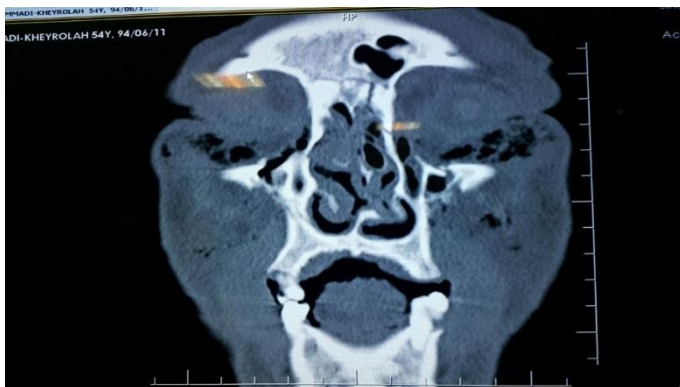

Figure 2. Fracture lines on CT scan, should be noticed and marked

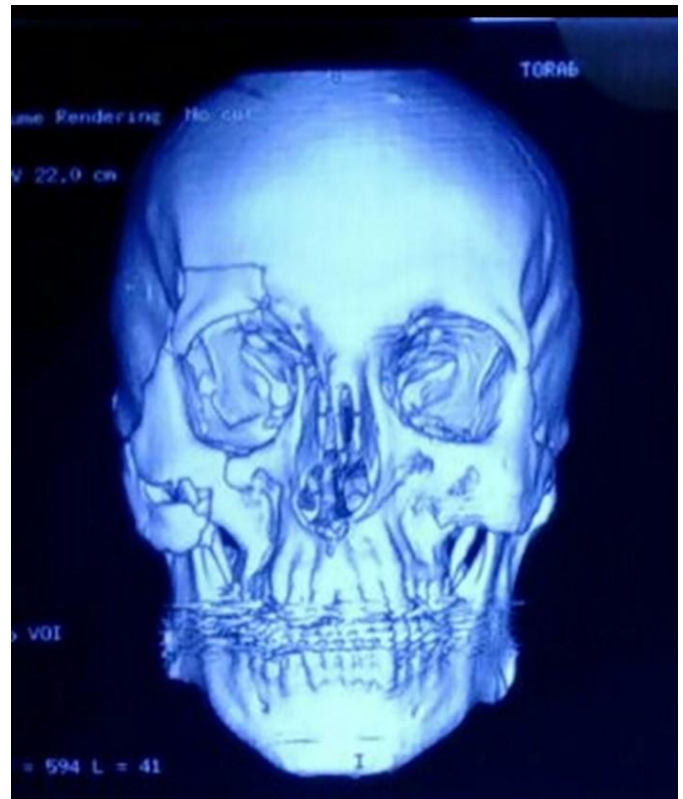


Figure 3. Marking fracture line on 3D CT scan

recommended to take post-operative high-resolution fine cut 3D CT scans for evaluating the accuracy of reduction in fracture lines (Figure 5).

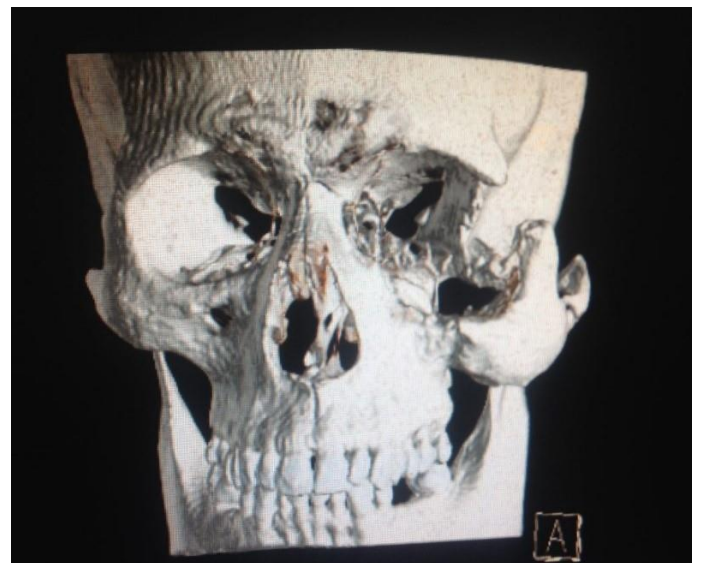


Figure 4. Pre- op 3D CT



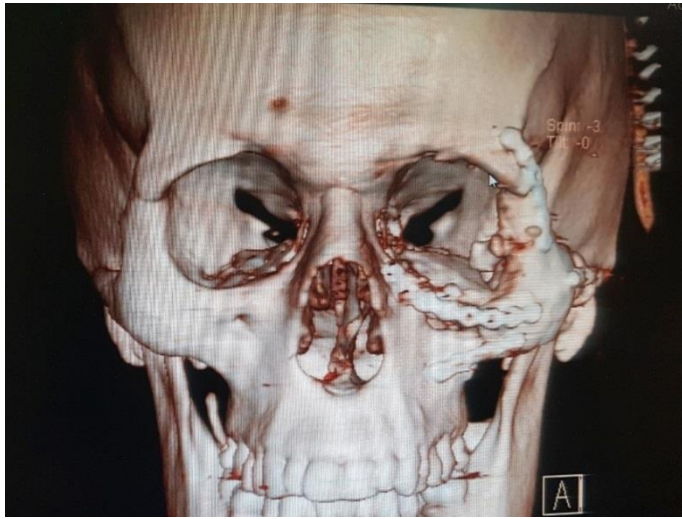


Figure 5. Post- op 3D CT showing appropriate reduction

Intubation

Orotracheal or Nasotracheal intubation is not favorable when the patient has concomitant mandible fracture along with nasal bone fracture; which would require manipulation during surgery, so submental intubation is suggested for these types of panfacial fractures (11). It also obviates the need for tracheotomy or the necessity of changing tube position from nasal to oral intraoperatively (Figure 6).

From our point of view, in ZMC and panfacial fractures,

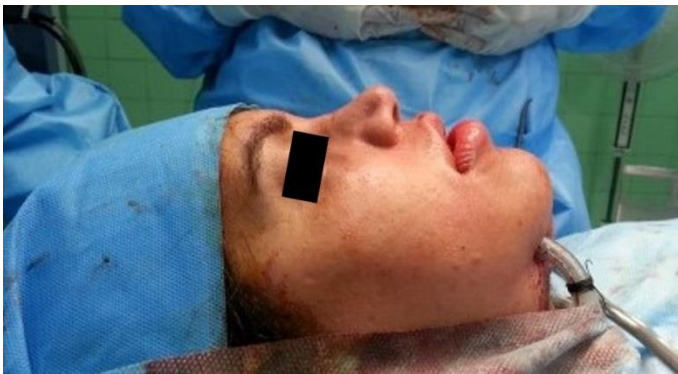

Figure 6. Submental intubation

[submental intubation is the method of choice since it creates negligible complications and scars.

Oral or nasal intubation may cause lip or nasal deformation or may interfere with the holistic view of the face but submental intubation with the tube located in a para median position will

not damage the Wharton's duct or cause any facial deformation. In submental intubation, it would be possible to see the whole face for assessing facial symmetry after fracture reduction. It is crucial to check the connection of the tube for separation before starting intubation since it is difficult to separate the connection in some of the newly designed tubes.

Surgical Approaches

Originally described by Tessier (12, 13) for better approach to the orbits, the coronal approach is useful for exposure of not only the zygomatic arches but also for the superior orbital rims, frontozygomatic suture, and medial and lateral orbital walls (Figure 7). Some authors also suggest that coronal approach is necessary to provide access to the zygomatic arch, but it should be used selectively (14).

It is also believed that a coronal approach will facilitate accurate reduction and fixation of fragments and will allow good cosmetic result with minimal or negligible complications. The coronal incision should be the first choice in case of comminuted, multiple and late zygomaticomaxillary complex fractures.

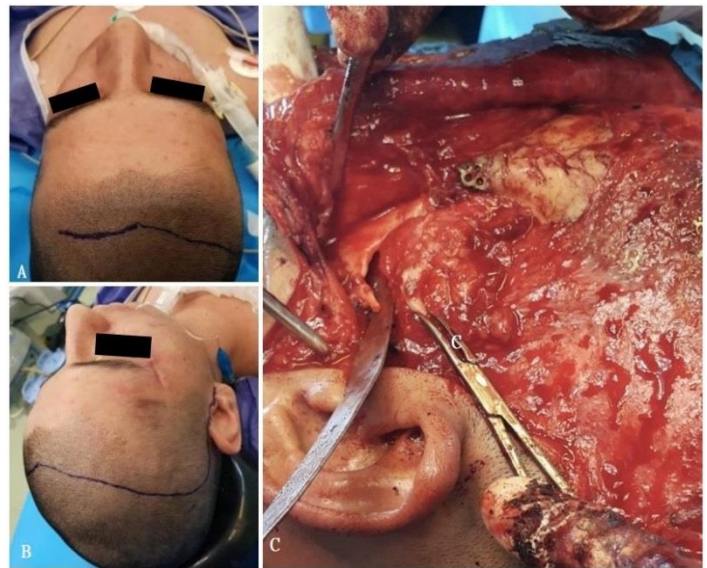


Figure 7. (A, B, C) Coronal approach

However, indications for the use of coronal incision must be strictly applied (Figure 8). It is important to bear in mind that in pan facial fracture or old ZMC fractures, we prefer hemicoronal or bicoronal approaches depending on the need for harvesting calvarial graft. In comminuted pan facial fractures, it is crucial to observe the zygomatic arch especially when its root is



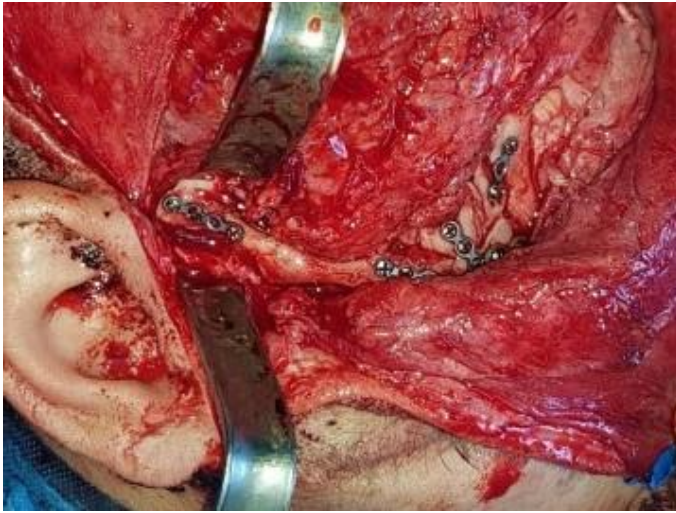

Figure 8. Appropriate reduction and fixation of zygomatic arch through coronal approach

fractured since it indicates the displacement of the whole complex. Generally, approaches to the fracture is determined based on the fracture lines in the CT scan. For this reason, we prepare a 3D CT scan and highlight all the fracture lines and then the most convenient procedures are selected. Our approaches are usually a combination of bicoronal or hemicoronal, vestibular and periorbital incisions.

When scars are present in frontal region, most surgeons prefer using these scars to access fracture lines. However, in our experience it is not advisable to use existing scars for reduction and fixation of frontal fractures. Ideally, the best approach is still the coronal approach in such cases since approaching the fracture lines through scars might hinder adequate access and visibility.

Some surgeons are afraid of using transconjunctival incision since they carry the possibility of acquired cicatricial entropion. (15) On the other hand, cutaneous approaches are associated with a high incidence of scarring and, in some studies, a higher incidence of ectropion. In one systematic review in 2017, it was revealed that the incidence of ectropion and lid malposition is significantly higher in subciliary approach compared to transconjunctival approach. It was concluded that overall, the transconjunctival approach creates the lowest incidence of complications (16).

In our experience, among periorbital incisions, transconjunctival and subciliary incisions produce acceptable scars, but sub tarsal or infraorbital incisions leave a terrible scar. In transconjunctival approach with cantholysis, it is necessary to

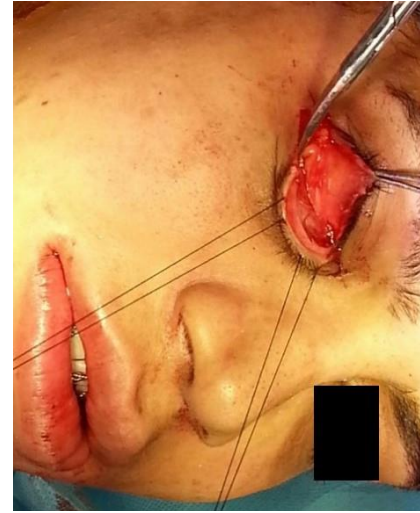

Figure 9. Transconjunctival incision to access orbital floor fracture

perform accurate canthopexy in order to prevent lid malposition (Figure 9, 10). In this approach, it is also necessary to place two retraction sutures on inferior tarsal plate, one laterally and another medially then conjunctiva should be caught with another retraction suture to save both edges.

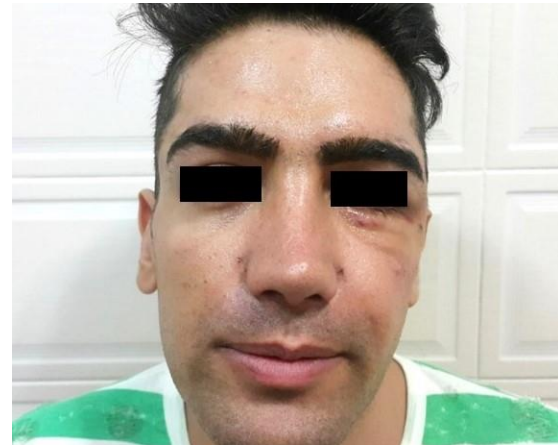

Figure 10. Post- op photo of a patient with transconjunctival approach

Orbital regions can be explored in sagittal view of CT scans preoperatively but from our point of view when there is a fracture with large displacement that requires considerable manipulation, clinical exploration of orbital floor is recommended. It is important to bear in mind that in clinical examination, the best view is supraorbital view (Birds view). According to 4-leg chair concept, all four processes and the zygomatic buttress should be explored to confirm appropriate reduction (Figure 11) (17). In simple fracture, three-process

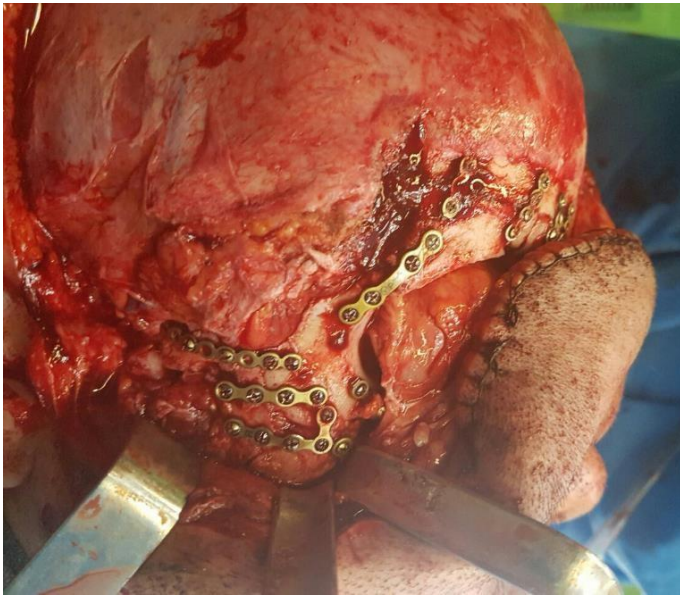


Figure 11. Zygomatic arc and body fixation

exposure seems to be enough but in old or comminuted fractures, all four processes should be explored.

This concept was approved by a systematic review and meta-analysis performed in 2019. In this study, it was suggested that regarding fracture stability, 3-point exposure and fixation provides superior results (18).

Especially in old fractures, the presence of bone loss, bone resorption and callus bone formation is frequently evident. Therefore, it is advisable to remove these calluses for proper bony reduction. In dealing with callus, two points should be kept in mind:

1. Consistency of callus bone is less than native bone and removal is easier
2. Callus bone in young patients is purple because of abundant vascular supply.

Fixation

It has been discussed that direct inspection of fracture reduction in zygomaticosphenoid (ZS) suture at the lateral orbital wall seems to be the most reliable assessment for adequate reduction (19,20,21,22). In our experience, it is important to directly observe ZS suture since it is the key point of ZMC reduction. Sometimes, novice surgeons reduce all fracture lines except ZS and subsequently, lateral rotation of the ZMC complex will occur resulting from the gap in the ZS area. In our experience,

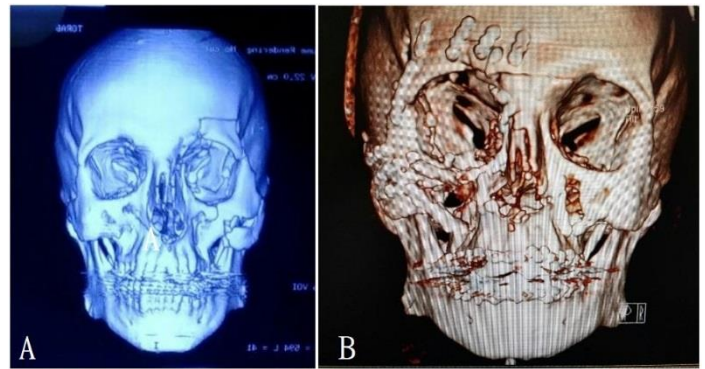


Figure 12. (A, B). Pre and post-op CT

the best results are achieved in cases that ZF fracture line is primarily fixed, followed by horizontal buttresses fixation including infraorbital rim, and finally zygomatic arc. However sometimes it might be necessary to re-fix ZF at this stage. It is also preferred to fix zygomatic arc and infraorbital rim at the same time to achieve a better reduction. In a recent systematic review, it was shown that in the treatment of ZMC fractures, the use of 3-point fixation was superior to 2-point fixation (23). This finding is in total alignment with our experience.

Zygomatic arc plays a key role in ZMC fracture treatment because its root might be fractured and might be left unnoticed. It is recommended to first expose the horizontal plate of the temporal bone or the root of the zygomatic arc. Sometimes there is a fracture line in the middle of the arc but during surgical exploration, we see a green stick fracture line at the root, which was not noticed in 3D CT scans primarily. These green stick fracture lines should be reduced and fixed; otherwise, they might widen the face.

We always use low profile microplate for arc fixation because the skin overlying the arc is very thin and miniplates might be palpable. It is also suggested to undercorrect the arc a little and estimate the arc prominence with microplate thickness (Figure 11). In two regions, we should use stronger plates: lateral orbital rim and zygomaticomaxillary buttress. In these areas, we have to use miniplates. In some cases with thinner soft tissue envelope, it is also possible to use plates with lower profile for infraorbital rim fixation (Figure 12).

In isolated ZMC fractures, we can use intraoral approaches for infraorbital rim reduction and fixation but in pan facial or old ZMC fractures, transconjunctival or subciliary approaches are more appropriate. Both of these approaches can produce different postoperative complications including prolonged



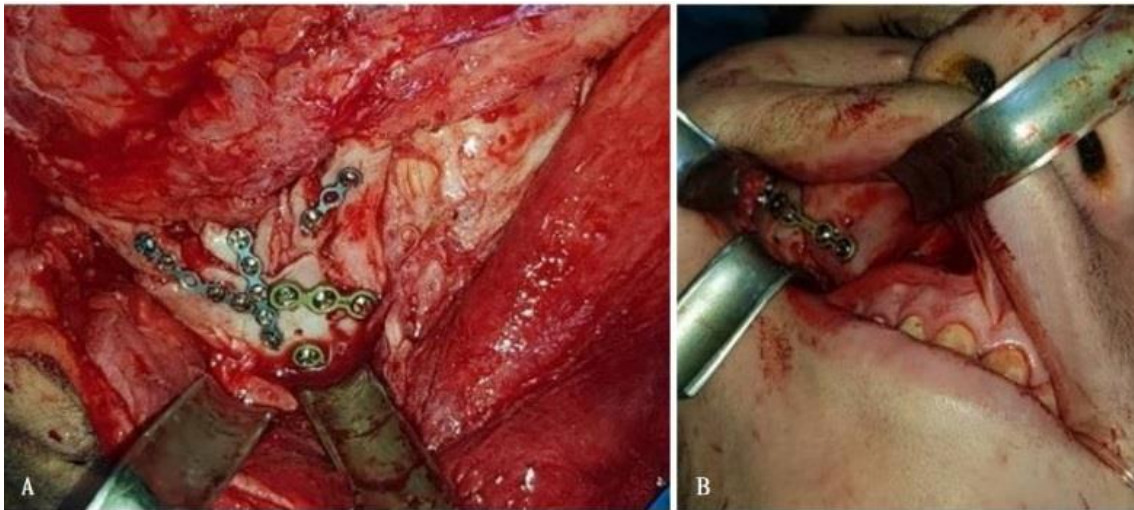


Figure 13. (A, B) Lateral orbital rim and zygomatic buttress fixation

edema and ectropion so novice surgeons need to build up adequate experience to master both techniques and their appropriate indications (24). In infraorbital rim fractures, sometimes there is medial fracture in nasal bone that needs to be exposed with either lynch or H type incisions. This fracture

should be usually fixed first (25). The result of a well-organized operation is good alignment of zygomatic buttress. If the reduction is not appropriate, it will cause medial or lateral displacement of the zygomaticomaxillary complex (Figure 13,14).

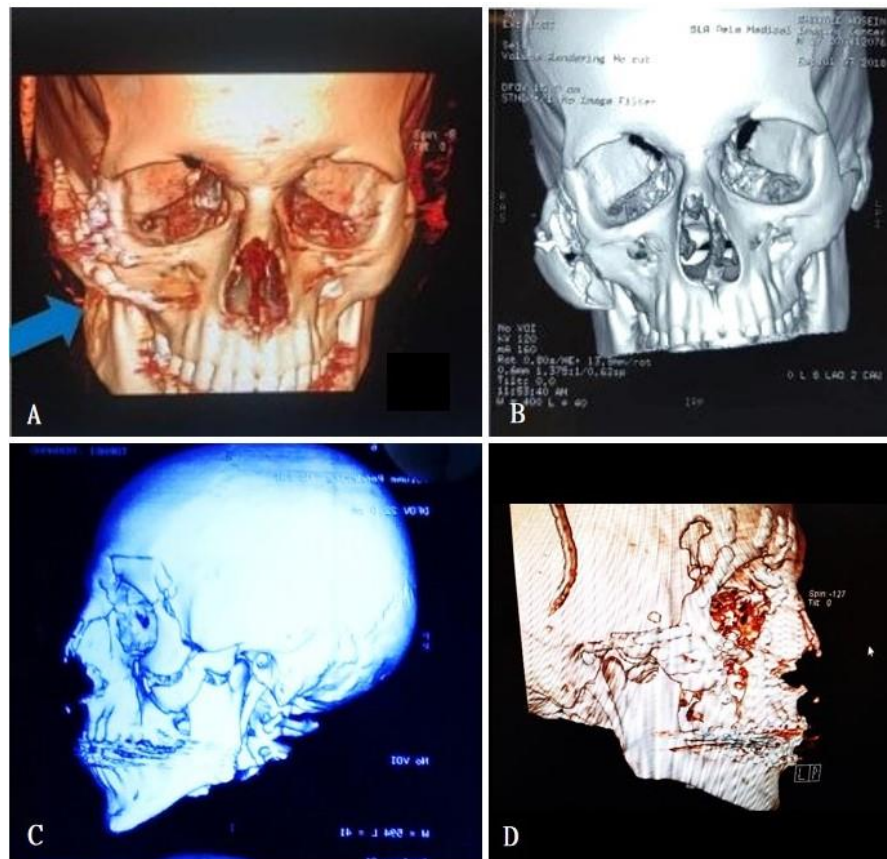


Figure 14. (A, B, C, D) Pre and post op CT of ZMC fracture



Orbital floor reconstruction

The orbital axis extends from the lateral orbital rim to the anterior portion of the lacrimal bone (17). Most fat along the orbital floor is extraconal, meaning that it is anterior to this axis (17). Displacement of this fat through an orbital floor fracture will seldom result in enophthalmos (17).

However, because most of the orbital wall is posterior to this axis, displacement of this osseous segment will result in an increase in orbital volume and resultant enophthalmos (17). Comminuted fractures in the lamina papyracea of the ethmoid bone, which also lies behind the global axis, will have the same effect. Intraconal fat is present behind the global axis, and loss of this structure will likely result in the development of enophthalmos (17).

In orbital floor reconstruction, it is very important to overcorrect the defect because after surgery or trauma, tissue atrophy occurs. This over correction should be performed in orbital floor, posterior to orbital axis. Posterior defects of orbital floor should be explored meticulously. Sometimes it is necessary to reconstruct the lateral orbital walls without the presence of any fracture lines because of the post-traumatic tissue atrophy in that area (Figure 15, 16).

In some cases, orbital volume increase is the cause of enophthalmos and thick blocks of autogenous bone are required to modify orbital volume. In order to prevent dropping the bone block in maxillary sinus, it is advisable to place the block over a previously fixed Titanium mesh in orbital floor. Titanium mesh is thin and flexible and it is possible to place it posterior enough and then place the bone block on its surface (Figure 17, 18,19).

We prefer high density porous polyethylene material (Medpore) to other available materials because it is flexible and is available in various sizes. It also has a soft surface while titanium mesh does not provide a soft surface and may later restrict eye movement because of muscle entrapment. In large total orbital floor defects, it is better to use autograft but smaller defects can be managed with allografts or alloplastic materials. Several layers of Medpor can be used but each layer should be fixed with two sutures or screws. Medpors have two surfaces, the soft surface should face the globe and while trimming, this layer should be protected. Medpors should be completely passive after placement. Any projections will result in interference with globe movement.

It is also suggested to suspend zygomatic minor and major muscles to lateral orbital plate with 2-0 nylon suture for

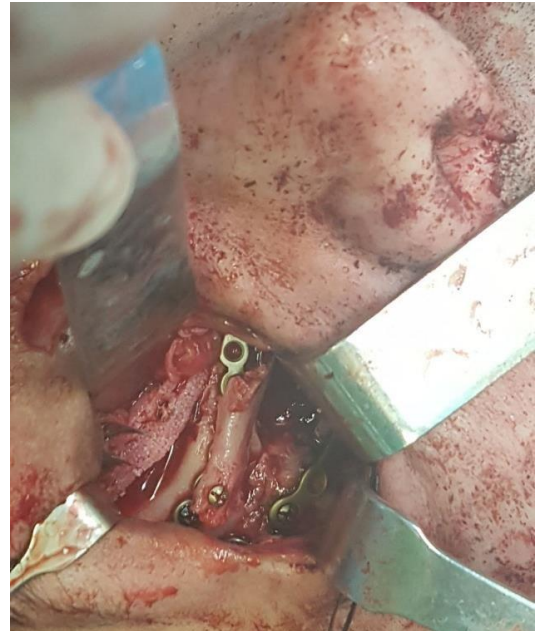

Figure 15. Internal rigid fixation in orbital rim and augmentation

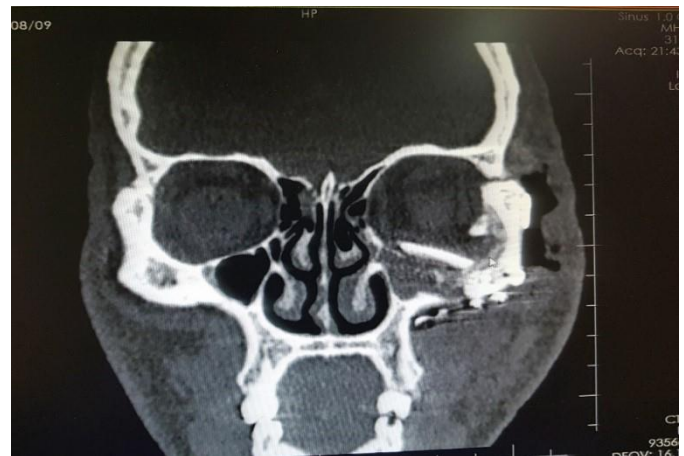

Figure 16. Orbital floor reconstruction to overcorrect the defect

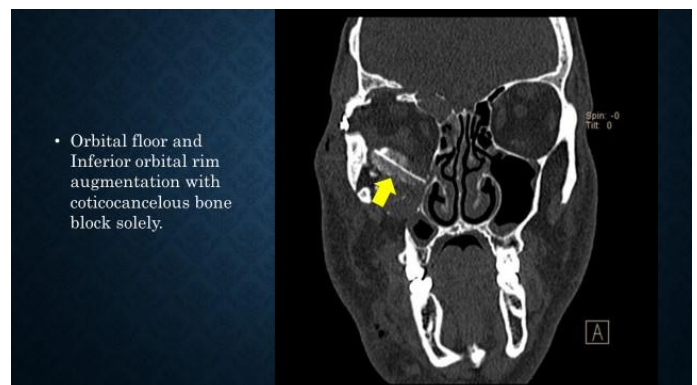


Figure 17. Orbital graft has dropped in to the maxillary sinus



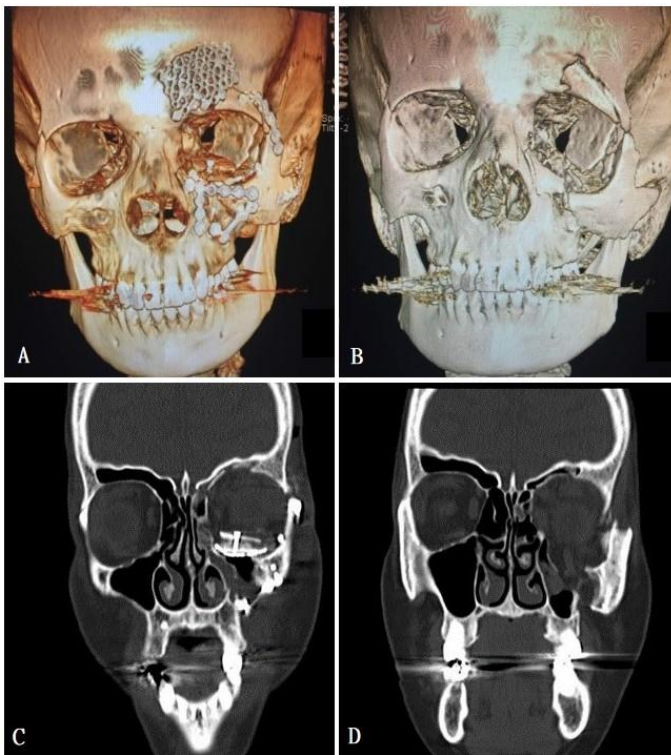


Figure 18. (A, B, C, D) Appropriate bed for corticocancellous bone block

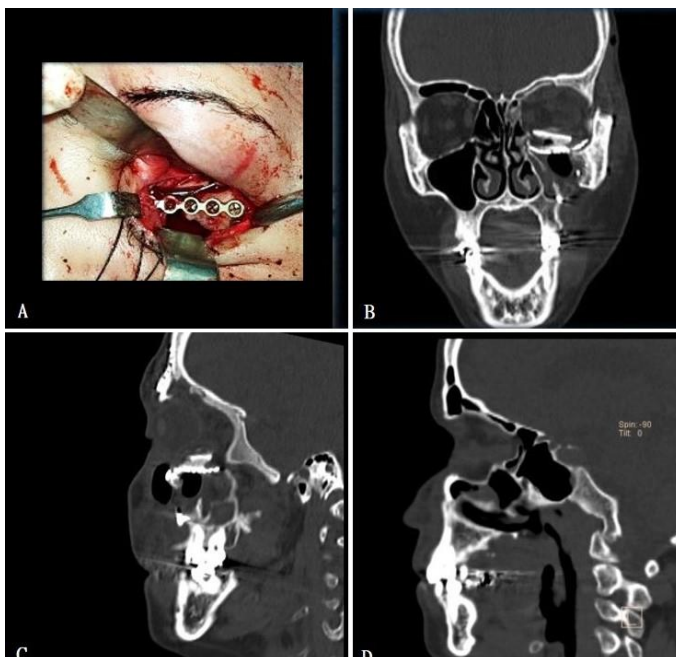


Figure 19. (A, B, C, D) Sagittal view of an appropriately placed autogenous block

muscular reattachment to prevent muscular sagging. When using subciliary or transconjunctival incisions, frost suture is advisable for at least 4-5 days' post operatively.

In managing panfacial fractures, any little bony fractures should be reduced and if a segment of fractured bone is lost or is impossible to reduce, Titanium mesh should be used to reconstruct the area because some of these defects in bone will become visible after a while.

In medial orbital wall reconstruction, sometimes canthopexy is performed and after few days, relapse is evident because instead of catching the cantus, peripheral fibrotic tissue is sutured and attached. It is suggested to remove the fibrosis first and then reattach the cantus neatly. Generally, wire is preferred over sutures for canthopexy.

Medial orbital wall reconstruction could be very difficult because of the presence of angular artery and vein, anterior and posterior ethmoidal arteries and lacrimal apparatus, therefore having a team approach and including an ophthalmologist in the team is recommended. Medial orbital wall can be exposed using three approaches: coronal, lynch and infraorbital incisions. For isolated medial orbital wall and orbital floor fractures, transconjunctival approach with transcoroncular modification is recommended. For patients with panfacial fracture using all three approaches are suggested. In coronal approach, it is better to use calvarial graft to prevent two donor sites morbidity (26), but when the treatment plan consists of augmentation without osteotomy, iliac graft is preferred.

We usually use bottom to top approach: first mandible, then maxilla and finally zygomatic bone. Sometimes maxilla is displaced minimally, in this cases it is possible to reduce mandible first and then proceed to zygoma and finally maxilla. It is important to remember that in case of bilateral condylar fractures, it is necessary to open both condyles most of the times.

Closure

For wound closure, simple and separate sutures are preferred over continuous sutures. In coronal approach, it is very important to put subcutaneous sutures close to each other, tighten them with internal ties, and evert the incision line. Staples are also suggested since they are faster to use and cause less scar.

In subciliary incisions, periosteum and skin should be sutured, and the muscle should remain unsutured, to prevent



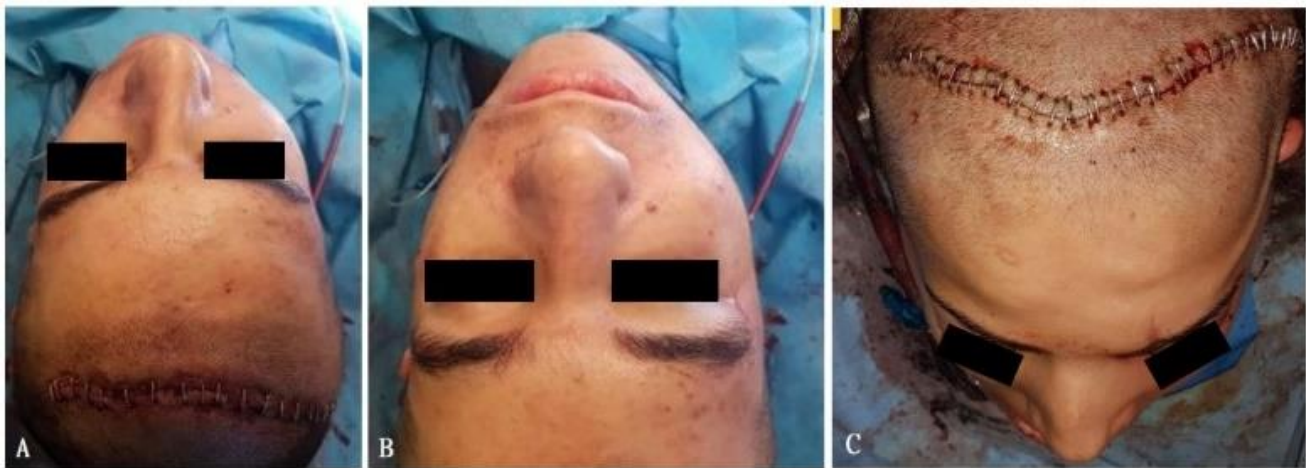

Figure 20. (A, B, C) Wound closure

ectropion. In subciliary incision, step-like incision is preferred. These two considerations help prevent ectropion.

In transconjunctival incisions, it is suggested to close conjunctiva with three separated sutures and the ties should be internal, i.e. not facing the globe.

In closing cantholysis incision, the two footplates of the lateral canthal ligament should be detected and grabbed with 5-0 nylon suture without knotting. After transconjunctival sutures are placed, lower footplate should be suspended to the lateral plate to prevent lateral cantus displacement. The skin of the lateral canthotomy incision is then sutured. Pseudo ectropion and lower lid displacement will occur in subconjunctival incisions if lower footplate is not suspended properly.

Sometimes after using coronal approach, a hollowing is visible on temporal muscle area postoperatively. This could be caused by temporal muscle retraction or perforation instead of dissecting over the deep temporal fascia (27). It is recommended to suture the temporal fascia before skin closure to avoid this

complication. Sometimes temporal muscle atrophy occurs because of previous surgery or trauma. In such cases, dermis fat graft is suggested to restore the bulk (Figure 20,21).

Conclusion

In order to have acceptable functional and cosmetic outcomes in treatment of ZMC fractures, surgeons should pay meticulous attention to every detail in treatment process. Accurate diagnosis and early intervention are of crucial importance. Careful paraclinical assessment, formulation of a clear treatment plan, adequate surgical exposure and proper reduction of fractured segments will help achieve the desirable outcome. In the end, surgical expertise, which is acquired through practice, will help surgeons attain the ideal results and manage complications in case they arise.

Acknowledgment

The authors would like to thank Dr. Hossein Heydar and Dr. Mohammad Bayat for their dedication in educating multiple generations of competent maxillofacial surgeons.

Conflict of Interest: 'None declared'.

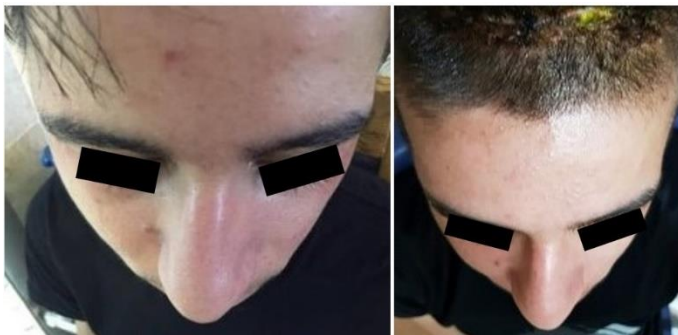

Figure 21. Wound healing (Birds view)



References

- Lin Q, Hong XY, Zhang D, Jin HJ. Preoperative evaluation and surgical technique of functional and cosmetic aspects in zygomatic complex fracture patients. *J Biol Regul Homeost Agents*. 2017;31(4):1005-1012.
- Marinho R O, Freire-Maia B. Management of fractures of the zygomaticomaxillary complex. *Oral Maxillofac Surg Clin North Am*. 2013;25(4):617-636
- Ramezani M, Mahmoud-Hashemi H, Vaezi T, Beshkar M, Hasheminasab M. The pattern of maxillofacial fractures: a study of 302 patients and a discussion of fracture classification. *J Ramezani et al \102 Craniomax Res* 2015;2(1-2) 95-102)
- Malaviya P, Choudhary S. Zygomaticomaxillary buttress and its dilemma. *J Korean Assoc Oral Maxillofac Surg*. 2018;44(4):151-158. doi:10.5125/jkaoms.2018.44.4.151.
- van Hout WM, Van Cann EM, Koole R, Rosenberg AJ. Surgical treatment of unilateral zygomaticomaxillary complex fractures: A 7-year observational study assessing treatment outcome in 153 cases. *J Craniomaxillofac Surg*. 2016;44(11):1859-1865. doi: 10.1016/j.jcms.2016.09.002
- Brasileiro B F, Passeri L A. Epidemiological analysis of maxillofacial fractures in Brazil: a 5-year prospective study. *Oral Surg Oral Med Oral Pathol Oral Radiol Endod*. 2006; 102:28-34
- Zhang X, Han CY, Dai MJ, et al., Application of computer-assisted surgery techniques in the management of zygomatic complex fractures. *Chin J Traumatol*. 2018;21(5):281-286. doi: 10.1016/j.cjtee.2018.01.007
- Bao T, Yu D, Luo Q, Wang H, Liu J, Zhu H. Quantitative assessment of symmetry recovery in navigation-assisted surgical reduction of zygomaticomaxillary complex fractures. *J Craniomaxillofac Surg*. 2019;47(2):311-319. doi: 10.1016/j.jcms.2018.12.003
- Myga-Porosilo J, Skrzewski S, Sraga W, Borowiak H, Jackowska Z, Kluczevska E. CT Imaging of facial trauma. Role of different types of reconstruction. Part I—bones. *Pol J Radiol*. 2011;76(1):41-51.
- Markiewicz MR, Gelesko S, Bell RB. Zygoma reconstruction. *Oral Maxillofac Surg Clin North Am*. 2013;25(2):167-201. doi: 10.1016/j.coms.2013.02.005
- González-Magaña F, Malagón-Hidalgo HO, García-Cano E, Vilchis-López R, Fentanes-Vera A, Ayala-Ugalde FA. Airway management through submental derivation: a safe and easily reproduced alternative for patients with complex facial trauma. *J Korean Assoc Oral Maxillofac Surg*. 2018;44(1):12-17. doi:10.5125/jkaoms.2018.44.1.12
- Abubaker AO, Sotereanos G, Patterson GT. Use of the coronal surgical incision for reconstruction of severe craniomaxillofacial injuries. *J Oral Maxillofac Surg*. 1990; 48:579-86.
- Matras H, Kuderna H. Combined cranio-facial fractures. *J Maxillofac Surg*. 1980; 8:52-9.
- Nicholas Peretti and Stephen MacLeod. Zygomaticomaxillary complex fractures: diagnosis and treatment. *J Maxillofacial surgery*. 2017; 00:1-6.
- Ridgway EB, Chen C, Lee BT. Acquired entropion associated with the transconjunctival incision for facial fracture management. *J Craniofac Surg*. 2009;20(5):1412-1415. doi:10.1097/SCS.0b013e3181aee3ee.
- Al-Moraissi EA, Thaller SR, Ellis E. Subciliary vs. transconjunctival approach for the management of orbital floor and periorbital fractures: A systematic review and meta-analysis. *J Craniomaxillofac Surg*. 2017;45(10):1647-1654. doi: 10.1016/j.jcms.2017.07.004
- Fonseca J. oral and maxillofacial trauma. 4th ed.2013.
- Jazayeri HE, Khavanin N, Yu JW, et al., Fixation Points in the Treatment of Traumatic Zygomaticomaxillary Complex Fractures: A Systematic Review and Meta-Analysis. *J Oral Maxillofac Surg*. 2019;77(10):2064-2073. doi: 10.1016/j.joms.2019.04.025)
- Marinho and Freire-Maia. Management of Fractures of the Zygomaticomaxillary Complex. *Oral Maxillofac Surg Clin N Am*. 2013;25: 617-636.
- Zingg M, Laedrach K, Chen J, et al., Classification and treatment of zygomatic fractures: a review of 1,025 cases. *J OralMaxillofac Surg*.1992; 50:778-90
- Lee EI, Mohan K, Koshy JC, et al., Optimizing the surgical management of zygomaticomaxillary complex fractures. *Semin Plast Surg*. 2010;24:389-97.
- Hollier LH, Thornton J, Pazmino P, et al., The management of orbitozygomatic fractures. *Plast Reconstr Surg*. 2003; 111:2386-92.
- Gadkari N, Bawane S, Chopra R, Bhate K, Kulkarni D. Comparative evaluation of 2-point vs 3-point fixation in the treatment of zygomaticomaxillary complex fractures - A systematic review. *J Craniomaxillofac Surg*. 2019;47(10):1542-1550. doi: 10.1016/j.jcms.2019.07.009
- El-Anwar MW, Elsheikh E, Hussein AM, Tantawy AA, Abdelbaki YM. Transconjunctival versus subciliary approach to the infraorbital margin for open reduction of zygomaticomaxillary complex fractures: a randomized feasibility study. *Oral Maxillofac Surg*. 2017;21(2):187-192. doi:10.1007/s10006-017-0617-2
- Ha YI, Kim SH, Park ES, Kim YB. Approach for naso-orbito-ethmoidal fracture. *Arch Craniofac Surg*. 2019;20(4):219-222. doi:10.7181/acfs.2019.00255.
- Gema SM, Momeni M, Badri AA. Split Calvarial Graft and Titanium Mesh for Reconstruction of Post-Craniotomy Frontal Bone Defect. *Ethiop J Health Sci*. 2018;28(2):245-248. doi:10.4314/ejhs.v28i2.16
- Matic DB, Kim S. Temporal hollowing following coronal incision: a prospective, randomized, controlled trial. *Plast Reconstr Surg*. 2008;121(6):379e-385e. doi:10.1097/PRS.0b013e318170724c.

Please cite this paper as: Momeni M, Hasheminasab M, Afsar N. Clinical Pearls in Treatment of Zygomaticomaxillary Complex Fractures . *Regen Reconstr Restor*. 2020;5 (1): e20. Doi: 10.22037/rrr.v5i1.29335.

