

# Localized Inlay Extended Tuberosity Block Bone Graft Technique: Simultaneous Management of Unfavorable Posterior Intermaxillary Space and Vertical Ridge Deficiency

Seied Omid Keyhan<sup>a</sup>, Seifollah Hemmat<sup>b</sup>, Sina Ghanean<sup>a\*</sup>, Alireza Jahangirnia<sup>c</sup>

<sup>a</sup> Department of Oral and Maxillofacial Surgery, Dental School, Shahid Sadoughi University of Medical Sciences, Yazd, Iran; <sup>b</sup> Department of Oral and Maxillofacial Surgery, Dental School, Hormozgan University of Medical Sciences, Bandar Abbas, Iran; <sup>c</sup> Oral and Maxillofacial Surgeon, Private Practice, Tehran, Iran

\*Corresponding author: Sina Ghanean, Department of Oral and Maxillofacial Surgery, Shahid Sadoughi University of Medical Sciences, Yazd, Iran. Tel: +98-912 6076927; E-mail: sinasin@gmail.com

Submitted: 2016-02-11; Accepted: 2016-04-27

After extraction of posterior mandibular teeth, posterior dentoalveolar maxillary extrusion is a common finding in edentulous patients. As the edentulous area continues to atrophy, there is a continuous loss of bone height and density as well as antral pneumatization. Various techniques can be used for correction of this condition. The present article presents an innovative technique that can correct moderate to severe localized defects of the alveolar process prior to implant placement in the posterior maxillary ridge. The combination of extended tuberosity block bone graft harvesting with modified alveoloplasty (alveolectomy) and quadrilateral open sinus lift (localized inlay tuberosity block bone graft technique) is presented as an alternative to simple alveoloplasty for management of the deficient interarch space and antral pneumatization for prosthetics rehabilitation in the posterior edentulous maxillary segments. Surgical intrusion of the osteotomised bone segment as a corticocancellous block bone graft to the sinus cavity results in adequate interarch space and simultaneous vertical ridge augmentation in deficient posterior maxillary ridge for surgical and prosthetic outcomes without the need to harvest bone from another site. This quick and simple method does not need general anesthesia and has fewer complications. Localized inlay extended tuberosity block bone graft can be used as an alternative to simple alveoloplasty and posterior maxillary segmental osteotomy in distal extended edentulous patients for simultaneous management of unfavorable interocclusal distance and sinus pneumatization.

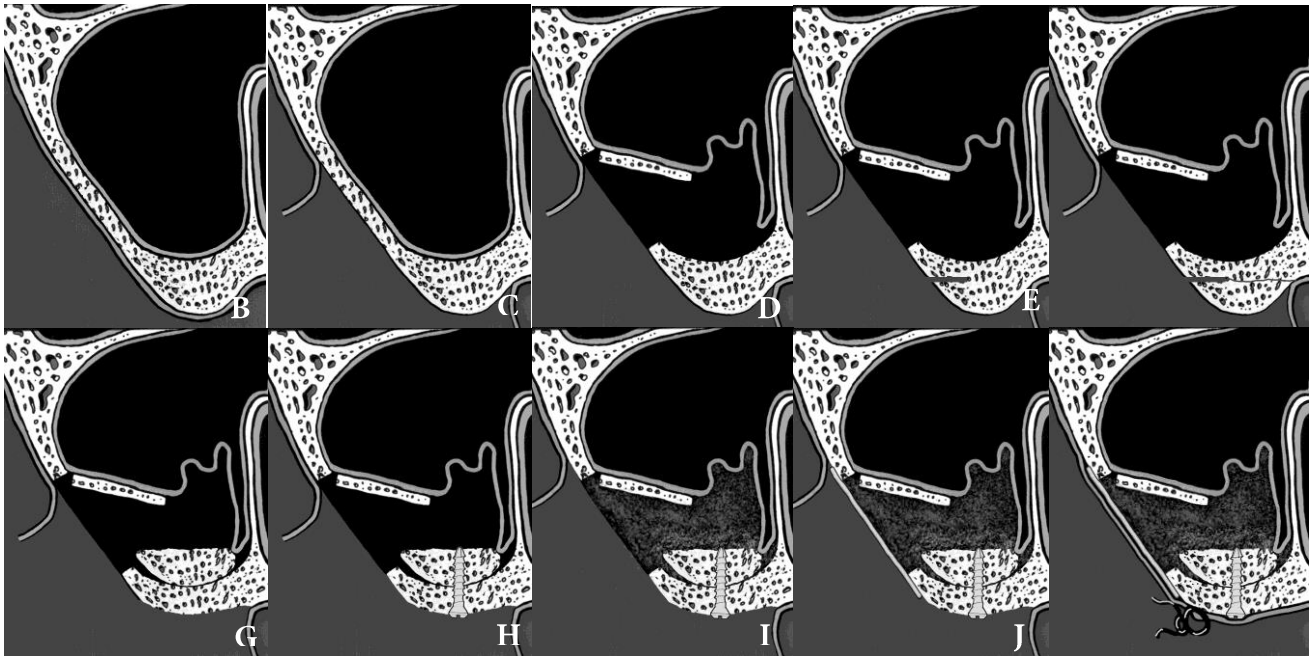
**Keywords:** Sinus floor augmentation; Alveolar ridge augmentation; Alveoloplasty; Tuberosity

## Introduction

After extraction of posterior mandibular teeth, the posterior dentoalveolar maxillary extrusion is a common finding in edentulous patients. In this condition, if the posterior maxillary teeth were lost, the initial decrease in bone width would occur due to the resorption of the buccal bone plate. Progressive decrease in bone height and density and ongoing antral pneumatization is appeared with accelerating atrophy of edentulous regions (1, 2). Hence, it is common to find the sinus floor close to the alveolar crest. This situation is due to two circumstances: 1) increased osteoclastic activity of the periosteum of the schneiderian membrane which causes post-extraction sinus expansion to the detriment of the alveolus (1, 3); 2) increased positive intra-antral pressure which causes expanded pneumatization of the sinus (4). The treatment of the posterior maxillary bone is dependent on the volume of bone available in the subsinus area.

In prosthetic reconstruction of edentulous or partially edentulous patients, undesirable interocclusal distance is a major concern. Oversize fibrous tuberosity is the most frequent

cause of inadequate posterior interarch space that needs soft tissue correction. In addition, there may be a need for skeletal correction. Posterior segmental maxillary osteotomy (PSMO), simple reduction alveoloplasty, orthodontic treatment such as tooth intrusion, crown lengthening with restorative intervention are treatment options that have been used for correction of unfavorable intermaxillary space (5-8). Particulate and block autogenous bone has been used for correction of alveolar ridge deficiencies. In the clinical practice, a maxillary tuberosity bone graft has often been used as a particulate graft for augmentation of deficient alveolar ridge or maxillary sinus prior to or simultaneously with implant insertion (9). Several classifications have been proposed to categorize the amount of bone present below the sinus (1) and treatment of this condition depends on the extent of bone loss. The extended tuberosity block bone graft harvested by modified alveoloplasty technique modified in combination with quadrilateral open sinus lift "localized inlay extended tuberosity block bone graft technique" can be used as an alternative to simple alveoloplasty for simultaneous ridge augmentation and reduction in management of edentulous patients with oversize tuberosity. Several advantages of this



**Figure 1.** Schematic illustration of extended tuberosity block harvest and simultaneous sinus lifting

method include the following: no need for general anesthesia, being cost benefit process, being fast and simple and it consists of alveoloplasty without loss of cortical bone. The main disadvantages of this method include having complications such as sinus exposure, bone graft resorption, creating mobilized keratinized mucosa, and the widened edentulous ridge.

In this study, we aimed to introduce block graft harvest from maxillary tuberosity and adjacent alveolar bone for sinus lift and bone augmentation.

## Surgical Technique

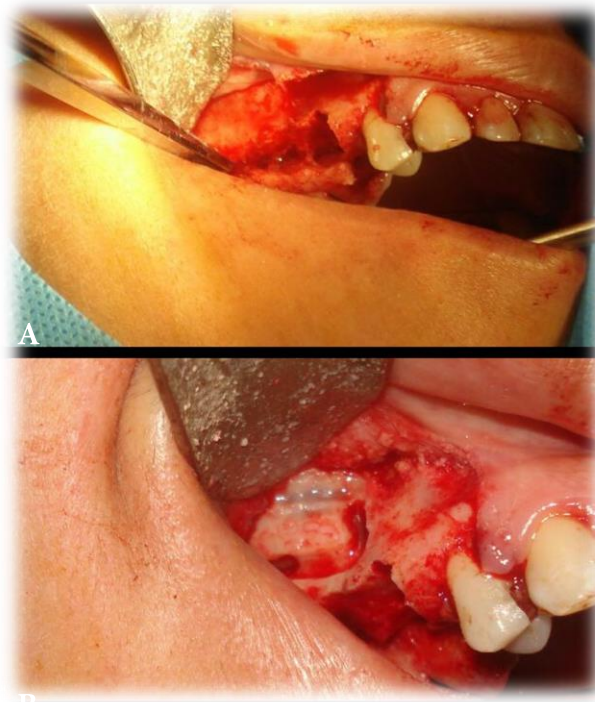
The procedure is done with the patient under local anesthesia (lidocaine 2% and epinephrin 1/100000). A crestal wedge-shaped incision is made and full-thickness mucoperiosteal flap is elevated from the premolars teeth to the posterior section of the maxillary tuberosity (Figure 1 A, B). Quadrilateral osteotomy is performed for hinge osteotomy sinus lift technique, where a hinge bony rectangle is created in the lateral wall of the maxilla, approximating the malar buttress. This bony rectangle is then pushed inward, along with the schneiderian membrane, to function as a new sinus floor (Figure 1C).

A periodontal probe is inserted between the antral membrane and the bony wall of the sinus and extended down to the osseous floor. Reduction of this number from an external alveolar height that is measured from the inferior bone cut of the quadrilateral osteotomy to the crest of the alveolar process determined the vertical bone height that is in access for reduction alveoloplasty. By this method of measurement, it is

possible to determine the remained bone between the sinus floor and the alveolar crest for harvesting extended tuberosity block bone graft from tuberosity and alveolar crestal bone and to correct unfavorable interocclusal distance. The osteotomy cut for reduction alveoloplasty and harvesting bone graft is made to leave approximately 1 to 1.5 mm of alveolar bone height anteriorly and posteriorly to prevent exposure of sinus floor. The desired corticocancellous block graft is marked by guiding holes from buccal to the lingual aspect of alveolar ridge, then holes connected to each other with bur and finally with a fine osteotome, the corticocancellous block bone graft harvested from tuberosity and posterior alveolar ridge crest (Figure 1D, E). Bone grafts are inserted to normal saline solution for later procedures. Other correction and bone edge smoothing is done by bone file and bone cutter. The block bone graft is inserted in the sinus cavity on the sinus floor from cancellous aspect and fix with lag screw technique from the crestal aspect (Figure 1F, G). Then the platelet rich plasma is placed under the elevated sinus membrane (Figure 1H). The guided bone regeneration (GBR) membrane is trimmed and placed over the lateral wall window (Figure 1I). The mucoperiosteal flap is repositioned and sutured (Figure 1J). The clinical procedure is demonstrated in Figures 2 A, B.

## Discussion

Unfavorable interocclusal space is a common problem in prosthetic rehabilitation of edentulous patients. Oversize



**Figure 2.** (A, B) Clinical photographs of extended tuberosity block harvest and simultaneous sinus lifting

fibrous tuberosity is the most frequent cause of inadequate posterior interarch space that requires soft tissue correction. However, regularly bone removal is also mandatory. Posterior segmental maxillary osteotomy (PSMO), simple reduction alveoloplasty, orthodontic treatment such as tooth intrusion and crown lengthening with restorative intervention are options that have been used for correction of unfavorable intermaxillary space. Each of these techniques has advantages, disadvantages, and indications (5-8). In this case, alveolar vertical reduction of the edentulous ridge is usually the first treatment option. Although vertical reduction of the overgrown tuberosity seems to be a simple procedure, it may be accompanied with some complications such as loss of cortical bone during reduction; mobilized keratinized mucosa, widened edentulous ridge, and sinus exposure. These complications cause difficulties for future implant placement and prosthetic rehabilitation. PSMO is usually performed in dentate segments and may be an alternative to vertical alveolar reduction in edentulous segments. But this is a complex and costly procedure with major complications such as tissue necrosis with several considerations, contraindications, and requires general anesthesia. When over eruption is extreme or involves several teeth, Orthodontic intrusion is difficult and time consuming with complications such as root resorption. Crown lengthening with restorative intervention is the simplest method, but has limited indications with unpredictable results. Localized inlay extended tuberosity block bone graft technique is an alternative method that seems to be beneficial with few

complications (10) which can be used as an alternative to simple alveoloplasty for simultaneous ridge augmentation and reduction in management of patients with oversized tuberosity with unfavorable inter occlusal distance and sinus pneumatization. Advantages of this method include: 1) no need for general anesthesia, 2) no major complication, 3) not being time consuming, 4) an one stage procedure, 5) alveoloplasty without cortical bone loss, and 6) easy technique. The main disadvantages include: 1) limited indications, 2) sinus exposure, 3) bone graft resorption, 4) mobilized keratinized mucosa, 5) widened edentulous ridge. Autogenous bone is usually chosen over xenograft, allogeneic, and synthetic bone substitutes, due to its compatibility and osteogenic, osteoinductive, and osteoconductive properties. Recently, human maxillary tuberosity was known as a proper source of osteoprogenitor cells for bone tissue engineering (11). Simultaneously, bone quality of posterior maxilla, especially in the maxillary tuberosity area, is normally inadequate and contains mostly of a thin cortical layer and a mixture of marrow spaces, adipose tissue, and a small amount of vital osteogenic cells (2). In spite of this, the maxillary tuberosity as a donor site for particulate bone is utilized for correction of small atrophic, traumatic, and periodontal bone defects of the alveolar ridge and subantral augmentation (4). Expansion or overgrowth of the maxillary tuberosity is a common situation that a surgeon may confront while evaluating for complete maxillary denture construction in edentulous patients. It is often recommended by surgical specialists to remove undercuts and



facilitate conventional denture prosthetics. In many implant reconstruction cases involving the partial or complete arch, an enlarged maxillary tuberosity is often overlooked as a potential source of autogenous block bone graft (12, 13). Quantitative comparison of different intraoral grafts is not easy because of variability in surgical approaches. It has been reported that volume of corticocancellous symphyseal (chin) block graft ranges 4 to 5 mL of with a mean block size of approximately 21x10 x7 mm (14). A ramus cortical block graft from the posterior mandible can be the same size or larger depending on the particular donor site (ascending ramus, external oblique ridge, retromolar, or molar area). The size of maxillary tuberosity corticocancellous block graft also depends on the size of the maxillary tuberosity. A horizontal 1 to 2 cm deficient ridge of maxilla could be an optimal recipient for this kind of graft (4). The tuberosity can be shaped or reduced slightly before harvesting. There are many advantages of using maxillary tuberosity block bone graft over other intraoral sources of autogenous block grafts (symphysis, ramus). Symphyseal (chin) block grafts carry a possibility of lower incisor tooth numbness or wooden sensation, temporary or permanent mental nerve injury (15, 16), incisor tooth injury, lingual cortex fracture, and perforation into the lingual soft tissue (17), uncomfortable scarring in the lower vestibule, esthetic disharmony of the lower facial contours, etc. Ramus block grafts bear a possibility of inferior alveolar nerve paresthesia or anesthesia, decreased sensitivity in the posterior vestibular mucosa (corresponding to the injury of the long buccal nerve) (15), significant postoperative discomfort, swelling, and bleeding. Removing a block graft from the normally dense cortical bone with a saw or bur and postoperative incomplete regeneration of the donor site are technical complications of bone harvest from chin and ramus (9). The maxillary tuberosity is usually missed at the time of implant evaluation as a potential source for not only particulate but also block bone grafts for localized ridge deformities. It seems that the use of the maxillary tuberosity, if large enough and suitable for a block graft, can be a relatively simple and valuable alternative technique that can offer an intraoral corticocancellous autogenous graft with fewer intraoperative difficulties and postoperative complications, without the need to repair the donor site, and excellent potential to correct localized alveolar ridge defects. It is also a source of both block and particulate autogenous bone.

Conflict of Interest: 'None declared'.

## References

1. Davarpanah M, Martinez H, Tecucianu JF, Hage G, Lazzara R. The modified osteotome technique. *Int J Periodontics Restorative Dent*. 2001;21(6):599-607.
2. Garg AK. Augmentation grafting of the maxillary sinus for placement of dental implants: anatomy, physiology, and procedures. *Implant Dent*. 1999;8(1):36-46.
3. Kraut RA, Kessler HP, Holmes RE. Quantification of bone in dental implant sites after composite grafting of the mandible: report of a case. *Int J Oral Maxillofac Implants*. 1989;4(2):153-8.
4. Smiler DG, Johnson PW, Lozada JL, Misch C, Rosenlicht JL, Tatum OH, Jr., et al. Sinus lift grafts and endosseous implants. Treatment of the atrophic posterior maxilla. *Dent Clin North Am*. 1992;36(1):151-86; discussion 87-8.
5. Ataoglu H, Kucukkolbasi H, Ataoglu T. Posterior segmental osteotomy of maxillary edentulous ridge: an alternative to vertical reduction. *Int J Oral Maxillofac Surg*. 2002;31(5):558-9.
6. McArthur DR, Turvey TA. Maxillary segmental osteotomies for mandibular removable partial denture patients. *J Prosthet Dent*. 1979;41(4):381-7.
7. Mopsik ER, Buck RP, Connors JO, Watts LN. Surgical intervention to reestablish adequate intermaxillary space before fixed or removable prosthodontics. *J Am Dent Assoc*. 1977;95(5):957-60.
8. Rosen PS, Forman D. The Role of Orthognathic Surgery in the Treatment of Severe Dentoalveolar Extrusion. *The Journal of the American Dental Association*. 1999;130(11):1619-22.
9. Tolstunov L. Maxillary tuberosity block bone graft: innovative technique and case report. *J Oral Maxillofac Surg*. 2009;67(8):1723-9.
10. Khojasteh A, Nazeman P, Tolstunov L. Tuberosity-alveolar block as a donor site for localised augmentation of the maxilla: a retrospective clinical study. *Br J Oral Maxillofac Surg*. 2016.
11. Cicconetti A, Sacchetti B, Bartoli A, Michienzi S, Corsi A, Funari A, et al. Human maxillary tuberosity and jaw periosteum as sources of osteoprogenitor cells for tissue engineering. *Oral Surg Oral Med Oral Pathol Oral Radiol Endod*. 2007;104(5):618.e1-12.
12. Raghoebar GM, Timmenga NM, Reintsema H, Stegenga B, Vissink A. Maxillary bone grafting for insertion of endosseous implants: results after 12-124 months. *Clin Oral Implants Res*. 2001;12(3):279-86.
13. Raghoebar GM, Brouwer TJ, Reintsema H, Van Oort RP. Augmentation of the maxillary sinus floor with autogenous bone for the placement of endosseous implants: a preliminary report. *J Oral Maxillofac Surg*. 1993;51(11):1198-203; discussion 203-5.
14. Montazem A, Valauri DV, St-Hilaire H, Buchbinder D. The mandibular symphysis as a donor site in maxillofacial bone grafting: a quantitative anatomic study. *J Oral Maxillofac Surg*. 2000;58(12):1368-71.
15. Clavero J, Lundgren S. Ramus or chin grafts for maxillary sinus inlay and local onlay augmentation: comparison of donor site morbidity and complications. *Clin Implant Dent Relat Res*. 2003;5(3):154-60.
16. Weibull L, Widmark G, Ivanoff CJ, Borg E, Rasmusson L. Morbidity after chin bone harvesting--a retrospective long-term follow-up study. *Clin Implant Dent Relat Res*. 2009;11(2):149-57.
17. Cordaro L, Amade DS, Cordaro M. Clinical results of alveolar ridge augmentation with mandibular block bone grafts in partially edentulous patients prior to implant placement. *Clin Oral Implants Res*. 2002;13(1):103-11.

**Please cite this paper as:** Keyhan SO, Hemmat S, Ghanean S, Jahangirnia A. Localized Inlay Extended Tuberosity Block Bone Graft Technique: Simultaneous Management of Unfavorable Posterior Intermaxillary Space and Vertical Ridge Deficiency. *Regen Reconstr Restor*. 2016;1(3):145-148.

