

Comparison of Morphine and Diclofenac Intra-articular Injection in Temporomandibular Joint Disorders: A Randomized Controlled Clinical Trial

Shahrokh Raeesian^a, Hamid Reza Fallahi^a, Mahdis Masoudrad^{a*}

^a Department of Oral and Maxillofacial Surgery, Jondishapour University of Medical Sciences, Ahvaz, Iran.

*Corresponding author: Mahdis Masoudrad, Department of Oral and Maxillofacial Surgery, Jondishapour University of Medical Sciences, Ahvaz, Iran, P.O. 15794-61357. E-mail: mahdis.mr@gmail.com; Tel: +98-61 13367543

Submitted: 2016-02-31; Accepted: 2016-04-16

Introduction: Intra-articular injection has been used in patients with chronic temporomandibular joint (TMJ) pain for several years; however, there are still doubts regarding its effectiveness and duration of action. The aim of this study was to compare the analgesic effects of intra-articular injection of morphine, diclofenac, and isotonic saline on the patients with chronic TMJ pain. **Materials and Methods:** Sixty-six patients with TMJ pain were enrolled in a prospective randomized double-blind and placebo-controlled clinical study. Patients were randomly allocated into three groups in which 12 patients consisted in each group. The analgesic effect of intermittent morphine injection (10 mg/ml), diclofenac sodium (25mg/ml), and normal saline was evaluated. In each group, pain reduction was evaluated by using visual analog scale (VAS) by following time points: 10, 60 min, and a week after injection. **Results:** All patients in the three groups experienced pain reduction during the experiment. Among them, patients who received morphine showed significantly more reduction in pain than the other the two groups at 60 minutes ($P<0.05$) and a week after the second injection ($P<0.001$). **Conclusion:** Regardless of the type of treatment, TMJ pain was initially reduced presumably due to the arthrocentesis effect of the drug or because of the placebo effect. According to the analytical results, 10 mg of morphine had a longer effect on pain reduction followed by diclofenac.

Keywords: Morphine; Diclofenac sodium; Temporomandibular joint

Introduction

Approximately 80% of the population experience inappropriate forces on the temporomandibular joint (TMJ) such as bruxism and malocclusion. Out of them, 25% demonstrate symptoms such as joint sounds and more than 4 % of the patients require treatment (1-3).

Common treatments for TMJ disorders fall into two general categories: Surgical treatments and non-surgical treatments (4). The aim of non-surgical treatments is to reduce pain and inflammation, since sustained pain or inflammation may lead to severe central neuropathic and chronic pains (5).

Intra-articular injection of drugs has been used over the years to reduce pain; however, there are limitations and ambiguities on its effectiveness and duration of action (6). Drugs that are slowly injected in the joint directly affect the intra-capsular receptors to reduce pain (7). The most common injectable drugs include steroids and sodium hyaluronate (8). In addition, opioids are also

injected in the joint and the most desirable effect of opioids is their analgesic effect. The analgesic effect may occur in the spinal cord, brain, or through peripheral receptors (5).

The systemic use of opioids is associated with side effects such as decreased activity and gastrointestinal motility, respiratory depression, urinary retention, drowsiness, nausea and vomiting. Nonetheless, chronic use of opioids may lead to resistance to the medication and it could cause addiction. However, their local administration does not lead to such complications (4). Opioids analgesic effect may be due to the activation of pre-synaptic receptors in spinal cord or activation of post-synaptic receptors in brainstem and midbrain. The efficacy of intra-articular injection of solo morphine, local anesthesia, or a combination of opioids and local anesthetics for relieving postoperative pain has been demonstrated (9, 10).

According to the statistical results of a meta-analysis, intra-articular injection of 1-5 mg of morphine had more adequate analgesic effect than the placebo; nevertheless, the effect was not

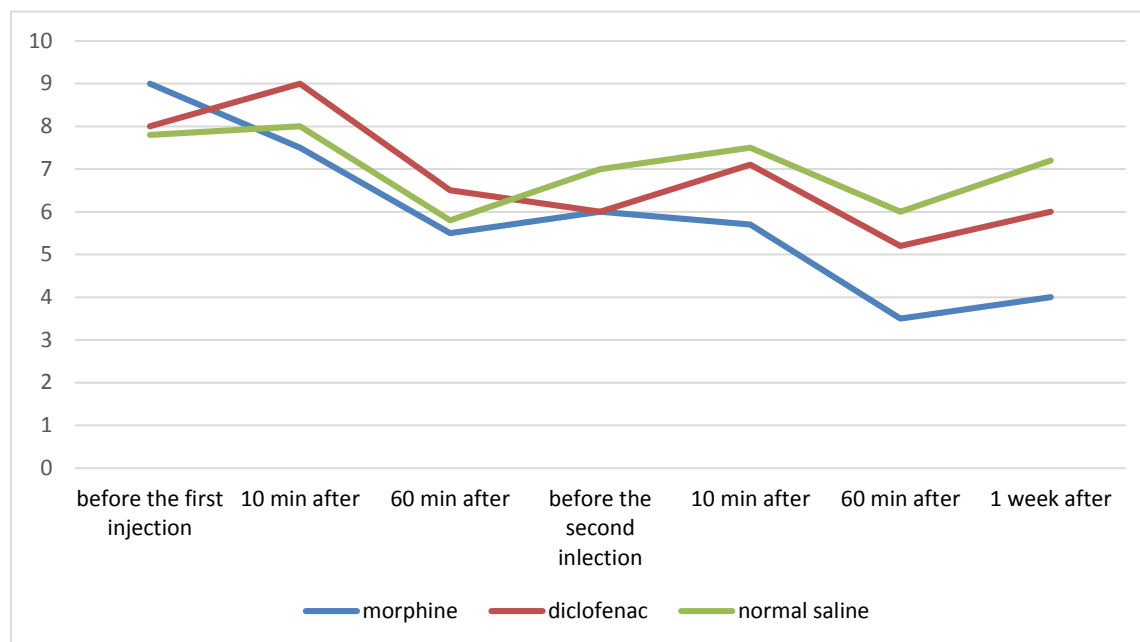


Figure 1. Pain distribution among patients according to VAS

significant enough (11). Rosseland *et al.*, found no significant difference between intra-articular injection of normal saline as a placebo and morphine as an analgesic medication (12). These conflicting findings could be due to differences in the intensity of pain following TMJ arthroscopy, pain assessment scale, systemic effects of opioids, or the entire mentioned factors (13).

Most studies on intra-articular injection have been conducted in orthopedic field on knee joint (9-11). There are few studies on TMJ and these limited studies have examined how to manage pain after TMJ surgery. The purpose of the present study is to compare the effects of intra-articular injection of 10 mg morphine, diclofenac sodium, and isotonic saline as the placebo in patients with chronic pain caused by TMJ disorders.

Materials and Methods

This double-blind clinical trial was conducted on patients with TMJ disorders referred to Imam Khomeini Hospital in Ahvaz from January 2015 to February 2016. The ethical committee at Ahvaz Jundi Shapour University approved this study. Patients with a history of TMJ pain on one side for at least three months with a minimum pain score of 6 based on the visual analog scale (VAS) (10) were enrolled; on the other hand, children, patients with drug dependency, or drug addiction, people with known intolerance to opioids, known nonsteroidal anti-inflammatory

drugs (NSAID) sensitivity, and patients with muscle disorders or symptoms of an acute inflammation and those with pathological lesions were excluded from the experiment. In total, 36 patients were included during the study. Informed consent was obtained from all 36 patients.

The samples were randomly divided into groups A, B, and C in which each group included 12 patients. Randomization was performed by using the site: www.randomization.com. Drugs used in groups A, B, and C were 10 mg/ml morphine sulfate (Daroupakhsh Co., Tehran, Iran), 25 mg/ml diclofenac sodium (Alborz Darou, Tehran, Iran), and isotonic saline as the placebo, respectively. Two ml of the drug was injected twice in the upper part of TMJ within 48 hours intervals.

The entire injections were performed by neural and maxillofacial surgeon. The operator and the patients were blinded regarding the syringe contents. Patients pain intensity were evaluated base on VAS prior to each injection and every 10, 60 min and a week after injection. The patients filled a questionnaire about the quality of sleep and chewing at the end of the study. The quality of sleep and chewing was assessed by Cochran Q test. Data analysis was performed by Statistical Package for Social Sciences (SPSS 20.0.1 for windows; SPSS Inc, Chicago, IL).

Data on patients pain was evaluated using repeated measures ANOVA, one-way ANOVA and Least Square Mean (LSD) test. $P \leq 0.05$ was considered as statistically significant.

Table 1. Quality of sleep, sleep disorder=0, lack of disorder=1.0

Time/Group	Prior to the first injection		Prior to the second injection		One week after the second injection	
	1	0	1	0	1	0
A	5	7	11	1	11	1
B	7	5	10	2	10	2
C	7	5	7	5	7	5

Table 2. Quality of eating, eating disorder=0, lack of disorder=1.0

Time/Group	Prior to the first injection		Prior to the second injection		One week after the second injection	
	0		1	0	0	1
A	11		1	7	3	9
B	12		0	7	9	3
C	9		3	9	9	3

Results

Among 36 participants, 21 were female and 15 were male. The patients were randomly divided into three groups. The distribution of the patients were as follow: 12 with bruxism, 8 with clenching, 10 with anterior teeth wear, 13 with malocclusion, and 21 with joint sounds.

Patients who received morphine showed significantly more pain reduction than the other two groups 60 minutes after the first injection ($P<0.05$). Furthermore, a week after the second injection, patients in which received morphine showed quite more reduction in pain than the other two groups ($P<0.001$). The pain in patients who received diclofenac and morphine was significantly reduced at the end of the study in which indicated the long-term effects of these drugs as compared to the normal saline solution. It must be noted that patients receiving morphine showed more pain reduction than those receiving diclofenac at the end of the study ($P<0.001$) (Figure 1).

Among the patients who received morphine, 2 patients reported mild pain (VAS less than 3), 9 patients reported moderate pain (VAS between 3 and 5), and 1 had severe pain (VAS greater than 6) following a week after the last injection. None of the patients in the group which received diclofenac reported mild pain, 6 patients reported moderate pain and 6 patients reported severe pain a week after the last injection. In the group which received saline solution, 1 patient reported mild pain and 11 patients reported severe pain.

According to one-way ANOVA, there was no difference between the groups in terms of pain reduction 48 h after the first injection. However, patients who received morphine showed more pain reduction than the other groups a week after the last injection ($P<0.05$).

The designed questionnaire was used to evaluate sleep and eating disorders with 5 questions regarding sleep, pain, and

eating in each section by using yes or no questions. The results were consistent with the analgesic results in different groups. According to Cochran test, the patients who received morphine ($P<0.01$) and diclofenac ($P<0.05$) experienced a significant improvement in quality of sleep, while those who received saline showed no change in sleep quality ($P=1$). A similar trend was found for eating disorders in different groups (Tables 1 and 2).

Discussion

Similar to arthrocentesis, in intra-articular injections, the pumping effect leads to dilated joint space and eliminates negative pressure inside the joint and increases maximum mouth opening (14). Both oral and injectable analgesics have absolute importance in the control of chronic pain (15). Injection of such drugs even with small doses can have a useful analgesic effect (6). According to literature reviews, it has been shown that few studies investigated the direct effect of intra-articular injection in TMJ following TMJ surgery in a 24 hour period.

According to the previous studies, TMJ pain may be relieved either by arthrocentesis or placebo effects regardless of types of injected medication (13).

As reported in the present study, morphine could be effective in pain control; in addition, 10 mg of morphine sulfate presented the sufficient long-term analgesic effect.

Based on the findings of this study and other similar reports, local administration of 10 mg morphine can be effective in managing inflammatory conditions. Moreover, due to the lack of specific symptoms following injection of morphine (15), intra-articular injection of morphine could be a safe treatment.

It is noteworthy that we used the same concentration of morphine used by Ziegler *et al.*, (15).



Conclusion

According to the results, it may be concluded that TMJ pain could be reduced regardless of the type of injected drug either as a result of the drug arthrocentesis effect, or due to the placebo effect; in addition, diclofenac sodium showed an analgesic effect to a lesser extent. The results showed that 10 mg morphine has tremendous effect on pain reduction in short follow- up times. Further studies are recommended to confirm its effectiveness in long- term pain control.

Conflict of Interest: 'None declared'.

References

- Gray R, Davies S, Quayle A. A clinical approach to temporomandibular disorders. 1. Classification and functional anatomy. *British dental journal*. 1994;176(11):429.
- Gray R, Davies S, Quayle A. A clinical approach to temporomandibular disorders. III: Examination of the articulatory system: The muscles. *British dental journal*. 1994;177(1):25-8.
- Zwijnenburg A, Lobbezoo F, Kroon G, Naeije M. Mandibular movements in response to electrical stimulation of superficial and deep parts of the human masseter muscle at different jaw positions. *Archives of oral biology*. 1999;44(5):395-401.
- Bessa-Nogueira RV, Vasconcelos BC, Niederman R. The methodological quality of systematic reviews comparing temporomandibular joint disorder surgical and non-surgical treatment. *BMC Oral Health*. 2008;8(1):1.
- Werneke M, Hart DL. Centralization phenomenon as a prognostic factor for chronic low back pain and disability. *Spine*. 2001;26(7):758-64.
- Khoury G, Garland D, Stein C. Intraarticular opioid-local anesthetic combinations for chronic joint pain. *Middle East journal of anaesthesiology*. 1994;12(6):579-85.
- Kunjur J, Anand R, Brennan P, Ilankovan V. An audit of 405 temporomandibular joint arthrocentesis with intra-articular morphine infusion. *British Journal of Oral and Maxillofacial Surgery*. 2003;41(1):29-31.
- Aktas I, Yalcin S, Sencer S. Intra-articular injection of tenoxicam following temporomandibular joint arthrocentesis: a pilot study. *International journal of oral and maxillofacial surgery*. 2010;39(5):440-5.
- Stein C, Comisel K, Haimerl E, Yassouridis A, Lehrberger K, Herz A, et al. Analgesic effect of intraarticular morphine after arthroscopic knee surgery. *New England Journal of Medicine*. 1991;325(16):1123-6.
- Joshi G, McCarroll S, Cooney C, Blunnie W, O'Brien T, Lawrence A. Intra-articular morphine for pain relief after knee arthroscopy. *Journal of Bone & Joint Surgery, British Volume*. 1992;74(5):749-51.
- Gupta A, Bodin L, Holmström B, Berggren L. A systematic review of the peripheral analgesic effects of intraarticular morphine. *Anesthesia & Analgesia*. 2001;93(3):761-70.
- Bryant C, Harrison S, Hopper C, Harris M. Use of intra-articular morphine for postoperative analgesia following TMJ arthroscopy. *British Journal of Oral and Maxillofacial Surgery*. 1999;37(5):391-6.
- Zuniga JR, Ibanez C, Kozacko M. The analgesic efficacy and safety of intra-articular morphine and mepivacaine following temporomandibular joint arthroplasty. *Journal of oral and maxillofacial surgery*. 2007;65(8):1477-85.
- Ziegler C, Steveling H, Umstadt H, Mühling J. Arthroskopische lysis und lavage des Kiefergelenks zur Therapie von Diskusverlagerungen. *Arthroskopie*. 1999;12(6):318-22.
- Ziegler CM, Wiechnik J, Mühling J. Analgesic effects of intra-articular morphine in patients with temporomandibular joint disorders: a prospective, double-blind, placebo-controlled clinical trial. *Journal of oral and maxillofacial surgery*. 2010;68(3):622-7.

Please cite this paper as: Raeesian SH, Fallahi HR, Masoudrad M. Comparison of Morphine and Diclofenac Intra-articular Injection in Temporomandibular Joint Disorders: A Randomized Controlled Clinical Trial. *Regen Reconstr Restor*. 2016;1(3):149-152.