

Reliability of the Thickness Measurement and Histogram of Elbow Flexors by Ultrasonography in Patients with Fascioscapulohumeral Dystrophy and Healthy Subjects

Shideh Badeleh^a, Asghar Rezasoltani^{b*}, Alireza Akbarzadeh Baghban^c, Mehdi Vahid Dastjerdi^d, Omid Aryani^e, Behzad Lahouti^f

^a Physiotherapy Research Centre, School of Rehabilitation, Shahid Beheshti University of Medical Sciences, Tehran, Iran; ^b Physiotherapy Research Centre, School of Rehabilitation, Shahid Beheshti University of Medical Sciences, Tehran, Iran; ^c Physiotherapy Research Centre, School of Rehabilitation, Shahid Beheshti University of Medical Sciences, Tehran, Iran; ^d Bo-Ali Hospital, Tehran Medical Sciences Branch, Islamic Azad University, Tehran, Iran; ^e Department of Neuroscience, Iran University of Medical Science, Tehran, Iran; ^f Physiotherapy Research Centre, School of Rehabilitation, Shahid Beheshti University of Medical Sciences, Tehran, Iran

*Corresponding Author: Asghar Rezasoltani, Physiotherapy Research Centre, School of Rehabilitation, Shahid Beheshti University of Medical Sciences, Damavand Ave., across from Bo-Ali Hospital, Tehran, Iran. Tel: +98-21 77569900; E-mail: a_rezasoltani@sbmu.ac.ir

Submitted: 2016-09-25; Accepted: 2017-01-24

Abstract

Introduction: Ultrasonography is a non-invasive and available technique used to assess normal and pathological tissue in people with neuromuscular diseases. The aim of this study was to determine relative and absolute reliability of ultrasonography in evaluation of thickness and histogram of elbow flexor muscles in patients with facioscapulohumeral muscular dystrophy (FSHD) and healthy subjects. **Materials and Methods:** The present study was carried out on an experimental group of six patients with FSHD and a control group comprising 6 healthy individuals. The thickness and histogram of elbow flexors were evaluated while subjects were in sitting position with knees bent, arms at 90 degrees abduction, elbows at 90 degrees flexion and forearms in neutral position. The probe was placed on the anterior surface of arm at 2/3 distance between the lateral tip of acromion and the lateral epicondyle of the humerus. Standard deviation of echogenicity based on histogram curve was also used to estimate the echogenic uniformity of muscle tissue (STDE), subsequently two parameters including L-mean and STDE were recorded. The intra-class correlation coefficient (ICC), standard error measurement (SEM) and minimal detectable changes (MDC) tests were applied to measure relative and absolute reliability and to estimate the measurement errors. **Results:** The values of the reliability of muscle thickness measurement were ICC=0.95, SEM=2.14 and MDC=5.94 and ICC=0.95, SEM=1.34 and MDC=3.72 in the experimental group and the control group respectively. Additionally, for L-mean measurements it appeared to be ICC=0.89, SEM=1.75 and MDC=4.86 among patients and ICC=0.66, SEM=1.04 and MDC=2.89 in healthy subjects. Finally, the reliability of STDE measurement was revealed to be ICC=0.98, SEM=0.18 and MDC=0.51 and (ICC=0.75, SEM=0.63 and MDC=1.74) among the participants of the experimental and the control groups. **Conclusion:** The results of this study showed that ultrasonography method used in this study had a high level of accuracy to measure the thickness and histogram of elbow flexors in both healthy subjects and patients with FSHD. The method can be recommended to compare or determine the effectiveness of different treatment methods in patients with FSHD.

Key words: Elbow Flexors, Fascioscapulohumeral Dystrophy Histogram, Reliability; Thickness, Ultrasonography

Please cite this paper as: Badeleh SH, Rezasoltani A, Akbarzadeh Baghban A, Vahid Dastjerdi M, Aryani O, Lahouti B. Reliability of the Thickness Measurement and Histogram of Elbow Flexors by Ultrasonography in Patients with Fascioscapulohumeral Dystrophy and Healthy Subjects. J Clin Physio Res. 2017; 2(2): 75-79.

Introduction

Fascioscapulohumeral muscular dystrophy (FSHD) refers to a slow progress of autosomal dominant myopathy. It often starts with asymmetric weakness of the facial and shoulder girdle muscles and extends to the pelvic girdle and lower extremities

and causes disability and limitation of movement (1-3). It has an incidence of 1 per 21,000 to 1 per 15,000 people.¹ In many neuromuscular diseases, a non-invasive and painless technique is needed to monitor the disease and therapeutic effects.

CT-Scan, MRI and ultrasonography are known as the most common imaging methods in neuromuscular diseases due to

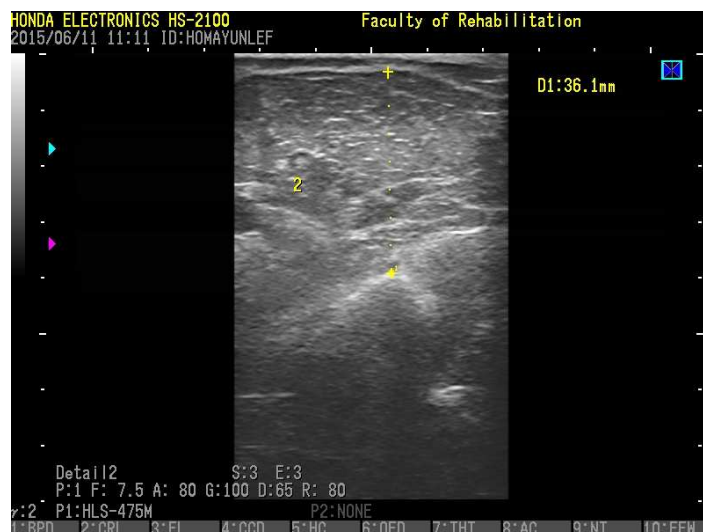

Figure 1. Transverse image, measurement of the thickness of elbow flexors. The distance between humerus and superficial fascia of biceps brachii

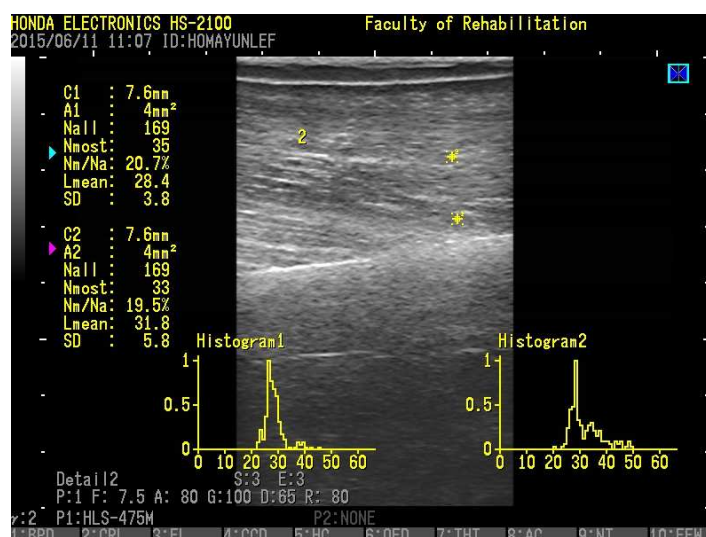


Figure 2. Longitudinal image, Measurement of the echo intensity of elbow flexors. The mean of echo intensity between the space of biceps brachii angle with humerus and the surface of superficial fascia of muscle.

some advantages they serve (4). The main advantages of ultrasound compared to MRI and CT-Scan include the non-ionizing radiation, low cost and availability (5), so that in recent years, it has been of considerable interest to researchers for evaluation of normal and pathological tissue in neuromuscular diseases (6). In myopathies, such as muscular dystrophies, muscle tissue is replaced by adipose and fibrotic tissues. Using qualitative and quantitative ultrasound measurements, adipose and fibrotic tissues are seen as increased echo intensity (EI) in muscle, and in fact the pathologic muscle is seen whiter than

normal muscle (4). In previous studies, qualitative measurement has been performed by Heckmatt visual criteria, but recently EI measurement is quantitatively analyzed by computer that has a greater inter-observer consistency. Jansen *et al.* in 2012 and also Janssen *et al.* in 2014 measured the echo intensity by histogram analysis in patients with neuromuscular diseases. (4, 5). In neuromuscular diseases, muscle thickness (MT) can be normal, reduced or increased. Studies have shown that quantitative analysis of MT and EI by ultrasound is a sensitive method for evaluating patients with neuromuscular diseases (7-9).

In patients with FSHD, involvement of upper extremity is more likely than the lower extremities; therefore, assessment of upper limb muscles which are typically involved is preferred to lower limbs (10).

To assess the morphological changes in muscle tissue in patients suffering from FSHD, a reliable method is required. So far, no study has been conducted to evaluate the reliability of ultrasonography method for these patients. The aim of this study was to investigate the reliability of this technique to measure histogram and thickness of elbow flexors by in patients with FSHD.

Materials and Methods

The current methodological study aimed at evaluating the reliability of ultrasonography to measure the elbow flexors' thickness and histogram both in FSHD patients and healthy individuals. This study was conducted on 6 patients with FSHD and (6) healthy subjects, both of whom volunteered to participate in the study.

Eligible participants were categorized into two equal groups of experimental and control group. The experimental group includes patients with FSHD diagnosed by a neurologist.

On the other hand, people who were reported to have neither motor weakness symptoms nor the history of peripheral or central nervous system injuries were placed in the control group

People in both groups were similar in terms of age, gender, and body mass index (BMI). Sampling was performed through non-random convenient method.

Checklist of personal and demographic information was completed and informed consent was obtained from all participants before the study began.

The process of Imaging was performed by Hunda Ultrasound device (Model No. 2100, Honda co; Japan) with 5-cm linear probe operating on the frequency of 7.5MHz.

While forearm was kept in neutral position, Ultrasonography of the elbow flexors was applied in sitting position, knee bent arm in 90° abduction and elbow in 90° flexion while supported by the handles attached to the seat. During this stage, the probe was placed on the anterior surface of arm at a 2/3 proximal distance between the lateral tip of acromion and the lateral epicondyle of humerus (11). Then, longitudinal and transverse planes were imaged at rest. Eventually, the related measurements were made by one tester twice on the same day with an interval of 1 hour.

Next, the distance between humerus and superficial fascia of biceps brachii was measured in the transverse image to measure the thickness of elbow flexors (including biceps brachii and brachialis muscles) (Figure 1). Imaging was repeated 3 times for each subject and the means of the results gained were used for data analysis.

The measurement of muscle's echo intensity by histogram consisted of the following steps. In the longitudinal image, the space between biceps brachii angle with humerus and the surface of superficial fascia of muscle was divided into three equal parts to locate three 4*4 mm² regions of interests. Then, three consecutive images of every participant were taken, subsequently, the mean of echo intensity of the three selected points in three images were calculated according to histogram analysis of ultrasound device (Figure 2) (5). By using histogram, the mean of dark and light spots can be presented in the form of L-mean that is in fact echogenicity of the selected areas. We also used standard deviation of echogenicity based on histogram curve to estimate the echogenicity uniformity of muscle tissue (STDE). So by using the histogram curve, two parameters including L-mean and STDE were recorded.

At the next stage, to examine the reliability of data, intra-class correlation coefficient (ICC), standard error of measurement (SEM), and minimal detectable change (MDC) were computed by using SPSS software program for windows (version 16) with 95% confidence intervals. In the following step, the analysis of the data was performed at the significance level of 0.05, and to express the ICC degree, Ronser category was used (12):

Less than 40% as poor reliability

Between 40-75% as moderate to good reliability

More than 75% as excellent reliability

Results

The mean age and BMI of the experimental group consisting patients with FSHD were 34.83±10.77 and 22.74±3.53; these values for subjects of the control group were 29.83±10.4 and 23.09±3.61 respectively (Table 1).

Indices measuring the thickness and histogram of elbow flexors in two ultrasonography tests performed by one tester are demonstrated in table 2. The results of the reliability are shown in table 3. As the results indicate, the reliability of each variable in both groups was at a high level ($0.75 \leq \text{ICC} \leq 0.98$), with the exception of L-mean measurement in healthy individuals that ranged from fair to good ($\text{ICC}=0.66$).

Table 1: The mean, SD, and range of the demographic variables in groups of FSHD and healthy subjects (n=12)

Group parameter	patients			healthy		
	Mean±SD	N	Range	Mean±SD	N	Range
Age(year)	34.83±10.77	6	24-55	29.83± 10.4	6	20-50
Height(Cm)	174±9.59	6	161-184	172.5± 11.89	6	156-184
Weight(Kg)	68.66±11.77	6	60-90	69± 15.34	6	55-90
BMI (Kg/M ²)	22.74±3.53	6	18.51-26.41	23.09± 3.61	6	18.51-26.62

Table 2. Thickness and histogram of elbow flexors in groups of FSHD and healthy subjects in two measurements

Group parameter	patient		healthy	
	Mean±SD	N	Mean±SD	N
MT1(mm)	16.94±9.59	6	24.21±6.01	6
MT2(mm)	16.58±9.52	6	24.71±6.1	6
L-mean1	32.77±5.29	6	25.9±1.79	6
L-mean2	33.56±5.1	6	26.73±3.2	6
STDE1	3.84±1.31	6	5.16±1.26	6
STDE2	3.57±1.24	6	5.48±1.42	6

MT1: Muscle Thickness measurement of the first time; MT2: Muscle Thickness measurement of the second time; L-mean1: L-mean measurement of the first time; L-mean2: L-mean measurement of the second time; STDE1: Standard Deviation of the histogram in the first time; STDE2: Standard Deviation of the histogram in the second time

Table 3. Reliability of parameters in groups of FSHD and healthy subjects

Variable		ICC	95% Confidence Interval		SEM	MDC
			Lower Band	Upper Band		
MT	Patient	0.95	0.70	0.99	2.14	5.94
	Healthy	0.95	0.70	0.99	1.34	3.72
L-mean	Patient	0.89	0.43	0.95	1.75	4.86
	Healthy	0.66	0.18	0.94	1.04	2.89
STDE	Patient	0.98	0.90	0.99	0.18	0.51
	Healthy	0.75	0.00	0.96	0.63	1.74

MT: Muscle Thickness; L-mean: L-mean measurement; STDE: Standard Deviation of the histogram

Discussion

In this study, in order to investigate the reliability and measurement error, ICC test was used to evaluate the relative reliability, and SEM and MDC of the tests were used to assess the absolute reliability (ambiguous). This study was conducted for the purpose of assessing the reliability and measurement error of ultrasonography in evaluation of thickness and histogram of elbow flexor muscles. Bearing this purpose in mind, the researchers used ICC test to evaluate the relative reliability by which SEM and MDC were accounted to assess the absolute reliability. The SEM and MDC values determine the accuracy of measurements and represent if the data obtained by the measurements of the same examiner contain

any errors. Having the clear values of the SEM and MDC measured, in the follow up studies, the researchers are inclined to detect the amount of changes resulting from the treatment intervention and the amount of measurement errors.

The higher ICC and the lower MDC and SEM improve the reliability (ambiguous). The SEM for each of three parameters of MT, L-mean and STDE was reported to be very similar in both groups indicating that ultrasonography allows the precise investigation of these parameters. In this study, ICC for these parameters was moderate to high ($0.66 \leq \text{ICC} \leq 0.95$) in healthy subjects and high ($0.89 \leq \text{ICC} \leq 0.98$) in patients.

Formerly, Jenkins *et al.* examined the reliability of ultrasound imaging for assessing biceps brachii thickness and echo intensity in healthy subjects. They reported the ICC for

biceps brachii thickness as 0.97. Besides, ICC for biceps brachii echo intensity was 0.82 (13). Based on their findings, they suggested that US imaging is a reliable technique for quantifying MT and EI of the biceps brachii.

Also Chen *et al.* and Radaelli *et al.* reported the ICC for elbow flexors echo intensity measured by ultrasonography as 0.92 and 0.91 in healthy subjects (14, 15). It could be concluded that the findings of this study are compatible with the previous studies with regard to the acceptable repeatability in measuring the thickness and the echo intensity of elbow flexors in healthy groups.

No studies have yet evaluated the reliability of ultrasonography in measuring the histogram and thickness of muscles in patients with FSHD. So, comparison of the results of this study with other studies was not completely possible. Based on the above mentioned results, it can be estimated that the ultrasound imaging technique is a valid and a reliable method for measuring thickness and histogram of elbow flexor muscle both in healthy individuals and patients diagnosed with FSHD.

Due to the severe morphological changes in the muscles of these patients, a uniform landmark for the location of ultrasound probe is essential in patients and healthy people. In the current study, histogram evaluation for elbow flexors has been performed in location of Biceps Brachii muscle angle as a uniform landmark.

Conclusion

According to the results of this study, ultrasonography method could be considered as an appropriate method to evaluate the morphology of muscles in patients with FSHD. Furthermore, we might suggest this method as a suitable one in order to compare or to determine the effectiveness of different treatment methods.

Acknowledgments:

None

Conflict of interest:

None

Funding support:

This project had no external funding, and no financial or other relationships pose a conflict of interest

Authors' contributions:

All authors made substantial contributions to conception, design, acquisition, analysis and interpretation of data.

References

1. Pandya S, King WM, Tawil R. Facioscapulohumeral dystrophy. *Physical therapy*. 2008;88(1):105.
2. Statland JM, McDermott MP, Heatwole C, Martens WB, Pandya S, van der Kooi E, *et al.* Reevaluating measures of disease progression in facioscapulohumeral muscular dystrophy. *Neuromuscular Disorders*. 2013;23(4):306-12.
3. Stübgen J-P, Stipp A. Facioscapulohumeral muscular dystrophy: a prospective study of weakness and functional impairment. *Journal of neurology*. 2010;257(9):1457-64.
4. Janssen BH, Pillen S, Voet N, Heerschap A, Engelen BG, Alfen N. Quantitative muscle ultrasound versus quantitative magnetic resonance imaging in facioscapulohumeral dystrophy. *Muscle & nerve*. 2014;50(6):968-75.
5. Jansen M, van Alfen N, van der Sanden MWN, van Dijk JP, Pillen S, de Groot IJ. Quantitative muscle ultrasound is a promising longitudinal follow-up tool in Duchenne muscular dystrophy. *Neuromuscular Disorders*. 2012;22(4):306-17.
6. Pillen S, Arts IM, Zwarts MJ. Muscle ultrasound in neuromuscular disorders. *Muscle & nerve*. 2008;37(6):679-93.
7. Tieleman A, Vinke A, van Alfen N, van Dijk J, Pillen S, van Engelen B. Skeletal muscle involvement in myotonic dystrophy type 2. A comparative muscle ultrasound study. *Neuromuscular Disorders*. 2012;22(6):492-9.
8. Pillen S, Scholten R, Zwarts M, Verrips A. Quantitative skeletal muscle ultrasonography in children with suspected neuromuscular disease. *Muscle & nerve*. 2003;27(6):699-705.
9. Pillen S, Verrips A, Van Alfen N, Arts I, Sie L, Zwarts M. Quantitative skeletal muscle ultrasound: diagnostic value in childhood neuromuscular disease. *Neuromuscular Disorders*. 2007;17(7):509-16.
10. Tawil R, Van Der Maarel SM. Facioscapulohumeral muscular dystrophy. *Muscle & nerve*. 2006;34(1):1-15.
11. Zaidman CM, Connolly AM, Malkus EC, Florence JM, Pestronk A. Quantitative ultrasound using backscatter analysis in Duchenne and Becker muscular dystrophy. *Neuromuscular Disorders*. 2010;20(12):805-9.
12. Rosner B. *Fundamental of Biostatistics* sE, Belmont: Duxbury Press. 2006; p: 223.
13. Jenkins ND, Miller JM, Buckner SL, Cochrane KC, Bergstrom HC, Hill EC, *et al.* Test-retest reliability of single transverse versus panoramic ultrasound imaging for muscle size and echo intensity of the biceps brachii. *Ultrasound in medicine & biology*. 2015;41(6):1584-91.
14. Chen H-L, Nosaka K, Chen TC. Muscle damage protection by low-intensity eccentric contractions remains for 2 weeks but not 3 weeks. *European journal of applied physiology*. 2012;112(2):555-65.
15. Radaelli R, Bottaro M, Wilhelm EN, Wagner DR, Pinto RS. Time course of strength and echo intensity recovery after resistance exercise in women. *The Journal of Strength & Conditioning Research*. 2012;26(9):2577-84.