Int Clin Neurosci J. 2026;13:e53639 Original Article

doi: 10.22037/icnj.v13iContinuous.53639

Posterior C1-C2 Fusion Using the Harms Technique for Atlanto-Axial Dislocation: A Single-Centre Case Series

Shahan Ara Parveen[1], Monzurul Haque[2], Lylatul Kadir[1], Rafiqul Islam[1], Shamsul Huda[1]

[1]Department of Neurosurgery, Rajshahi Medical College Hospital, Rajshahi, Bangladesh.

[2]Head of Department, Neurosurgery, Rajshahi Medical College Hospital, Rajshahi, Bangladesh.

Abstract

Background: Atlanta-axial dislocation is a serious disorder involving abnormal movement between C1 and C2, which may result from trauma, congenital conditions, inflammation, or tumors. Because this junction is closely related to the spinal cord and vertebral arteries, instability can lead to severe neurological complications. This study presents institutional experience with posterior C1–C2 fusion using the Harms technique, focusing on the surgical approach, neurological recovery, and complications.

Methods: This retrospective observational study included patients of all ages with atlanto-axial dislocation who underwent the Harms technique at a tertiary hospital in Bangladesh between 2023 and 2025. Data were collected using a standardized form, and neurological status was assessed before surgery and at one year in surviving patients using mJOA severity categories. Postoperative evaluation relied on plain radiographs. Descriptive and exploratory analyses were performed in SPSS, including the Wilcoxon signed-rank test to compare pre- and postoperative mJOA categories and Fisher's exact test to assess the association between etiology and outcome. Statistical significance was set at $p < 0.05$.

Results: Eleven patients underwent posterior C1-C2 fixation using the Harms technique; 8 (72.7%) were male. The most frequent age groups were 21-40 years and above 60 years, 4 (36.4%) each. AAD was traumatic in 10 (90.9%). Complications occurred in 4 (36.4%): three deaths (27.3%) and one CSF leak (9.1%). A good outcome was achieved in 8 (72.7%) patients; all three poor outcomes were deaths, all in patients over 60 years. All 8 survivors improved by at least one mJOA severity category at one year (Wilcoxon p=0.007); the three patients who died had no postoperative score. Fusion could not be assessed because postoperative CT was not performed.

Conclusion: In this small exploratory series, Harms C1-C2 fixation was followed by neurological improvement in survivors, but mortality was high (27.3%), and fusion was not confirmed radiologically. The findings do not establish efficacy or safety; larger prospective studies with CT-based fusion assessment are needed.

Keywords: Atlanto-axial Dislocation; Harms Technique; C1-C2 Fusion; Posterior Stabilization; Craniovertebral Junction; Surgical Outcomes; Spinal Fusion.

Received: October 1, 2026, **Accepted:** November 14, 2026, **Published online:** November 18, 2026

Citation: Parveen SA, Haque M, Kadir L, Islam R, Huda S. Posterior C1-C2 Fusion Using the Harms Technique for Atlanto-Axial Dislocation: A Single-Centre Case Series. Int Clin Neurosci J. 2026;13:e53639.

Introduction

Atlanto-axial dislocation (AAD) represents a pathological displacement at the C1-C2 articulation that destabilizes the craniovertebral junction, rendering the cervico-medullary cord and vertebral vasculature susceptible to compressive insult and culminating in a clinical spectrum spanning progressive myelopathy to abrupt neurological catastrophe. The clinical presentation typically includes neck pain, reduced range of motion, and torticollis (i.e., "cock-robin" position)[1]. The pathologies of AAD can generally be divided into traumatic, congenital, inflammatory, degenerative, and tumor factors[2]. Considering the etiology for patients with AAD is important when selecting imaging approaches. Imaging evaluation should include not only the direction of dislocation and etiology but also associated skeletal anomalies, such as os odontoideum (OO), C2-3 fusion, Arnold-Chiari malformation, and so on[3]. The presentation of atlantoaxial dislocation may range from minor axial neck pain to death. Approximately 50% of patients present with neck pain and/or neck movement restriction,70% with weakness and/or numbness, and 90% with pyramidal signs[4]. Conventional X-ray (radiographs), computed tomography (CT), and magnetic resonance imaging (MRI) of the cervical spine are common imaging approaches to diagnose AAD[2]. Nonoperative treatment for atlantoaxial dislocation consists of cervical halter traction in the supine position and

*Correspondence to: Shahan Ara Parveen, Email: shahan.52rmc@gmail.com

© 2026 The Author(s). This is an open access article distributed under the terms of the Creative Commons Attribution License (http://creativecommons.org/licenses/by/4.0/), which permits unrestricted use, distribution, and reproduction in any medium, provided the original work is properly cited.

active range-of-motion exercises for 24 to 48 hours first, followed by ambulatory orthotic immobilization with active range-of-motion exercises until free motion returns[5]. Since the beginning of the 20th century, various atlantoaxial posterior fusion techniques have been developed, ranging from sublaminar wiring, hooks, claws, to the screw-rod construct widely used today. Reducible AAD requires posterior fusion alone, whereas an irreducible AAD requires anterior transoral decompression plus posterior fusion[6-8]. The most common posterior surgical methods include C1–C2 trans-articular screw fixation, C1 lateral mass screw–to–C2 pedicle screw fixation, and C1 lateral mass screw–to–C2 laminar screw fixation[9]. The Magerl technique, or C1–C2 trans-articular screw fixation with posterior wiring, was first described in 1986 and became popular for cervical fixations, including treatment of atlantoaxial dislocation, because of its superior biomechanical strength and high fusion rates compared with posterior wiring,12 with fusion rates as high as 100% reported[10-12]. In 1994, Goel and Laheri described a new posterior fixation technique using a C1 lateral mass-C2 pars screws construct connected by posterior cervical plates, which provided rigid posterior fixation and a reported 100% fusion rate in an early study of 30 patients, and subsequently a larger study of 160 cases with atlantoaxial instability during the 14-year follow-up period[13-14]. In 2001, Harms and Melcher reported a modification of the Goel technique using C1 lateral mass screws and C2 pedicle screws connected by rods, with a 100% fusion rate in their series[15]. Since then, the Harms technique has been widely adopted. Advances in technology and surgical techniques have improved the safety profile, increased fusion rates, and improved clinical outcomes.

Despite its global use, outcome data on the Harms technique remain limited from resource-constrained tertiary centers in South Asia, where AAD presentations are frequently delayed, severe, and etiologically diverse. Most published outcome data originate from Western and East Asian institutions, leaving a gap in evidence for these populations. This case series addresses that gap by reporting outcomes, complications, and neurological recovery from a single Bangladeshi neurosurgical center.

Anatomical Basis of AAD

The atlas is the first cervical vertebra, which supports the globe of the head[16]. Its dimensions and relationship to the vertebral artery groove are surgically important[17]. It looks like a ring and comprises the anterior and posterior arches and lateral masses on both sides. The vertebral artery passes through a groove on the surface of the posterior arch, pierces the dura mater, and then proceeds cranially through the foramen magnum[18]. The axis vertebra has unique features, including a modified body (odontoid process or dens) and a roomy vertebral canal; it also has unique superior articulating facets[19]. The apical, alar, and cruciate ligaments constrain movement at the atlanto-axial articulation. Other ligaments supporting the cervical spine include the anterior and posterior longitudinal ligaments and the posterior ligament complex[20, 21]. The C1–C2 complex allows 50% of all spinal rotation, 10% of flexion-extension, and 50 degrees of axial rotation. Therefore, fusing these segments would undoubtedly cause this motion to be permanently lost[22]. The CVJ is an anatomical transition zone between the skull and the cervical spine. The atlas and axis vertebrae within the CVJ have anatomical properties that differ from other cervical vertebrae[23]. Atlantoaxial and craniovertebral instability present unique challenges in spinal surgeries[24] (Figure 1).

Classification of AAD

AAD classifications are useful for determining treatment strategies for different conditions based on clinical and radiographic parameters, since opinions on the indications for different treatment methods vary. In recent years, clinical classifications of AAD, which can help spine surgeons choose treatment strategies, have also been developed[9]

According to cause

There are traumatic, congenital, and pathologic causes for AAD. Traumatic AAD is most common, often arising from odontoid fracture and transverse ligament rupture. The mortality of trauma-related AAD is reportedly 60%–80%; serious injuries in this region can lead to paralysis and death[9, 27]. Another common type of AAD is associated with congenital deformity at the occipital-cervical junction, such as dens malformation, assimilation of the atlas, Klippel–Feil syndrome, and basilar invagination[18]. Os odontoideum (OO) is a rare cervical anomaly in which there is a lack of bony connection between the axis and the odontoid process, which can lead to AAD and may require surgical treatment to stabilize the upper cervical spine, relieve spinal cord

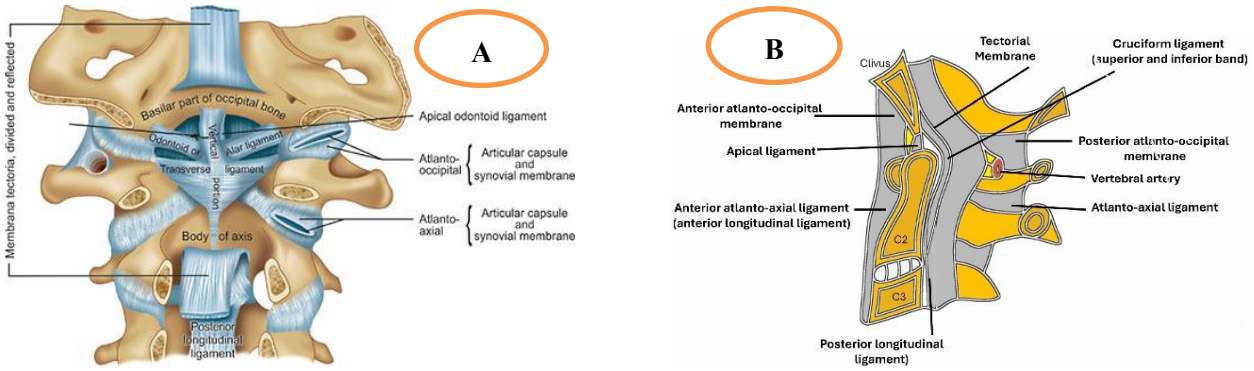

Figure 1. Anatomy of the atlas, axis, and related ligaments. **(A)** Beginning and end points of cruciate and alar ligaments[25] **(B)** Sagittal view showing the connection between atlantoaxial-related ligaments and the spinal cord[26].

compression, and prevent future neurological injury[28, 29]. The pathologic type of AAD is the least common, including rheumatoid arthritis, tuberculosis, infection, or tumors of the atlas or axis[18].

According to Direction of Dislocation

Possible directions of dislocation are anterior, posterior, and rotational. Anterior dislocation is most common, often resulting from rupture of the transverse ligament or deformity of the dens. Posterior AAD is relatively uncommon and often associated with odontoid fracture. Rotational AAD is relatively rare and can be easily diagnosed on CT.

According to Time since Dislocation

There are fresh and old types of AAD, depending on the interval between dislocation and diagnosis. The fresh type is used when a definite diagnosis is made within 3 weeks of the dislocation, and the old type when it is over 3 weeks[18].

According to Reducibility of Dislocation

There are reducible, irreducible, and non-reducible types of AAD.

The Harms technique

It's a modified version of the Goel technique that uses C1 lateral mass screws and C2 pedicle screws. The Harms technique for C1–2 fusion begins by retracting the C2 nerve root to expose the C1 lateral mass, where a 3.5 mm polyaxial screw is inserted at a specific entry point for bicortical purchase. A second screw is placed into the C2 pedicle at the cranial and medial quadrant, directed 20–30° medially and cranially. Both screws are then connected by a rod to form a stable screw-rod construct. Bone graft harvested from the iliac crest or allograft is placed over the decorticated C1–C2 lamina to achieve arthrodesis. Compared with other fixation techniques like Goel and trans-articular screws, the Harms technique works even when posterior elements are compromised, better preserves the C2 ganglion, allows reduction of the C1–2 region, and carries fewer complications overall (30–33). The bilateral C1 lateral mass and C2 pedicle screw construct is widely regarded as the gold standard for maximum C1–2 stability, making the Harms technique increasingly popular among spine surgeons globally (34). A review article showed that C2 pedicle screw and the C2 pars screw are both broadly used for C1–2 fusion. It demonstrated a slightly higher rate of successful fusion in patients treated with bilateral pedicle screw fixation compared with those with pedicle and pars hybrid or bilateral pars screw constructs (99.8% vs. 95.6%)[35] (Figure 2).

Materials and Methods

Data Acquisition

A three-year (2023 to 2025) retrospective observational study was conducted in the Department of Neurosurgery at Rajshahi Medical College Hospital, Bangladesh.

Sampling

Sampling was done through purposive sampling. A total of 11 patients were operated on for AAD.

Inclusion and Exclusion Criteria

Patients of all age groups were included in the study regardless of etiology. Patients with a previous history of AAD surgery were excluded.

Data collection and Variables

Demographics, clinical presentations, and imaging findings were recorded on a standardized pro forma. Preoperative imaging consisted of CT scan of the craniovertebral junction (CVJ) and MRI of the cervical spine, whereas postoperative evaluation was performed using plain X-ray of the cervical spine only; postoperative CT was not performed. Neurological status was assessed preoperatively in all patients and at one year postoperatively in all surviving patients using the modified Japanese Orthopaedic Association (mJOA) score, grouped into normal (18), mild (15–17), moderate (12–14), and severe (0–11) categories. Postoperative scores were not available for the three patients who died. Variables included age group, gender, etiology of AAD, pre-operative and post-operative mJOA category, revision operation, post-operative complications, and outcome.

Statistical analysis

Data were analyzed using SPSS version 30. Categorical variables are presented as counts and percentages. Outcome was categorized as good or poor based on clinical improvement and complications. Because of the very small sample, expected cell frequencies were below 5, and Fisher's exact test was used to compare etiology with

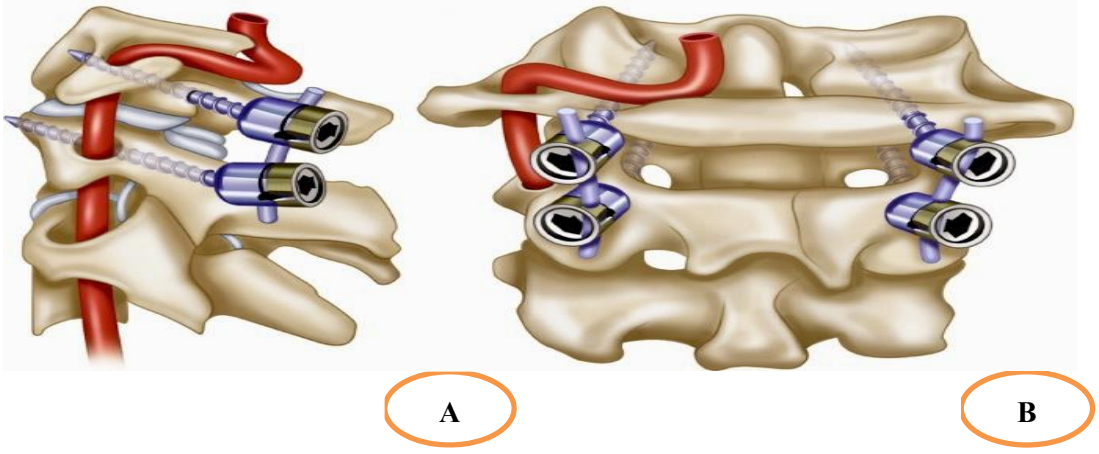

Figure 2. Illustration of the Harms technique: C1 lateral mass screw— C2 pedicle screw fixation with rods. **(A)** Sagittal and **(B)** coronal planes[36].

outcome. Pre- and post-operative mJOA severity categories were compared in surviving patients using the Wilcoxon signed-rank test (paired ordinal data); the three patients who died had no post-operative score and were excluded from this comparison. Two-sided $p<0.05$ was considered statistically significant. All analyses were exploratory, and no adjustment for multiplicity was made.

Postoperative management and Follow-up

Postoperatively, all patients were monitored for neurological status, wound condition, and signs of implant-related complications. Plain X-ray of the cervical spine was obtained to evaluate screw placement and construct alignment. CT was not performed postoperatively; therefore, bony fusion was not assessed. The sutures were removed on the 10th day after surgery. Surviving patients were followed up for 1 year to evaluate outcomes and complications.

Results

A total of 11 patients underwent posterior C1-C2 fixation using the Harms technique; 8 (72.7%) were male, and 3 (27.3%) were female (Figure 3). Patients were categorized into four age groups: 1–20 years, 1 (9.1%); 21–40 years, 4 (36.4%); 41–60 years, 2 (18.2%); and more than 60 years, 4 (36.4%). Ten patients (90.9%) had AAD of traumatic etiology and one (9.1%) of congenital etiology. Post-operative complications occurred in 4 of 11 patients (36.4%): death in 3 (27.3%) and CSF leak in 1 (9.1%). Outcomes were classified as good or poor based on clinical improvement and complications. A good outcome was achieved in 8 patients (72.7%) and a poor outcome in 3 (27.3%); all three poor outcomes were deaths, giving an overall mortality of 27.3%. None of the patients required revision surgery.

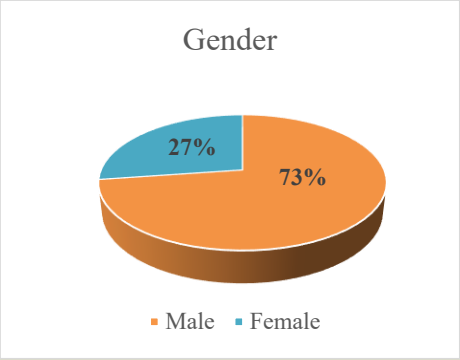

Figure 3. Gender distribution of the study participants (n=11).

Three of the 11 patients (27.3%) died. All three had traumatic AAD and were older than 60 years (3 of the 4 patients in that age group); two were men and one was a woman, and their pre-operative mJOA categories were normal, moderate, and severe (one patient each). The cause and timing of each death and its relationship to the procedure are given in Table 1.

Of the 10 patients with traumatic AAD, 7 had a good outcome and 3 a poor outcome; the single patient with congenital AAD had a good outcome (Figure 4). Because of the very small numbers, the study had no power to detect an association between etiology and outcome (Fisher's exact test, $p = 1.000$).

Neurological status at one year was available for the 8 surviving patients; the 3 patients who died had no post-operative mJOA score and were excluded from the neurological comparison (Table 2). Before surgery, these 8 patients were in the moderate (n = 5) or severe (n = 3) mJOA category. At one year, 1 patient was in the normal category, 4 in the mild category, 3 in the moderate category, and none in the severe category (Figure 5). All 8 survivors (100%) improved by at least one mJOA severity category (one patient by two categories). The median category improved from moderate to mild (Wilcoxon signed-rank test, $Z = -2.71$, $p = 0.007$). This comparison is exploratory: it is restricted to survivors, uses severity categories rather than raw scores, and

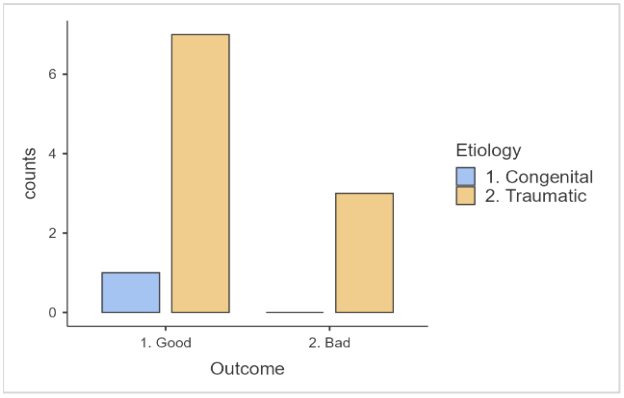

Figure 4. Surgical outcome according to etiology (n=11).

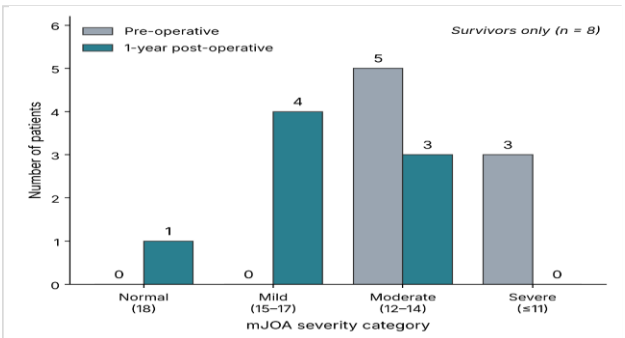

Figure 5. Pre-operative and one-year post-operative mJOA severity categories in the 8 surviving patients (the 3 patients who died are not included).

Table 1. Details of the three patients who died.

Case	Age/sex	Etiology	Pre-op mJOA category	Cause of death	Timing of death (post-op day)	Attributed to procedure?
1	>60 y / female	Traumatic	Normal (18)	Undetermined	25th POD	No
2	>60 y / male	Traumatic	Moderate (12–14)	Aspiration Pneumonia	5th POD	NO
3	>60 y / male	Traumatic	Severe (0–11)	Undetermined	1st POD	No

rests on only 8 pairs; it is therefore subject to survivor bias and should not be read as evidence of efficacy.

Table 2. Pre-operative and one-year post-operative mJOA severity category (n=11). The three patients who died have no post-operative score.

Pre-operative mJOA category	Post-operative (1-year) mJOA category					Total
	Normal (18)	Mild (15–17)	Moderate (12–14)	Severe (0–11)	Died, no score	
Normal (18)	0	0	0	0	1	1
Mild (15–17)	0	0	0	0	0	0
Moderate (12–14)	1	4	0	0	1	6
Severe (0–11)	0	0	3	0	1	4
Total	**1**	**4**	**3**	**0**	**3**	**11**

Discussion

Due to the complex anatomy of the Atlas and axis and the location of the vertebral artery in this region, surgical treatment of instability here is difficult[37]. The male predominance observed in our study (73%) is consistent with previously published literature, wherein traumatic atlantoaxial dislocation disproportionately affects the male population, likely attributable to their higher exposure to high-energy trauma mechanisms such as motor vehicle collisions[38, 39]. Traumatic etiology was the predominant cause of AAD in our series (90.9%), consistent with published literature identifying motor vehicle collisions as the leading cause of CVJ injuries, reflecting the high incidence of road traffic accidents in the developing world, particularly in Bangladesh[9, 40]. The surgical management of atlantoaxial dislocation is guided by the reducibility of the dislocation following cervical dorsal traction. Reducible AAD is managed with posterior reduction and instrumentation, while irreducible AAD requires transoral release followed by posterior fixation using the Transoral Atlantoaxial Reduction Plate (TARP) procedure. Non-reducible AAD requires transoral decompression or a combined approach utilizing Cervical Decompression Reconstruction Procedure (CD-RP) and TARP for definitive stabilization[41]. In our study, all patients underwent posterior C1-C2 fusion utilizing the Harms technique, which employs polyaxial lateral mass screws at C1 and pedicle screws at C2 connected by a rod construct. Postoperative complications occurred in 36.4% of patients, and mortality (27.3%) was the most significant adverse event; the cause and timing of each death are given in Table 1. This mortality is high. All three deaths occurred in patients older than 60 years (3 of the 4 patients in that age group). Still, in a series of 11 patients, we cannot determine to what extent the deaths reflect age, the severity of the underlying injuries, delayed presentation, limited perioperative resources, or the procedure itself. CSF leak occurred in 9.1% of patients, was managed conservatively with acetazolamide, and resolved completely within three weeks. Although no patient required revision surgery, this does not establish solid arthrodesis: postoperative assessment relied on plain radiographs, and CT was not performed, so the fusion rate, which is the definitive endpoint of C1-C2 fixation, could not be evaluated. All eight survivors improved by at least one mJOA severity category at one year. This is a descriptive, survivor-only observation in a very small uncontrolled series; some improvement may reflect natural recovery after decompression and stabilization irrespective of the technique, and it cannot be attributed to the Harms technique or generalized.

The Harms technique was selected over alternative fixation modalities because of its reported biomechanical rigidity, technical versatility, and favorable complication profile. Compared to the Goel screw-plate system, the Harms screw-rod construct offers greater ease of C2 ganglion preservation and facilitates intraoperative reduction of the C1-C2 segment. Furthermore, unlike trans-articular screw fixation, it remains applicable in patients with compromised posterior elements and aberrant vertebral artery anatomy, which is why it is the preferred modality at our institution. Our experience shows that the technique can be performed at a tertiary care center in Bangladesh; however, given the mortality observed, the absence of radiological fusion data, and the very small sample, no conclusion about its comparative safety or effectiveness can be drawn from this series. Larger prospective multicenter studies with CT-based fusion assessment, standardized reporting of causes of death, and extended follow-up are warranted.

Limitations

a) Small sample size (n=11); all inferential analyses are exploratory and underpowered.

b) Retrospective, single-centre design with purposive sampling and a heterogeneous population (all ages; traumatic and congenital etiologies).

c) No postoperative CT: plain radiographs cannot confirm arthrodesis, so the fusion rate could not be evaluated, and the absence of revision surgery cannot be equated with fusion.

d) Mortality of 27.3% (3/11); the neurological comparison is restricted to the 8 survivors (survivor bias) and uses mJOA severity categories, and attribution of deaths to the procedure is limited by the small number.

e) No control or comparison group; neurological improvement cannot be attributed to the technique, and follow-up was limited to one year.

Conclusion

In this small, single-centre retrospective series of 11 patients, posterior C1-C2 fixation using the Harms technique was followed by neurological improvement in all 8 survivors at one year. Still, it was accompanied by a mortality of 27.3% (3/11) and one CSF leak. Because fusion

could not be confirmed radiologically, the series was uncontrolled, and the sample was very small; these findings are exploratory and do not establish the efficacy, reliability, or safety of the technique. Larger prospective multicenter studies with CT-based fusion assessment, standardized reporting of causes of death, and longer follow-up are needed.

Acknowledgments

None.

Ethical consideration

The study was conducted in accordance with the Declaration of Helsinki. This study was not reviewed by an institutional review board or ethics committee. All patients underwent C1-2 Fixation as part of routine clinical care, and no intervention or procedure beyond standard management was performed for research purposes. Data were collected prospectively from routine clinical care and anonymized for analysis. Written informed consent for surgery and for the use of anonymized data was obtained from patients or their parents or legal guardians.

Competing Interests

The authors declare no conflict of interest.

Funding

No funds were received for this research.

References

1. Ono Y, Hongo M, Kasukawa Y, Misawa A, Kudo D, Miyakoshi N. Chronic atlantoaxial rotatory fixation with neurofibromatosis type I: A case report. Surg Neurol Int. 2022;13. doi: 10.25259/SNI_1171_2021
2. Li G, Zhang H, Wang Q. Imaging and classifications of atlantoaxial dislocation: a narrative review. EFORT Open Reviews. British Editorial Society of Bone and Joint Surgery; 2025. p. 551–61. doi: 10.1530/EOR-2024-0061
3. Jain VK. Atlantoaxial dislocation. Neurology India. 2012. p. 9–17. doi: 10.4103/0028-3886.93582
4. Sobolewski BA, Mittiga MR, Reed JL. Atlantoaxial rotary subluxation after minor trauma. Pediatr Emerg Care. 2008;24(12):852–6.
5. Egol KA, Koval KJ, Zuckerman JD. Handbook of Fractures, 4e. Lippincott Williams & Wilkins; 2009.
6. Jain VK, Behari S. Management of congenital atlanto-axial dislocation: some lessons learnt. Neurol India. 2002;50(4):386–97.
7. Salunke P, Sharma M, Sodhi HBS, Mukherjee KK, Khandelwal NK. Congenital atlantoaxial dislocation: A dynamic process and role of facets in irreducibility: Clinical article. J Neurosurg Spine. 2011 Dec;15(6):678–85. doi: 10.3171/2011.7
8. Wang S, Wang C, Yan M, Zhou H, Dang G. Novel surgical classification and treatment strategy for atlantoaxial dislocations. Spine (Phila Pa 1976). 2013 Oct 1;38(21). doi: 10.1097/BRS.0b013e3182a1e5e4
9. Yang SY, Boniello AJ, Poorman CE, Chang AL, Wang S, Passias PG. A Review of the Diagnosis and Treatment of Atlantoaxial Dislocations. Global Spine J. 2014;4(3):197–210. doi: 10.1055/s-0034-1376371
10. Platzer P, Vécsei V, Thalhammer G, Oberleitner G, Schurz M, Gaebler C. Posterior Atlanto-Axial Arthrodesis for Fixation of Odontoid Nonunions. Spine (Phila Pa 1976) [Internet]. 2008;33(6). Available from: https://journals.lww.com/spinejournal/fulltext/2008/03150/posterior_atlanto_axial_arthrodesis_for_fixation.9.aspx
11. Finn MA, Apfelbaum RI. Atlantoaxial Transarticular Screw Fixation: Update on Technique and Outcomes in 269 Patients. Neurosurgery [Internet]. 2010;66(3). Available from: https://journals.lww.com/neurosurgery/fulltext/2010/03001/atlantoaxial_transarticular_screw_fixation__update.23.aspx
12. Guo X, Ni B, Zhao W, Wang M, Zhou F, Li S, et al. Biomechanical Assessment of Bilateral C1 Laminar Hook and C1-2 Transarticular Screws and Bone Graft for Atlantoaxial Instability. Clin Spine Surg [Internet]. 2009;22(8). Available from: https://journals.lww.com/jspinaldisorders/fulltext/2009/12000/biomechanical_assessment_of_bilateral_c1_laminar.7.aspx
13. Goel A, Desai KI, Muzumdar DP. Atlantoaxial Fixation Using Plate and Screw Method: A Report of 160 Treated Patients. Neurosurgery [Internet]. 2002;51(6). Available from: https://journals.lww.com/neurosurgery/fulltext/2002/12000/atlantoaxial_fixation_using_plate_and_screw.4.aspx
14. Goel A, Laheri V. Plate and screw fixation for atlanto-axial subluxation. Acta Neurochir (Wien). 1994;129(1):47–53. doi: 10.1007/BF01400872
15. Harms J, Melcher RP. Posterior C1–C2 Fusion With Polyaxial Screw and Rod Fixation. Spine (Phila Pa 1976) [Internet]. 2001;26(22). Available from: https://journals.lww.com/spinejournal/fulltext/2001/11150/posterior_c1_c2_fusion_with_polyaxial_screw_and.14.aspx
16. Lalit M, Piplani S, Kullar JS, Arora AK, Mannan R. The morphological analysis of the superior articular facet of the adult human atlas vertebra. J Clin Diagn Res. 2011;5(2):274–7.
17. Gosavi SN, Vatsalaswamy P. Morphometric study of the atlas vertebra using manual method. Malays Orthop J. 2012;6(3):18–20. doi: 10.5704/MOJ.1207.015
18. Yin QS, Wang JH. Current Trends in Management of Atlantoaxial Dislocation. Orthop Surg. 2015;7(3):189–99. doi: 10.1111/os.12196
19. Xu R, Nadaud MC, Ebraheim NA, Yeasting RA. Morphology of the second cervical vertebra and the posterior projection of the C2 pedicle axis. Spine (Phila Pa 1976). 1995;20(3):259–63.
20. Offiah CE, Day E. The craniocervical junction: embryology, anatomy, biomechanics and imaging in blunt trauma. Insights into Imaging. Springer Verlag; 2017. p. 29–47. doi: 10.1007/s13244-016-0530-5
21. Lopez AJ, Scheer JK, Leibl KE, Smith ZA, Dlouhy BJ, Dahdaleh NS. Anatomy and biomechanics of the craniovertebral junction. Neurosurg Focus. 2015;38(4):1–8. doi:10.3171/2015.1
22. Swartz EE, Floyd RT, Cendoma M. Cervical spine functional anatomy and the biomechanics of injury due to compressive loading. J Athl Train. 2005;40(3):155–61.
23. Şengül G, Kadioğlu HH. Morphometric anatomy of the atlas and axis vertebrae. Turk Neurosurg. 2006;16(2):69–76.
24. Gluf WM, Schmidt MH, Apfelbaum RI. Atlantoaxial transarticular screw fixation: a review of surgical indications, fusion rate, complications, and lessons learned in 191 adult patients. J Neurosurg Spine. 2005;2(2):155–63.
25. Chapter 05 Posterior Approach to the Craniocervical Junction and Posterior Spine (1).
26. Joaquim AF, Schnake KJ, Bransford RJ, Chabbra HS, Bigdon SF, El-Sharkawi M, et al. Craniocervical traumatic ligamentous injuries – AO spine type B injuries – Anatomy, biomechanics and clinical perspectives. J Clin Orthop Trauma. 2025;71:103223. doi: 10.1016/j.jcot.2025.103223
27. Mukherjee S, Abhinav K, Revington PJ. A review of cervical spine injury associated with maxillofacial trauma at a UK tertiary referral centre. Ann R Coll Surg Engl. 2015;97(1):66–72. doi: 10.1308/003588414X14055925059633
28. Yang B, Lu T, He X, Li H. Analysis of surgical strategies and efficacy in the treatment of Os odontoideum with atlantoaxial dislocation. J Orthop Surg Res. 2023;18(1). doi: 10.1186/s13018-023-03517-x
29. Stulik J, Vyskocil T, Sebesta P, Kryl J. Atlantoaxial fixation using the polyaxial screw-rod system. European Spine Journal. 2007 Apr;16(4):479–84. doi: 10.1007/s00586-006-0241-6
30. Melcher RP, Puttlitz CM, Kleinstueck FS, Lotz JC, Harms J, Bradford DS. Biomechanical testing of posterior atlantoaxial fixation techniques. Spine (Phila Pa 1976). 2002;27(22):2435–40. doi: 10.1097/00007632-200211150-00004
31. Jeon S, Jeong J, Choi G, Moon S, Hwang H, Choi S. Clinical

outcome of posterior fixation of the C1 lateral mass and C2 pedicle by polyaxial screw and rod. Clin Neurol Neurosurg. 2011 Nov 28;114:539–44. doi: 10.1016/j.clineuro.2011.11.001

32. Elliott RE, Tanweer O, Boah A, Morsi A, Ma T, Frempong-Boadu A, et al. Outcome Comparison of Atlantoaxial Fusion With Transarticular Screws and Screw-Rod Constructs: Meta-Analysis and Review of Literature. Clin Spine Surg [Internet]. 2014;27(1). Available from: https://journals.lww.com/jspinaldisorders/fulltext/2014/02000/outcome_comparison_of_atlantoaxial_fusion_with.2.aspx
33. Kim JY, Oh CH, Yoon SH, Park HC, Seo HS. Comparison of outcomes after atlantoaxial fusion with transarticular screws and screw-rod constructs. J Korean Neurosurg Soc. 2014 May 1;55(5):255–60. doi: 10.3340/jkns.2014.55.5.255
34. Elliott RE, Tanweer O, Boah A, Smith ML, Frempong-Boadu A. Comparison of safety and stability of C-2 pars and pedicle screws for atlantoaxial fusion: Meta-analysis and review of the literature: a systematic review. Journal of Neurosurgery: Spine. 2012. p. 577–93. doi: 10.3171/2012.9.SPINE111021
35. Elliott RE, Tanweer O, Boah A, Morsi A, Ma T, Smith ML, et al. Atlantoaxial Fusion with Screw-Rod Constructs: Meta-Analysis and Review of Literature. World Neurosurg. 2014;81(2):411–21. doi: 10.1016/j.wneu.2012.03.013
36. Prasarn ML, Crosby S. Atlantoaxial Procedures. In: Davis SF, editor. Surgical Procedures of the Spine for Intraoperative Neurophysiological Monitoring Providers [Internet]. Cham: Springer International Publishing; 2022. p. 1–22. doi: 10.1007/978-3-031-17580-0_1
37. Karakoyun Do. Clinical Results of Harms Technique in Atlantoaxial Instability Treatment. Middle Black Sea Journal of Health Science. 2020;6(3):294–8. doi: 10.19127/mbsjohs.771475
38. Wang Y, Wang C, Yan M. Clinical Outcomes of Atlantoaxial Dislocation Combined with High-Riding Vertebral Artery Using C2 Translaminar Screws. World Neurosurg. 2019;122:e1511–8. doi: 10.1016/j.wneu.2018.11.092
39. Lang Z, Han X, Fan M, Liu Y, He D, Tian W. Posterior atlantoaxial internal fixation using Harms technique assisted by 3D-based navigation robot for treatment of atlantoaxial instability. BMC Surg. 2022;22(1). doi: 10.1186/s12893-022-01826-2
40. Krasner H, Maitra S, McNickle AG. A comprehensive analysis of traumatic atlanto-occipital and atlanto-axial dislocations: A case series from a level one trauma center. Trauma Case Rep. 2025;60. doi: 10.1016/j.tcr.2025.101251
41. Chen Q, Brahimaj BC, Khanna R, Kerolus MG, Tan LA, David BT, et al. Posterior atlantoaxial fusion: A comprehensive review of surgical techniques and relevant vascular anomalies. Journal of Spine Surgery. 2020;6(1):164–80. doi: 10.21037/jss.2020.03.05