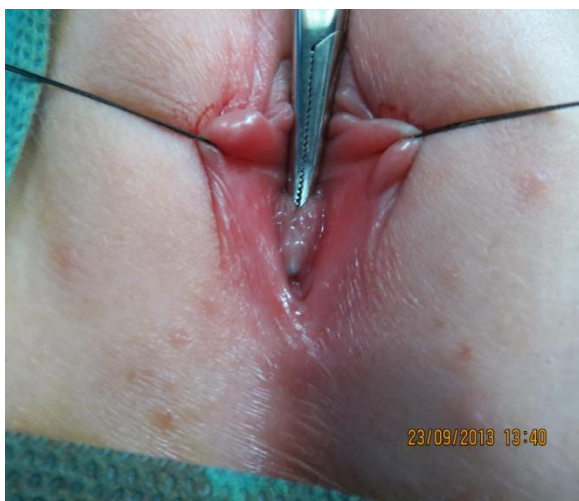

## Case Report

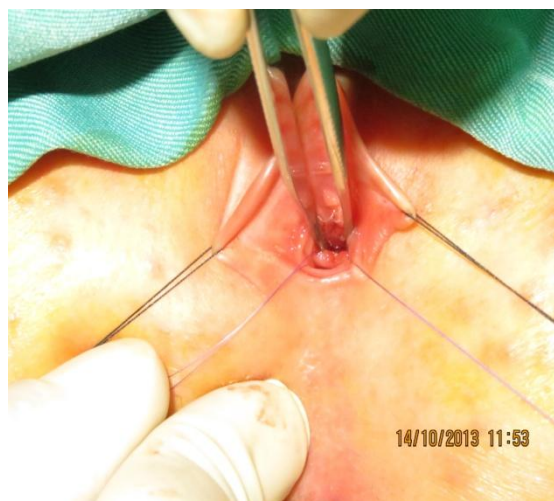
<http://journals.sbm.ac.ir/jpn>

### A 6 Year-old Female Presenting with Recurrent Urinary Tract Infections

A 6 year -old girl was admitted because of pyelonephritis. She had a history of recurrent urinary tract infections (UTIs) and daytime wetting. Her urinary tract ultrasonography was shown normal kidneys, increased bladder wall thickening and volume of post voiding residual urine. In voiding cystoureterography there was no vesicoureteral reflux. Urodynamic study showed high pressure detrusor and low compliance. Due to some difficulty in passing urinary catheter during VCUG, the patient underwent cystoscopy.



**Figure 1.** Pre operation



**Figure 2.** Post operation

### Answer