

# Meningitis Retention Syndrome in an 11-Year-Old Boy: A Case Report of an Underreported Clinical Scenario in Children

Md Abdul Qader<sup>1\*</sup>,  
Lutfunnahar Begum<sup>1</sup>,  
Zeena Salwa<sup>1</sup>,

<sup>1</sup>Department of Pediatrics, Square  
Hospitals Ltd. Dhaka, Bangladesh.

**\*Corresponding Author**

Dr. Md Abdul Qader,  
Email: drabdulqader@squarehospital.com

**Received:** August, 2019

**Revised:** August, 2019

**Accepted:** September, 2019

## Abstract

Meningitis retention syndrome (MRS) is an underreported clinical syndrome in children that presents with meningitis and acute retention of urine. It is usually associated with aseptic meningitis, but there are case reports of MRS associated with viral and other kind of meningitis. There is no imaging abnormalities in the brain and spine associated with acute urinary retention. Here we report a case of an 11-year-old boy who presented with signs of meningism and acute urinary retention. Further evaluation revealed features of meningitis in cerebrospinal fluid analysis and normal imaging of the brain and spine. He completely recovered from urinary retention after meningitis treatment.

**Keywords:** Meningitis; Urinary Retention; Child; Case Report.

**Conflict of interest:** The authors declared no conflict of interest.

**Please cite this article as:** Abdul Qader M, Begum L, Salwa Z. Meningitis Retention Syndrome in an 11-Year-Old Boy: A Case Report of an Underreported Clinical Scenario in Children. J Ped Nephrol. 2019;7(3). <https://doi.org/10.22037/jpn.v7i3.26828>

## Introduction

Meningitis retention syndrome (MRS), a newly described clinical condition, is associated with aseptic meningitis without any identifiable etiological agents and acute urinary retention (1, 2). Urinary retention without a neurological etiology is extremely rare in children, young adults, and women (3).

The etiology/cause of acute urinary retention can be divided into two groups: disorders of the peripheral nervous system (sacral herpes caused by herpes simplex virus or varicella zoster virus) and disorders of the central nervous system (MRS).

## Case Report

An 11-year-old boy was referred to our hospital with the complaints of fever for 15 days and inability to void completely for 10 days. The fever was initially low grade but then progressed to become high grade (maximum temperature: 40°C); it was intermittent and was associated with headache and episodes of vision dimness.

He was admitted to a local hospital and treated with ceftriaxone and amikacin for septicemia.

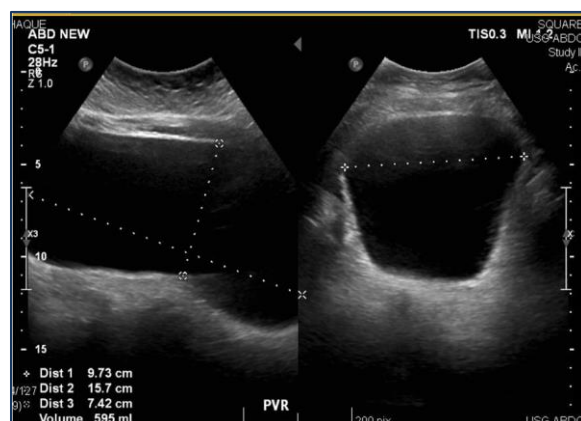
After 5 days, he developed urinary retention associated with lower abdominal pain.

As his condition was not improving, ceftriaxone was switched to meropenem after 5 days. Upon admission to our hospital, he had a temperature of 37.2°C, a pulse rate of 100 beats/min, and a blood pressure of 120/70 mmHg (95<sup>th</sup> centile). His weight was 62 Kg (above 95<sup>th</sup> centile) and his height was 154.5 cm (between 90<sup>th</sup> to 95<sup>th</sup> centile).

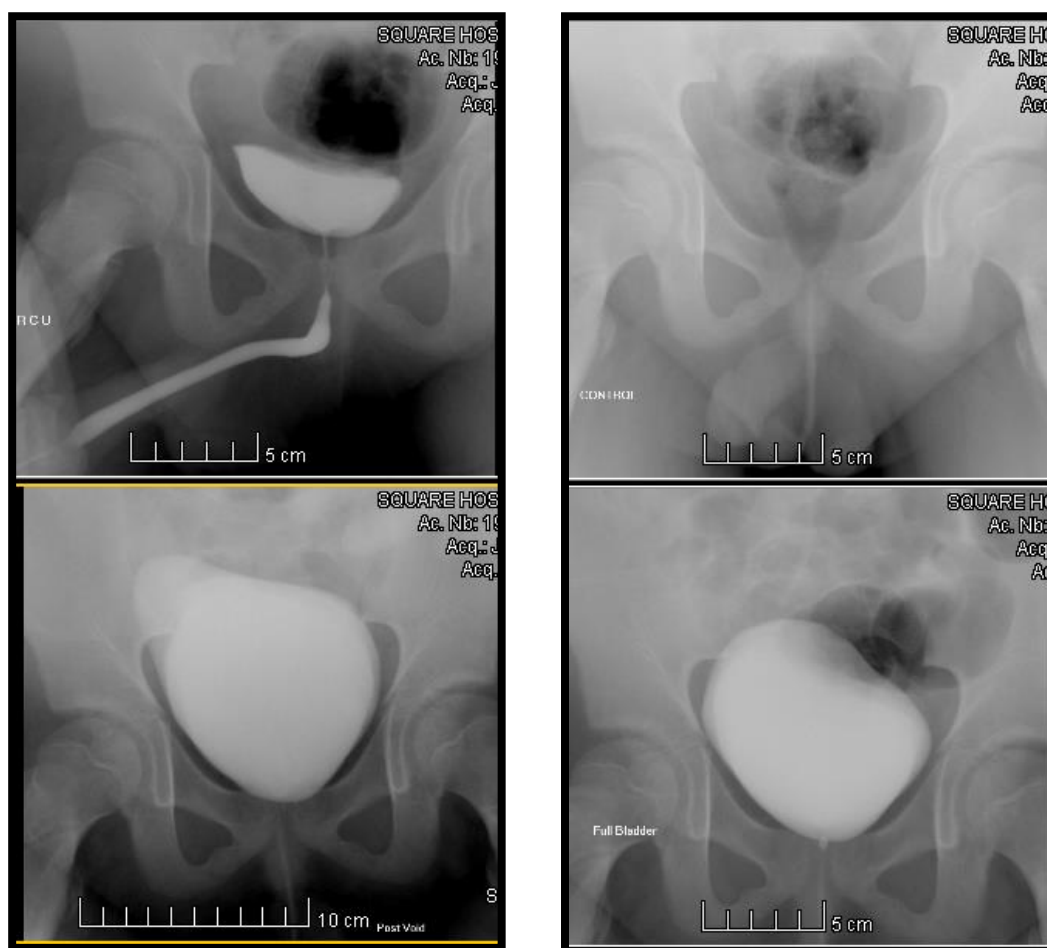
He did not look pale or icteric but his tongue was slightly coated. He did not have neck rigidity and the Kernig's sign was negative. Examination of the nervous system, abdomen, and respiratory system revealed normal findings. Blood investigation showed a borderline leukocytosis with normal differential counts and platelets. C-reactive protein (<5 mg/L) and procalcitonin (<0.01 ng/mL) were within normal limits. The rest of the hematological and biochemical parameters were normal. Urine and blood cultures were negative.

Abdominal ultrasonography (USG) revealed mild pelvicaliceal dilatation in the left kidney with a high post void residue (PVR) of 595 mL (Figure 1).

Retrograde and voiding cystourethrography showed a significant amount of PVR (Figure 2).



**Figure 1.** Post void residue (595 ml) on ultrasound of the bladder.



**Figure 2.** Significant amount of post void residue on VCUG.

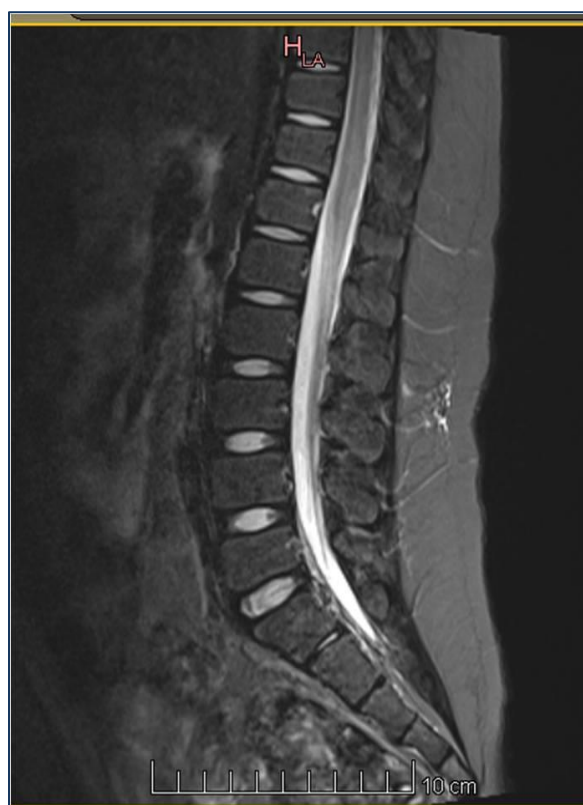At this stage, he was catheterized with a Foley's catheter for ensuring adequate void and comfort. His treatment was continued with meropenem

and he became afebrile on day 6 of meropenem administration. Magnetic resonance imaging (MRI) of the brain and dorsal spine was

unremarkable. MRI of spine was shown in Figure 3. The results of CSF analysis were as follows: total WBC=129 cells/ $\mu$ L (lymphocyte: 97%), protein=187 mg/dL (N: 12-60), and glucose=39.6 mg/dL (N: 40-70).

CSF bacterial and viral serology and culture were negative. Although he became afebrile, he still had a headache. Therefore, considering the CSF results, antiviral treatment with acyclovir was started suspecting a viral etiology and continued for a total of 10 days.

The Foley's catheter was removed after completing the course of acyclovir therapy and he was able to void completely. Follow-up ultrasound KUB revealed a PVR of 65mL without any pelvicaliceal dilatation.



**Figure 3.** T2W (MRI) image showing normal spine.

## Discussion

MRS is a clinical syndrome mostly reported in Japan. Akiyuki et al. (4) presented 37 cases of MRS in whom the most common presenting features were headache (100%), fever, nausea, and myalgia. Our patient presented with fever and headache without any signs of meningeal irritation. He developed acute urinary retention

after 5 days of the onset of symptoms. The average time between the onset of symptoms of meningitis and acute retention is about 8 days, which was a little shorter in our patient (4).

MRS has been mostly reported with aseptic meningitis but some cases have been reported with viral and or other etiologies (5, 6). In our case, the specific etiology of meningitis could not be identified because all the serological reports and cultures from the CSF and blood were negative.

The mechanism behind urinary retention in MRS is poorly understood and remains unclear. Unfortunately, in our case, we could not evaluate the bladder function by urodynamic study (UDS) but usual UDS findings include an underactive detrusor with or without an unrelaxing sphincter (7).

An underactive detrusor originates from different sites of lesion along the neural axis with lower motor neuron lesions being the commonest. Without any clinical and radiological evidence in our case, a lower motor lesion was unlikely. Upper motor lesions causing an underactive detrusor usually occur in an acute phase like acute disseminated encephalomyelitis (ADEM), which could be a possibility. In fact, a mild form of acute disseminated encephalomyelitis (ADEM) was considered earlier (1, 2). However, spontaneous recovery without any immune treatment does not support this etiology.

The duration of recovery from retention varies from 2 to 10 weeks in MRS (2, 8-10), which is similar to our case. The predictors of developing MRS have been previously discussed but further studies are required to define the factors preceding MRS development in a child with meningitis.

## Conclusion

MRS is a clinical syndrome that is underreported in children. It is important to know the natural course and long-term prognosis of the syndrome. In this article, we described the presenting features, clinical findings, and lab reports of a case of MRS.

## Acknowledgements

Not declared.

**Conflict of interest**

The authors declared no conflict of interest.

**Financial Support**

Not declared.

**References**

1. Sakakibara R, Uchiyama T, Liu Z, Yamamoto T, Ito T, Uzawa A, et al. Meningitis-retention syndrome. *Journal of neurology*. 2005;252(12):1495-9.
2. Sakakibara R, Kishi M, Tsuyusaki Y, Tateno A, Tateno F, Uchiyama T, et al. "Meningitis retention syndrome": A review. *Neurourology and urodynamics*. 2013;32(1):19-23.
3. Herbaut AG. Neurogenic urinary retention. *International urogynecology journal*. 1993;4(4):221-8.
4. Hiraga A, Kuwabara S. Meningitis-retention syndrome: Clinical features, frequency and prognosis. *Journal of the neurological sciences*. 2018;390:261-4.
5. Yamanishi T, Yasuda K, Sakakibara R, Hattori T, Uchiyama T, Minamide M, et al. Urinary retention due to herpes virus infections. *Neurourology and Urodynamics: Official Journal of the International Continence Society*. 1998;17(6):613-9.
6. Logan SA, MacMahon E. Viral meningitis. *Bmj*. 2008;336(7634):36-40.
7. Ohe C. A case of urinary retention secondary to aseptic meningitis. *Rinshou Hinyoukika*. 1990;44:911-3.
8. Kim TW, Whang JC, Lee SH, Choi JI, Park SM, Lee JB. Acute urinary retention due to aseptic meningitis: meningitis-retention syndrome. *International neurourology journal*. 2010;14(2):122.
9. Krishna A, Devulapally P, Ghobrial I. Meningitis retention syndrome. *Journal of community hospital internal medicine perspectives*. 2012;2(1):15761.Y.
10. Tanaka Y, Satomi K. Cystometrography of meningitis-retention syndrome. *Case Reports*. 2017;2017:bcr-2017.