

Excision of Epulis Granulomatosa with Diode Laser in 8 Years Old Boy

Sara Ghadimi^{1,2}, Nasim Chiniforush¹, Mahsa Najafi², Sepideh Amiri^{2*}

¹Laser Research Center of Dentistry, Dental Research Institute, Tehran University of Medical Sciences, Tehran, Iran.

²Department of Pediatric Dentistry, School of Dentistry, Tehran University of Medical Sciences, Tehran, Iran

Abstract:

Introduction: Epulis granulomatosa is a lesion which grows from an extraction socket. It can be misdiagnosed with lesions of the same clinical appearance such as: foreign body or pyogenic granuloma, or as a herniation of the maxillary sinus. The most common treatment is surgical excision.

Case report: The present article reports an Epulis granulomatosa which was removed with diode laser (810 nm) due to child's fear related to traditional surgical instruments and bleeding.

Results and conclusion: Lasers are useful for soft tissue surgery in modern dentistry, especially in relation to pediatric patients due to the rapid and regular wound healing without sutures.

Keywords: diode laser; oral lesions; Epulis granulomatosa; children

Please cite this article as follows:

Sara Ghadimi, Nasim Chiniforush, Mahsa Najafi, Sepideh Amiri. Excision of Epulis Granulomatosa with Diode Laser in 8 Years Old Boy: A Case Report. J Lasers Med Sci 2015;6(2):92-5

*Corresponding Author: Sepideh Amiri, DDS; Department of Pediatric Dentistry, School of Dentistry, North Kargar St, Tehran, Iran. Tel: +98-2122673703; Fax: +98-2188754512; E-mail: sepide_k87@yahoo.com

Introduction

There are several oral soft tissue lesions in pediatric patients with different clinical presentations¹. Gingival enlargement is a common finding during clinical examination². The etiology and pathogenesis of gingival enlargement are still not well established. Most of the gingival enlargements are inflammatory in origin and therefore can be treated completely with conventional periodontal treatment such as internal bevel gingivectomy. Because of its unusual clinical features, the diagnosis and treatment plan can be complicated in some cases. Histopathologic examination is the gold standard for the most reliable diagnosis of these lesions². Epulis granulomatosa refers to a tissue growth into the oral cavity which is a post-surgical lesion emanating from an extraction socket³. It can be misdiagnosed with lesions of the same clinical appearance, for example, foreign body or pyogenic granulomas, or as a herniation of the maxillary sinus². There are several techniques for removal of the oral lesions, including: Scalpel, Electro surgery and Laser techniques. The most common treatment is

surgical excision⁴. The present report concentrates on a case which was treated using diode laser as the child was afraid of traditional surgical blade and bleeding.

Case report

An 8-year-old boy patient referred to the Pediatric Dentistry Department, Tehran University of Medical Sciences complaining of a gingival mass in the upper right region at the extracted first primary molar area. There was no history of systemic disease. Oral hygiene was poor and the patient reported history of acute abscess in the upper right primary first molar which was extracted 2 months ago. Clinical examination revealed a soft, ulcerative reddish mass measuring approximately 1*1.2*0.8 cm³. (Figure 1-A, B) The lesion was asymptomatic but caused some mastication problems. In radiographic examination, the underlying bone was normal and there was no radiolucency or erosion in the bone. Because of the child's fear related to scalpel and bleeding, excisional biopsy was performed with a diode laser (Elexxionnano, Germany) (808 nm ± 10 nm) under local anesthesia. (Lidocaine 2%

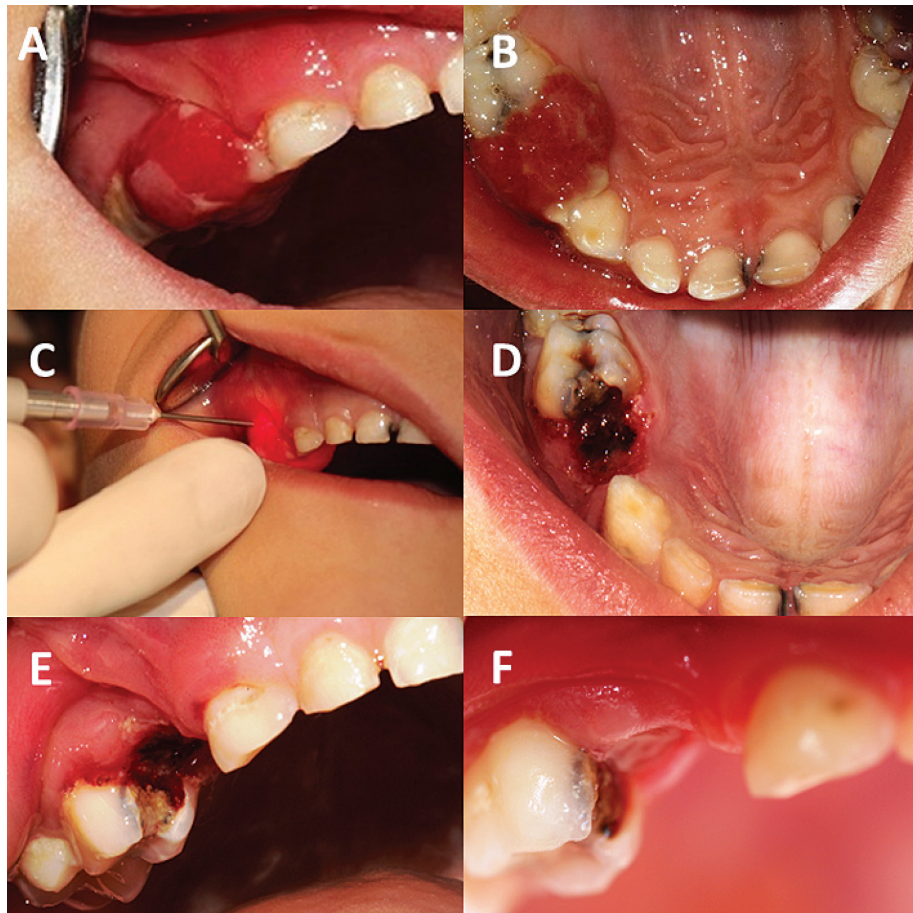


Figure 1. A, B) Ulcerative reddish mass at region of extracted first primary molar C) Excisional biopsy with diode laser D, E) Site of surgery immediately after operation and F) Site of surgery at follow up session 2 weeks after surgery

with epinephrine 1:100,000). (Figure 1-C) The excision was made using a 400µm fiber, in pulse mode with 15W peak power, a frequency of 10000Hz and pulse duration of 16µs in contact mode. 4W continuous mode was used for coagulation through non-contact application in the site of surgery. No medication was prescribed for the patient. After 2 weeks, at the follow up session, the site of surgery was completely healed (Figure 1-D to 1-F)

Histopathology

The sample was stored in 10% formalin and sent for histopathological examination. In order to make an accurate diagnosis, pathologist was informed that the lesion had been removed by laser.

The histological examination revealed connective tissue elements consisting of proliferation of plump fibroblasts and endothelial cells with spindle shape nuclei. Numerous and various sized blood vessels with extensive infiltration of chronic inflammatory cells, mostly lymphocytes were also evident. (Figure 2) In most

areas, the overlying non-keratinized stratified squamous epithelium was ulcerated. In the depth of the specimen, areas of bone trabeculae and osteoid matrix were also visible. (Figure 3)

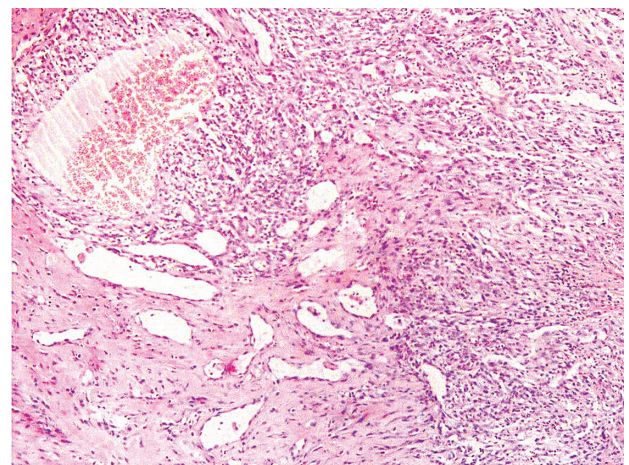


Figure 2. The histological examination revealed connective tissue elements consisting of proliferation of plump fibroblasts and endothelial cells with spindle shape nuclei. Numerous and various size of blood vessels.

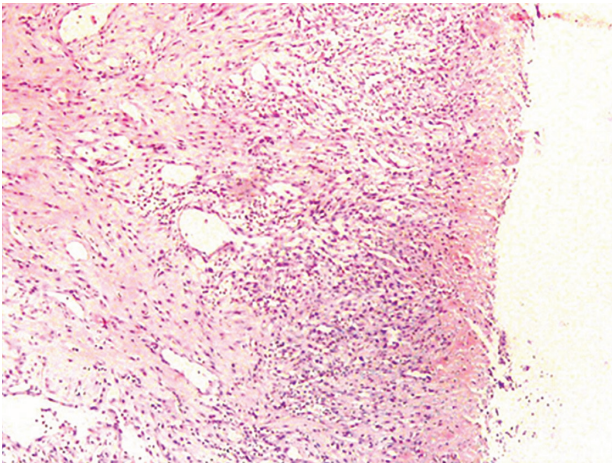


Figure 3. In most areas the overlying non-keratinized stratified squamous epithelium was ulcerated.

Discussion

Many benign lesions or abnormalities of children's oral soft tissues can be treated by general practitioners⁵. Oral surgery in children is often a challenging procedure due to lack of patient cooperation. Several authors have explained that the use of laser in soft and hard tissue surgery causes less discomfort and better tolerance by young patients and their parents^{6,7}. Thus, laser can decrease psychological trauma and panic during the surgical procedure due to reduced surgery time. Recent advances have shown that laser therapy can be used as an alternative or complement to traditional methods^{5,8}. Laser surgery usually requires local anesthesia, but rarely needs sutures. Advantages of laser excision of these lesions are least hemorrhage, lower post-surgical pain and rapid wound healing after surgery⁹. Today, diode laser is widely used in oral surgery to excise lesions¹⁰. The relatively small size and lower costs of diode laser have made it interesting to dental practitioners for use in different indications. Benefit of diode laser over traditional surgery with scalpel comprises convenient mucosa removal, high precision in tissue destruction^{4,11}, easy ablation of soft tissue, immediate sterilization, decreased mechanical trauma, increased patients acceptance, no or few sutures⁸, homeostasis, decreased bacteremia, decreased edema, less operative and post-operative discomfort^{4,8}, little wound contraction and minimal scar^{5,8}. In addition to all the benefits mentioned, laser is very useful in pediatric patients for oral surgical procedures⁵. Compared to Nd:YAG lasers, the radiation of diode laser shows more absorption and less penetration depth, mainly in blood-rich tissue^{12,13}. Diode lasers with wavelengths in the range of 800-980 nm are available

for use in dentistry. All diode wavelengths are strongly absorbed by tissue pigments and penetrate deeply. The application of diode laser can stimulate fibroblast proliferation, collagen synthesis, vessels proliferation accompanied by enhanced epithelial cell division resulting in faster wound healing¹³. Diode laser with 810 nm wavelength is significantly absorbed in tissue due to the presence of hemoglobin. This causes not only better incision, but also very good coagulation of tissues. With laser sterilization of wound; the inflammatory response is mild and delayed. Less discomfort may correspond to the decreased inflammatory reaction related to laser application. Moreover, laser irradiation causes sealing of the nerve endings in the surgical contact area and the denaturalized collagen layer formed on the surface of the surgical wound serves to isolate it from the oral fluids^{4,14}.

Conclusion

Due to the rapid and regular wound healing without sutures, lasers are useful for soft tissue surgery in modern dentistry, especially in relation to pediatric patients. Laser technology provides optimal care for children without many of the 'fear factor' found in routine dental care and can increase the cooperation of pediatric patients.

References

1. Pinto A. Pediatric soft tissue lesions. *Dent Clin North Am.* 2005; 49(1):241-58.
2. Benjamin A. EPULIS HAEMANGIOMATOSA-POST EXTRACTION SEQUELAE. *Sci J.* 2009; 3.
3. Leong R, Seng GF. Epulis granulomatosa: extraction sequellae. *Gen Dent.* 1998; 46(3):252-5.
4. Agrawal AA, Mahajan M, Mahajan A, Devhare S. Application of diode laser for excision of non-inflammatory vascular epulis fissuratum. *Int J Case Rep Images.* 2012;3(9):42-5.
5. Boj JR, Poirier C, Hernandez M, Espassa E, Espanya A. Case series: laser treatments for soft tissue problems in children. *Eur Arch Paediatr Dent.* 2011; 12(2):113-7.
6. Olivi G, Genovese MD, Caprioglio C. Evidence-based dentistry on laser paediatric dentistry: review and outlook. *Eur J Paediatr Dent.* 2009; 10(1):29-40.
7. American Academy of Pediatric Dentistry (AAPD). Policy on the Use of Lasers for Pediatric Dental Patients. *Oral Health Policies.* 2013; 36:75-7.
8. Amid R, Kadkhodazadeh M, TalebiArdakani M, Hemmatzadeh S, Refoua S, Iranparvar P, et al. Using Diode Laser for Soft Tissue Incision of Oral Cavity. *J Lasers Med Sci.* 2012;3(1)36-43.
9. Ghadimi S, Chiniforush N, Bouraima SA, Johari M. Clinical

- Approach of Laser Application in Different Aspects of Pediatric Dentistry. *J Lasers Med Sci*. 2012; 3(2):84-90.
10. Angiero F, Parma L, Crippa R, Benedicenti S. Diode laser (808 nm) applied to oral soft tissue lesions: a retrospective study to assess histopathological diagnosis and evaluate physical damage. *Lasers Med Sci*. 2012; 27(2):383-8.
 11. Robert A. Strauss GJ, Dorothy E, Wojtkowski. A comparison of postoperative pain parameters between CO₂ Laser and Scalpel Biopsies. *Oral laser Appl*. 2006; 6:39-42.
 12. Yeliz K, Sedat C. Surgical Removal of a Giant Sialolith by Diode Laser. *Open J Stomatol*. 2014; 4:484-8.
 13. Fekrazad R, Chiniforush N, Bouraima SA, Valipour M, Aslani M, Zare M, Ashtiani Safari O. Low Level Laser Therapy in Management of Complications after Intra Oral Surgeries. *J Lasers Med Sci* 2012; 3(4):135-40.
 14. Goharkhay K, Moritz A, Wilder-Smith P, Schoop U, Kluger W, Jakolitsch S, et al. Effects on Oral Soft Tissue Produced by a Diode Laser in vitro. *Lasers Surg Med*. 1999; 25:401-6.