



# A Comparative Study of the Use of a 980 nm Diode Laser and 10600nm CO<sub>2</sub> in the Treatment of Gingival Melanin Pigmentation

Reza Birang<sup>1</sup>, Sayed Mohsen Sadeghi<sup>2</sup>, Ehsan Birang<sup>3</sup>, Nafiseh Birang<sup>4</sup>, Reza Fekrazad<sup>5</sup>, Samaneh Soltani<sup>6</sup>, Nasim Chiniforush<sup>7</sup>, Jaber Yaghini<sup>8</sup>

<sup>1</sup>Department of Periodontology, Dental Research Center, Dental Research Institute, School of Dentistry, Isfahan University of Medical Sciences, Isfahan, Iran

<sup>2</sup>Department of Endodontics, School of Dentistry, Qom University of Medical Sciences, Qom, Iran

<sup>3</sup>Department of Periodontology, School of Dentistry, International Campus, Iran University of Medical Sciences, Tehran, Iran

<sup>4</sup>Post Graduate Student of Physical Medicine, Shiraz University of Medical Sciences, Shiraz, Iran

<sup>5</sup>Radiation Sciences Research Center, Laser Research Center in Medical Sciences, AJA University of Medical Sciences, Tehran, Iran

<sup>6</sup>Department of Periodontology, School of Dentistry, Qom University of Medical Sciences, Qom, Iran

<sup>7</sup>Laser Research Center of Dentistry, Dentistry Research Institute, Tehran University of Medical Sciences, Tehran, Iran

<sup>8</sup>Department of Periodontics, Dental Implants Research Center, Dental Research Institute, School of Dentistry, Isfahan University of Medical Sciences, Isfahan, Iran

## \*Correspondence to

Samaneh Soltani,  
Email: [s.soltani@dnt.mui.ac.ir](mailto:s.soltani@dnt.mui.ac.ir)

Received: May 18, 2024

Accepted: September 17, 2024

ePublished: December 7, 2024

## Abstract

**Introduction:** Gingival depigmentation with the help of lasers is known as an effective technique. The aim of this study was to compare the efficiency of 980nm diode and CO<sub>2</sub> lasers in the treatment of gingival hyperpigmentation.

**Methods:** In this clinical trial study, 14 individuals (8 females and 6 males) with the age range of 19 to 47 years were selected. One quadrant was randomly treated with CO<sub>2</sub> laser (10600 nm, non-contact, super pulse mode) and the opposite quadrant was treated with a diode laser (980 nm, continuous wave [CW], 1.5 W). The area of the pigmented region, Dummett oral pigmentation index (DOPI), the amount of changes in the RGB parameter (red, green, blue) and  $\Delta E^*$  in clinical photographs before, one and three months after the treatment were calculated by ImageJ and Photoshop software. Pain and discomfort were assessed one hour, one day and one week later by the visual analogue scale (VAS). In addition, after 3 months, the cosmetic results achieved for the different therapeutic approaches were evaluated by patients and professional evaluator. Data were analyzed by the paired samples *t* test, repeated measures ANOVA and Wilcoxon test.

**Results:** The results of this study showed that the duration of CO<sub>2</sub> laser treatment was statistically and significantly shorter than the time of 980-nm diode laser treatment ( $P < 0.05$ ). There were no statistically significant differences in the pigmented lesion area ( $P > 0.05$ ), RGB parameter ( $P > 0.05$ ), DOPI index ( $P > 0.05$ ) and  $\Delta E$  parameter ( $P > 0.05$ ) in one month and three months after treatment follow-ups between the two types of lasers. There was no statistically significant difference in patient satisfaction ( $P > 0.05$ ) and professional evaluation ( $P > 0.05$ ) between the two groups of lasers. Post-treatment pain scores were not statistically significant between the two groups.

**Conclusion:** Both 980-nm diode laser and 10600-nm CO<sub>2</sub> are effective in the treatment of gingival depigmentation while CO<sub>2</sub> laser radiation with super pulse mode is faster in terms of operating time. While working with the diode laser is more controllable.

**Trial Registration Number:** IRCT20200309046728N1; <https://irct.behdasht.gov.ir/>.

**Keywords:** Gingival pigmentation; Depigmentation; Diode laser; CO<sub>2</sub> laser.



## Introduction

Gingival colour is one of the most important factors in facial beauty and smile. It is determined by various factors such as the number and size of blood vessels, epithelial

thickness, keratinization rate, and pigments in the epithelial layer. Melanin is one of the main pigments that determine the color of the gums and forms the gingival melanin pigmentation.<sup>1</sup> Hyperpigmentation of the oral

mucosa is a multifactorial event that can be physiological or pathological and influenced by a series of local or systemic factors such as genetics, tobacco use or long-term use of certain drugs such as antimalarial drugs or tricyclic antidepressants.<sup>2</sup>

Physiologic hyperpigmentation of the oral mucosa, especially the gums, is a multifocal or diffuse melanin pigmentation that has different prevalence in different race groups.<sup>3,4</sup> The physiological pigmentation of the gums is symmetrical and does not affect the normal structure of the gums. Melanin is made in the melanosome of melanocytes, which are usually located in the basal and supra-basal cell layers of the epithelium.<sup>5,6</sup> Melanocytes are equally present in the mucosa of all people (with dark and light skin), but melanocyte activity is higher in people with dark skin and in pigmented areas. Melanin-containing macrophages have also been observed in the superficial layers of the lamina propria of individuals with pigmented gums.<sup>7-9</sup>

Hyperpigmentation of the gingiva does not present a medical problem, although complaints of dark gums may pose an esthetic concern.<sup>10</sup>

There are various techniques for gingival depigmentation, including epithelial abrasion using a bur,<sup>11</sup> free gingival graft (FGG),<sup>12</sup> gingivectomy using scalpel surgery,<sup>13</sup> cryosurgery<sup>14</sup> and laser-assisted surgery.<sup>1,15,16</sup> Using lasers in dentistry dates back to the early 1980s.<sup>17</sup> Lasers have various applications in periodontics. For instance, they can be used to reduce dentin sensitivity,<sup>18</sup> adjuvant therapy in periodontitis,<sup>19</sup> photodynamic therapy,<sup>20</sup> retarding epithelial migration in periodontal surgery,<sup>21</sup> and various soft tissue surgeries.<sup>22</sup>

Gingival depigmentation by lasers is also known as an efficient and convenient technique.<sup>1</sup> Ease of work, short treatment time, hemostasis, and excellent coagulation are known as the benefits of lasers.<sup>23</sup>

Various lasers such as CO<sub>2</sub>, Nd:YAG, argon, diode, Er:YAG and Er, Cr:YSGG have been reported to be effective in removing gingival pigmentation.<sup>1,15,16,24,25</sup> Two successful strategies have been suggested for the use of lasers in gingival depigmentation, depending on the wavelength absorption specification. In the surgical/ablative approach, the gingival epithelium is vaporized with melanin. All surgical wavelengths could be utilized in this approach. The second approach is non-surgical or non-ablative, where a specific wavelength, such as visible diode laser (445 nm) and near-infrared diode laser (810 nm), degranulates the melanosomes or denatures the melanin without de-epithelization of the gingival epithelium.<sup>26</sup>

Diode lasers have received more attention due to their small size, ease of use, and availability. Laser light at 800-980 nm is poorly absorbed in water but is highly absorbed in hemoglobin and other pigments. Arif et al reported that 980-nm laser diodes were effective in removing gingival pigmentation.<sup>27,28</sup>

The CO<sub>2</sub> laser has been used in some studies for gingival depigmentation.<sup>29</sup> The CO<sub>2</sub> laser is another popular and available device in the clinical field. In animal studies, the effectiveness of this laser in depigmentation has been shown, and it has been used in human studies over time.<sup>16,30,31</sup> It seems that the use of this laser in gingival depigmentation due to greater absorption in surface layers and less risk of damage to deeper tissues is desirable.<sup>32</sup> Despite the low penetration of the CO<sub>2</sub> laser, it seems that the radiation of this laser on the surface of the gingival epithelium, due to its high absorption coefficient in tissue water, causes epithelial cells to be removed through the epithelial-peel technique, and it penetrates the basal layer and destroys pigment cells.<sup>16</sup>

Few studies have worked on different methods of gingival depigmentation in terms of efficacy, persistence, postoperative pain, and treatment satisfaction, and most of them are case report studies. There is a lack of controlled clinical trial studies in this area. In addition, few studies have investigated the effect of the CO<sub>2</sub> laser on the treatment of gingival depigmentation and compared it with other lasers. Different modes of radiation of this laser (super pulse, pulsed or continuous) have been used in previous studies, which have had different results. In the present study, we investigated and compared the effect of two types of 980-nm diode and CO<sub>2</sub> lasers on gingival depigmentation from different aspects.

## Materials and Methods

Participants in this study were selected by the convenience sampling method from those referred to the School of Dentistry of Isfahan University of Medical Sciences from 2019 to 2020. The study started after obtaining the approval of the university ethics committee and receiving the IRCT code with registration number IRCT20200309046728N1.

Individuals with physiological gingival pigmentation who complained of this problem in terms of cosmetic issues and who were systemically healthy were included in the study after the treatment process was explained to them and they signed the consent form. They were at a minimum age of 19 and at a maximum of 47 years (an average of 33 years). Exclusion criteria were systemic or local conditions that lead to hyperpigmentation, including Addison's disease, Albright syndrome, Peutz-Jegher syndrome, use of antimalarial or tricyclic antidepressants, and smoking, as well as untreated periodontal disease. Those with uncontrolled diabetes, pregnancy and lactation, and other diseases that interfere with wound healing were also excluded from the study.

The sample size with 95% confidence interval and 80% test power factor was obtained with at least 13 people. Finally, with consideration of a 20% drop, 16 people were included in the study.

In the first phase, scaling and root planning was performed one week before the surgery if needed. Clinical

photographs were taken before the surgery (Figure 1A) using a Canon 60-D digital camera (Canon Inc. Tokyo, Japan). To even out the digital camera images, it was set on a tripod and all images were taken with the same magnification (6x) with a focal length of 30 cm and with an adjustment of 1.200 seconds for the camera shutter. The central point of the image in the patient's midline was considered 5 mm more apical than the contact point of the teeth. A dental cheek retractor was used to pull the lips aside to make the gums (gingiva) appear better. In order to standardize the position of the patient's head, after they sat on the chair, the head was placed upright so that the line connecting the outer corner of the eye to the center of the tragus was parallel to the horizontal plane or ground floor. One and three months after the surgery, the images were taken in the same way after the treatment. To standardize the ambient light in all cases (patients), photography is done in day light between 12 and 13 o'clock in the same room. Based on the random number table, one maxillary quadrant was randomly treated with a diode laser, and the other quadrant was treated with a CO2 laser. This study was single-blind and it was not possible to blind the operator (primary investigator). After the injection of infiltration anesthesia with 2% lidocaine with 1: 100 000 epinephrine, each quadrant was treated with the laser depending on the group in which it was located. All operations were performed by one experienced laser therapist.

#### Group 1 (980 nm Diode Laser)

A 980 nm diode laser (ARC Laser GmbH, Nuremberg, Germany) with a power of 1.5 W with continuous wave (CW) was used. First, the fiber tip was initiated by using a dark articulating paper for 5 seconds. The fiber tip was then moved back and forth in contact with the tissue (contact mode) by brushing strokes in the cervico-apical direction and removing the gingival epithelium at a distance of one millimeter from the gingival margin. This was done to prevent possible gingival recession. In

addition, the fiber tip was cleaned regularly during the irradiation period.

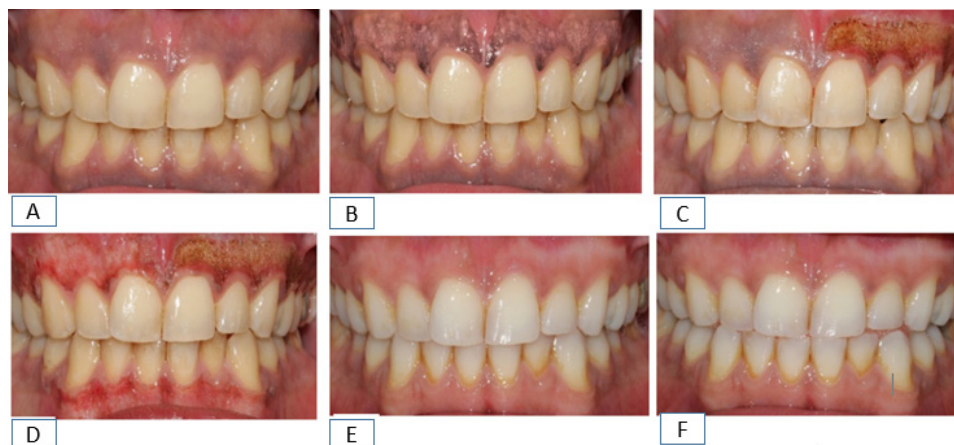#### Group 2 (CO2 Laser)

In this study, the CO2 laser with a wavelength of 10 600 nm (Daeshin, model DS-40U, Daeshin Corp. Seoul, Korea) and super pulse mode was used. Irradiation was in non-contact mode, defocused, with a 1.5 mm diameter beam and a spot size of approximately 1.5 mm. The laser tip was held perpendicular to the target area and was irradiated at a distance of 8 mm from the tissue surface. In this device, three default parameters of peak power, pulse duration and repeated time with different values were set for the super pulse mode. In this study, we used the following parameters for radiation:

- Peak power = 146 W
- Pulse duration = mode A / 1 ms
- Repeated time = 5 ms

Special glasses were used for each laser device to protect the eyes of both the clinician and the patient while working. Also, a smoke evacuator was used when The CO2 Laser was applied. The gingival epithelium was removed by using the epithelial-peel technique until the entire epithelium of the irradiated area was regularly peeled off by a moist gas.<sup>33</sup> The surgery was performed in one session by one clinician for each patient. In addition, to protect the quadrants against the scattered rays of the laser beam, a protector was placed on it with the help of putty paste.

Irradiation time in both 980nm and CO2 lasers depended on the severity and development of gingival pigmentation and continued until a melanin-pigment-free surface was created.<sup>16</sup> The operating time was calculated and recorded separately for each patient (from the beginning of laser radiation to the end of depigmentation). Also, to control the plaque, chlorhexidine mouthwash was prescribed for the patient every 12 hours for one week. Furthermore, the patients were told to take painkillers if there was uncontrollable pain.



**Figure 1.** (A) Initial image, (B) Initial image to calculate the area of the pigmented area, (C) Treatment of left maxillary quadrants with the diode laser, (D) Treatment of right maxillary and mandibular quadrants with the CO2 laser, (E) One-month follow-up photo and (F) Three-month follow-up photo

During the first 24 hours after the treatment, the patients were advised not to eat hot, spicy and hard foods and to avoid trauma for a week.

The patients came one week after the treatment to check for possible problems and ensure complete depigmentation. After that, each patient was re-evaluated at one and three months and a photograph was taken of the affected area (Figure 1E, 1F). Photographic images were qualitatively and quantitatively evaluated. Quantitative evaluation of digital photo analysis was obtained with the help of computer software. In addition, with the help of the oral pigmentation index, the severity of pigmentation was quantitatively assessed by a specialist. In addition, qualitative analysis was obtained by a questionnaire of patient and specialist satisfaction.

### Dummett Oral Pigmentation Index

Dummett oral pigmentation index (DOPI), in addition to the presence or absence of pigmentation, also determines its severity. According to digital photographs in each quadrant, the numbers of this index were obtained before the intervention and one month and three months after the intervention by a blinded specialist in relation to the treatment method in each quadrant. The images were shown to him under the same conditions by a monitor. In order to obtain this index, each area from the anterior maxilla (canine to the central of each quadrant) was divided into three areas, and each area was assigned a number from zero to 3 according to the following explanations<sup>34</sup>:

0=No pigment, 1=Light brown, 2=Medium brown or a mixture of brown and pink, 3=Severe clinical pigmentation

The mean numbers of the three regions were reported as the final quadrant index, which is divided into mild to severe gingival pigmentation groups according to the following classification<sup>34</sup>:

0= Absence of clinical pigmentation, 0.031-0.97= Mild gingival pigmentation, 1-1.9= Moderate gingival pigmentation, 2-3= Severe gingival pigmentation

### The Area of the Pigmented Area

The area of the pigmented area was obtained from digital images before the intervention and one month and three months after the intervention with the help of software

(Fij, Madison, WI) ImageJ after calibrating the software<sup>17</sup> (Figure 1B).

### Color Analysis Using Color Matching ( $\Delta E$ ) and RGB Code

In order to evaluate digital photos with the help of a computer, photographs before the intervention and one and three months after the treatment were processed in Photoshop software with the help of color code analysis (RGB Red, Green, Blue) and CIELAB system (Lab).<sup>35,36</sup> In the RGB code, a number between 0-255 is assigned to each of the red, green, and blue colors, and the combination of the three colors determines the final color that is displayed on the monitor. Ten points in each quadrant (within the pigmentation area and in the attached gingiva area) were randomly selected,<sup>37</sup> and the RGB index for each point was calculated, and then the mean of ten points was reported as the final RGB number in each quadrant. RGB numbers for these ten points were also calculated in one-month and three-month photographs.

Another color quantification was based on the CIELAB system and was expressed according to  $L^*$ ,  $a^*$  and  $b^*$  color parameters. The Lab system indicates the amount of light (l: 0-100), green (a: -), red (a: +), blue (b: -) and yellow (b: +). After random selection of an area in the part of the gingiva that underwent laser therapy,  $\Delta E^*$  (Color difference) was calculated between the values of that part and adjacent non-pigmented gingiva, at times of one and three months after the treatment process to study color matching. Color difference ( $\Delta E^*$ ) between the values of previously pigmented gingiva and adjacent non-pigmented gingiva was calculated by this equation:  $\Delta E^* = [(\Delta L^*)^2 + (\Delta a^*)^2 + (\Delta b^*)^2]^{1/2}$ .<sup>38</sup>

In order to obtain the numbers, related to the above analyses in Photoshop software, we used the color sampler tool and selected the dimensions of the dropper in the range of  $3 \times 3$ . To identify the selected points before the treatment and one and three months later (which were randomly selected in the first phase), we used a grade that we placed on the photos. In order to match this checkerboard exactly in the next photos, first a vertical reference line was drawn in contact between the central incisors, and the horizontal reference line was drawn tangentially to the coronal end of the midline papilla. The next horizontal and vertical lines were placed at a distance of 3 mm from these reference lines (Figure 2).

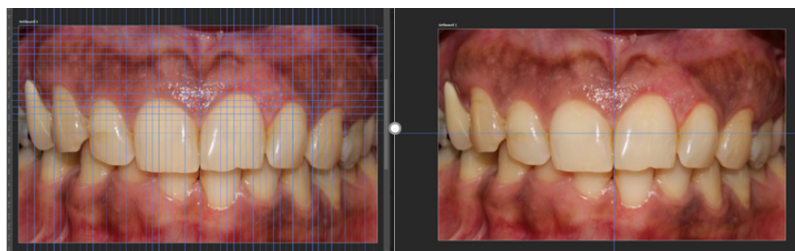


Figure 2. Drawing a Grid on the Photo

In the follow-up photos, the same point that was analyzed for color with the dropper tool in the original photo was re-selected and analyzed (Figures 3 and 4).

### Professional Evaluation of Cosmetic Outcomes

Preoperative and postoperative images were compared by a professional for the evaluation of esthetic outcomes in each quadrant separately. The evaluation was done by a blinded postgraduate student who was not involved in the therapeutic procedures, with the same monitor under the same conditions. Photographs were rated according to the professional evaluator's opinion for each quadrant, by one of the following categories: (1) poor, (2) average, (3) good, (4) very good, and (5) excellent.<sup>39</sup>

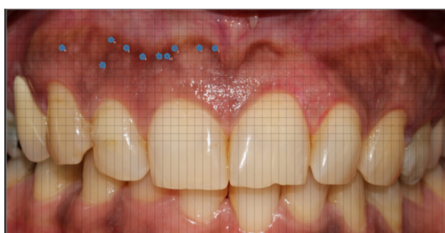
### Pain

The pain variable was assessed one hour, one day and one week after the treatment. This variable was evaluated based on the visual analog scale (VAS) which includes degrees 0 to 10. The patient was asked to express the amount of pain from the range of 0 to 10. Number 0 presented no pain, 0.01--3 mild pain, 3.01-6 moderate pain, and 6.01-10 severe pain.<sup>40</sup> The participants were also told to use acetaminophen 625 mg tablets if they felt pain or discomfort after the anesthetic wore out and to record the number of pills taken.

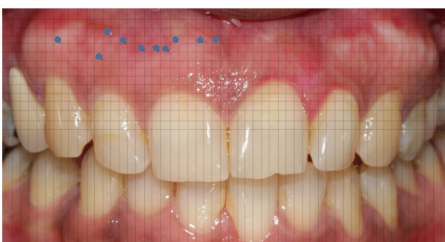
### Patient Satisfaction 3 Months After Treatment

At the end of three months, another questionnaire was given to the participants to determine their perceptions concerning the improvements in the esthetic features on each side separately.

The questionnaire used a simplified scale to record the satisfaction of treatment in terms of the esthetic features of the treated gingiva by selecting one of the following



**Figure 3.** Selection of 10 Spots in the Pigmentation Area in the Right Quadrant Before the Treatment



**Figure 4.** Re-selection of the Previous Points After the Treatment With the Help of a Checkerboard

choices: very satisfied, satisfied, neutral, moderately satisfied, or unsatisfied.<sup>39</sup> All questionnaires were analyzed by a person blinded to the type of laser used.

### Working Time

The working time was calculated and recorded in minutes immediately after the start of laser treatment in each group, from the beginning of treatment to the end of depigmentation.

In this study, image analysis and statistical analysis were performed by a researcher, blinded to the treatment method. However, it was impossible to make the therapist and the patient blinded to the study due to the different sizes of the two lasers, so our study was a single-blind study.

### Results

Sixteen eligible volunteers were included in the study, but two of them were excluded from the study due to not applying on time for the 3-month follow-up. Finally, 14 people with an age range of 19 to 47 with a mean age of 33 and a standard deviation of 8.5 years were studied. In each individual, one maxilla quadrant was treated with the CO<sub>2</sub> laser and the other quadrant was treated with the 980-diode laser. Eight subjects (57.1%) were female and 6 subjects (42.9%) were male.

### DOPI Index

The paired samples *t* test showed that the mean DOPI index before the treatment ( $P=0.30$ ) and three months after the treatment ( $P=0.19$ ) was not significantly different between the two groups. The mean DOPI index was exactly the same in both groups one month after the treatment. The Repeated Measures ANOVA test showed that the mean DOPI index in both groups was significantly different at different times ( $P<0.001$ ). The LSD post hoc test (Least Significant Difference) showed that the mean DOPI index in the diode laser group was significantly lower than that before the treatment one month ( $P<0.001$ ) and 3 months after the treatment ( $P<0.001$ ), but there was no significant difference between one month and 3 months after the treatment ( $P=0.08$ ). In the CO<sub>2</sub> laser group, the mean DOPI index was significantly lower than that before the treatment one month ( $P<0.001$ ) and three months after the treatment ( $P<0.001$ ), but there was no significant difference between one month and three months after the treatment ( $P=0.99$ ) (Table 1).

### Pigmentation Area

The paired samples *t* test showed no significant difference in the mean area of pigmentation before the treatment ( $P=0.73$ ), one month after the treatment ( $P=0.89$ ), and three months after the treatment ( $P=0.82$ ) between the two groups. The repeated measures ANOVA test showed that the mean area of pigmentation in both groups was significantly different between the three times ( $P<0.001$ ).

The least significant difference (LSD) post hoc test showed that the mean area of pigmentation in the diode laser group ( $P=0.14$ ) and in the CO2 laser group ( $P=0.12$ ) was not significantly different between one month and three months after the treatment. Nevertheless, in the post-treatment periods, it was significantly lower than that before the treatment ( $P<0.001$ ). (Table 2).

**RGB Code**

The paired samples *t* test showed that before the treatment, the mean values of red ( $P=0.52$ ), green ( $P=0.61$ ) and blue ( $P=0.22$ ) were not significantly different in the two groups. One month after the treatment, the values of red ( $P=0.51$ ), green ( $P=0.12$ ) and blue ( $P=0.13$ ) were not significantly different between the two groups. Three months after the treatment, the mean of none of the components of the RGB code was significantly different between the two groups ( $P>0.05$ ) (Table 3).

**Color Matching Analysis With the Help of ΔE**

The paired samples *t* test showed that the mean ΔE of one

**Table 1.** Mean DOPI Index at Different Times in the Two Groups

	Diode Laser		CO2 Laser		P Value
	Mean	SD	Mean	SD	
Before treatment	2.3	0.6	2.4	0.5	0.30
1 Month after treatment	0.23	0.06	0.23	0.07	1
3 Months after treatment	0.31	0.06	0.24	0.07	0.19
P value	<0.001		<0.001		-

**Table 2.** Mean Area of Pigmentation at Different Times in Two Groups

	Diode Laser		CO2 Laser		P Value <sup>a</sup>
	Mean	SD	Mean	SD	
Before treatment	4.53	2.15	4.47	2.26	0.73
1 Month after treatment	0.11	0.09	0.10	0.07	0.39
3 Months after treatment	0.13	0.09	0.12	0.06	0.82
P value <sup>b</sup>	<0.001		<0.001		---

<sup>a</sup> Paired samples *t* test.

<sup>b</sup> Repeated measures ANOVA test.

**Table 3.** RGB Code Changes in Follow Up Times

Color code	Time	Diode Laser		CO2 Laser		P Value
		Mean	SD	Mean	SD	
Red (R)	Before treatment	129.6	22.3	127.2	19.1	0.52
	1 month after	168.4	12.3	166.6	14.2	0.51
	3 months after	167.5	12	165.8	13.4	0.55
Green (G)	Before treatment	66.6	16.6	68.1	12.3	0.61
	1 month after	85.2	12.5	81.4	10.5	0.12
	3 months after	82.8	13.3	81.8	9.9	0.67
Blue (B)	Before treatment	58.5	15	61.6	13.6	0.22
	1 month after	77.3	13.4	73.5	10.9	0.13
	3 months after	76.4	13.7	73.7	10.4	0.27

month ( $P=0.36$ ) and also three months after the treatment ( $P=0.26$ ) was not significantly different between the two groups (Table 4).

**Specialist and Patient Satisfaction With the Treatment**

The Wilcoxon test showed that the level of specialist satisfaction was not significantly different between the two groups ( $P=0.56$ ). In addition, the levels of patient satisfaction were exactly the same in the two groups (Table 5).

**Working Time**

The paired samples *t* test showed that the mean duration of treatment in the CO2 laser group was significantly shorter than the diode laser group ( $P<0.001$ ) (Table 6).

**Pain**

The paired samples *t* test showed that the mean pain score was not significantly different between the two groups in any of the three times ( $P>0.05$ ) (Table 7).

**Discussion**

Many lasers have been used in various studies to

**Table 4.** Mean ΔE at Different Times in Two Groups

	Diode Laser		CO2 Laser		P Value
	Mean	SD	Mean	SD	
1 Month after treatment	5.6	1.9	6.3	2.2	0.36
3 months after treatment	6.8	2.2	7.7	2.2	0.26

**Table 5.** Frequency Distribution of Specialist and Patient Satisfaction Levels in the Two Groups

Variable	Satisfaction Level	Diode Laser		CO2 Laser		P Value
		No.	%	No.	%	
Specialist satisfaction	Good	2	14.3	2	14.3	0.56
	Very good	5	35.7	4	28.6	
	Excellent	7	50	8	57.1	
Patient satisfaction	Very satisfied	3	21.43	3	21.43	1
	satisfied	11	78.57	11	78.57	

**Table 6.** Mean Working Time of Treatment in the Two Groups

Variable	Diode Laser		CO2 Laser		P Value
	Mean	SD	Mean	SD	
Time duration	9.4	4	5	1.6	<0.001

**Table 7.** Mean Pain Score (According to VAS Criteria) at Different Times in Two Groups

	Diode Laser		CO2 Laser		P Value
	Mean	SD	Mean	SD	
1 hour after surgery	3.7	1.9	3.8	1.7	0.85
1 day after surgery	4	2.5	3.7	2.2	0.37
7 days after surgery	0.07	0.07	0	0	0.34

remove gingival hyperpigmentation. Choosing the most appropriate laser parameters is very important in terms of a better performance and fewer side effects. Therefore, comparing different types of lasers with each other can help us achieve this goal. In this study, we compared the 980 nm diode laser (1.5 W; CW) and the CO<sub>2</sub> laser (10600 nm, super pulse mode) in terms of efficiency in removing hyperpigmented gingival tissue, prevalence of repigmentation, postoperative pain, and satisfaction with treatment. The efficiency of the 980 nm diode laser has already been confirmed. In addition, its comparison with the scalpel technique shows comparable results in the removal of pigmented tissue.<sup>8,33,41</sup>

Nevertheless, the CO<sub>2</sub> laser has been less used in the treatment of gingival melanin depigmentation in human studies. Animal studies by Nakamura et al (6~8 W, pulse mode)<sup>42</sup> and Sharon et al (3 W, CW),<sup>31</sup> along with histological investigation in dogs, demonstrated the successful use of this laser in gingival depigmentation. Sharon et al reported that the use of the CO<sub>2</sub> laser (3 W, CW) was effective in eliminating the pigmented areas in oral mucosa, gingivae, and skin. No recurrence of melanin was detected in either the oral mucosa or gingiva at any of the follow-up times. In the skin, however, a small amount of melanin repigmentation was noticeable.<sup>31</sup> There are few studies on the successful effect of the CO<sub>2</sub> laser on the treatment of gingival depigmentation and its comparison with other lasers. In addition, different types of radiation modes of this laser (super pulse, pulse mode, CW) have been used in previous studies, which have had different results.<sup>16,17</sup> The present study is the first study to compare the effect of the 980 nm diode laser treating gingival depigmentation with CW mode and the CO<sub>2</sub> laser with super pulse mode. The results of this study showed that both types of lasers can be used successfully in the treatment of gingival pigmentation, so that in terms of pigmentation index parameters, professional evaluator opinion, color analysis and pain after treatment, no difference was observed between the two groups.

The DOPI index before the treatment indicated severe gingival pigmentation in both laser groups. This index showed mild gingival pigmentation one month and three months after the treatment. The difference in the index between the two groups was not statistically significant in any of the time periods (Table 1). Also, analyzing pigmentation areas showed no significant difference in the mean area of pigmentation before the treatment between the two groups (Table 2).

Digital image analysis to obtain RGB code was performed by using Photoshop software.<sup>36,37,43</sup> RGB values before and after depigmentation did not show a statistically significant change between diode and CO<sub>2</sub> laser groups (Table 3).

Comparison of the color matching of the treated pigmented area with the adjacent non-pigmented area

that has not been laser-irradiated is done by using the parameter  $\Delta E$ . Increasing  $\Delta E$  indicates more color difference, and consequently, less matching.<sup>35,44</sup>

L, a and b parameters were obtained from digital image processing using Photoshop software.<sup>35</sup> Mean  $\Delta E$  differences were not statistically significant one month and three months after the treatment between the two groups (Table 4). This result indicates that in the present study, which used both the CO<sub>2</sub> laser and the diode laser, the recurrence of gingival pigmentation did not occur after three months. However, previous reports indicated spontaneous gingival repigmentation at different intervals due to various possible causes, including the migration of melanocytes from the pigmented areas, adjacent to the treated area.<sup>13</sup>

According to Azzeq, due to the presence of rete peg in the oral epithelium, the removal of surface layers to a certain depth will not lead to the removal of all melanocytes.<sup>45</sup> Soliman et al (Diode 808 nm, 1-2 W, CW) believed that some underlying melanocytes were not sufficiently affected by the heat to be destroyed in their study.<sup>46</sup> Schroeder also attributed the reason for the return of pigmentation to the incomplete destruction of pigments, especially in the areas around the pigmented lesion.<sup>47</sup> Nakamura et al (CO<sub>2</sub> laser, 6-8 W, pulse mode) identified the papilla area as the most difficult area to remove pigmentation and reported that this area usually requires repeated laser irradiation. They attributed the reversal of hyperpigmentation to the increased activity of melanocytes in the area.<sup>16</sup> Esen et al believed that the removal of the pigmented area in the marginal and interdental papilla was more sensitive due to proximity to the tooth and fear of damage to tooth tissue or gingival resorption. They also believed that the reason for the repigmentation in these areas was more related to inadequate treatment in these areas.<sup>17</sup>

Therefore, in Esen and colleagues' study (CO<sub>2</sub> 10 W, super pulse mode), in addition to protecting the tooth surface to control radiation in these areas, they used a laser type with a smaller diameter. In that study, treatment was performed for all patients in one session, without the need for re-irradiation. They reported only two cases of pigmentation recurrence in people with a history of smoking.<sup>17</sup> In the present study, similar to the study of Esen et al, CO<sub>2</sub> laser super pulse mode was used for gingival depigmentation, but only non-smokers were included in the study. However, mild repigmentation was observed in the papilla area of some patients within three months (3 cases in the CO<sub>2</sub> laser-treated group and 1 case in the diode laser-treated group). Perhaps this result is related to the more controllable handpiece and the thinner fiber tip of the diode laser compared to the CO<sub>2</sub> laser, which allowed a more accurate removal of the range and depth of pigmentation in the papillary areas by the diode laser.

What we found in the present study while comparing the two types of lasers in terms of performance was that working with a diode laser was more controllable than a CO<sub>2</sub> laser, especially in the papillary areas close to the teeth. Sharon et al observed that the onset of mild repigmentation was in the marginal and papillary areas, adjacent to the lesion. In their view, due to the proximity of the gingival margin to the tooth, the lesser effect of the laser in this area was not far from the mind, and in the interdental papillary area, it was related to the migration of melanocytes from the palatal side. The researchers stated that the increase in pigmentation occurs only when the formation of the epithelium is complete.<sup>31</sup>

The perception of pain after surgery is a complex process and depends on environmental conditions and the physical and psychological characteristics of the individuals. Various studies have shown less postoperative pain in laser surgery groups than in blade surgery ones. This can be related to the formation of a coagulated protein layer on the surface of the epithelium that protects the wound as a biological dressing and blocks the end of the sensory nerves.<sup>8,33,48,49</sup>

The mean pain at intervals of one hour, one day and one week after surgery was not significantly different between the two groups, and based on the data obtained, it can be classified as moderate pain. Only one patient reported mild pain on the diode side after one week. None of the patients used painkillers after surgery. This finding is consistent with the results of studies by Hegde et al<sup>33</sup> and Esen et al.<sup>17</sup>

The comparison between the two lasers in terms of working time indicates a shorter CO<sub>2</sub> laser treatment time (Tables 4-6). Several possible reasons for this can be mentioned. The first reason is the use of decentralized CO<sub>2</sub> laser radiation, which was exposed to a wider surface during surgery, compared to the diode laser.

The second one is the need to regularly clean the fiber tip of the diode laser during surgery, which caused more time to be spent, compared to the CO<sub>2</sub> laser. The third reason, which may be more important than the other two, is the use of super pulse mode in this study. Esen et al used super pulse mode in their study and reported that they were able to depigment the epithelial surface in a very short time and during one session. They state that in super pulse mode, each pulse has a short duration (800 µs) and is high in energy. These researchers attributed the lack of need for CO<sub>2</sub> laser re-irradiation in therapeutic areas, and they reached the desired result during a session to the super-pulse state of the laser. They believe that this mode of laser reduces carbonization and heat damage to the tissue, leading to better vision and control of gingival tissue removal. Therefore, the optimal and sufficient treatment in a shorter time has been possible in one session, compared to CW.<sup>17</sup> In the Nakamura and colleagues' study, in which CW was used, about

3 to 5 sessions of treatment were needed to complete depigmentation.<sup>16</sup>

Moeintaghavi et al demonstrated that the degree of esthetics was significantly greater in both diode laser groups (810 nm, 6 W, pulsed mode and 3 W, CW) than the CO<sub>2</sub> laser group (10 600 nm, 3 W, CW).<sup>50</sup> Moreover, they reported that operative chair time was significantly shorter when using the diode laser in pulsed mode compared to the CO<sub>2</sub> laser and continuous mode of the diode laser. The CO<sub>2</sub> and diode laser parameters which they used in their study are different from ours, which can explain this difference in outcomes.

Concerning the cosmetic outcomes, the present trial revealed that both lasers promoted similar patient satisfaction when esthetics was considered. 78.57% of the patients in both groups of lasers expressed their satisfaction, which is consistent with other studies conducted on treatment satisfaction.<sup>38,44</sup> The professional evaluation of cosmetic improvements also demonstrated that the diode laser and the CO<sub>2</sub> laser achieved similar outcomes at 3-month follow-ups.

In this research, we tried to use both objective and subjective parameters to evaluate the cosmetic outcomes between the two lasers. We analyzed photos with the help of computer programs and used the opinions of the expert clinician and patients themselves. Also, for the first time, we prepared a grade on the photos (Figures 3 and 4) for a more precise selection of points in the Photoshop program in before and after treatment photos. Moreover, the DOPI index used in our study shows the intensity of pigmentation in addition to the presence or absence of pigmentation.

The split-mouth design of the study minimized the effect of interindividual variations on the outcomes. All operations were performed by one laser therapist to avoid different surgical skills that can affect the treatment results.

Finally, further studies are suggested to evaluate the effectiveness of these two types of lasers in gingival depigmentation. The follow-up period in this study was short (3 months) and the sample size was small, so we need studies with a larger sample size and a long-term follow-up to get more accurate results.

## Conclusion

According to the results of this study, both 980 nm diode (CW) and CO<sub>2</sub> (super pulse mode) lasers are effective in treating gingival depigmentation, and at the 3-month follow-up, the application of the diode laser (980 nm, CW) produced the same cosmetic outcomes as the CO<sub>2</sub> laser (10 600 nm, super pulse mode).

The mean pain at intervals of one hour, one day and one week after surgery was not significantly different between the two laser groups and can be classified as moderate pain.

CO<sub>2</sub> laser radiation with super pulse mode is faster in terms of surgery time, while working with the diode laser is more controllable.

#### Authors' Contribution

**Conceptualization:** Reza Birang.

**Data curation:** Samaneh Soltani.

**Formal analysis:** Smaneh Soltani, Sayed Mohsen Sadeghi.

**Methodology:** Ehsan Birang.

**Project administration:** Reza Birang.

**Resources:** Nafiseh Birang.

**Software:** Samaneh Soltani, Sayed Mohsen Sadeghi.

**Supervision:** Reza Birang, Jaber Yaghini.

**Writing—original draft:** Samaneh Soltani, Nafiseh Birang.

**Writing—review & editing:** Reza Fekrazad, Nasim Chiniforush.

#### Competing Interests

The authors report there are no competing interests to declare.

#### Ethical Approval

The study protocol was approved by Ethics Committee of Isfahan University of Medical Sciences.

#### Funding

This work was supported by Isfahan University of Medical Sciences under Grant number 398967.

#### References

- Tal H, Oegiesser D, Tal M. Gingival depigmentation by erbium:YAG laser: clinical observations and patient responses. *J Periodontol.* 2003;74(11):1660-7. doi: [10.1902/jop.2003.74.11.1660](https://doi.org/10.1902/jop.2003.74.11.1660).
- Aguirre A, Alawi F, Tapia JL. Pigmented Lesions of the Oral Mucosa. In: *Burket's Oral Medicine.* John Wiley & Sons; 2021. p. 139-69.
- Gulati N, Dutt P, Gupta N, Tyagi P. Gingival pigmentation: revisited. *J Adv Med Dent Sci Res.* 2016;4(1):48-57.
- Abdel Moneim RA, El Deeb M, Rabea AA. Gingival pigmentation (cause, treatment and histological preview). *Future Dent J.* 2017;3(1):1-7. doi: [10.1016/j.fdj.2017.04.002](https://doi.org/10.1016/j.fdj.2017.04.002).
- Çiçek Y, Ertaş U. The normal and pathological pigmentation of oral mucous membrane: a review. *J Contemp Dent Pract.* 2003;4(3):76-86.
- Dummett CO. Overview of normal oral pigmentations. *J Indiana Dent Assoc.* 1980;59(3):13-8.
- Kauzman A, Pavone M, Blanas N, Bradley G. Pigmented lesions of the oral cavity: review, differential diagnosis, and case presentations. *J Can Dent Assoc.* 2004;70(10):682-3.
- Grover HS, Dadlani H, Bhardwaj A, Yadav A, Lal S. Evaluation of patient response and recurrence of pigmentation following gingival depigmentation using laser and scalpel technique: a clinical study. *J Indian Soc Periodontol.* 2014;18(5):586-92. doi: [10.4103/0972-124x.142450](https://doi.org/10.4103/0972-124x.142450).
- Gondak RO, da Silva-Jorge R, Jorge J, Lopes MA, Vargas PA. Oral pigmented lesions: clinicopathologic features and review of the literature. *Med Oral Patol Oral Cir Bucal.* 2012;17(6):e919-24. doi: [10.4317/medoral.17679](https://doi.org/10.4317/medoral.17679).
- Gupta G. Management of gingival hyperpigmentation by semiconductor diode laser. *J Cutan Aesthet Surg.* 2011;4(3):208-10. doi: [10.4103/0974-2077.91256](https://doi.org/10.4103/0974-2077.91256).
- Roshannia B, Nourellahi M, Ahmadpanahi T, Norouzfard A, Shivaie Kojoori S. Comparison of bur abrasion and CO<sub>2</sub> laser in treatment of gingival pigmentation: 6 months follow-up. *Oral Health Prev Dent.* 2021;19:321-6. doi: [10.3290/j.ohpd.b1492771](https://doi.org/10.3290/j.ohpd.b1492771).
- Suryavanshi PP, Dhadse PV, Bhongade ML. Comparative evaluation of effectiveness of surgical blade, electrosurgery, free gingival graft, and diode laser for the management of gingival hyperpigmentation. *J Datta Meghe Inst Med Sci Univ.* 2017;12(2):133-7. doi: [10.4103/jdmimsu.jdmimsu\\_60\\_17](https://doi.org/10.4103/jdmimsu.jdmimsu_60_17).
- Murthy MB, Kaur J, Das R. Treatment of gingival hyperpigmentation with rotary abrasive, scalpel, and laser techniques: a case series. *J Indian Soc Periodontol.* 2012;16(4):614-9. doi: [10.4103/0972-124x.106933](https://doi.org/10.4103/0972-124x.106933).
- Kumar S, Bhat GS, Bhat KM. Comparative evaluation of gingival depigmentation using tetrafluoroethane cryosurgery and gingival abrasion technique: two years follow up. *J Clin Diagn Res.* 2013;7(2):389-94. doi: [10.7860/jcdr/2013/4454.2779](https://doi.org/10.7860/jcdr/2013/4454.2779).
- Atsawasuwan P, Greethong K, Nimmanon V. Treatment of gingival hyperpigmentation for esthetic purposes by Nd:YAG laser: report of 4 cases. *J Periodontol.* 2000;71(2):315-21. doi: [10.1902/jop.2000.71.2.315](https://doi.org/10.1902/jop.2000.71.2.315).
- Nakamura Y, Hossain M, Hirayama K, Matsumoto K. A clinical study on the removal of gingival melanin pigmentation with the CO<sub>2</sub> laser. *Lasers Surg Med.* 1999;25(2):140-7. doi: [10.1002/\(sici\)1096-9101\(1999\)25:2<140::aid-lsm7>3.0.co;2-7](https://doi.org/10.1002/(sici)1096-9101(1999)25:2<140::aid-lsm7>3.0.co;2-7).
- Esen E, Haytac MC, Oz IA, Erdoğan O, Karşli ED. Gingival melanin pigmentation and its treatment with the CO<sub>2</sub> laser. *Oral Surg Oral Med Oral Pathol Oral Radiol Endod.* 2004;98(5):522-7. doi: [10.1016/j.tripleo.2004.02.059](https://doi.org/10.1016/j.tripleo.2004.02.059).
- Yaghini J, Mogharehabed A, Safavi N, Mohamadi M, Ashtiju F. Evaluation of the effect of low-level laser therapy toothbrush in treatment of dentin hypersensitivity. *J Lasers Med Sci.* 2015;6(2):85-91.
- Birang R, Yaghini J, Nasri N, Noordeh N, Iranmanesh P, Saeidi A, et al. Comparison of Er:YAG laser and ultrasonic scaler in the treatment of moderate chronic periodontitis: a randomized clinical trial. *J Lasers Med Sci.* 2017;8(1):51-5. doi: [10.15171/jlms.2017.10](https://doi.org/10.15171/jlms.2017.10).
- Khan NS, Beegum F. Photodynamic therapy: a targeted therapy in periodontics. *Int J Laser Dent.* 2014;4(1):26-30.
- Israel M, Rossmann JA, Froum SJ. Use of the carbon dioxide laser in retarding epithelial migration: a pilot histological human study utilizing case reports. *J Periodontol.* 1995;66(3):197-204. doi: [10.1902/jop.1995.66.3.197](https://doi.org/10.1902/jop.1995.66.3.197).
- Masse JF, Landry RG, Rochette C, Dufour L, Morency R, D'Aoust P. Effectiveness of soft laser treatment in periodontal surgery. *Int Dent J.* 1993;43(2):121-7.
- Kathariya R, Pradeep AR. Split mouth de-epithelization techniques for gingival depigmentation: a case series and review of literature. *J Indian Soc Periodontol.* 2011;15(2):161-8. doi: [10.4103/0972-124x.84387](https://doi.org/10.4103/0972-124x.84387).
- Suthprasertporn S. Treatment of gingival melanin hyperpigmentation by Er,Cr:YSGG laser: report of 2 cases. *Thai J Periodontol.* 2007;1:46-55.
- Lagdive S, Doshi Y, Marawar PP. Management of gingival hyperpigmentation using surgical blade and diode laser therapy: a comparative study. *J Oral Laser Appl.* 2009;9(1):41-8.
- Muruppel AM, Jagadish Pai BS, Bhat S, Parker S, Lynch E. Laser-assisted depigmentation—an introspection of the science, techniques, and perceptions. *Dent J (Basel).* 2020;8(3):88. doi: [10.3390/dj8030088](https://doi.org/10.3390/dj8030088).
- Yousuf A, Hossain M, Nakamura Y, Yamada Y, Kinoshita J, Matsumoto K. Removal of gingival melanin pigmentation with the semiconductor diode laser: a case report. *J Clin Laser Med Surg.* 2000;18(5):263-6. doi: [10.1089/clm.2000.18.263](https://doi.org/10.1089/clm.2000.18.263).
- Arif RH, Kareem FA, Zardawi FM, Al-Karadaghi TS. Efficacy of 980 nm diode laser and 2940 nm Er:YAG laser in gingival depigmentation: a comparative study. *J Cosmet Dermatol.* 2021;20(6):1684-91. doi: [10.1111/jocd.13733](https://doi.org/10.1111/jocd.13733).
- Green HA, Margolis R, Boll J, Kochevar IE, Parrish JA, Oseroff

- AR. Unscheduled DNA synthesis in human skin after in vitro ultraviolet-excimer laser ablation. *J Invest Dermatol.* 1987;89(2):201-4. doi: [10.1111/1523-1747.ep12470562](https://doi.org/10.1111/1523-1747.ep12470562).
30. Nakamura Y, Funato A, Wakabayashi H, Matsumoto K. A study on the removal of the melanin pigmentation of dog gingiva by CO<sub>2</sub> laser irradiation. *J Clin Laser Med Surg.* 1992;10(1):41-6. doi: [10.1089/clm.1992.10.41](https://doi.org/10.1089/clm.1992.10.41).
31. Sharon E, Azaz B, Ulmansky M. Vaporization of melanin in oral tissues and skin with a carbon dioxide laser: a canine study. *J Oral Maxillofac Surg.* 2000;58(12):1387-93. doi: [10.1053/joms.2000.18272](https://doi.org/10.1053/joms.2000.18272).
32. Ozbayrak S, Dumlu A, Ercalik-Yalcinkaya S. Treatment of melanin-pigmented gingiva and oral mucosa by CO<sub>2</sub> laser. *Oral Surg Oral Med Oral Pathol Oral Radiol Endod.* 2000;90(1):14-5. doi: [10.1067/moe.2000.106396](https://doi.org/10.1067/moe.2000.106396).
33. Hegde R, Padhye A, Sumanth S, Jain AS, Thukral N. Comparison of surgical stripping; erbium-doped:yttrium, aluminum, and garnet laser; and carbon dioxide laser techniques for gingival depigmentation: a clinical and histologic study. *J Periodontol.* 2013;84(6):738-48. doi: [10.1902/jop.2012.120094](https://doi.org/10.1902/jop.2012.120094).
34. Dummett CO, Gupta OP. Estimating the epidemiology of oral pigmentation. *J Natl Med Assoc.* 1964;56(5):419-20.
35. Raoofi S, Asadinejad SM, Khorshidi H. Evaluation of color and width of attached gingiva gain in two surgical techniques: free gingival graft and connective tissue graft covered by thin mucosal flap, a clinical trial. *J Dent (Shiraz).* 2019;20(4):224-31. doi: [10.30476/dentjods.2019.44916](https://doi.org/10.30476/dentjods.2019.44916).
36. Amini Sedeh S, Badihi S, Esfahaniyan V. Comparison of recurrent rate of gingival pigmentation after treatment by liquid nitrogen and cryoprob in 18 months follows-up. *Dent Res J (Isfahan).* 2014;11(5):592-8.
37. Farahmand A, Moghareh Abed A, Mansouri Y. Clinical application of Er:YAG laser and cryosurgery in gingival depigmentation. *World J Dent.* 2016;5(2):102-8. doi: [10.5005/jp-journals-10015-1268](https://doi.org/10.5005/jp-journals-10015-1268).
38. Lee YK, Lim BS, Kim CW. Effect of surface conditions on the color of dental resin composites. *J Biomed Mater Res.* 2002;63(5):657-63. doi: [10.1002/jbm.10383](https://doi.org/10.1002/jbm.10383).
39. Ribeiro FV, Cavaller CP, Casarin RC, Casati MZ, Cirano FR, Dutra-Corrêa M, et al. Esthetic treatment of gingival hyperpigmentation with Nd:YAG laser or scalpel technique: a 6-month RCT of patient and professional assessment. *Lasers Med Sci.* 2014;29(2):537-44. doi: [10.1007/s10103-012-1254-5](https://doi.org/10.1007/s10103-012-1254-5).
40. Gupta G, Kumar A, Khatri M, Puri K, Jain D, Bansal M. Comparison of two different depigmentation techniques for treatment of hyperpigmented gingiva. *J Indian Soc Periodontol.* 2014;18(6):705-9. doi: [10.4103/0972-124x.147404](https://doi.org/10.4103/0972-124x.147404).
41. Kher U, Khan Z. Gingival depigmentation using the diode laser: three case reports. *Int J Laser Dent.* 2012;2(3):78-83.
42. Nakamura Y, Funato A, Wakabayashi H, Matsumoto K. A study on the removal of the melanin pigmentation of dog gingiva by CO<sub>2</sub> laser irradiation. 1992;10(1):41-6. doi: [10.1089/clm.1992.10.41](https://doi.org/10.1089/clm.1992.10.41).
43. Suragimath G, Lohana MH, Varma S. A split mouth randomized clinical comparative study to evaluate the efficacy of gingival depigmentation procedure using conventional scalpel technique or diode laser. *J Lasers Med Sci.* 2016;7(4):227-32. doi: [10.15171/jlms.2016.40](https://doi.org/10.15171/jlms.2016.40).
44. Berns R, Billmeyer F, Saltzman M. Measuring color. Billmeyer and Saltzman principles of color technology. New York: John Wiley; 2000.
45. Azzeh MM. Treatment of gingival hyperpigmentation by erbium-doped:yttrium, aluminum, and garnet laser for esthetic purposes. *J Periodontol.* 2007;78(1):177-84. doi: [10.1902/jop.2007.060167](https://doi.org/10.1902/jop.2007.060167).
46. Soliman MM, Al Thomali Y, Al Shammrani A, El Gazaerly H. The use of soft tissue diode laser in the treatment of oral hyper pigmentation. *Int J Health Sci (Qassim).* 2014;8(2):133-40. doi: [10.12816/0006079](https://doi.org/10.12816/0006079).
47. Schroeder HE. Melanin containing organelles in cells of the human gingiva. 3. Connective tissue cells. *Helv Odontol Acta.* 1969;13(1):46-55.
48. Kaarthikeyan G, Jayakumar ND, Padmalatha O, Varghese S, Kapoor R. Pain assessment using a visual analog scale in patients undergoing gingival depigmentation by scalpel and 970-nm diode laser surgery. *J Laser Dent.* 2012;20(1):20-3.
49. Fisher SE, Frame JW, Browne RM, Tranter RM. A comparative histological study of wound healing following CO<sub>2</sub> laser and conventional surgical excision of canine buccal mucosa. *Arch Oral Biol.* 1983;28(4):287-91. doi: [10.1016/0003-9969\(83\)90069-9](https://doi.org/10.1016/0003-9969(83)90069-9).
50. Moeintaghavi A, Ahrari F, Fallahrastegar A, Salehnia A. Comparison of the effectiveness of CO<sub>2</sub> and diode lasers for gingival melanin depigmentation: a randomized clinical trial. *J Lasers Med Sci.* 2022;13:e8. doi: [10.34172/jlms.2022.08](https://doi.org/10.34172/jlms.2022.08).