

Effect of Low-Level Laser Therapy on the Osseointegration of Immediately Loaded Implants with a Connective Tissue Graft: A Randomized Clinical Trial



Mohadese Momeni^{1*}, Malihe Safari², Arash Sarrafzadeh³, Ehsan Momeni^{4*}

¹School of Dentistry, Arak University of Medical Sciences, Arak, Iran

²Department of Biostatistics, School of Medicine Arak University of Medical Sciences, Arak, Iran

³School of Dentistry, Specialist of Oral and Maxillofacial Surgery, Arak University of Medical Sciences, Arak, Iran

⁴Department of Oral Medicine, School of Dentistry, Arak University of Medical Sciences, Arak, Iran

***Correspondence to**

Ehsan Momeni,
Email: momeni6384@gmail.com

Received: November 18, 2023

Accepted: April 21, 2024

ePublished: June 30, 2024

Abstract

Introduction: This study assessed the effect of low-level laser therapy (LLLT) on the osseointegration of immediately loaded implants with a connective tissue graft (CTG).

Methods: This clinical trial was conducted on patients with buccal bone dehiscence requiring dental implants. A CTG was harvested from the palate and placed in the labial side by considering the 2 mm distance between the implant thread and bone. Autogenous bone was harvested from the tuberosity, mixed with the allograft, and implanted at the site. After sufficient torquing of the implant, a customized abutment was fabricated and placed. The patients were randomly assigned to two groups (n=5) of intervention and control. The patients in the intervention group received LLLT with a 940 nm gallium-aluminum-arsenide laser while those in the control group received placebo irradiation. The primary implant stability was measured before the delivery of customized abutment while the secondary implant stability was measured after 12 weeks by Osstell® and reported as the implant stability quotient (ISQ).

Results: No significant difference was found in secondary ISQ between the laser and control groups ($P>0.05$). In the intervention group, a significant difference was found between the primary and secondary ISQ in the buccolingual dimension ($P<0.05$) but not in the mesiodistal dimension ($P>0.05$). The two groups had no significant difference in gingival thickness or vertical bone gain ($P>0.05$). All implants were successful with no complications.

Conclusion: LLLT had a significant positive efficacy for the enhancement of secondary stability of implants in the buccolingual dimension. CTG showed optimal efficacy for the treatment of buccal bone dehiscence.

Keywords: Dental implants; Immediate dental implant loading; Osseointegration; Low-level light therapy.



Introduction

Extraction is often indicated for teeth with irreparable caries or severely damaged teeth due to trauma. Replacement of the lost teeth depends on the amount of residual alveolar bone. Thus, a precise examination is imperative before and after tooth extraction to assess the possibility of using different treatment strategies such as dental implant placement.¹

Immediate loading (IL) is extensively used in implant treatment to decrease the treatment time. This technique eliminates the waiting time and enables using a temporary restoration after implant placement, and function of dental implant during the recovery period. The success of IL depends on several parameters such as primary stability, surgical technique, bone quality, underlying systemic diseases, number of implants, and occlusal forces. The primary stability of the implant is

an important parameter in IL, and resonance frequency analysis is the most commonly used method for the assessment of primary stability.

The enhancement of bone healing with physical stimuli such as ultrasound, low-level laser therapy (LLLT), and ozone therapy has gained increasing popularity in recent years. LLLT is a non-invasive modality with confirmed efficacy for the enhancement of bone healing.²

IL is challenging in the case of the presence of buccal bone dehiscence, which may be due to chronic inflammation following the vertical root fracture and its adverse effect on periodontal attachments, severe trauma, or chronic infection.³ Also, evidence shows that up to 50% of horizontal bone may be lost within 12 months following tooth extraction, and the highest change in ridge contour occurs in the first month after tooth extraction, which is statistically and clinically significant. The mean

ridge width reduction is 3 to 5 mm after 6 months. Buccal bone resorption may compromise the esthetic outcome of implant-supported restorations because the periodontium undergoes atrophy after tooth extraction. Changes are not limited to the hard and soft tissue contour and may include tissue discoloration due to the loss of the buccal bone plate. Thus, the preservation of the residual ridge contour and minimizing the destruction of the buccal bone plate are highly important, especially in the esthetic zone.⁴ Also, buccal bone thickness has been recognized as the most critical parameter in bone resorption and can serve as a prognostic factor for the detection of sites at risk of buccal bone loss after tooth extraction.⁵

Socket preservation methods can effectively decrease post-extraction ridge resorption. Bone augmentation and socket preservation techniques for implant placement often include the application of bone grafts with/without using a membrane. Several techniques have been proposed for this purpose; however, no gold standard exists regarding the best graft material or technique with/without the membrane.⁴ The connective tissue graft (CTG) can be used to replace a defective bone plate in periodontal regeneration surgery. It further stabilizes the clot and improves the outcome of regenerative treatments. Moreover, the optimal capacity of the connective tissue to firmly attach to the titanium surface with fibers oriented parallel to the implant surface, and also the optimal efficacy of connective tissue attachments for the prevention of sub gingival plaque accumulation has been well confirmed.¹

The potential of LLLT as an adjunct for the enhancement of bone regeneration has been the topic of many recent investigations.⁶ Low-level laser (LLL) refers to red or near infrared wavelengths between 600 to 1100 nm with low energy density.⁷ LLLT can biologically stimulate the tissues, regulate tissue responses such as angiogenesis, inflammation, cell proliferation, and cell differentiation, and accelerate the healing course in vitro and in vivo.⁸⁻¹⁰ LLLT induces the cytokines and growth factors responsible for the proliferation and migration of fibroblasts and enhances bone regeneration as such. It also accelerates angiogenesis and induces the differentiation of mesenchymal cells to osteoblasts and their subsequent attachment to the implant surface.¹¹

The results regarding the effects of LLLT on the osseointegration of dental implants have been controversial. Some authors reported its positive effect for the improvement of osseointegration¹² while some others reported no significant effect.¹¹ Thus, this study aimed to assess the effect of LLLT on the osseointegration of immediately loaded implants in cases with buccal bone dehiscence (Elia's class II and III)¹³ with a CTG.

Methods

This study was conducted at the Oral Medicine

Department of the School of Dentistry, Arak University of Medical Sciences, between August 2022 and January 2023. The study protocol was approved by the ethics committee of the university (IR.ARAKMU.REC.1400.321) and registered in the Iranian Registry of Clinical Trials (identifier: IRCT20220517054888N1).

Trial Design

A double-blind randomized controlled clinical trial was designed. In this trial, the intervention group received LLLT after immediate implantation and IL while the control group received placebo irradiation. The results were reported in accordance with the guidelines of the Consolidated Standards of Reporting Trials.

Participants, Eligibility Criteria, and Settings

The inclusion criteria were patients requiring the extraction of anterior or premolar teeth and subsequent immediate implantation, patients having buccal bone dehiscence class II and III according to Elia's classification,¹³ patients with no systemic diseases such as diabetes mellitus, endocrine conditions such as hyperthyroidism, cardiovascular diseases contraindicating surgery, and autoimmune diseases, patients with no chronic intake of steroidal and non-steroidal analgesics, patients with no infectious diseases such as AIDS, patients with no soft or hard tissue healing impairments, patients with no metabolic bone diseases such as osteoporosis, and patients willing to participate in the study.

The exclusion criteria were active infections, dentoalveolar pathologies or cysts at the implant site, and the presence of > 4 mm distance between the bone crest and interproximal bone.

The sample consisted of 10 patients requiring tooth extraction and immediate implantation.

Interventions

Written informed consent was obtained from all the patients. After tooth extraction, dental implants (AnyRidge; MegaGen Implants Co. Ltd. Daegu, South Korea) with the X-speed surface were placed 1 mm subcrestally relative to the palatal cortex according to the drilling protocol recommended by the manufacturer. The CTG was harvested from the palate and placed at the labial surface by observing the 2 mm distance between the implant thread and bone. The Medesy tunneling instrument was used to create a split thickness tunnel at the interval of the gingival margin and mucogingival line, and the CTG was fixed in a desired apico-coronal position. Autogenous bone was harvested from the tuberosity by using a trephine bur and mixed with allograft material (Cenobone, Hammanad Saz Baft Kish Co., Iran) with 150-500 µm particle size. The allograft particles were hydrated for 30 minutes by immersing them in normal saline. Subsequently, the hydrated allograft was mixed

with autograft particles. A fine elevator was used to acquire a 1 mm space between the thread and labial flap, which was filled with a bone graft. The implants were then torqued to at least 45 N/cm, and then a customized abutment was fabricated for the patients' chairside using a polyether ether ketone abutment and flowable composite (Fildent, Dental world c., Italy). The patients were then randomly assigned to two groups of intervention and control (n=5). The patients in the intervention group underwent LLLT with a gallium-aluminum-arsenide laser with a 940 nm wavelength (Biolase MD, USA) in continuous mode, 90 J total energy (5 J at each contact point), 10 seconds of irradiation time at each point, and 500 mW laser power. A total of 18 points in the buccal and lingual surfaces were irradiated. Placebo light was used in the control group. Open-tray impressions were made by addition silicone impression material (Elsodent, Harmony, France) and poured with Vel-Mix dental stone. Soft gingival masks (Nova) were placed on the cast for the respective measurements.

Implant stability was measured for the first time prior to the delivery of customized abutment. The Osstell® device (Osstell USA, Linthicum, MD, USA) was used for the measurement of implant stability quotient (ISQ), and its transducer was tightened with 10 N/cm torque. Implant stability was measured three times, and the mean value was calculated and recorded as baseline (primary) implant stability. Implant stability was measured again after 12 weeks and recorded as secondary implant stability.

Gingival thickness was measured by an electronic caliper (Lwanson Decimal Caliper, Asa Dental) with 0.1 mm accuracy (in millimeters) immediately after the procedure and also after 12 weeks using the impression obtained by the open-tray technique.

Gingival height was measured by a probe (Probe Corp. Gainesville FL, USA) immediately after the procedure and also after 12 weeks.

Periapical radiographs were obtained in a parallel position immediately after the procedure and also after 12 weeks, and crestal bone height was measured on the radiographs. Finally, a cement-retained implant-supported restoration was delivered to the patients.

The success of implants was finally evaluated based on the presence/absence of pain, mobility, bone loss, and puss by using Table 1.¹⁴ Side effects such as dehiscence, infection, mobility of a healing abutment, and thread exposure were also recorded.

Outcomes (Primary and Secondary)

The main objective of this study was to assess the effect of LLLT on the stability of immediately loaded implants and gingival thickness. Soft tissue thickness, gingival height, and implant success were the secondary outcomes. The soft tissue thickness was measured like gingival thickness;

Table 1. Implant Success Criteria

Implant Quality Scale	Clinical Conditions
Success (optimum health)	No pain or tenderness upon function
	No mobility
	<2 mm radiographic bone loss since the initial surgery
	No history of exudates
Satisfactory survival	No pain on function
	No mobility
	2–4 mm radiographic bone loss
	No history of exudates
Compromised survival	May have sensitivity on function
	No mobility
	Radiographic bone loss >4 mm (less than 1/2 of implant body)
	Probing depth >7 mm
	May have a history of exudates
Failure (clinical or absolute failure)	Uncontrolled exudate
	No longer in mouth
	Mobility
	Pain on function
	Radiographic bone loss >1/2 length of implant

however, after the grafting procedure, it was hypothesized that some allografts may migrate and be encapsulated.

Sample Size Calculation

Due to the absence of a similar previous study, a pilot study was carried out and the sample size was calculated to be 10.

Interim Analyses and Stopping Guidelines

No interim analyses were performed and no stopping guidelines were established.

Randomization

Randomization was done by using 4 blocks: AABB, ABAB, BBAA, and BABA. The selection of these blocks was carried out by using sealed and unspecified envelopes (black), and the sequence was performed according to the selected envelope.

Blinding

The patients were blinded to the use of laser or placebo. In addition, the examiner who measured the implant stability and secondary outcomes was blinded to the group allocation of patients.

Statistical Analysis

The normal distribution of data was evaluated by the Kolmogorov-Smirnov test. According to the results, the two groups were compared regarding normally distributed variables by the independent t-test and non-

normally distributed variables by the Mann-Whitney test. The two groups were compared by the chi-square test. All statistical analyses were carried out by SPSS version 24. A P value < 0.05 was defined as statistically significant.

Results

Participant Flow

The sample consisted of 10 patients (seven females & three males) with a mean age of 41.3 years. Three implants were placed in the upper lateral incisors, four implants in the upper premolars, and three implants in the lower premolars. Figure 1 shows the CONSORT flow diagram of patient selection and allocation.

Harms

No patients were harmed during the study.

Subgroup Analyses

Primary Outcome

Implant stability: Table 2 presents the mean primary and secondary stability of dental implants mesiodistally and buccolingually and gingival thickness in the two groups. Within-group comparisons showed that in the laser group, the primary and secondary ISQ were not significantly different in the mesiodistal dimension ($P=0.19$). However, in the buccolingual dimension, the secondary ISQ was significantly higher than the primary ISQ ($P=0.02$). The primary and secondary ISQ in mesiodistal and buccolingual directions were significantly different neither in the laser group nor in the control group ($P>0.05$). Between-group comparisons showed no significant difference in primary ISQ in the mesiodistal dimension ($P=0.11$), secondary ISQ in the mesiodistal dimension ($P=0.83$), primary ISQ in the buccolingual dimension ($P=0.17$), or secondary ISQ in

the buccolingual dimension ($P=0.83$) between the laser and control groups.

Gingival thickness: As demonstrated in Table 2, within-group comparisons showed that the primary and secondary gingival thicknesses were significantly different neither in the intervention group ($P=0.58$) nor in the control group ($P=0.53$). Between-group comparisons showed no significant difference in primary gingival thickness ($P=0.99$) or secondary gingival thickness ($P=0.65$) between the laser and control groups.

Secondary Outcome

Gingival height: No significant difference was found in vertical bone gain between the two groups ($P=1$).

Table 2. Mean Primary and Secondary Implant Stability (ISQ) and Gingival Thickness in the Intervention and Control Groups (n = 5)

Group			Mean	Standard Deviation	Statistic	P Value
Intervention (laser)	ISQ	Primary	70.20	3.42	-1.5	0.19
		MD Secondary	73.80	6.34		
	ISQ	Primary	68.20	3.49	-2.64	0.02
		BL Secondary	73.80	6.34		
	Gingival thickness	Primary	3.00	0.00	0.59	0.58
		Secondary	2.80	0.76		
Control	ISQ	Primary	73.00	3.39	-0.8	0.46
		MD Secondary	74.60	4.83		
	ISQ	Primary	71.60	4.28	-1.19	0.29
		BL Secondary	73.60	6.27		
	Gingival thickness	Primary	3.00	0.00	0.67	0.53
		Secondary	2.72	0.93		

MD: Mesiodistally; BL: Buccolingually.

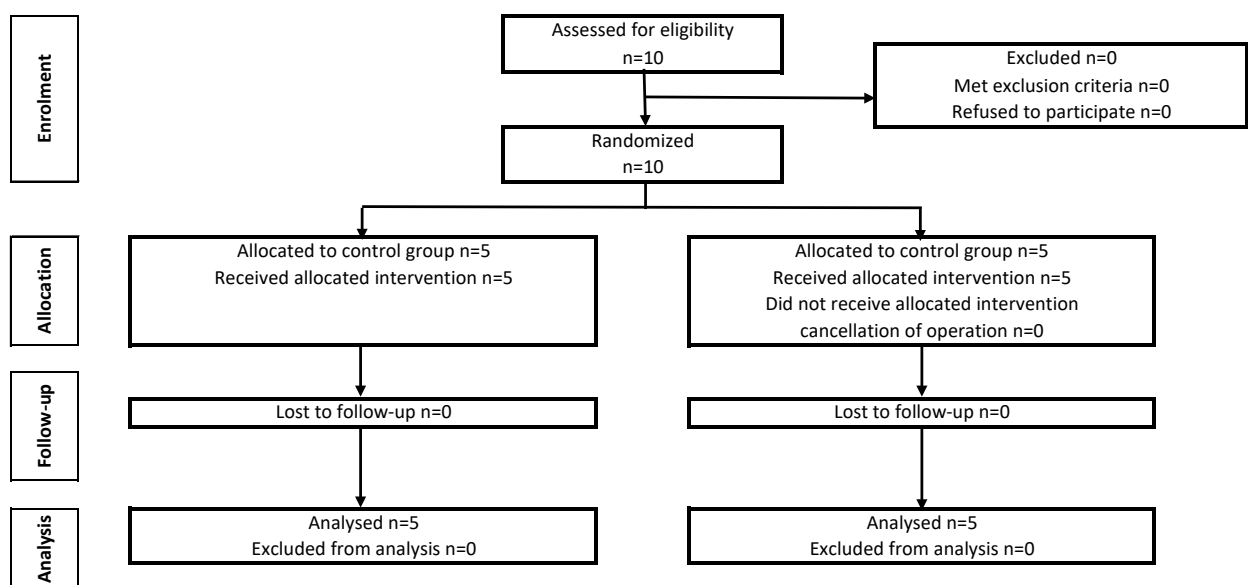


Figure 1. CONSORT Flow Diagram of Patient Selection and Allocation

Discussion

This study assessed the effect of LLLT on the osseointegration of immediately loaded implants in cases with buccal bone dehiscence (Elian's class II and III) [13] with a CTG. The results showed no significant difference in secondary ISQ between the laser and control groups. However, the secondary ISQ was significantly higher than the primary ISQ in the buccolingual dimension in the laser group. No significant change in ISQ was noted in the control group. The two groups had no significant difference in gingival thickness and vertical bone gain. The higher efficacy of LLLT in the buccolingual dimension, compared with the mesiodistal dimension, in the present study may be due to the use of the LLL hand-piece, which does not allow close irradiation of mesial and distal surfaces. Thus, buccal and lingual surfaces were irradiated more efficiently. Also, the implants (Anyridge) used in the present study had an X-speed surface which enhances osseointegration and may have a synergistic effect with LLLT. Furthermore, this implant type has knife-edge threads about 1 mm and is placed subcrestally, which further stabilizes the lingual cortex and implant. In ideal bone conditions, this implant gains sufficient stability for loading of permanent restoration within 4 weeks. In the present study, the integration time was considered to be 3 months for graft maturation. Thus, implant stability was pleasant with a mean ISQ of over 70.

Although LLLT or photobiomodulation has been suggested for the enhancement of peri-implant bone quality and acceleration of bone healing,^{15,16} some authors reported its positive effect on osseointegration¹² and some others refuted such an effect.¹¹ Lopes et al¹⁶ reported that LLLT enhanced peri-implant bone healing. LLLT has anti-inflammatory effects, induces the absorption of ascorbic acid by the cells, and activates lymphocytes and mast cells.¹⁷ It also induces the differentiation of undifferentiated mesenchymal cells to osteoblasts and accelerates their differentiation to osteocytes. Furthermore, it induces angiogenesis and collagen synthesis and enhances bone healing as such.¹⁸ LLLT enhances the production of mitochondrial ATP, RNA, and DNA, protein synthesis, and release of growth factors and cytokines. It enhances the production of calcium phosphate and bone matrix and its mineralization, which may positively affect osseointegration.^{16, 19}

Osteoblasts better absorb laser energy in near infrared wavelengths.^{15,20-22} Gene expression analysis shows that irradiation of a 980 nm diode laser decreases the number of inflammatory cells and enhances bone regeneration by inducing the proliferation of fibroblasts and osteoblasts.²¹ Jakse et al²³ evaluated the effect of LLLT on sinus floor augmentation and implant placement in a sheep model. They reported that despite the insignificant effect of LLLT on bone regeneration, the bone-implant contact area significantly increased in the LLL group.

Rasouli Ghahroudi et al²⁴ found that LLLT of xenograft material enhanced the regeneration of bone defects. The application of LLLT in combination with Bio-Oss improved bone healing, and it may be efficacious for the clinical regeneration of bone defects. In a review study, Zein et al¹⁹ showed the positive effect of LLLT on bone regeneration while adopting a specific dosage/output power protocol. They added that a high dosage combined with low power or a low dosage combined with high power had a positive effect on bone regeneration. The adopted laser parameters, sample size, and frequency of irradiations can affect the results and explain the reported controversy in the literature regarding the efficacy of LLLT for the enhancement of bone regeneration. In the present study, LLLT was performed for only one session immediately after implant placement and minimum laser energy was used. However, Karaca et al² evaluated the effect of LLLT on the osseointegration of immediate implants. They irradiated a gallium-aluminum-arsenide diode laser with an 830 nm wavelength, 86 ± 2 mW laser power, 0.0028 cm^2 spot size, 92.1 J/cm^2 energy density, 0.25 J energy at each spot, and 3 seconds of irradiation time at each point. The total energy was 5 J, and 20 points were irradiated after the procedure. LLLT was repeated once every 2 days for 2 weeks. The overall 6-month survival rate of dental implants was 92%, and they reported significantly higher ISQ in the LLLT group, compared with the control group.

Vertical bone gains as determined by using a probe and palpation of crestal bone revealed bone regeneration to the level of platform in all the patients in the present study. Due to ethical reasons and according to the "as low as reasonably achievable" principle, postoperative cone-beam computed tomography scans were not obtained in the present study. However, periapical radiographs confirmed mesiodistal bone regeneration to the level of the platform.

In the present study, the primary and secondary gingival thicknesses were significantly different neither in the laser group nor in the control group. Nonetheless, thread exposure did not occur in any case either, and the metallic shadow of porcelain-fused-to-metal restorations did not appear through the gingiva, indicating optimal soft tissue status around the implant cuff. Furthermore, all implants had optimal health status according to Misch's table and had no complications.¹⁴

In the present study, the authors tried to minimize the effect of confounders on implant success and osseointegration by standardization of factors such as surgical technique, materials used, and height and diameter of dental implants between the two groups. Accordingly, all patients underwent the same surgical protocol by the same surgical team. All cases had 4 mm buccal bone defects with a sound palatal cortex and normal gingival zenith categorized as Elian's class II and

III.¹³

A small sample size and LLLT for only one session and with only one protocol were among the limitations of this study. Future studies with a larger sample size are required on different protocols of LLLT and higher frequency of sessions to more precisely assess the effects of LLLT on implant osseointegration. Also, longer follow-ups are required to assess the soft tissue changes and possible gingival recession after soft tissue regeneration.

Conclusion

LLLT had a significant positive efficacy for the enhancement of secondary stability of implants in the buccolingual dimension. CTG showed optimal efficacy for the treatment of buccal bone dehiscence.

Acknowledgments

We would like to thank the Vice-Chancellor of Research and Technology, Arak University of Medical Sciences, for the approval and support of the study.

Authors' Contribution

Conceptualization: Ehsan Momeni, Arash Sarrafzadeh, Mohadese Momeni.

Data curation: Mohadese Momeni.

Formal analysis: Malihe Safari.

Funding acquisition: Ehsan Momeni.

Investigation: Mohadese Momeni, Ehsan Momeni.

Methodology: Ehsan Momeni, Arash Sarrafzadeh.

Project administration: Mohadese Momeni, Ehsan Momeni.

Resources: Ehsan Momeni.

Software: Malihe Safari.

Supervision: Ehsan Momeni, Arash Sarrafzadeh.

Validation: Ehsan Momeni, Arash Sarrafzadeh.

Visualization: Mohadese Momeni.

Writing—original draft: Ehsan Momeni, Malihe Safari, Mohadese Momeni.

Writing—review & editing: Ehsan Momeni, Malihe Safari, Arash Sarrafzadeh.

Competing Interests

No conflict of interest is declared.

Ethical Approval

The study was approved by the ethics committee of Arak University of Medical Sciences (No. IR. ARAKMU.REC. 1400.321).

Funding

This research was supported by grant from the Arak University of Medical Sciences.

References

1. Tirone F, Genovesi F. Immediate implant placement and loading in the esthetic area when the buccal socket wall is significantly damaged. *J Esthet Restor Dent*. 2021;33(4):542-9. doi: [10.1111/jerd.12707](https://doi.org/10.1111/jerd.12707).
2. Karaca IR, Ergun GU, Ozturk DN. Is low-level laser therapy and gaseous ozone application effective on osseointegration of immediately loaded implants? *Niger J Clin Pract*. 2018;21(6):703-10. doi: [10.4103/njcp.njcp_82_17](https://doi.org/10.4103/njcp.njcp_82_17).
3. Sarnachiaro GO, Chu SJ, Sarnachiaro E, Gotta SL, Tarnow DP. Immediate implant placement into extraction sockets with labial plate dehiscence defects: a clinical case series. *Clin Implant Dent Relat Res*. 2016;18(4):821-9. doi: [10.1111/cid.12347](https://doi.org/10.1111/cid.12347).
4. Tan-Chu JH, Tuminelli FJ, Kurtz KS, Tarnow DP. Analysis of buccolingual dimensional changes of the extraction socket using the "ice cream cone" flapless grafting technique. *Int J Periodontics Restorative Dent*. 2014;34(3):399-403. doi: [10.11607/prd.1605](https://doi.org/10.11607/prd.1605).
5. Chappuis V, Araújo MG, Buser D. Clinical relevance of dimensional bone and soft tissue alterations post-extraction in esthetic sites. *Periodontol* 2000. 2017;73(1):73-83. doi: [10.1111/prd.12167](https://doi.org/10.1111/prd.12167).
6. Kim YD, Kim SS, Hwang DS, Kim SG, Kwon YH, Shin SH, et al. Effect of low-level laser treatment after installation of dental titanium implant-immunohistochemical study of RANKL, RANK, OPG: an experimental study in rats. *Lasers Surg Med*. 2007;39(5):441-50. doi: [10.1002/lsm.20508](https://doi.org/10.1002/lsm.20508).
7. de Freitas LF, Hamblin MR. Proposed mechanisms of photobiomodulation or low-level light therapy. *IEEE J Sel Top Quantum Electron*. 2016;22(3):7000417. doi: [10.1109/jstqe.2016.2561201](https://doi.org/10.1109/jstqe.2016.2561201).
8. Stanford C, Oates T, Beirne R, Ellingsen JE. Thematic abstract review: effects of low-level laser treatment on bone regeneration and osseointegration of dental implants. *Int J Oral Maxillofac Implants*. 2007;22(5):691-5.
9. Markovic A, Kokovic V, Todorovic L. The influence of low-power laser on healing of bone defects: an experimental study. *J Oral Laser Appl*. 2005;5(3):169-72.
10. Pinheiro AL, Gerbi ME. Photoengineering of bone repair processes. *Photomed Laser Surg*. 2006;24(2):169-78. doi: [10.1089/pho.2006.24.169](https://doi.org/10.1089/pho.2006.24.169).
11. Khadra M, Lyngstadaas SP, Haanaes HR, Mustafa K. Effect of laser therapy on attachment, proliferation and differentiation of human osteoblast-like cells cultured on titanium implant material. *Biomaterials*. 2005;26(17):3503-9. doi: [10.1016/j.biomaterials.2004.09.033](https://doi.org/10.1016/j.biomaterials.2004.09.033).
12. García-Morales JM, Tortamano-Neto P, Todescan FF, de Andrade JC Jr, Marotti J, Zezell DM. Stability of dental implants after irradiation with an 830-nm low-level laser: a double-blind randomized clinical study. *Lasers Med Sci*. 2012;27(4):703-11. doi: [10.1007/s10103-011-0948-4](https://doi.org/10.1007/s10103-011-0948-4).
13. Elian N, Cho SC, Froum S, Smith RB, Tarnow DP. A simplified socket classification and repair technique. *Pract Proced Aesthet Dent*. 2007;19(2):99-104.
14. Misch CE, Perel ML, Wang HL, Sammartino G, Galindo-Moreno P, Trisi P, et al. Implant success, survival, and failure: the International Congress of Oral Implantologists (ICOI) Pisa Consensus Conference. *Implant Dent*. 2008;17(1):5-15. doi: [10.1097/ID.0b013e3181676059](https://doi.org/10.1097/ID.0b013e3181676059).
15. Pinheiro AL, Martinez Gerbi ME, de Assis Limeira F Jr, Carneiro Ponzi EA, Marques AM, Carvalho CM, et al. Bone repair following bone grafting hydroxyapatite guided bone regeneration and infra-red laser photobiomodulation: a histological study in a rodent model. *Lasers Med Sci*. 2009;24(2):234-40. doi: [10.1007/s10103-008-0556-0](https://doi.org/10.1007/s10103-008-0556-0).
16. Lopes CB, Pinheiro AL, Sathaiiah S, Duarte J, Cristinamartins M. Infrared laser light reduces loading time of dental implants: a Raman spectroscopic study. *Photomed Laser Surg*. 2005;23(1):27-31. doi: [10.1089/pho.2005.23.27](https://doi.org/10.1089/pho.2005.23.27).
17. Conlan MJ, Rapley JW, Cobb CM. Biostimulation of wound healing by low-energy laser irradiation. A review. *J Clin Periodontol*. 1996;23(5):492-6. doi: [10.1111/j.1600-051x.1996.tb00580.x](https://doi.org/10.1111/j.1600-051x.1996.tb00580.x).
18. Islam N. Effects of low-level laser (Diode-830 nm) therapy on-human bone regeneration [dissertation]. Bangladesh: Suhrawardy Med Coll Hosp; 2010.
19. Zein R, Selting W, Benedicenti S. Effect of low-level laser

- therapy on bone regeneration during osseointegration and bone graft. *Photomed Laser Surg.* 2017;35(12):649-58. doi: [10.1089/pho.2017.4275](https://doi.org/10.1089/pho.2017.4275).
20. Martinez Gerbi ME, Marques AM, Ramalho LM, Ponzi EA, Carvalho CM, de Carneiro Santos R, et al. Infrared laser light further improves bone healing when associated with bone morphogenic proteins: an in vivo study in a rodent model. *Photomed Laser Surg.* 2008;26(1):55-60. doi: [10.1089/pho.2007.2026](https://doi.org/10.1089/pho.2007.2026).
 21. Park JJ, Kang KL. Effect of 980-nm GaAlAs diode laser irradiation on healing of extraction sockets in streptozotocin-induced diabetic rats: a pilot study. *Lasers Med Sci.* 2012;27(1):223-30. doi: [10.1007/s10103-011-0944-8](https://doi.org/10.1007/s10103-011-0944-8).
 22. Fekrazad R, Sadeghi Ghuchani M, Baghaban Eslaminejad M, Taghiyar L, Kalhori K, Pedram MS, et al. The effects of combined low level laser therapy and mesenchymal stem cells on bone regeneration in rabbit calvarial defects. *J Photochem Photobiol B.* 2015;151:180-5. doi: [10.1016/j.jphotobiol.2015.08.002](https://doi.org/10.1016/j.jphotobiol.2015.08.002).
 23. Jakse N, Payer M, Tangl S, Berghold A, Kirmeier R, Lorenzoni M. Influence of low-level laser treatment on bone regeneration and osseointegration of dental implants following sinus augmentation. An experimental study on sheep. *Clin Oral Implants Res.* 2007;18(4):517-24. doi: [10.1111/j.1600-0501.2007.01369.x](https://doi.org/10.1111/j.1600-0501.2007.01369.x).
 24. Rasouli Ghahroudi AA, Rokn AR, Kalhori K, Khorsand A, Pournabi A, Pinheiro AL, et al. Effect of low-level laser therapy irradiation and Bio-Oss graft material on the osteogenesis process in rabbit calvarium defects: a double-blind experimental study. *Lasers Med Sci.* 2014;29(3):925-32. doi: [10.1007/s10103-013-1403-5](https://doi.org/10.1007/s10103-013-1403-5).