



# Photobiomodulation Therapy for Managing Motor and Sensory Dysfunctions Following Temporomandibular Joint Surgery: A Case Report

Luiz Felipe Palma<sup>1\*</sup>, Thales dos Santos Porfírio<sup>2</sup>, Rafael Verardi Serrano<sup>2</sup>, Luana Campos<sup>3</sup>, Luís Otávio Carvalho de Moraes<sup>1,4</sup>

<sup>1</sup>Department of Pathology, Federal University of São Paulo, São Paulo, SP, Brazil

<sup>2</sup>Graduate Program in Dentistry, Ibirapuera University, São Paulo, SP, Brazil

<sup>3</sup>Graduate Program in Implantology, University of Santo Amaro, School of Dentistry, São Paulo, SP, Brazil

<sup>4</sup>Department of Morphology and Genetics, Federal University of São Paulo, São Paulo, SP, Brazil

## \*Correspondence to

Luiz Felipe Palma,  
Email: [luizfelipep@hotmail.com](mailto:luizfelipep@hotmail.com)

Received: September 8, 2023

Accepted: November 10, 2023

ePublished: December 28, 2023



## Abstract

**Introduction:** Surgical procedures involving the temporomandibular joint (TMJ) are frequently associated with nerve injuries and subsequent dysfunctions. Considering that traumatic peripheral nerve injuries may resolve slowly and their prognosis is generally unpredictable, the current study aimed to report a clinical case in which both motor (affecting the temporal and zygomatic branches of the facial nerve) and sensory dysfunctions (affecting the auriculotemporal nerve of the trigeminal nerve) following TMJ surgery were effectively treated by using photobiomodulation therapy (PBMT).

**Case Report:** PBMT sessions, involving a total of 30 facial points, were administered twice a week for 10 weeks. The following parameters were utilized: wavelength of 808 nm, energy density of 75 J/cm<sup>2</sup>, power output of 100 mW, total energy of 3 J, and duration of 30 seconds per point. A considerable improvement in both facial asymmetry and muscle function was achieved within 5 weeks, along with a total restoration of cutaneous sensitivity. By the 10th week of PBMT, the facial movement dysfunction was completely resolved.

**Conclusion:** According to the current case, PMBT seems to be an effective intervention to manage motor and sensory nerve dysfunctions following TMJ surgery.

**Keywords:** Low-level laser; Cranial nerve injuries; Facial nerve; Trigeminal nerve.

## Introduction

The main surgical procedures in the temporomandibular joint (TMJ) related to complications are categorized into three major groups: arthroscopic surgery, open arthroplasty, and total joint reconstruction.<sup>1</sup> Undesirable events, while infrequent, should not be disregarded,<sup>2</sup> and their etiology can be attributed to anatomical, neurovascular, infectious, autoimmune, or biomechanical factors. Although meticulous surgical planning and technique are strongly suggested to mitigate complications of TMJ surgery, a thorough understanding of early identification and therapeutic management is also crucial.<sup>1</sup>

Preserving the functional integrity of the facial nerve is a critical determinant of success in TMJ surgery, as it is inherently susceptible to injury during the procedure.<sup>3</sup> Morphofunctional damage to its branches may manifest as either permanent (disruption during incision or dissection) or transient conditions (compression and stretching during tissue retraction or even edema-

induced neuropraxia).<sup>1</sup> Although reported rates of nerve complications range from 1% to 55%, they are generally temporary and resolve within a maximum duration of 6 months.<sup>3</sup> Clinically, impaired facial nerve function may affect emotional expression, result in functional deficits, and lead to cosmetic deformities<sup>4</sup> due mainly to weakness in the forehead region.<sup>5</sup>

TMJ surgery may also potentially damage certain branches of the trigeminal nerve, particularly those from the mandibular division which provide sensory innervation to the face and mouth.<sup>1,6</sup> A study revealed that 23.4% of patients who underwent TMJ arthroscopy surgery experienced numbness in the distribution of the auriculotemporal nerve for some months. Moreover, 3.6% of the patients also presented transient dysfunction affecting both inferior alveolar and lingual nerves.<sup>7</sup>

Microsurgical nerve repair (i.e., direct repair with epineural microsutures) has been the gold standard surgical treatment for severe axonotmesis and neurotmesis injuries for more than 50 years.<sup>8</sup> The clinical outcomes,

however, are dependent upon a series of factors such as the type and location of injury/repair, surgical technique, time from the injury, and patient comorbidities. In recent years, non-surgical therapies, traditionally regarded as supplementary to surgery and adjunctive to the reinnervation process, have garnered attention due to their potential to enhance nerve regeneration. Recently, studies have yielded promising results through the use of a series of interventions and therapeutic agents such as electrical and magnetical stimulation, exercises, acupuncture, photobiomodulation therapy (PBMT), growth factors, cell sources, bioscaffolds, and many other substances.<sup>9</sup>

Most evidence of peripheral nerve regeneration and functional restoration by the use of PBMT has come from *in vitro* and animal model studies,<sup>9</sup> and only a limited number of studies in humans are available (mainly involving the median and ulnar nerves).<sup>10</sup> Considering that traumatic peripheral nerve injuries may resolve slowly and their prognosis is generally unpredictable,<sup>11</sup> the current study postulated that PBMT would accelerate the recovery of nerve dysfunctions. The rationale is that such laser therapy is considered a non-invasive, safe, painless, and cost-effective therapeutic modality<sup>12</sup> with a proven capacity to modulate certain events of the inflammatory response and to promote tissue healing.<sup>13,14</sup> For that, we herein present a comprehensive clinical case in which motor and sensory dysfunctions resulting from TMJ surgery were effectively treated by using PBMT.

### Case Report

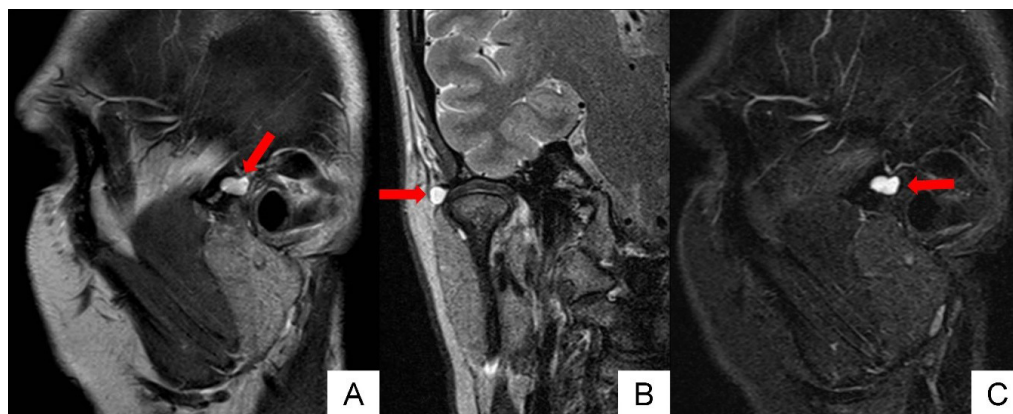
A 43-year-old female patient presented for a consultation with an oral and maxillofacial surgeon due to intermittent pain in the TMJ (right side) during mouth opening and closing, as well as limited mouth opening with deviation to the affected side and joint noises. Additionally, she reported constant tinnitus and severe episodes of headaches. The patient did not have any systemic disease and was not taking any medication.

A TMJ magnetic resonance imaging examination was requested, and it revealed bilateral findings of little clinical significance, such as mild disc displacement (medial) with reduction, mild joint effusion, and early degenerative joint disease. However, the presence of a lobulated “cyst-like” lesion of approximately 1 cm associated with the right mandibular head was also identified (Figure 1A-C).

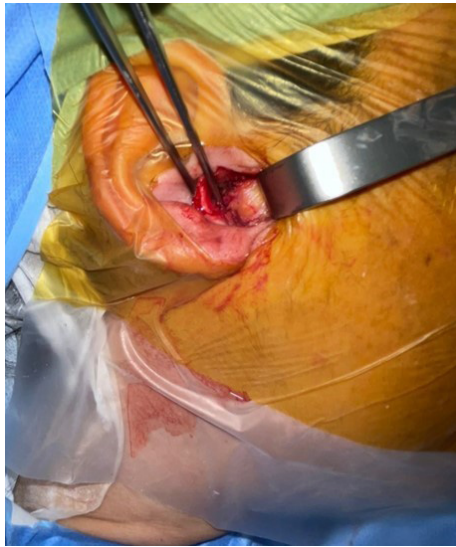
The patient was diagnosed by using the Taxonomic Classification from the Diagnostic Criteria for Temporomandibular Disorders (DC/TMD) for Clinical and Research Applications,<sup>15</sup> and conservative therapies were proposed as the initial treatment approach (occlusal splint, physiotherapy, cognitive-behavioral therapy, and pharmacological agents). As there was no clinical improvement in the symptoms of the joint condition within some weeks, the surgical excision of the lesion (diagnostic hypothesis: synovial cyst) was proposed under general anesthesia.

A solution of lidocaine with epinephrine was locally administered, and the endaural approach was initiated with an incision contouring the lateral aspect of the tragus, along the avascular portion anterior to the external auditory meatus. Sharp dissection was directed anterosuperiorly and slightly medially towards the zygomatic arch and then extended to the joint. Surgical retractors were positioned without exerting excessive traction on the tissues to provide an adequate view of the surgical field. Hemostasis, when necessary, was achieved by electrocoagulation.

The joint lesion was easily identified due to its somewhat superficial (lateral) position and clinical features (i.e., coloration and texture) (Figure 2); however, it fragmented into numerous tiny specimens during the excision. This fact hindered subsequent histopathological analyses, and a definitive diagnosis of the lesion could not be achieved. Finally, multiple-layer wound closure was performed and oral medications including a non-steroidal anti-inflammatory, a steroid, an antibiotic, and an analgesic, were prescribed for up to seven days.



**Figure 1.** Nuclear Magnetic Resonance Examination of the Temporomandibular Joint (Right Side) showing a “Cyst-like” Lesion of Approximately 1 cm. (A) A sagittal DP-weighted image: note the lesion at the tip of the red arrow. (B) A coronal DP-weighted image: note the lesion at the tip of the red arrow. (C) A sagittal STIR T2-weighted image: note the lesion at the tip of the red arrow



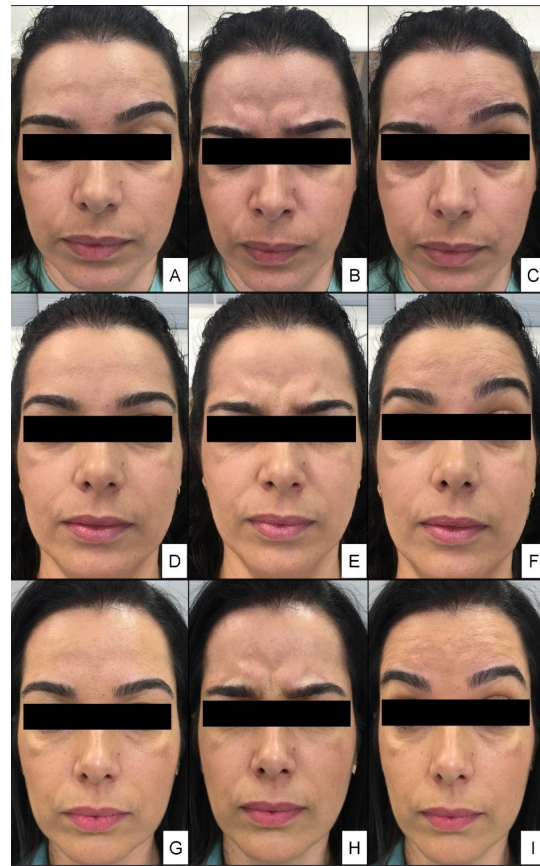**Figure 2.** Excision of the Lesion Through Temporomandibular Joint Surgery With an Endaural Approach

Within 14 days, the patient had no complaints regarding TMJ dysfunction but presented a persistent dysfunction of the muscles in the upper third of the right face, resulting in significant facial asymmetry at rest and minimal observable movements during some facial expressions (Figure 3A-C). Incomplete eye closure was also noted, leading to mild ocular discomfort characterized by dryness and itching. Although the specific type and severity of nerve damage could not be objectively determined through electrodiagnosis studies due to economic constraints, the House-Brackmann Facial Nerve Grading System revealed severe dysfunction.<sup>16</sup> Furthermore, complete loss of sensation in the right pre-auricular and temporal regions was reported.

Motor dysfunction affecting both the temporal and zygomatic branches of the facial nerve (motor component, VII cranial nerve) and sensory dysfunction affecting the auriculotemporal nerve of the trigeminal nerve (neurosensory component, V cranial nerve) were therefore diagnosed. As the patient no longer exhibited postsurgical edema and showed no improvement in nerve functions, the clinician attributed the neuropathies to traumatic injuries during the TMJ surgery.

For the management of both nerve dysfunctions, it was proposed to conduct a minimum of 20 PBMT sessions over 10 weeks (twice a week). For that, a continuous wave InGaAlP diode laser device was used, and the following parameters were applied: wavelength of 808 nm, energy density of 75 J/cm<sup>2</sup>, power output of 100 mW, total energy of 3 J, duration of 30 seconds per point, and 30 facial points (Table 1). The irradiation points were based on the anatomical facial areas corresponding to each injured nerve (Figure 4). The handpiece was held perpendicular to the skin surface and applied in contact mode.

A rapid improvement was observed in both facial asymmetry and muscle function within 5 weeks



**Figure 3.** The Clinical Course of Muscle Movement Dysfunction. (A-C) Initial clinical presentation (14 days after surgery): at rest (neutral) and in function. Note a marked dysfunction of the muscles in the upper third of the right face. (D-F) 5 weeks of photobiomodulation therapy: at rest (neutral) and in function. Note a partial improvement in the dysfunction of the muscles in the upper third of the right face. (G-I) 10 weeks of photobiomodulation therapy: at rest (neutral) and in function. Note a total recovery of muscle movements in the upper third of the right face

(Figure 3D-F), along with a total restoration of cutaneous sensitivity that no longer caused discomfort to the patient. The House-Brackmann Facial Nerve Grading System<sup>16</sup> revealed moderate dysfunction.

By the 10th week of PBMT, the muscle movement dysfunction was completely resolved,<sup>16</sup> and the patient reported no further complaints (Figure 3G-I). Therefore, the laser treatment was no longer necessary and could be discontinued.

## Discussion

The present paper presented a case in which twice-weekly PBMT sessions were highly effective in restoring muscle function and cutaneous sensitivity after TMJ surgery with an endaural approach. What makes this case exceptional is a relatively swift resolution of both nerve dysfunctions, which typically require several months for recovery.<sup>3,7</sup> Furthermore, to the best of our knowledge, no other paper with a similar approach has been published so far.

Modern approaches employed in open TMJ surgeries have primarily focused on minimizing facial nerve damage.<sup>5</sup> The endaural, favored as the first-line option for

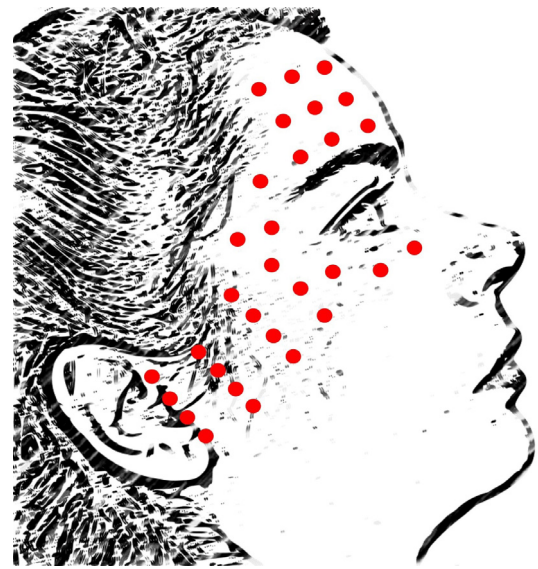
**Table 1.** Information About the Laser Device and Irradiation/Treatment Parameters

Specifications	Information
Manufacturer	MMOptics® Ltda
Model identifier	Twin Flex III Evolution
Number of emitters	One
Emitter type	InGaAlP
Beam delivery system	Fiberoptic
Type of laser	Diode
Operation mode	Continuous
Center wavelength	808 nm
Exposure duration	30 s
Delivery system	Optical fiber
Energy density	75 J/cm <sup>2</sup>
Energy per point	3 J
Number of points irradiated	30 points
Total radiant energy	90 J
Peak radiant power	100 mW
Average radiant power	100 mW
Focus spot area	0.04 cm <sup>2</sup>
Beam spot size on the target	0.04 cm <sup>2</sup>
Irradiance on the target	2.5 W/cm <sup>2</sup>
Application technique	Skin contact
Beam divergence	No

TMJ access by some experts,<sup>17</sup> incorporates an incision design with specific dissection planes that theoretically avoids damage to all the main branches of the facial nerve. Furthermore, this approach provides excellent posterior, lateral, and anterior access to the joint, with the resulting scar positioned behind the tragus.<sup>5</sup>

Despite all the suggested benefits of the endaural approach and the low rates of facial nerve paresis reported by some,<sup>2</sup> we faced important nerve damage in the current case. In a retrospective study investigating TMJ arthroplasty using the same approach, 58.3% of patients (or 56.4% of the surgical procedures) exhibited signs of facial nerve injury, most affecting either the temporal branches or the temporal and zygomatic branches concomitantly. It was also reported that only 3 of the 22 TMJ surgeries resulted in persistent signs of facial nerve weakness within 6 months.<sup>5</sup> These findings underscore the importance of the laser treatment proposed herein.

In the current case, we also managed the auriculotemporal nerve disorder, in which the resolution occurred over a relatively shorter period in comparison with facial nerve dysfunction. Although it is poorly reported following open TMJ surgeries probably because its neurosensory nature is considered a minor sequela, high rates are related to TMJ arthroscopy procedures, and cutaneous numbness may persist for up to three months.<sup>7</sup> Another aspect of concern when the auriculotemporal

**Figure 4.** Photobiomodulation Therapy: 30 Facial Irradiation Points Used for the Management of Motor and Sensory Disorders

nerve is damaged is auriculotemporal syndrome (or Frey syndrome), a rare condition characterized by sweating and flushing in the preauricular area triggered by mastication or salivary stimulation<sup>18</sup> in patients submitted to some surgical procedures in the region, including TMJ surgeries.<sup>19</sup>

Even though the present report provides encouraging findings, the underlying mechanisms of PBMT in facilitating the morphofunctional recovery of peripheral nerves remain unclear. It is important to highlight that the majority of available studies are *in vitro* or employ animal models, while the limited human studies involve small patient cohorts and encompass different nerves and types of injury. Likewise, the highly heterogeneous light parameters used in the studies such as total energy, power density, and type of wavelength, restrict the clinical applicability of PBMT.

Nevertheless, in general, PBMT is believed to present immediate protective and anti-inflammatory effects (reducing edema and scar tissue formation and increasing axonal metabolism), stimulate tissue healing (cell proliferation, cell migration, lower cell death rates), and affect mitotic activity (resulting in a faster nerve regeneration process).<sup>11</sup> PBMT has also been proposed to contribute to an increase in the axonal growth rate, the thickness of myelin sheaths,<sup>20</sup> and fiber sprouting,<sup>9</sup> and to prevent or decrease degeneration in the corresponding motor neurons of the spinal cord.<sup>21</sup>

Molecular studies have shown that laser irradiation is related to elevated immunoreactivities of growth-associated protein-43 (GAP-43) in the early stages of rat sciatic nerve regeneration,<sup>22</sup> and it also upregulates alpha-calcatonin gene-related peptide (CGRP) mRNA expression in the facial motor nuclei after axotomy.<sup>23</sup> These findings may support the theory that PBMT enhances the rate of

nerve regeneration, target reinnervation, and neuronal survival of the axotomized neuron.<sup>23,24</sup>

### Conclusion

According to the current case, PBMT seems to be an effective intervention to manage motor and sensory dysfunctions following TMJ surgery.

### Authors' Contribution

**Conceptualization:** Luiz Felipe Palma, Luana Campos, Luís Otávio Carvalho de Moraes.

**Data curation:** Luiz Felipe Palma, Thales dos Santos Porfírio.

**Investigation:** Luiz Felipe Palma, Thales dos Santos Porfírio, Rafael Verardi Serrano, Luana Campos, Luís Otávio Carvalho de Moraes.

**Methodology:** Luiz Felipe Palma, Rafael Verardi Serrano, Luana Campos.

**Project administration:** Luiz Felipe Palma, Luana Campos.

**Supervision:** Luiz Felipe Palma, Luana Campos, Luís Otávio Carvalho de Moraes.

**Writing—original draft:** Luiz Felipe Palma, Thales dos Santos Porfírio, Rafael Verardi Serrano.

**Writing—review & editing:** Luiz Felipe Palma, Luana Campos, Luís Otávio Carvalho de Moraes.

### Competing Interests

The authors have no relevant financial or non-financial interests to disclose.

### Ethical Approval

This study was approved by University of Santo Amaro (reference number: 6.296.368). Written informed consent was obtained from the patient.

### Funding

The authors declare that no funds, grants, or other support were received during the preparation of this manuscript.

### References

- Hoffman D, Puig L. Complications of TMJ surgery. *Oral Maxillofac Surg Clin North Am.* 2015;27(1):109-24. doi: [10.1016/j.coms.2014.09.008](https://doi.org/10.1016/j.coms.2014.09.008).
- Pauwels A, Lozano C, López JP. The facial nerve injury after temporomandibular joint surgery after endaural approach with sharp dissection. *J Maxillofac Oral Surg.* 2022;21(3):957-60. doi: [10.1007/s12663-021-01570-9](https://doi.org/10.1007/s12663-021-01570-9).
- Weinberg S, Kryshtalskyj B. Facial nerve function following temporomandibular joint surgery using the preauricular approach. *J Oral Maxillofac Surg.* 1992;50(10):1048-51. doi: [10.1016/0278-2391\(92\)90488-l](https://doi.org/10.1016/0278-2391(92)90488-l).
- do Egito Vasconcelos BC, Bessa-Nogueira RV, da Silva LC. Prospective study of facial nerve function after surgical procedures for the treatment of temporomandibular pathology. *J Oral Maxillofac Surg.* 2007;65(5):972-8. doi: [10.1016/j.joms.2006.06.280](https://doi.org/10.1016/j.joms.2006.06.280).
- Liu F, Giannakopoulos H, Quinn PD, Granquist EJ. Retrospective study of facial nerve function following temporomandibular joint arthroplasty using the endaural approach. *Craniofacial Trauma Reconstr.* 2015;8(2):88-93. doi: [10.1055/s-0034-1393726](https://doi.org/10.1055/s-0034-1393726).
- Fernández Sanromán J, Costas López A, Fernández Ferro M, de Sánchez AL, Stavaru B, Arenaz Bua J. Complications of temporomandibular joint arthroscopy using two-portal coblation technologies: a prospective study of 475 procedures. *J Craniomaxillofac Surg.* 2016;44(9):1221-5. doi: [10.1016/j.jcms.2016.06.027](https://doi.org/10.1016/j.jcms.2016.06.027).
- Weinberg S, Kryshtalskyj B. Analysis of facial and trigeminal nerve function after arthroscopic surgery of the temporomandibular joint. *J Oral Maxillofac Surg.* 1996;54(1):40-3. doi: [10.1016/s0278-2391\(96\)90301-8](https://doi.org/10.1016/s0278-2391(96)90301-8).
- Grinsell D, Keating CP. Peripheral nerve reconstruction after injury: a review of clinical and experimental therapies. *Biomed Res Int.* 2014;2014:698256. doi: [10.1155/2014/698256](https://doi.org/10.1155/2014/698256).
- Martínez de Albornoz P, Delgado PJ, Forriol F, Maffulli N. Non-surgical therapies for peripheral nerve injury. *Br Med Bull.* 2011;100:73-100. doi: [10.1093/bmb/ldr005](https://doi.org/10.1093/bmb/ldr005).
- Muniz XC, de Assis ACC, de Oliveira BSA, Ferreira LFR, Bilal M, Iqbal HMN, et al. Efficacy of low-level laser therapy in nerve injury repair—a new era in therapeutic agents and regenerative treatments. *Neurol Sci.* 2021;42(10):4029-43. doi: [10.1007/s10072-021-05478-7](https://doi.org/10.1007/s10072-021-05478-7).
- de Oliveira Rosso MP, Buchaim DV, Kawano N, Furlanette G, Pomini KT, Buchaim RL. Photobiomodulation therapy (PBMT) in peripheral nerve regeneration: a systematic review. *Bioengineering (Basel).* 2018;5(2):44. doi: [10.3390/bioengineering5020044](https://doi.org/10.3390/bioengineering5020044).
- Palma LF, Morimoto S, Serrano RV, Alvares CMA, Muñoz-Lora VRM, Campos L. Muscle function recovery following botulinum toxin type A facial injections: a case managed with photobiomodulation therapy. *J Lasers Med Sci.* 2022;13:e54. doi: [10.34172/jlms.2022.54](https://doi.org/10.34172/jlms.2022.54).
- Berlingieri G, Alvares CMA, Serrano RV, Palma LF, Campos L. Phototherapies for COVID-19-associated opportunistic oral infections. *Photodiagnosis Photodyn Ther.* 2022;37:102678. doi: [10.1016/j.pdpdt.2021.102678](https://doi.org/10.1016/j.pdpdt.2021.102678).
- Rezende SB, Campos L, Palma LF, Tateno RY, Simões A, Macedo MC, et al. Antimicrobial photodynamic therapy for recurrent herpes labialis in chronic graft-versus-host disease: a case report. *Photodermatol Photoimmunol Photomed.* 2021;37(4):321-3. doi: [10.1111/phpp.12655](https://doi.org/10.1111/phpp.12655).
- Schiffman E, Ohrbach R, Truelove E, Look J, Anderson G, Goulet JP, et al. Diagnostic criteria for temporomandibular disorders (DC/TMD) for clinical and research applications: recommendations of the International RDC/TMD Consortium Network\* and Orofacial Pain Special Interest Group†. *J Oral Facial Pain Headache.* 2014;28(1):6-27. doi: [10.11607/jop.1151](https://doi.org/10.11607/jop.1151).
- House JW, Brackmann DE. Facial nerve grading system. *Otolaryngol Head Neck Surg.* 1985;93(2):146-7. doi: [10.1177/019459988509300202](https://doi.org/10.1177/019459988509300202).
- Santos GS, Nogueira LM, Sonoda CK, de Melo WM. Using endaural approach for temporomandibular joint access. *J Craniofac Surg.* 2014;25(3):1142-3. doi: [10.1097/scs.0000000000000465](https://doi.org/10.1097/scs.0000000000000465).
- Motz KM, Kim YJ. Auriculotemporal syndrome (Frey syndrome). *Otolaryngol Clin North Am.* 2016;49(2):501-9. doi: [10.1016/j.otc.2015.10.010](https://doi.org/10.1016/j.otc.2015.10.010).
- Swanson KS, Laskin DM, Campbell RL. Auriculotemporal syndrome following the preauricular approach to temporomandibular joint surgery. *J Oral Maxillofac Surg.* 1991;49(7):680-2. doi: [10.1016/s0278-2391\(10\)80226-5](https://doi.org/10.1016/s0278-2391(10)80226-5).
- Er-Rouassi H, Benichou L, Lyoussi B, Vidal C. Efficacy of LED photobiomodulation for functional and axonal regeneration after facial nerve section-suture. *Front Neurol.* 2022;13:827218. doi: [10.3389/fneur.2022.827218](https://doi.org/10.3389/fneur.2022.827218).
- Rochkind S, Geuna S, Shainberg A. Chapter 25: phototherapy

- in peripheral nerve injury: effects on muscle preservation and nerve regeneration. *Int Rev Neurobiol.* 2009;87:445-64. doi: [10.1016/s0074-7742\(09\)87025-6](https://doi.org/10.1016/s0074-7742(09)87025-6).
22. Shin DH, Lee E, Hyun JK, Lee SJ, Chang YP, Kim JW, et al. Growth-associated protein-43 is elevated in the injured rat sciatic nerve after low power laser irradiation. *Neurosci Lett.* 2003;344(2):71-4. doi: [10.1016/s0304-3940\(03\)00354-9](https://doi.org/10.1016/s0304-3940(03)00354-9).
23. Snyder SK, Byrnes KR, Borke RC, Sanchez A, Anders JJ. Quantitation of calcitonin gene-related peptide mRNA and neuronal cell death in facial motor nuclei following axotomy and 633 nm low power laser treatment. *Lasers Surg Med.* 2002;31(3):216-22. doi: [10.1002/lsm.10098](https://doi.org/10.1002/lsm.10098).
24. Rochkind S. Phototherapy in peripheral nerve regeneration: from basic science to clinical study. *Neurosurg Focus.* 2009;26(2):E8. doi: [10.3171/foc.2009.26.2.e8](https://doi.org/10.3171/foc.2009.26.2.e8).