



Immune Response in Laser Tattoo Removal: A Systematic Review

Arya Tjipta¹, Hafiz Ramadhan², Rahmi Amelia Lubis³

¹Reconstructive and Aesthetic Plastic Surgery, Faculty of Medicine, University of North Sumatra, 20155, Indonesia

²General Practitioner, Faculty of Medicine, University of North Sumatra, 20155, Indonesia

³Bachelor of Public Health, Faculty of Public Health, University of North Sumatra, 20155, Indonesia

*Correspondence to

Arya Tjipta,
Email: Indonesia.arya.tjipta@usu.ac.id

Received: July 2, 2023

Accepted: October 14, 2023

Published: December 27, 2023

Abstract

Introduction: The immune response to laser tattoo removal poses a significant challenge in its management, primarily due to its unpredictable nature, which can range from mild hypersensitivity reactions to severe anaphylaxis. Such responses can potentially hinder the effectiveness of laser tattoo removal procedures. Therefore, gaining a comprehensive understanding of the immune response to tattoo removal using laser techniques is of utmost importance to develop more efficient management strategies. This study aims to address this need by analyzing eight carefully selected articles obtained through a thorough literature review.

Methods: To explore the immune response associated with laser techniques in tattoo removal, we employed a rigorous research methodology. A thorough literature review was conducted using reputable search engines such as Google Scholar, SagePub, and PubMed to collect relevant articles. Initially, 788 potential articles were identified through this process. Following meticulous scrutiny, only eight articles that met stringent inclusion criteria were selected for our study. This meticulous selection process ensures that the information presented here is derived from high-quality and pertinent research.

Results: Based on the analysis of the eight selected articles, our findings illuminate the various immune responses that emerge following tattoo removal using laser techniques. These responses include hypersensitivity reactions, allergic manifestations, and, in certain instances, anaphylaxis. Hypersensitivity reactions typically manifested as erythema, edema, and pruritus, while allergic responses were observed in the form of urticaria. In summary, our study highlights that the immune response to laser tattoo removal primarily elicits hypersensitivity and, in some cases, anaphylaxis reactions.

Conclusion: Our study underscores the significance of clinicians being vigilant regarding potential immune responses during laser tattoo removal. It is crucial to closely monitor patients to promptly address any adverse reactions. Further research holds the potential to enhance our understanding, paving the way for improved management strategies that can enhance patient safety and treatment success.

Keywords: Laser tattoo removal; Immune response; Laser technique; Hypersensitivity.



Introduction

Tattooing, an enduring practice involving the permanent application of pigmentation onto the skin, has garnered significant prevalence and emerged as a distinctive attribute among numerous individuals.¹ Nonetheless, due to a multitude of factors, certain individuals may express a desire to eliminate their tattoos. Consequently, the topic of tattoo removal has gained increased prominence within the domain of dermatology, prompting further scholarly investigation.^{2,3} Numerous approaches have been suggested, including surgical intervention or chemical-based eradication procedures; nevertheless, laser therapy is often regarded as the most efficacious remedy. Several laser options have been suggested for the management of this particular problem. Historically, ablative lasers, including CO₂ lasers, quality switched

laser (QSL), and various other laser modalities, have been conventionally employed. Nevertheless, alternative types of lasers, namely non-ablative lasers like neodymium-doped yttrium aluminum garnet (Nd: YAG) and alexandrite lasers, have been innovated to mitigate the potential for scarring and expand the applicability to various skin types. The utilization of laser therapy in the context of tattoo removal has experienced a surge in popularity, mostly attributable to its superior efficacy and safety in comparison to alternative approaches.⁴ In addition to the potential adverse effects of scarring and hypopigmentation, the process of laser tattoo removal presents difficulties in its management owing to the unexpected immunological response it elicits. The laser-based procedures employed for tattoo removal typically elicit immunological responses characterized

by hypersensitivity and anaphylaxis, introducing additional complexities to the treatment procedure, it is crucial to thoroughly evaluate the potential drawbacks and advantages associated with laser tattoo removal before completing the process. Seeking guidance from a certified dermatologist is essential to ensure the effective mitigation of any possible harmful consequences.^{5,6} In the course of tattooing, the introduction of tattoo ink occurs by means of injection into the epidermal layer, ultimately reaching the dermis. The dermal compartment encompasses a diverse array of immune cells, among which macrophages are included. Dermal macrophages function as sentinels of the skin, phagocytosing pathogens, dead cells, and other particulate matter. In the laser tattoo treatment procedure, ink pigments are fragmented into smaller particles, facilitating their uptake by macrophages through phagocytosis. The aforementioned procedure initiates an immunological response, whereby the macrophages secrete cytokines that serve to recruit additional immune cells to the treatment site. Nevertheless, the immunological response might exhibit unpredictability and could lead to hypersensitivity and allergic responses.⁷ Indeed, tattoo inks may have a diverse array of metals and chemical substances, which possess the potential to elicit an immunological response. The application of laser treatment to a tattoo results in the fragmentation of ink particles into smaller entities. This process has the potential to elicit an immune system reaction towards the foreign particles that are released, resulting in a variety of immunological reactions including hypersensitivity, allergy, and anaphylaxis. Consequently, the utilization of laser treatments for tattoo removal typically elicits immunological responses characterized by hypersensitivity and anaphylactic reactions.⁸

Fibroblasts are crucial to the maintenance of skin stability and homeostasis, as well as the regulation of immune cell function, through their involvement in the synthesis and degradation of extracellular matrix proteins. Furthermore, fibroblasts play a crucial role in the wound healing process and the subsequent development of scar tissue. As a result, these cells are activated in response to tissue damage in order to eliminate deteriorated collagen and produce fresh collagen fibrils. This process is essential for preserving the structural and functional properties of the skin.⁹

Fibroblasts have been found to possess an additional function beyond their primary job in preserving skin integrity, since they have been implicated in the storage of pigment particles. The examination of human tattooed skin by electron microscopy has revealed the presence of pigment particles that are adhered to the membrane of fibroblast cells. Hence, fibroblasts can further fulfill a function in the preservation of skin pigmentation within tattooed regions, thereby contributing to the enduring attributes of tattoos.^{10,11}

The utilization of laser technology for tattoo removal has been in existence for over a decade, with current advancements in its technological capabilities. The utilization of laser technology for the purpose of tattoo removal has emerged as the primary approach to address a predicament that was previously deemed irreversible. The most recent advancement in tattoo removal techniques is the utilization of the picosecond laser. This innovative technology operates by employing a laser that emits pulses at picosecond intervals (equivalent to one trillionth of a second) to effectively disintegrate tattoo particles. The ink particles are fragmented into minuscule dimensions. Subsequently, the intricate immune system of the individual assumes control of the laser-based tattoo removal procedure. Indeed, it is the immune system that bears the primary responsibility in this context. The laser facilitates the fragmentation of ink particles into dimensions suitable for translocation within bodily tissues and vascular structures. The ink particles are engulfed by the immune system, particularly macrophages, which subsequently transport them across various tissues and eliminate them via the excretory system.

The ink particles are situated within the dermis, where they are encased by collagen scar cells. When a substantial amount of ink is present, the body's immune system is unable to eliminate it. This is the reason why tattoos possess the appearance of being enduring throughout an individual's lifetime. Each instance of itching following a tattoo application signifies the immune system's endeavor to eliminate the ink from the skin.

The significance of this research is in its capacity to enhance knowledge and comprehension regarding the potential adverse effects linked to laser tattoo removal. The increasing prevalence of tattoo removal methods underscores the importance of prioritizing the safety and welfare of those who pursue these therapies.

This study serves as an important reminder for both practitioners and potential patients by emphasizing the potential hazards of scarring and hypopigmentation resulting from injury to the superficial tissue of the skin, particularly in situations involving large-scale tattoos. This statement underscores the significance of exercising prudence in the selection of a tattoo removal specialist, highlighting the criticality of engaging with reputed and seasoned practitioners who possess the ability to mitigate potential hazards and achieve the most favorable outcomes.

Additionally, this study has the potential to stimulate subsequent investigations and advancements in laser tattoo removal methodologies, resulting in heightened safety measures and improved efficacy of the operations. Consequently, this phenomenon contributes to the general progress of the discipline and facilitates healthcare providers in delivering improved care to their patients. Ultimately, this benefits individuals seeking to undergo

tattoo removal procedures with less difficulties.

To date, there has been a dearth of thorough research examining the immunological response of individuals following laser-based tattoo removal methods. Hence, the objective of this research endeavor is to conduct a comprehensive analysis of existing scholarly works and compile data pertaining to the immune response within the human body subsequent to laser-based tattoo removal procedures. This study aims to enhance comprehension about the immune system's response to laser-based tattoo removal procedures, as well as offering a more precise assessment of the efficacy of laser techniques in the context of tattoo removal. Therefore, the findings of this research have the potential to greatly enhance the advancement of improved and more efficient techniques for tattoo removal.

Methods

A comprehensive examination of the existing body of literature was conducted, focusing specifically on scholarly articles pertaining to the role of immune response in the process of laser tattoo removal. Articles that were accessible on the internet without any restrictions were accessed on a worldwide scale. The findings of these studies were documented in accordance with the principles outlined in the Preferred Reporting Items for Systematic Review and Meta-Analysis (PRISMA) declaration of 2020.

Inclusion and Exclusion

The inclusion criteria of the study were centered on articles that were published between January 2021 and June 2022. This selection aimed to prioritize the inclusion of the latest and most current research findings pertaining to the global immune response in laser tattoo removal. The chosen time span was intended to encompass recent breakthroughs and advancements in the field, with the goal of enhancing comprehension and control of immunological responses within this particular setting. In addition, the decision to restrict the scope of the study to publications that are freely available and published in the English language was made in order to enhance the inclusivity of the study and facilitate global access for researchers and clinicians. By excluding studies conducted prior to 2021, our analysis was able to prioritize the utilization of the most up-to-date information, thus augmenting the reliability and pertinence of our conclusions.

Study Selection

The process of article selection was conducted in two distinct stages. During the initial phase, the titles and abstracts of all resources were examined based on the predetermined inclusion criteria and search phrases. The titles and abstracts of the selected articles were

subsequently examined to determine if their content had the ability to address the research issues of the review. Abstracts that were deemed irrelevant were removed from the study, after which the researcher proceeded to retrieve the full articles corresponding to the selected abstracts. During the second phase, a comprehensive assessment was conducted on the complete articles in order to find relevant aspects that align with the objectives of the study. In a manner akin to the initial phase, comprehensive articles were examined to ascertain their alignment with the objectives of the review. The process of article selection was conducted utilizing the PRISMA flow diagram, depicted in [Figure 1](#).

Search Strategy and Information Sources

An exhaustive search was initially done to locate primary studies, reviews, and grey literature pertaining to the immune response in laser tattoo removal. The search aimed to collect research published within the past year. However, the duration of this period was extended to June 2022 in order to provide an update of the literature search prior to the completion of the final analysis and writing process. The investigation was conducted utilizing various electronic resources, namely PubMed and Google Scholar. The development of the search strategy was informed by the selection of appropriate search phrases. The literature search involved the utilization of Boolean operators, specifically "or" and "and," to effectively merge the keywords (immune, laser, tattoo) and associated terms.

Data Extraction

Materials were omitted from consideration if they lacked relevance and failed to provide a description of the immune response in the context of laser tattoo removal. Additionally, materials published outside the timeframe of January 2021 to June 2022 were also excluded. The objectives of the review guided the selection process. Subsequently, the pertinent publications were evaluated in order to address the inquiries posed in the review. The study features derived from publications encompassed several key elements, namely the author's name, the objective and aim of the background research, the year of publication, as well as the laser treatment and immunological response. The search yielded outcomes wherein the data obtained from the complete articles were effectively managed, extracted, and subsequently documented using Microsoft Word.

Quality Appraisal

A comprehensive evaluation of the methodological rigor and overall quality was conducted on all qualitative and quantitative studies that were accessible without any cost and were published within the specified search timeframe. The studies included in the analysis were

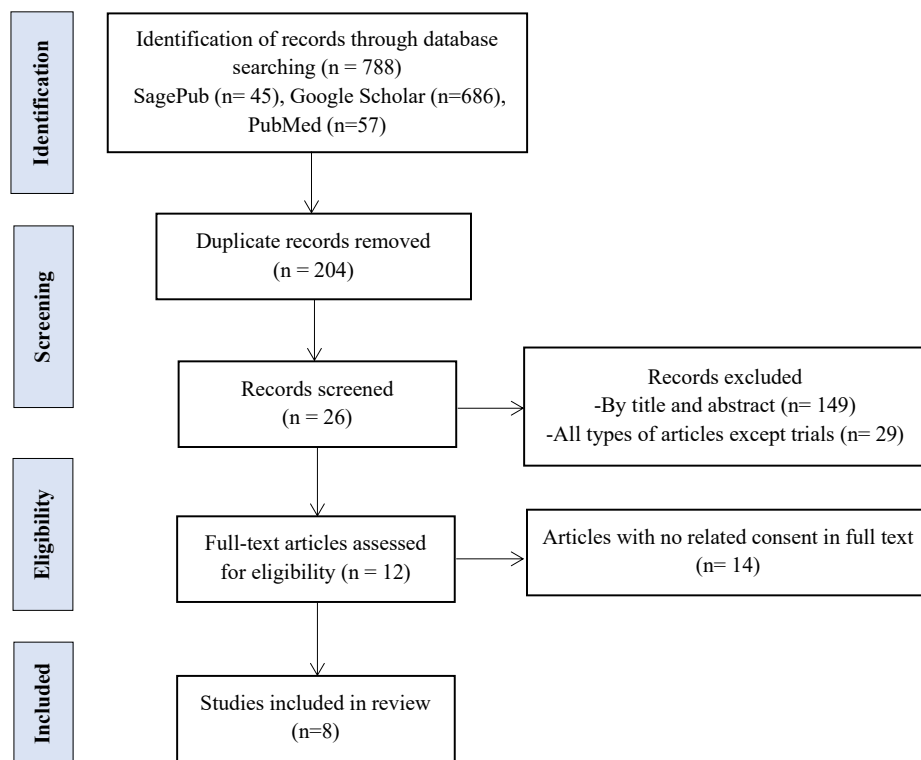


Figure 1. PRISMA Data Flowchart of the Literature Search

evaluated for their relevance. No studies were excluded from the analysis due to the quality assessment.

Data Analysis

A descriptive analysis was conducted on characteristics pertaining to the year of publication, number of studies, complications examined in the study, and treatment and outcome categories to which they were assigned.

Research Limitations

This study has several limitations that need to be acknowledged in interpreting our findings. Firstly, we faced limitations in obtaining information about the specific immune and hormonal status of patients during the laser procedure. As our data source relied on a literature review, we did not have direct access to complete patient data. This resulted in a lack of detailed information about immune responses and hormonal involvement in tattoo removal using lasers. These limitations may impact the accuracy and comprehensiveness of our analysis.

Additionally, data limitations were also present regarding information about tattoo pigments and the extent of tattooed areas in patients. Some of the studies we reviewed may not have provided comprehensive details about the specific pigments used or the precise size of the treated areas during laser procedures. The lack of complete data on tattoo pigments and tattooed areas could affect our ability to conduct in-depth analyses on the influence of specific pigments or tattoo

size on immune responses and tattoo removal outcomes using lasers. These limitations have implications for the development of relevant prediction algorithms. The lack of comprehensive information about patient immune and hormonal status, as well as limited data on tattoo pigments and tattooed areas, makes it challenging to develop robust and accurate prediction algorithms. Effective prediction algorithms require detailed and comprehensive datasets to yield more valid and reliable results.

Results

There are a total of eight studies that will be reviewed in this study. Table 1 provides information on the immune responses of individuals after undergoing tattoo removal procedures, including the research problem and objectives, patient age, and the type of laser used in tattoo removal. This table provides detailed information on the immune responses found in these studies, with the most common being hypersensitivity reactions, itching, and anaphylaxis. In addition, the most commonly used type of laser in tattoo removal procedures is the QSL.

In the first study, observations were made on the immune responses of patients who experienced hypersensitivity reactions during tattoo removal procedures using QSL. The second study analyzed the immune responses of patients who experienced itching after tattoo removal procedures using QSL. Another study was conducted to evaluate the effectiveness of using

Table 1. Several Scientific Articles That Discuss Immune Responses in Tattoo Removal Procedures Using Laser Techniques

Literature			Background Research		Aim	Laser Treated	Age (y)	Immune Response
First Author	Year	Objective						
Fusano ¹²	2022	Clinical outcomes of tattoo removal vary widely among different patients; it is known that tattoo-related features (such as pigments' type or quality, the use of multicolored inks, tattoo location size, location, layering, and duration) and personal habits (such as smoking or skin phototype) could influence the clinical response to treatment, the possible role of nutrition in affecting the laser treatment of tattoos has never been investigated.			This study aims to compare the clinical response of tattoo removal between omnivore and vegan patients treated with QSL.	Q-switched laser (QSL).	18-50	Transient erythema, edema
Wong ¹³	2021	A 45-year-old female who developed a severe reaction to both her treated and untreated tattoos after two picosecond laser treatments and subsequent widespread eczematous eruption			The aim of this journal is to bring attention to the potential hypersensitivity reactions to tattoos following picosecond laser treatment, as demonstrated by a specific case, emphasizing the dilemma of tattoo removal in sensitized patients and highlighting the need for additional therapeutic approaches.	Picosecond	45	Hypersensitivity reactions
Wang ¹⁴	2021	Pulsed lasers at the NIR range have been widely used in dermatology. Ultrashort pulsed picosecond lasers are found with the specific ability of very effective activation of skin repair and remodeling along with significant photodamage. Femtosecond lasers, with a shorter pulse width, may be a promising alternative to current NIR lasers in a clinic.			To perform optical micromachining by a femtosecond laser at 1030 nm to the skin of live mice in two modes of scanning of the focused laser and direct irradiation by the unfocused laser.	Femtosecond	-	The collagen and elastin repair was not activated either.
Laske ¹⁵	2022	The treatment of allergic reactions to red tattoo dye is challenging in most cases, as local therapy often does not offer long-term improvement, and laser therapy is considered relatively contraindicated by many authors owing to the risk of generalized side effects. Therefore, the surgical removal of these tattoos is favored; the shave excision is the method of choice, particularly for the removal of the entire dye			The aim of this article was to retrospectively analyze the best post-operative outcome after the surgical removal of allergic tattoo reactions using different excision techniques.	CO2	21-66	Allergic reactions
Weiß ¹⁶	2021	The treatment of allergic reactions to red tattoo dye is challenging in most cases, as local therapy often does not offer long-term improvement, and laser therapy is considered relatively contraindicated by many authors owing to the risk of generalized side effects. Therefore, the surgical removal of these tattoos is favored; the shave excision is the method of choice, particularly for the removal of the entire dye			This review summarizes possible adverse effects related to tattooing with a focus on the development of tattoo-mediated allergies. To date, relevant allergens were only identified in rare cases. Here, we present established methods and discuss current experimental approaches to identify culprit allergens in tattoo inks – via testing of the patient and in vitro approaches.	Ablative laser (CO2)	30	Burning sensation, allergic reactions
Cannarozzo ¹⁷	2021	Tattoo removal is a well-established procedure in dermatology. Lasers represent the gold standard in the management of this condition nowadays. In this study, authors report their experience with the use of a Q-switched nanosecond source.			To confirm literature findings on the safety and effectiveness of these devices	QSL	23-62	hyperpigmentation, hypopigmentation, and skin darkening
Marini ¹⁸	2022	Despite its innovation, the multi-pass laser-assisted intradermal pigment removal technique has notable drawbacks, with the most significant being the necessity to operate using two separate laser devices. This poses a challenge, as such equipment may not always be readily available in the majority of dermatological practices. Despite its innovation, the multi-pass laser-assisted intradermal pigment removal technique has notable drawbacks, with the most significant being the necessity to operate using two separate laser devices. This poses a challenge, as such equipment may not always be readily available in the majority of dermatological practices. With the advent of more powerful Q-S laser systems and sophisticated fractional optics, the versatile 1064-nm Nd:YAG wavelength has been used to produce highly efficient micro-ablative photo-acoustic tissue "drilling," reaching depths comparable to those produced by common fractional ablative lasers. Almost immediate pinpoint capillary bleeding, quite similar to that observed after 2940-nm Er:YAG and 10,600-nm CO2 fractional ablative lasers, is clinically evident after the fractional ablative Q-S 1064-nm laser, confirming micro-ablative penetrations down to papillary and superficial reticular vascular plexuses.			The purpose of this study was to evaluate the safety and efficacy of a new combined method of Q-S laser-assisted tattoo removal.	QSL	18-57	a superficial whitish discoloration described as a "popcorn" effect.
van der Bent ¹⁹	2021	Patients with allergic tattoo reactions are burdened with an itch and have a reduced quality of life. Conservative treatment is often insufficient and little is known about treatment options to remove the responsible allergen.			To address the effectiveness and safety of ablative laser therapy including measurement of patient satisfaction, in patients with allergic reactions to tattoos	CO2	44	Allergic reactions

QSL, quality switched laser; NIR, near infrared.

another type of laser, the PDL laser, in tattoo removal procedures and the immune response of patients after the procedure. The information obtained from these studies can provide a clearer understanding of the immune responses of individuals after tattoo removal procedures using laser techniques and expand our knowledge of the various types of lasers available for these procedures.

Discussion

In general, tattoo ink is injected into the skin using a needle that is moved by a tattoo machine. This creates many holes in the intact surface of the skin. Hemostasis usually closes the punctures and exudation occurs during the formation of a scab. Re-epithelialization then begins after a few hours, eventually closing the epidermis again through cell division and migration of keratinocytes. Understanding the process of tattooing is important for proper aftercare and potential complications. While the process of tattooing itself does not typically result in allergic reactions, the ink itself can cause an allergic response in some individuals. In addition, the injection of ink into the skin can lead to other complications, such as infection or scarring. Therefore, it is important to carefully consider the risks and potential complications before getting a tattoo.²⁰

In previous research, findings have indicated that diverse skin infections, including bacterial and viral infections, may arise following the application of tattoo ink to the skin.²¹ Moreover, tattoos have been linked to various skin reactions, such as allergic or granulomatous responses. The intricate immune system reaction is triggered by skin damage resulting from needle punctures and tattoo ink application, leading to both an inflammatory response and a complex immune reaction. In certain instances, skin infections related to tattoos can be attributed to the use of non-sterile equipment or inadequate post-tattoo care. This underscores the importance of employing sterile equipment and ensuring proper aftercare to mitigate the risk of skin infections. Additionally, tattoos can incite different skin reactions, such as allergic or granulomatous responses, potentially arising from the chemicals present in tattoo ink or immunological reactions to tattoo pigments. Therefore, it is crucial to carefully consider the risks of skin infections and allergic reactions before opting for a tattoo and to take necessary precautions. Further research may be necessary to assess alternative and safer methods for tattoo removal.²²

In the tattooing process, pigment particles are transferred to the dermis layer of the skin through needle punctures. Initially, the pigment particles reside in the papillary layer of the dermis, but over time, phagocytosis by immune cells causes the pigment particles to move deeper into the reticular layer of the dermis. In tattooed skin, these pigment particles appear as colored spots located within the dermal tissue. This phagocytosis

process involves cells such as macrophages, dendritic cells, and lymphocytes, which absorb the pigment particles and transport them through the lymphatic system to lymph nodes. Therefore, when tattooed skin is examined under a microscope, solid pigment particles in the dermis can be seen as a result of phagocytosis by different immune cells.^{23,24} Various laser methods used for tattoo removal have different immune responses. For example, the CO₂ laser with a wavelength of 10 600 nm has radiation that is absorbed by water and heated randomly throughout the tattooed skin area. Tattoo removal with the CO₂ laser results in the vaporization of the tattooed skin and the removal of all tattoo pigment particles. However, this procedure will definitely leave scarring on the entire tattooed skin area after laser treatment.²⁵

Conversely, in the context of tattoo removal utilizing Q-switched lasers, the laser beam is assimilated by the pigment particles present within the dermis. Q-switched lasers are characterized by their short pulse duration and high intensities, which result in the rapid heating of pigment particles. The application of this technique has the potential to induce shock waves, thus causing fragmentation of the pigment particles within the dermal layer. However, in response to this injury, the immune system initiates a cascade of events leading to the recruitment of immune cells, including macrophages, neutrophils, and dendritic cells, which play a crucial role in the repair and regeneration of the affected tissue. Subsequently, the aforementioned immune cells undergo migration and transport a portion of the shattered pigment particles via the lymphatic system. The primary factor attributed to the phenomenon of tattoo color fading subsequent to Q-switched laser treatment is widely acknowledged to be this.²⁶

At present, the prevailing laser technologies employed for the purpose of tattoo removal encompass Q-switched and picosecond lasers. The process of tattoo removal using lasers involves transepidermal elimination, subsequent disposal through the lymphatic system, and pigment phagocytosis by dermal cells. Extensive reports have documented the occurrence of skin allergic reactions to tattoo colors during the process of Q-switched laser removal.^{27,28} The observed phenomenon is hypothesized to arise from the interaction between fragmented extracellular tattoo pigments and the immune system of the body. This interaction may be influenced by alterations in antigenic determinants caused by the photothermal effect of laser therapy, leading to a heightened sensitivity response.²⁸

The initial study under discussion is a scholarly work authored by Fusano et al that endeavors to examine and contrast the clinical outcomes of tattoo removal procedures administered to patients who follow an omnivorous diet versus those who adhere to a vegan dietary regimen, utilizing the QSL treatment modality.¹²

The research highlights the considerable variability in clinical outcomes of tattoo removal across diverse patient populations. It is well-established that various factors associated with tattoos, including the type and quality of pigments, the use of multicolored inks, the size and location of the tattoo, as well as layering and duration, along with individual habits like smoking or skin phototype, can significantly impact the effectiveness of treatment. Nevertheless, the potential impact of nutrition on the efficacy of laser tattoo removal remains unexplored in existing research.

The hypothesis put up by the researchers in this study posits that individuals adhering to a vegan diet may exhibit a more advantageous clinical response to QSL tattoo removal in comparison to those following an omnivorous diet, owing to disparities in their nutritional profiles. The research encompassed a sample size of 22 individuals, consisting of 11 vegans and 11 omnivores, who underwent QSL tattoo removal. The findings of the study indicate that there was no statistically significant variation in the clinical response to tattoo removal between individuals who follow a vegan diet and those who consume both plant and animal products. Both groups had temporary redness and swelling, which subsided within a few days following the intervention. The research findings indicate that the clinical response to QSL tattoo removal is not significantly influenced by dietary status, particularly in the context of veganism.

In the study conducted by Wong and Cheung, a case report is presented. This report involves a 45-year-old female patient who experienced a significant adverse reaction to both her treated and untreated tattoos following two picosecond laser treatments. This was followed by the development of a broad eczematous eruption.¹³ The objective of the authors is to present an overview of the potential occurrence of tattoo hypersensitivity subsequent to picosecond laser treatment, as well as the ethical predicament that arises when removing tattoos in patients who have developed sensitization. The individual exhibited a delayed-type hypersensitivity response to the picosecond laser therapy, and the authors propose that this reaction was probably initiated by the liberation of tattoo pigment particles subsequent to the laser treatment. This study emphasizes the significance of conducting an assessment of patients to identify potential allergies to tattoos prior to undertaking laser tattoo removal procedures.

In the work conducted by Wang et al, the focus lies on examining the molecular reaction of the skin when subjected to micromachining using a femtosecond laser.¹⁴ The authors observe that pulsed lasers operating in the near-infrared (NIR) spectrum have been extensively employed in the field of dermatology. In particular, ultrashort pulsed picosecond lasers have demonstrated a remarkable capacity for stimulating skin healing

and remodeling, while also effectively addressing photodamage. Femtosecond lasers, characterized by their significantly shorter pulse width, show potential as a viable alternative to already employed NIR lasers within clinical settings. The research conducted optical micromachining on the skin of live mice using a femtosecond laser operating at a wavelength of 1030 nm. Two different techniques of scanning were employed: focused laser scanning and direct irradiation using an unfocused laser. The findings indicated that the activation of collagen and elastin repair was not observed, leading the authors to deduce that the use of femtosecond laser micromachining did not elicit substantial alterations in the molecular response of the skin.

In the study conducted by Laske et al, an examination is undertaken to explore the surgical intervention for the management of severe hypersensitivity reactions associated with red tattoo pigment. The authors acknowledge that managing allergic reactions to red tattoo dye is a complex task, as local therapy typically fails to provide sustained relief.¹⁵ Additionally, laser therapy is often seen as relatively contraindicated by numerous experts due to the potential for adverse effects that affect the entire body. Consequently, the preferred approach for eliminating these tattoos is through surgical intervention, with the have excision being the preferred option, especially when aiming to remove the complete pigment.

The authors of the fifth study conducted by Weiß et al provide a comprehensive examination of the negative consequences associated with tattooing.¹⁶ Additionally, they underscore the importance of employing uniform approaches for identifying and documenting these reactions. The article, moreover, includes contemporary scientific methodologies for the identification of allergens associated with allergies related to tattoos, including patient testing and in vitro techniques. The significance of discovering these allergens is emphasized by the authors in order to enhance the safety of tattoo inks and to provide valuable insights for the advancement of treatment approaches for allergies caused by tattoos.

Cannarozzo et al conducted a comprehensive investigation in their sixth study, which further explores the application of Q-switched nanosecond sources in the context of tattoo removal.¹⁷ The findings of this study provide additional evidence that supports the safety and efficacy of these sources for the goal of tattoo removal. The significance of employing appropriate techniques and parameters in order to attain optimal outcomes in tattoo removal using these devices is examined by the writers. Additionally, it is suggested that further investigation is required in order to optimize parameters and enhance outcomes within distinct patient populations.

The seventh study conducted by Marini et al offers a comprehensive case series examining the application

of QS laser micro-drilling and multipass full-beam QS laser in the context of tattoo removal¹⁸. The research, undertaken by Vander Bent, reveals that ablative CO2 laser treatment has the potential to alleviate itching, burning sensations, and the overall impact on daily life for tattoo allergy patients. The study, spanning from January 2010 to January 2018, included sixteen patients treated with a 10600 nm ablative CO2 laser, employing either full-surface ablation or fractional ablation techniques. Clinical information was gathered from medical files, supplemented by a 25-item questionnaire completed by fourteen patients.¹⁹ The research findings indicate that although these methodologies possess certain drawbacks, such as the possibility of scarring and extended treatment duration, they demonstrate efficacy in the eradication of tattoos. The significance of appropriate patient selection and counseling for tattoo removal operations is emphasized by the authors, who also call for further study to enhance the safety and effectiveness of tattoo removal techniques.

In the context of tattoo removal using lasers, there are several types of lasers used for this purpose, such as picosecond lasers, CO2 ablative lasers, and fractional lasers. From several articles that have reviewed and compared these different laser types, it has been found that a very common immune response after tattoo removal is hypersensitivity. During tattoo removal with picosecond lasers, allergic anaphylaxis often occurs in patients undergoing this procedure.

The primary methods employed in tattoo removal using picosecond lasers are the photoacoustic and mechanical mechanisms of photothermal response. The studied scientific narratives provide further data that support the notion that the photothermal action of laser therapy can lead to alterations in the antigenic determinants found in tattoo pigments, subsequently resulting in a hypersensitive response. The aforementioned scientific narratives also present additional evidence that supports the pathophysiology of autoeczematization reactions in laser tattoo removal. These reactions are triggered by the immune response to extracellular particles of pigments.

Furthermore, instances of skin allergic reactions have been documented in the context of tattoo removal procedures involving CO2 ablative and fractional lasers, specifically when the energy emitted by these lasers is not absorbed by the tattoo pigments. This phenomenon can potentially facilitate alterations in pigments with antigenic properties, thus contributing to the occurrence of hypersensitive reactions. Hence, it is imperative to properly address the management of allergies associated with laser-based tattoo removal in order to mitigate the potential for allergic responses among patients.²⁹⁻³¹

Therefore, the removal of tattoos in cases of allergic contact dermatitis caused by tattoo pigments presents a complex issue due to the potential for inducing

hypersensitive reactions. There exists an unresolved aspect within the realm of laser treatment for the purpose of tattoo removal. Multiple scholarly studies propose different management strategies, such as the utilization of topical and oral corticosteroids, as well as oral antihistamines, as post-laser interventions to mitigate hypersensitive reactions in specific instances.

In addition, there are other factors to consider when it comes to tattoo removal, such as the size and location of the tattoo and the type of pigments used. Some pigments, such as red and yellow, are known to be more prone to causing allergic reactions. Therefore, it is important to thoroughly assess and discuss potential risks with the patient before proceeding with tattoo removal.

Moreover, aftercare is crucial in minimizing the risk of adverse reactions, such as hypersensitivity. Patients should be advised to keep the treated area clean and dry, avoid exposure to direct sunlight, and follow any other specific instructions provided by their healthcare provider.

In summary, while laser tattoo removal can be an effective method for removing tattoos, there are potential risks and challenges, particularly in cases of allergic reactions. Therefore, a comprehensive assessment and management approach, along with appropriate aftercare, is crucial for ensuring optimal outcomes and minimizing adverse events.^{28,29,32}

Conclusion

In this study, the conclusion drawn is that the use of laser techniques in tattoo removal can result in an immune response that causes hypersensitivity and anaphylaxis in patients. This indicates the need for careful management and appropriate post-laser care to prevent allergic reactions in patients undergoing tattoo removal using laser techniques. It also emphasizes the importance of considering allergy risk factors before performing tattoo removal with laser techniques, and further research may be required to evaluate safer and more effective tattoo removal alternatives.

Acknowledgments

We would like to express our sincere gratitude to all the authors and researchers whose work we have reviewed and analyzed in this systematic review. We would also like to thank our colleagues for their valuable input and feedback during the development of this manuscript. Finally, we would like to acknowledge the hard work and dedication of the editorial team and reviewers for their insightful comments and suggestions that have helped to improve the quality of this manuscript.

Authors' Contribution

Conceptualization: Arya Tjipta, Hafiz Ramadhan, Rahmi Amelia Lubis.

Data curation: Hafiz Ramadhan.

Formal analysis: Arya Tjipta.

Investigation: Arya Tjipta and Hafiz Ramadhan.

Methodology: Hafiz Ramadhan, Rahmi Amelia Lubis.

Project administration: Arya Tjipta.

Resources: Rahmi Amelia Lubis.

Validation: Arya Tjipta and Hafiz Ramadhan.

Visualization: Hafiz Ramadhan.

Writing—original draft: Arya Tjipta, Hafiz Ramadhan, Rahmi Amelia Lubis.

Writing—review & editing: Arya Tjipta, Hafiz Ramadhan, Rahmi Amelia Lubis

Competing Interests

The author declare no conflict of interest

Ethical Approval

In this study, we would like to note that as it is a systematic review involving the analysis of secondary data from previously published literature, we do not directly involve human subjects or animal resources. Therefore, there are no specific ethical considerations or ethical approval procedures required for this research. We remain committed to upholding research ethics standards and reporting our findings with integrity and accuracy.

Funding

We want to emphasize that our initiative is entirely self-funded, and we have chosen to undertake this project independently, without seeking or receiving any financial assistance from external sources. This underscores our commitment to self-reliance and the dedicated pursuit of our goals without relying on external funding support.

References

- Witkoś J, Hartman-Petrycka M. Gender differences in subjective pain perception during and after tattooing. *Int J Environ Res Public Health*. 2020;17(24):9466. doi: [10.3390/ijerph17249466](https://doi.org/10.3390/ijerph17249466).
- Kluger N, Misery L, Seité S, Taieb C. Regrets after tattooing and tattoo removal in the general population of France. *J Eur Acad Dermatol Venereol*. 2019;33(4):e157-9. doi: [10.1111/jdv.15385](https://doi.org/10.1111/jdv.15385).
- Zhitny VP, Iftekhar N. Tattoo removal: a practice from ancient times. *Dermatology*. 2020;236(4):390-2. doi: [10.1159/000506419](https://doi.org/10.1159/000506419).
- Kim M, Park S, Lee HU, Kang HW. Quantitative monitoring of tattoo contrast variations after 755-nm laser treatments in in vivo tattoo models. *Sensors (Basel)*. 2020;20(1):285. doi: [10.3390/s20010285](https://doi.org/10.3390/s20010285).
- Mercuri SR, Brianti P, Dattola A, Bennardo L, Silvestri M, Schipani G, et al. CO₂ laser and photodynamic therapy: study of efficacy in periocular BCC. *Dermatol Ther*. 2018;31(4):e12616. doi: [10.1111/dth.12616](https://doi.org/10.1111/dth.12616).
- Cannarozzo G, Bennardo L, Negosanti F, Nisticò SP. CO₂ laser treatment in idiopathic scrotal calcinosis: a case series. *J Lasers Med Sci*. 2020;11(4):500-1. doi: [10.34172/jlms.2020.79](https://doi.org/10.34172/jlms.2020.79).
- Walmsley GG, Maan ZN, Hu MS, Atashroo DA, Whittam AJ, Duscher D, et al. Murine dermal fibroblast isolation by FACS. *J Vis Exp*. 2016(107):53430. doi: [10.3791/53430](https://doi.org/10.3791/53430).
- Haniffa M, Ginhoux F, Wang XN, Bigley V, Abel M, Dimmick I, et al. Differential rates of replacement of human dermal dendritic cells and macrophages during hematopoietic stem cell transplantation. *J Exp Med*. 2009;206(2):371-85. doi: [10.1084/jem.20081633](https://doi.org/10.1084/jem.20081633).
- Bainbridge P. Wound healing and the role of fibroblasts. *J Wound Care*. 2013;22(8):407-8. doi: [10.12968/jowc.2013.22.8.407](https://doi.org/10.12968/jowc.2013.22.8.407).
- Taylor CR, Anderson RR, Gange RW, Michaud NA, Flotte TJ. Light and electron microscopic analysis of tattoos treated by Q-switched ruby laser. *J Invest Dermatol*. 1991;97(1):131-6. doi: [10.1111/1523-1747.ep12478570](https://doi.org/10.1111/1523-1747.ep12478570).
- Fujita H, Nishii Y, Yamashita K, Kawamata S, Yoshikawa K. The uptake and long-term storage of India ink particles and latex beads by fibroblasts in the dermis and subcutis of mice, with special regard to the non-inflammatory defense reaction by fibroblasts. *Arch Histol Cytol*. 1988;51(3):285-94. doi: [10.1679/aohc.51.285](https://doi.org/10.1679/aohc.51.285).
- Fusano M, Galimberti MG, Bencini PL. Laser removal of tattoos in vegan and omnivore patients. *J Cosmet Dermatol*. 2022;21(2):674-8. doi: [10.1111/jocd.14134](https://doi.org/10.1111/jocd.14134).
- Wong IT, Cheung LW. Id reaction and allergic contact dermatitis post-picosecond laser tattoo removal: a case report. *SAGE Open Med Case Rep*. 2021;9:2050313x211057934. doi: [10.1177/2050313x211057934](https://doi.org/10.1177/2050313x211057934).
- Wang Y, Wang S, Zhu Y, Xu H, He H. Molecular response of skin to micromachining by femtosecond laser. *Front Phys*. 2021;9:637101. doi: [10.3389/fphy.2021.637101](https://doi.org/10.3389/fphy.2021.637101).
- Laske J, Maschke J, Bauer A, Beissert S, Aschoff R. Operative treatment of severe allergic reactions to red tattoo dye: presentation and comparison of possible surgical procedures in seven patients. *J Cutan Aesthet Surg*. 2022;15(1):24-32. doi: [10.4103/jcas.jcas_202_20](https://doi.org/10.4103/jcas.jcas_202_20).
- Weiß KT, Schreiber I, Siewert K, Luch A, Haslböck B, Berneburg M, et al. Tattoos - more than just colored skin? Searching for tattoo allergens. *J Dtsch Dermatol Ges*. 2021;19(5):657-69. doi: [10.1111/ddg.14436](https://doi.org/10.1111/ddg.14436).
- Cannarozzo G, Nisticò SP, Zappia E, Del Duca E, Provenzano E, Patruno C, et al. Q-switched 1064/532 nm laser with nanosecond pulse in tattoo treatment: a double-center retrospective study. *Life (Basel)*. 2021;11(7):699. doi: [10.3390/life11070699](https://doi.org/10.3390/life11070699).
- Marini L, Marini S, Cutlan J, Hreljac I. Q-S laser micro-drilling and multipass full-beam Q-S laser for tattoo removal - a case series. *Lasers Med Sci*. 2022;37(3):1763-71. doi: [10.1007/s10103-021-03431-w](https://doi.org/10.1007/s10103-021-03431-w).
- van der Bent SAS, Huisman S, Rustemeyer T, Wolkerstorfer A. Ablative laser surgery for allergic tattoo reactions: a retrospective study. *Lasers Med Sci*. 2021;36(6):1241-8. doi: [10.1007/s10103-020-03164-2](https://doi.org/10.1007/s10103-020-03164-2).
- Rittié L. Cellular mechanisms of skin repair in humans and other mammals. *J Cell Commun Signal*. 2016;10(2):103-20. doi: [10.1007/s12079-016-0330-1](https://doi.org/10.1007/s12079-016-0330-1).
- Dieckmann R, Boone I, Brockmann SO, Hammerl JA, Kolb-Mäurer A, Goebeler M, et al. The risk of bacterial infection after tattooing. *Dtsch Arztebl Int*. 2016;113(40):665-71. doi: [10.3238/arztebl.2016.0665](https://doi.org/10.3238/arztebl.2016.0665).
- Serup J, Sepehri M, Hutton Carlsen K. Classification of tattoo complications in a hospital material of 493 adverse events. *Dermatology*. 2016;232(6):668-78. doi: [10.1159/000452148](https://doi.org/10.1159/000452148).
- Manganoni AM, Sereni E, Pata G, Ungari M, Pavoni L, Farisoglio C, et al. Pigmentation of axillary sentinel nodes from extensive skin tattoo mimics metastatic melanoma: case report. *Int J Dermatol*. 2014;53(6):773-6. doi: [10.1111/ijd.12417](https://doi.org/10.1111/ijd.12417).
- Baranska A, Shawket A, Jouve M, Baratin M, Malosse C, Voluzan O, et al. Unveiling skin macrophage dynamics explains both tattoo persistence and strenuous removal. *J Exp Med*. 2018;215(4):1115-33. doi: [10.1084/jem.20171608](https://doi.org/10.1084/jem.20171608).

25. Reid R, Muller S. Tattoo removal by CO laser dermabrasion. *Plast Reconstr Surg.* 1980;65(6):717-28. doi: [10.1097/00006534-198006000-00001](https://doi.org/10.1097/00006534-198006000-00001).
26. Bäumlér W, Weiß KT. Laser assisted tattoo removal - state of the art and new developments. *Photochem Photobiol Sci.* 2019;18(2):349-58. doi: [10.1039/c8pp00416a](https://doi.org/10.1039/c8pp00416a).
27. Ashinoff R, Levine VJ, Soter NA. Allergic reactions to tattoo pigment after laser treatment. *Dermatol Surg.* 1995;21(4):291-4. doi: [10.1111/j.1524-4725.1995.tb00175.x](https://doi.org/10.1111/j.1524-4725.1995.tb00175.x).
28. England RW, Vogel P, Hagan L. Immediate cutaneous hypersensitivity after treatment of tattoo with Nd:YAG laser: a case report and review of the literature. *Ann Allergy Asthma Immunol.* 2002;89(2):215-7. doi: [10.1016/s1081-1206\(10\)61942-4](https://doi.org/10.1016/s1081-1206(10)61942-4).
29. Meesters AA, De Rie MA, Wolkerstorfer A. Generalized eczematous reaction after fractional carbon dioxide laser therapy for tattoo allergy. *J Cosmet Laser Ther.* 2016;18(8):456-8. doi: [10.1080/14764172.2016.1225962](https://doi.org/10.1080/14764172.2016.1225962).
30. Ibrahimi OA, Syed Z, Sakamoto FH, Avram MM, Anderson RR. Treatment of tattoo allergy with ablative fractional resurfacing: a novel paradigm for tattoo removal. *J Am Acad Dermatol.* 2011;64(6):1111-4. doi: [10.1016/j.jaad.2010.11.005](https://doi.org/10.1016/j.jaad.2010.11.005).
31. Zemtsov A, Wilson L. CO2 laser treatment causes local tattoo allergic reaction to become generalized. *Acta Derm Venereol.* 1997;77(6):497. doi: [10.2340/0001555577497](https://doi.org/10.2340/0001555577497).
32. Ashinoff R, Levine VJ, Soter NA. Allergic reactions to tattoo pigment after laser treatment. *Dermatol Surg.* 1995;21(4):291-4. doi: [10.1111/j.1524-4725.1995.tb00175.x](https://doi.org/10.1111/j.1524-4725.1995.tb00175.x).