



# Photobiomodulation and Antimicrobial Photodynamic Therapy for Oral Ulcers in a Patient With Thrombocytopenia Following Bone Marrow Transplantation

Luana Campos<sup>1\*</sup>, Daniel Campanhã<sup>2</sup>, Ricardo Yudi Tateno<sup>1</sup>, Luiz Felipe Palma<sup>3</sup>

<sup>1</sup>Graduate Program in Implantology, University of Santo Amaro, School of Dentistry, São Paulo, SP, Brazil

<sup>2</sup>Service of Oral Medicine, São Luiz Hospital, SP, Brazil

<sup>3</sup>Graduate Dentistry Program, Ibirapuera University. São Paulo, SP, Brazil

## \*Correspondence to

Luana Campos, School of Dentistry, University of Santo Amaro, Rua Prof. Enéas de Siqueira Neto, 340 - Jardim das Imbuías, São Paulo - SP, 04829-300, Brazil.  
Phone: +55 11 21418615. Email: [lucampos@prof.unisa.br](mailto:lucampos@prof.unisa.br)

Received: July 21, 2021

Accepted: February 12, 2022

Published online April 21, 2022



## Abstract

**Introduction:** Thrombocytopenia is usually seen after allogeneic hematopoietic stem cell transplantation (HSCT) and may favor the development of oral bleeding, infections, and ulcerations.

**Case Report:** A patient with chronic myelomonocytic leukemia had been submitted to allogeneic HSCT. Within a few days, she developed severe thrombocytopenia and an extensive ulcerative area comprising both lips, which bled spontaneously, as well as smaller ulcers on the tongue mucosa. The lesions were managed using a combination of phototherapies (photobiomodulation and antimicrobial photodynamic therapies), totalizing 4 laser sessions. After 4 days, there was an important reduction in the severity of the lesions, with spontaneous disappearance of the crusts and reepithelization.

**Conclusion:** The proposed combination of phototherapies would be a suitable therapeutic modality for the management of oral lesions related to platelet disorders induced by oncologic treatments.

**Keywords:** Photodynamic therapy; Low-level laser; Thrombocytopenia; Oral lesion; Lip diseases.

## Introduction

Thrombocytopenia, a complication related to life-threatening bleeding, is usually seen after allogeneic hematopoietic stem cell transplantation (HSCT).<sup>1</sup> It involves complex mechanisms such as impaired thrombopoiesis and increased platelet consumption, which are affected by many factors and conditions related to the features of the patients and transplantation regimen, drugs administered, and even infections.<sup>2</sup>

Persistent cases are thought to result in worse outcomes than fluctuating ones; however, in general, thrombocytopenia is highly associated with a uniformly dismal prognosis.<sup>2</sup> Furthermore, unfortunately, patients may also experience secondary failure of platelet recovery after achieving primary platelet recovery following allogeneic HSCT.<sup>1</sup> Severe thrombocytopenia requires platelet transfusion for the prevention and management of bleeding, and it is highly related to the therapeutic effects and prognosis of transplantation.<sup>3</sup>

Patients presenting hematologic diseases may receive chemotherapy, radiotherapy, and HSCT. Chemotherapy and the conditioning regimens for HSCT affect oral tissues in several different ways, according to both

the nature of medication and dosage. These patients commonly experience oral mucositis, which may get worse and become painful pseudomembranous ulcers. Moreover, neutropenia and thrombocytopenia induced by the oncologic treatment favor the development of oral bleeding, infections, and further ulcerations.<sup>4</sup>

Given these facts, the current study aimed to present a case in which a combination of phototherapies was used for managing extensive, bleeding oral ulcers in an oncologic patient with thrombocytopenia after allogeneic HSCT.

## Case Report

A 49-year-old female presenting chronic myelomonocytic leukemia was referred to the hospital for allogeneic HSCT with busulfan plus fludarabine (BuFlu) as a myeloablative conditioning regimen. Acyclovir, micafungin, teicoplanin, meropenem, and trimethoprim were prescribed prophylactically to prevent infections, and a combination of cyclosporine and methotrexate was administered for graft-versus-host disease prophylaxis following the transplantation.

On the third day, the patient developed grade-3 mucositis

throughout the oral cavity, which was controlled by using a daily protocol of photobiomodulation therapy (PBMT) at 660-nm (Therapy EC; DMC<sup>®</sup>, São Carlos, SP, Brazil) in contact mode, with 100 mW, 0,3 J, and 3 seconds per point. Later in the clinical course, on the thirteenth day (D + 13), she presented severe thrombocytopenia due to host-derived anti-HPA-3b, resulting in acute respiratory failure, hypertensive peaks, renal impairment, and weight gain, and requiring intensive care unit admission. Physical examination revealed 144×100 mm Hg arterial blood pressure, 123 beats/minute heart rate, and 38.5°C body temperature, and the blood count test showed 6.3 g/dL hemoglobin, 1410 /mm<sup>3</sup> leukocytes, 13 000/mm<sup>3</sup> platelets, and 2986 mg/dL C-reactive protein.

Within a short period, in general, oral mucositis got worse; however, the lesions on the lips and tongue presented the worst clinical evolution. An extensive ulcerative area comprising both lips bleeding spontaneously was noted, besides smaller ulcers on the tongue mucosa (Figure 1a). A nasogastric tube was then used for feeding since the patient reported severe pain on such lesions. Nasotracheal intubation was also performed because of respiratory impairment.

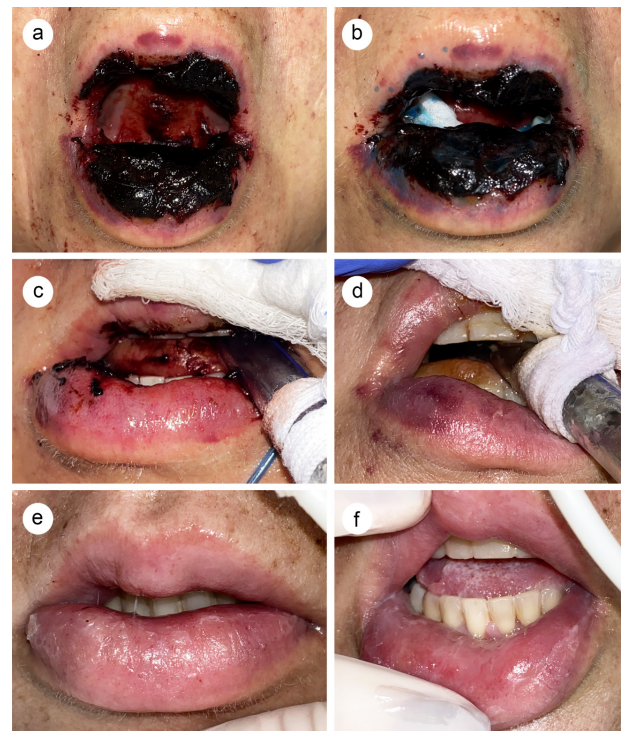
Besides supportive oral care measures used as the Hospital's protocol, an antimicrobial photodynamic therapy (aPDT) session was proposed for managing the ulcers. For that, 0.01% methylene blue solution (Figure 1b) was applied onto the lesions for 3 minutes, and then 660-nm laser irradiation (the same equipment cited above) was applied using the following parameters: contact mode, point by point, 100 mW, 5 J, 50 seconds per point. A total of 10 points were distributed throughout the affected areas. After 24 hours, PBMT sessions were retaken for the same areas (Table 1).

Within 72 hours, there was an important reduction in the severity of the lesions, with spontaneous disappearance of the crusts and reepithelization (Figure 1c). On the following day, despite no significant improvement in the patient's general medical status, the patient presented a better oral clinical condition (Figure 1d). She was extubated on the fifth day, and complete repair of the oral lesions could be noted (Figures 1e and 1f).

## Discussion

The current paper presented a case in which the treatment using phototherapies was successful in both relieving the patient's oral symptoms and reducing the severity of the lesions within a few days. To the best of our knowledge, there is no other study with regards to the benefits of this phototherapeutic approach for bleeding oral ulcers in an oncologic patient with thrombocytopenia after allogeneic HSCT. Furthermore, no report presenting similar oral lesions in such medically compromised patients was encountered.

The laser protocols herein applied were based on



**Figure 1.** Clinical Evaluation. (a) Initial clinical presentation, showing an extensive bleeding area in both lips and tongue mucosa; (b) Methylene blue application for aPDT; (c) 72 hours from the first aPDT session, showing a reduction in the severity of the lesions; (d) 4 days from the first aPDT session, showing complete tissue repair and a limited area with edema and erythema restricted to the lower lip mucosa; (e, f) 5 days from the first aPDT session, showing total tissue repair.

**Table 1.** Laser Parameters

| Specifications                      | Unit                   |
|-------------------------------------|------------------------|
| Type of laser                       | Diode                  |
| Emission mode                       | Continuous             |
| Time on/time off                    | -                      |
| Delivery system                     | Optical fiber          |
| Energy distribution – PDT           | 50 J - total           |
| Energy distribution - PBMT          | 3 J - total            |
| Peak power                          | 0.1 W                  |
| Average power                       | 0.1 W                  |
| Spot diameter at the focus          | -                      |
| Focus spot area                     | 0.028 cm <sup>2</sup>  |
| Spot diameter at the tissue         | -                      |
| Focus-to-tissue                     | In contact             |
| Spot area at the tissue             | 0.028 cm <sup>2</sup>  |
| Peak power density at spot area     | 3.57 W/cm <sup>2</sup> |
| Peak power density at the tissue    | 3.57 W/cm <sup>2</sup> |
| Average power density at spot area  | 3.57 W/cm <sup>2</sup> |
| Average power density at the tissue | 3.57 W/cm <sup>2</sup> |
| Beam divergence                     | No                     |
| Water irrigation                    | No                     |
| Air and aspirating airflow          | No                     |

previous reports of our research group in which oral lesions of dissimilar nature in oncologic patients with graft versus host disease following allogeneic HSCT have been successfully managed with this combination of phototherapies.<sup>5,6</sup> The rationale for it is that aPDT has an important antimicrobial effect, and PBMT promotes analgesia and mitigation of the inflammatory process<sup>6</sup> since the unusual, severe presentation of the oral lesions needed early treatment to prevent infections and substantial bleeding and to achieve pain relief.

### Conclusion

The present case suggests that the combination of aPDT and PBMT may be an efficient therapeutic modality for the management of oral lesions related to platelet disorders induced by oncologic treatments. Importantly, the technique proved to be safe and fast, being an easy alternative therapy to implement in a hospital environment.

### Acknowledgment

The findings and conclusions of this case report are the responsibility of the authors.

### Conflict of Interests

No potential conflict of interest was reported by the authors.

### Ethical Considerations

Informed consent was obtained from the patient for the publication of this case report.

### References

1. Akahoshi Y, Kanda J, Gomyo A, Hayakawa J, Komiya Y, Harada N, et al. Risk Factors and Impact of Secondary Failure of Platelet Recovery After Allogeneic Stem Cell Transplantation. *Biol Blood Marrow Transplant.* 2016;22(9):1678-1683. doi:10.1016/j.bbmt.2016.06.003
2. Akahoshi Y, Kimura SI, Gomyo A, Hayakawa J, Tamaki M, Harada N, et al. Delayed platelet recovery after allogeneic hematopoietic stem cell transplantation: Association with chronic graft-versus-host disease and survival outcome. *Hematol Oncol.* 2018;36(1):276-284. doi:10.1002/hon.2427
3. Zhang X, Fu H, Xu L, Liu D, Wang J, Liu K, Huang X. Prolonged Thrombocytopenia Following Allogeneic Hematopoietic Stem Cell Transplantation and Its Association with a Reduction in Ploidy and an Immaturity of Megakaryocytes. *Biol Blood Marrow Transplant.* 2011;17(2):274-280. doi:10.1016/j.bbmt.2010.09.007
4. Gomes AOF, Silva Junior A, Noce CW, Ferreira M, Maiolino A, Torres SR. The frequency of oral conditions detected in hematology inpatients. *Hematol Transfus Cell Ther.* 2018;40(3):240-244. doi:10.1016/j.htct.2018.02.006
5. Campos L, Rezende SB, Simões A, Palma LF, Tateno RY, da Silva RL, Macedo MC. Photobiomodulation and photodynamic therapy for the management of oral graft-versus-host disease: A case report. *Photodiagnosis Photodyn Ther.* 2020;30:101776. doi:10.1016/j.pdpdt.2020.101776
6. Rezende SB, Campos L, Palma LF, Tateno RY, Simões A, Macedo MC, Silva RLD. Photobiomodulation and antimicrobial photodynamic therapy for oral cytomegalovirus reactivation following acute graft-versus-host disease. *Photodiagnosis Photodyn Ther.* 2020;32:101849. doi:10.1016/j.pdpdt.2020.101849