



Effect of Low-Level Laser Therapy on Bone Formation in Rapid Palatal Expansion: A Systematic Review

Arash Farzan^{1*}, Katayoon Khaleghi², Zeynab Pirayesh³

¹Department of Orthodontics and Dentofacial Orthopedics, School of Dentistry, Zanjan University of Medical Sciences, Zanjan, Iran

²School of Dentistry, Zanjan University of Medical Sciences, Zanjan, Iran

³Dental Student, Research Committee, Zanjan University of Medical Sciences, Zanjan, Iran

*Correspondence to

Arash Farzan,
Email: dr.arash.farzan@gmail.com

Received: May 26, 2021
Accepted: January 2, 2022
Published online March 23, 2022



Abstract

Introduction: Crossbite is a common malocclusion with a 7-23% prevalence rate. Treatment is based on the expansion of the mid-palatal suture (MPS) with Rapid Palatal Expansion (RPE) followed by a retention period to reach new bone maturation, enough to maintain the results stable. This systematic review was conducted to evaluate the effectiveness of low-level laser therapy (LLLT) in increasing bone formation in MPS.

Methods: This article was written by the PRISMA checklist. Electronically, 3 databases, namely PubMed, Scopus, and Embase, were searched with the keywords selected based on PICO. Time (2010-2021) and language restrictions were performed.

Results: 528 articles, out of which 374 studies were screened, were found, and 9 full-text articles were subsequently included considering these inclusion criteria: randomized clinical trial (RCT) that examines the efficacy of LLLT in rapid palatal expansion (RPE), age under 15 years, non-surgical RPE with a tooth-supported appliance, and low-intensity laser application. Finally, 4 articles were appraised by Cochrane version 5.2.0 with 7 domains. 3 of 4 articles showed LLLT has a significant impact on bone formation. One of them showed no significant difference in pain perception and bone density between the laser and non-laser groups.

Conclusion: While many studies have assessed the effect of LLLT on bone formation in animal models, high-quality clinical trials are missing in this regard. The available clinical trials suggest a positive effect of LLLT on sutural bone formation after RPE.

Keywords: Laser therapy; Rapid palatal expansion; Bone remodeling; Photobiomodulation.

Introduction

Posterior cross bite is a discrepancy of upper and lower dental arches with a 7%-23% prevalence rate.¹ It can be caused by either tooth position or jaw position or even a combination of both. However, transverse maxillary insufficiency is the most common reason.² This occlusal disharmony and the aesthetic problem can cause jaw growth problems in growing kids and teens.³ There is also a confirmed correlation between maxillary constriction and nasal airway resistance with sleep apnea.^{4,5} The quality of treatment depends on mid-palatal suture (MPS) maturation; thus, for a significant and more effective long-term result, it has been suggested that the treatment should start before the pubertal peak.^{6,7} Rapid maxillary expansion (RME) has been extensively used for this treatment with various appliances. By opting for this method, a strong force can be applied over a short period of time. Depending on the amount and rate of the force, the expansion can happen slowly or rapidly.⁸ A hyrax expander is a tooth-supported appliance that provides

strong forces for RME, and it consists of two phases: the active phase for MPS disjunction that is followed by at least 3 months of retention time.⁹

In addition to complications such as pain, posterior teeth tipping, soft tissue swelling, and recession, RME may relapse after the retention period due to insufficient osseous regeneration in MPS.¹⁰ The acceleration of the suture bone remodeling after expansion would be helpful to prevent relapse and shorten the retention period.¹¹

Different methods have been tested to increase the speed of bone remodeling, like the case of drug injections, the application of ultrasound, an orthodontic treatment combined with periodontal surgery with a bone graft, and the application of low-intensity lasers.¹²

Low-intensity lasers are accepted in orthodontic treatments due to their biostimulating effects on pain reduction,¹³ acceleration in tooth movement,¹⁴ and alveolar remodeling.¹¹ Low-level laser therapy (LLLT) uses low and non-thermal energy to accelerate tissue repair procedures and metabolic bone activities.¹⁵

Many studies on animals^{16,17} and humans¹³ have confirmed the advantages of LLLT during new bone formation. Thus, using LLLT has been recommended to improve the retention of RME.^{18,19} Relevant studies on tooth socket healing,²⁰ tooth movement,²¹ peri-implant boneformation,²² and management of osteoradionecrosis²³ have looked for the effects of LLLT on bone formation.

The features of the lasers and their application protocols, as well as the assessment of bone density with conventional or tomographic radiographs, are important factors, which need to reach a consensus among articles in order to attain more definite treatment protocols.

Several protocols including the type of applied laser, dose, and timing have been used in clinical trials, and there is no consensus on a standard method or even the efficacy of applying LLLT in enhancing bone formation after palatal expansion. This study aimed at a systematic analysis of the effectiveness of LLLT in patients who underwent an RME to help find the best protocol for clinical use and future studies.

Material and Methods

This systematic review was performed based on the Preferred Reporting Items for Systematic Reviews and Meta-Analyses (PRISMA) checklist and final articles which met the inclusion criteria appraised by the Cochrane guideline.

Inclusion Criteria

- Randomized clinical trials (RCTs) that examine the efficacy of LLLT in bone formation or the amount of relapse after RPE in humans

- Age of the participants: < 15 years old
- Expansion protocol: non-surgical RPE with tooth-supported appliances
- Type of the used laser: Low-intensity laser

Exclusion Criteria

- Studies irrelevant to LLLT
- Case reports
- Clinical trials including individuals suffering from craniofacial deformities or syndromes
- Studies involving a mini-screw aiding rapid palatal expansion

An electronic search on PubMed, Scopus, and Embase was conducted. The search was limited to English reports from January 2010 to March 2021.

The search strategy was formulated based on PICO (Population, Intervention, Comparison and Outcomes) instructions, and the keywords for each group were determined. The all-inclusive keywords and the search results can be reviewed in Table 1 and Table 2 respectively.

P: midpalatal suture expansion

I: LLLT application

C: No LLLT application or Sham LLLT application

O: Outcome: retention/ bone healing/ bone formation

Assessment of the Risk of Bias

Studies were categorized into one of the 3 groups: ‘low’, ‘unclear’ and ‘high’ regarding Cochrane handbook version 6.1.²⁴ Each article was appraised by 7 domains.

Data Extraction

The following data were extracted from the literature:

Table 1. Keywords Used in Searching Databases According to PICO

Concept 1	Concept 2	Concept 4
Problem: midpalatal suture expansion	Intervention: LLLT	Outcome: retention/ bone healing
Maxilla (mesh)	Low-level light therapy (mesh)	Bone remodelling (mesh)
Malocclusion (mesh)	Laser therapy (mesh)	Wound healing (mesh)
Crossbite (mesh)	Lasers (mesh)	Regeneration
Palatal expansion technique (mesh)	laser phototherapy (mesh)	Remodelling
Malocclusion	"Low level light therapy"	Wound healing
Palatal expansion technique	"Low power laser therapy"	"Bone healing"
"Rapid maxillary expansion"	"Low level laser therapy"	"Bone repair"
"Rapid palatal expansion"	"Low-power laser irradiation"	"Bone formation"
"Midpalatal suture"	"Low-level laser applications"	Ossification*
RME	"Low-intensity laser"	Osteoclastogenesis
RPE	"Low-output laser"	Osteoconduction
MPS	"Soft laser"	"Osteoblastic bone formation"
Mid palatal	"Light emitting diode"	"Osteoblastic cells"
"Crossbite"	"Laser energy values"	"Bone density**"
"Maxillary transverse deficiency"	Diode lasers	Bone mineral density
Maxillary deficiency	"Laser biostimulation"	"Connective tissue**"
"Maxillary constriction"	"Laser phototherapy"	Relapse*
Maxillary expansion	Photobiomodulation	Retention
"Midpalatal anterior suture"	LLLT	"Maintenance phase"
"Midpalatal posterior suture"	GaAlAs	Retainer*
Midpalatal suture	AlGaAs	Recurrence
	GaAs	
	"Laser irradiation"	
	Laser*	
	Irradiation	
	Low level light therapy	
	Low power laser irradiation	

author, year, sample size, mean age of the contributors, radiography type, intervals of taking records, and the type of appliance used for expanding and its rate of activation, retention period, the laser application points, intervals, and outcomes (Table 3).

Results

The primary search of the databases resulted in 528 articles in total; 126 from PubMed, 288 from Scopus,

and 114 from Embase. Also, 154 duplicates were found and eliminated by Endnote version 8.1. Two authors independently started the screening by reviewing titles and abstracts in separate surveys. Finally, 9 Full texts of the presumed eligible studies were obtained and assessed to match the inclusion criteria. A third author evaluated any disagreements to reach a solution. Finally, 4 articles^{12,13,25,26} met the inclusion criteria. The PRISMA diagram of the included studies is shown in Figure 1. All of the 4 clinical trials were appraised using Cochrane guideline version 5.2.0 in 7 domains to determine the general conditions of the studies (Figure 2).

According to the analysis in Cepera and colleagues' study,²⁶ the initial ages of the patients and the amounts of screw opening in both groups were similar. The bone density between the groups was different at specified times. The means, standard deviations, and Student t-tests were used for drawing a bone-density comparison

Table 2. The Exact Search Strategy for PubMed

Search Strategy	
#1	OR between all keywords for P in title/abstract + 4 keywords in MeSH Terms
#2	OR between all keywords for I in title/abstract + 4 keywords in MeSH Terms
#3	OR between all keywords for O in title/abstract + 2 keywords in MeSH Terms
#4	#1 AND #2 AND #3

Table 3. General Information About Articles and Their Methodology

Author (y)	Cepera et al ²⁶	Garcia, V. J. et al ⁽¹²⁾ (2015)	Ferreira, F. N. et al ⁽²⁵⁾ (2015)	Matos, D. S. et al ⁽¹³⁾ (2020)
Sample Size	7 Males and 7 females	23 Females and 18 males	5 Males and 5 females	20
Age Range (Mean)	10.29	8.45	11	9.15
Intervention (Laser Type)	RME assisted with a diode laser (TWIN Laser; MMOptics, S~ao Carlos, Brazil)	RME assisted with an InGaAlP laser	RME assisted with GaAlAs	RME assisted with a diode laser (DC International, Carmel, CA, USA)
Diagnostic Records	Occlusal radiographs	2 CBCTs	CBCT of the anterior region of the maxilla	digital occlusal radiograph
Intervals of Record Taking	T1: start, T2: immediately after the appliance activations, T3: 3-5 days after T2, T4: a month after T3, T5: 2 months after T4	75 days apart	t0: shortly after disjunction, T1: after the retention period	T1: at the time of screw fixation, T2: 1 month after, T3: 2 months after, T4: 3 months after, T5: 6 months after.
Expander Device	Hyrax expander (DENTSPLY GAC International, Bohemia, NY)	Type S palatal Hyrax expansion screw (Forestadent, Pforzheim, Germany)	Hyrax-type expander with a 13 mm expansion screw (Morelli, Sorocaba, SP, Brazil)	Hyrax expander
Activation Protocol	4 activations on the first day (1 full turn) and 2 daily activations on the following 8 days (half turn)	a quarter turn two times a day until 50 % transversal overcorrection was achieved	A full turn at the moment of installation, followed by 1/2 turn daily activations (1/4 turn in the morning and 1/4 turn at night), until achieving overcorrection (after 14 days)	One full turn for initial activation. From the 2nd day after insertion, 2 daily ¼ turn activations, with an interval of 12 h for 15-21 days
Retention	3 months	6 months	4 months	6 months
Laser Application Points	10 points around the midpalatal suture	One vestibular and 6 palatal points	Incisal papilla, at the regions right and left to the palatal raphe, and most posterior region along the midpalatal suture	6 spots distributed bilaterally, parallel and at a 0.5 cm distance from the suture
Laser Application Stages	s1: from the start of activation for 5 days. s2: immediately after the end of expansion for 3 days. s3: every week for 3 weeks.	Seven applications were made on days 1 (the first day of the retention phase), 7, 14, 28, 42, 56, and 70.	12 sessions in total: Twice a week in the first month and once a week in the second month.	5, 10, and 15 days after screw fixation and then once a week for 8 weeks
Density Analysis	Two reference lines were drawn in occlusal images taken with the step wedge technique (the higher the value, the more bone is present in the area)	Inferior suture and superior suture	The distance between the alveolar crest and the incisal foramen	Radiographs were evaluated by software to measure pixel values of previously defined selections.
Outcomes	LLLT can speed up the bone formation	LLLT stimulates the repair process during the retention period	LLLT accelerates bone repair after RME	No effects were observed after RME and using LLLT.

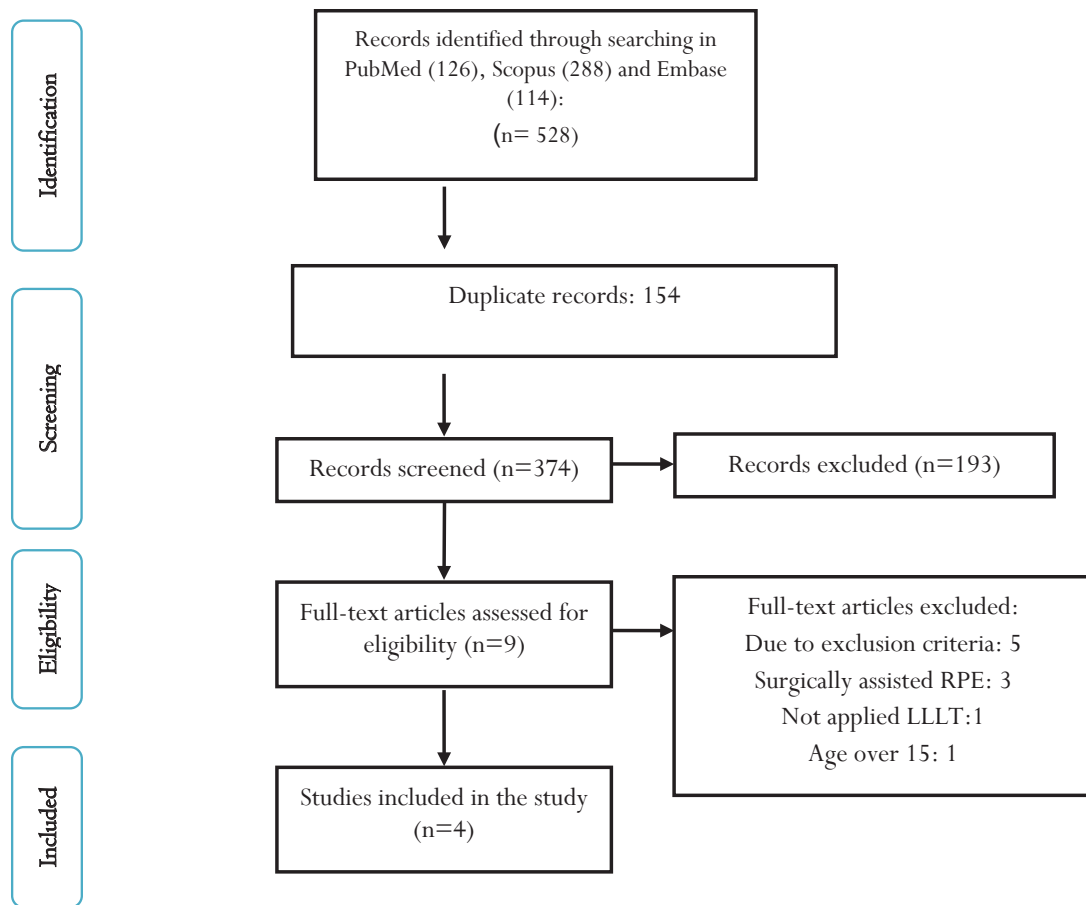


Figure 1. Search Strategy According to the PRISMA

Denise Souza Matos	Ferreira, F. N	Valentin Javier Garcia	Fernanda Cepera	
🟡	🟢	🟢	🟡	Adequate sequence generation
🟡	🟡	🟡	🟡	Allocation concealment
🟢	🟢	🟢	🟡	Blinding (Subjective outcomes)
🟢	🟢	🟢	🟢	Blinding (Mortality)
🔴	🟢	🟢	🔴	Incomplete outcome data addressed (Short-term outcomes)
🟢	🟢	🔴	🟢	selective reporting
🟢	🟢	🟢	🟢	other bias

Figure 2. Risk of Bias Assessment With Cochrane Version 5.2.0.

between the radiograph times (T1-T5) of the laser group and the no-laser group. The analysis showed a significant decrease in density during screw opening (T2-T1) and a significant increase in density during the final evaluation period (T5-T4). In the no-laser group, there was no statistically significant difference in densities during the evaluated periods.

In Garcia and colleagues' study,¹² age and gender were approximately similar in both groups. The approximation of four areas was assessed in 2 CBCT (cone-beam computed

tomography) with 75-day intervals. All four distances almost showed a greater degree of approximation in 27% of irradiated patients. On day 75 of retention (CBCT 2), the analysis showed a significant difference in superior distance between the two groups.

In Ferreira and colleagues' study,²⁵ similar to Garcia and colleagues', there was an increase in the final optical densities (OD) from T0 to T1 in both groups, and this increase was significant in the laser group. The student *t* test showed a statistically significant difference between the two groups at final OD (T1).

In Matos and colleagues' study,¹³ unlike the other three, the mean age of the control group (8.2 years) was significantly lower than the laser group (9.2) ($P=0.0308$), but sex was kept similar between the two groups. This article showed no significant difference in bone formation and pain sensation in the case of laser irradiation. The bone density was low in both groups of 3 months versus 6 months. The very fact proved that only time influenced bone formation. Children at the age of 7 also demonstrated less pain than 11-year-old children ($P=0.0176$).

Discussion

The most common concern for orthodontists after crossbite treatment is the probability of relapse.²⁷ The amount of relapse depends on the amount of bone

formation in MPS related to longer retention time.¹³ One of the methods for decreasing the retention time is the application of LLLT since the effect of LLLT is dose-dependent.²⁸ Further clinical studies are required to find the best protocol. In this systematic review, we analyzed the effectiveness of LLLT in MPS' bone density and discussed the major factors that influenced the results.

Radiographs Used for the Assessment of Bone Density

In many articles, conventional radiography like occlusal one is an adequate tool to evaluate the opening of the MPS. But the existence of the different types of tissues, the probability of the superimposition of structures owing to the two-dimensional (2D) representation of three-dimensional structures in a single plane,²⁹ and technical and processing errors may interfere with the diagnostic quality of images.³⁰ In another technique, contrast and density levels can be adjusted with digital imaging and a lower dose of radiation is required, but limitations of 2-dimensional images still exist.³¹ Because of the ability of analysis in different planes and depths in CBCT and the studies that assess the infra-bony defects caused by periodontal disease or identifying clinical bone defects such as fenestrations and dehiscence, using CBCT has higher integrity and accuracy in diagnosis.^{12,31}

However, CBCT can evaluate bone quality, while density measurement does not seem to be valid.¹² Besides the differentiation in the type of radiographs, the frequency of the radiographs, the place and the number of anatomic zones, as reference points are different in studies, make comparisons difficult.

Cepera et al took 128 occlusal radiographs in 7 intervals from the beginning of the treatment. Because of the large number of radiographs taken and some difficulty in standardizing the days of radiograph retrieval, the lack of some radiographs during the evaluation period happened.²⁶ Ferreira et al and Garcia et al both used CBCT for radiographic analysis. But in Ferreira and colleagues' study, CBCT scanning was limited to the anterior region of the maxilla to reduce the radiation exposure of the patients. The second CBCT in Ferreira and colleagues' study was taken 75 days later than 6 months in Garcia and colleagues'. The mean bone density of three points in a coronal section of the anterior part of the maxilla was calculated in Ferreira and colleagues' study, and Garcia et al assessed 4 inter-sutural references in the sagittal plane in both anterior and posterior parts.^{12,25} Matos et al used digital occlusal radiographs 5 times. The first 15 days after activation and the other four days were taken in the retention period. The reference point was selected in the center of the expanded MPS in Matos and colleagues' study and the anterior region in Cepera and colleagues'. The overall method of these two articles was similar.^{13,26}

According to some studies, using CBCT would produce more accurate results, and because of the triangular

configuration of the expanded suture with the maximum opening at the incisors region, in order to avoid metal artifact in radiographs due to the presence of the expander appliance in the site, it is recommended to choose the anterior part of the maxilla as a reference point which is far apart from the Appliance.^{12,13,25,26,29,31,32}

Time of the Initiation of the Laser Irradiation

Another controversial question is when is better to start LLLT application? Like the other issues, this topic is also different in literature.

Because some studies in rats reported that the laser was more effective during the initial stages of bone regeneration.³³ It is also stated in articles that LLLT could increase bone regeneration and accelerate MPS expansion.^{17,26} Three of the four articles started laser application from the activation period. Cepera et al started LLLT application from the start of expansion screw activation and analysis showed a reduction in bone level, demonstrating facilitation in opening the MPS.²⁶ In the studies by Cepera et al, Ferreira et al, and Matos et al, the frequency of laser radiation was higher in the activation time.^{13,25,26} In contrast with these studies, Garcia et al applied the laser 7 times only in retention time. The authors stated that due to the younger age of the participants and lack of reliable results, they did not need to start from the beginning.¹²

Except for the effectiveness of LLLT in MPS acceleration, because of other benefits of lasers, such as their effectiveness in pain reduction¹³ and wound healing,³⁴ and for better comparison between studies, we recommend that LLLT should be applied from the initial phase of treatment in future studies.

Laser Application

The place of laser application, the number of points, total radiation time and dosage, and the tube's location are effective factors in outcomes. On average, in four articles, LLLT was applied ten times for each person during the study. Also, on average, seven points, most of which were located in the anterior region, were irradiated. Furthermore, in all four articles, the incisive papilla was a point of application.^{12,13,25,26} Because of the greater importance of the front area, Garcia et al applied the LLLT to both sides of the jaw (vestibular and palatal).¹²

Garcia et al applied a 660nm laser with different amounts of energy per point (6 J and 3 J). The total laser dosage was not mentioned clearly.¹² Cepera et al applied 780nm with a total dose of 44 J,²⁶ and Ferreira et al used 780nm and the total applied dose was 140 J/cm².²⁵ Matos et al applied 980nm with 238.85 J/cm² total Radiant exposure.¹³ Although Matos et al concluded that the bone formation was not significantly affected by LLLT and was influenced only by time, authors believe that laser impacts like bone formation and suture healing depend on the dose, time,

and frequency irradiation.^{13,35} However, for more accurate results, further studies are needed. However, according to these three available studies and following the indication of the literature that for the young patients the application of the 1/3 of the adult dose is enough,³⁶ for future studies we recommend trying the efficacy of the lowest laser power and dosage.

Age

The effect of age on MPS is evident, and for more accessible treatment with a more satisfactory prognosis, it is better to start the treatment before the pubertal peak grows.³⁷⁻³⁹ Therefore, to reach uniformity, we included articles with similar age and treatment protocols.

Retention

Most of the studies stated that a retention period of three months is not sufficient, and a six-month retention time is more appropriate.^{6,9,13} Matos et al also showed that bone density in six months was higher than three months.¹³ Nevertheless, most of the studies done on LLLT showed that applying LLLT could significantly reduce the retention period, which is a notable advantage for the therapist and the patient.⁴⁰

Conclusion

LLLT seems to be an effective intervention to accelerate bone formation and be used in RPE to reduce retention time. According to the available literature, further studies, especially long-term, prospective randomized controlled clinical trials, including larger sample size, are needed to generate safe results and achieve the best method which is clinically applicable. However, according to the currently available data, clinical trials suggest a positive effect of LLLT on sutural bone formation after RPE.

Conflict of Interests

The authors declare that they have no conflict of interest.

Ethical Considerations

Not applicable.

References

- da Silva Filho OG, Santamaria M Jr, Capelozza Filho L. Epidemiology of posterior crossbite in the primary dentition. *J Clin Pediatr Dent.* 2007;32(1):73-8. doi: 10.17796/jcpd.32.1.h53g027713432102.
- Aloufi F, Preston CB, Zawawi KH. Changes in the upper and lower pharyngeal airway spaces associated with rapid maxillary expansion. *Int Sch Res Notices* (Online). 2012;2012. doi:org/10.5402/2012/290964
- Castañer Peiró A. Interceptive orthodontics: The need for early diagnosis and treatment of posterior crossbites. *Med Oral Patol Oral Cir Bucal.* 2006;11:E210-4.
- Cistulli PA, Sullivan CE. Influence of maxillary morphology on nasal airway resistance in Marfan's syndrome. *Acta Otolaryngol.* 2000;120(3):410-3. doi: 10.1080/000164800750000658.
- Johal A, Conaghan C. Maxillary morphology in obstructive sleep apnea: a cephalometric and model study. *Angle Orthod.* 2004;74(5):648-56. doi:10.1043/0003-3219(2004)074<0648:MMIOSA>2.0.CO;2.
- Baccetti T, Franchi L, Cameron CG, McNamara JA. Treatment timing for rapid maxillary expansion. *Angle Orthod.* 2001;71(5):343-50. doi:10.1043/0003-3219(2001)071<0343:TFRME>2.0.CO;2
- Suri L, Taneja P. Surgically assisted rapid palatal expansion: a literature review. *Am J Orthod Dentofacial Orthop.* 2008;133(2):290-302. doi: 10.1016/j.ajodo.2007.01.021.
- Muchitsch AP, Winsauer H, Wendl B, Pichelmayer M, Kuljuh E, Szalay A, et al. Remodelling of the palatal dome following rapid maxillary expansion (RME): laser scan-quantifications during a low growth period. *Orthod Craniofac Res.* 2012;15(1):30-8. doi: 10.1111/j.1601-6343.2011.01534.x.
- Costa JG, Galindo TM, Mattos CT, Cury-Saramago AA. Retention period after treatment of posterior crossbite with maxillary expansion: a systematic review. *Dental Press J Orthod.* 2017;22(2):35-44. doi: 10.1590/2177-6709.22.2.035-044.oar.
- Ghergu Jianu A, Chaqués-Asensi J, Llamas Carreras JM, Perillo L. Nonsurgical maxillary expansion in adults: report on clinical cases using the Hyrax expander. *Minerva Stomatol.* 2019;68(2):95-103. doi: 10.23736/S0026-4970.19.04178-5.
- Abreu MER, Viegas VN, Pagnoncelli RM, Martinelli E, de Lima S, Farret AM, et al. Infrared laser therapy after surgically assisted rapid palatal expansion to diminish pain and accelerate bone healing. *World J. Orthod.* 2010;11(3):273-7.
- Garcia VJ, Arnabat J, Comesaña R, Kasem K, Ustrell JM, Pasetto S, et al. Effect of low-level laser therapy after rapid maxillary expansion: a clinical investigation. *Lasers Med Sci.* 2016;31(6):1185-94. doi: 10.1007/s10103-016-1970-3.
- Matos DS, Palma-Dibb RG, de Oliveira Santos C, da Conceição Pereira Saraiva M, Marques FV, Matsumoto MAN, et al. Evaluation of photobiomodulation therapy to accelerate bone formation in the mid palatal suture after rapid palatal expansion: a randomized clinical trial. *Lasers Med Sci.* 2021;36(5):1039-1046. doi: 10.1007/s10103-020-03141-9.
- Sousa MVS. *Lasers in Dentistry: Guide for Clinical Practice.* Wiley-Blackwell; 2015.
- Santinoni CD, Oliveira HF, Batista VE, Lemos CA, Verri FR. Influence of low-level laser therapy on the healing of human bone maxillofacial defects: A systematic review. *J Photochem Photobiol B.* 2017;169:83-89. doi: 10.1016/j.jphotobiol.2017.03.004.
- Mohaghegh S, Mohammad-Rahimi H, Eslamian L, Ebadifar A, Badiie MR, Farahani M, et al. Effect of mesenchymal stem cells injection and low-level laser therapy on bone formation after rapid maxillary expansion: an animal study. *Am J Stem Cells.* 2020;9(5):78-88.
- Eslamian L, Ebadifar A, Rad MM, Motamedian SR, Badiie MR, Mohammad-Rahimi H, et al. Comparison of Single and Multiple Low-Level Laser Applications After Rapid Palatal Expansion on Bone Regeneration in Rats. *J Lasers Med Sci.* 2020;11(4):S37-S42. doi: 10.34172/jlms.2020.S6.
- da Silva AP, Petri AD, Crippa GE, Stuani AS, Stuani AS, Rosa AL, et al. Effect of low-level laser therapy after rapid maxillary expansion on proliferation and differentiation of osteoblastic cells. *Lasers Med Sci.* 2012;27(4):777-83. doi: 10.1007/s10103-011-0968-0.
- Prado GP, Pereira MD, Biló JP, Furtado F, Ferreira LM. Stability of surgically assisted rapid palatal expansion: a randomized trial. *J Dent Res.* 2013;92(7Suppl):49S-54S. doi: 10.1177/0022034513486899.
- Noda M, Aoki A, Mizutani K, Lin T, Komaki M, Shibata S, et al. High-frequency pulsed low-level diode laser therapy accelerates wound healing of tooth extraction socket: An

- in vivo study. *Lasers Surg Med*. 2016;48(10):955-964. doi: 10.1002/lsm.22560.
21. Kalemaj Z, Debernardi CL, Buti J. Efficacy of surgical and non-surgical interventions on accelerating orthodontic tooth movement: a systematic review. *Eur J Oral Implantol*. 2015;8(1):9-24.
 22. Prados-Frutos JC, Rodríguez-Molinero J, Prados-Privado M, Torres JH, Rojo R. Lack of clinical evidence on low-level laser therapy (LLLT) on dental titanium implant: a systematic review. *Lasers Med Sci*. 2016;31(2):383-92. doi: 10.1007/s10103-015-1860-0.
 23. Khan AA, Morrison A, Hanley DA, Felsenberg D, McCauley LK, O’Ryan F, et al. International Task Force on Osteonecrosis of the Jaw. Diagnosis and management of osteonecrosis of the jaw: a systematic review and international consensus. *J Bone Miner Res*. 2015;30(1):3-23. doi: 10.1002/jbmr.2405.
 24. Higgins JP, Thomas J, Chandler J, Cumpston M, Li T, Page MJ, Welch VA, editors. *Cochrane handbook for systematic reviews of interventions*. John Wiley & Sons; 2019 Sep 23.
 25. Ferreira FN, Gondim JO, Neto JJ, Dos Santos PC, de Freitas Pontes KM, Kurita LM, et al. Effects of low-level laser therapy on bone regeneration of the midpalatal suture after rapid maxillary expansion. *Lasers Med Sci*. 2016;31(5):907-13. doi: 10.1007/s10103-016-1933-8.
 26. Cepera F, Torres FC, Scanavini MA, Paranhos LR, Capelozza Filho L, Cardoso MA, et al. Effect of a low-level laser on bone regeneration after rapid maxillary expansion. *Am J Orthod Dentofacial Orthop*. 2012;141(4):444-50. doi: 10.1016/j.ajodo.2011.10.023.
 27. Gurel HG, Memili B, Erkan M, Sukurica Y. Long-term effects of rapid maxillary expansion followed by fixed appliances. *Angle Orthod*. 2010;80(1):5-9. doi: 10.2319/011209-22.1.
 28. Çokakoğlu S, Aydoğan Akgün F, Aydın B. Low Level Laser Therapy in Orthodontics. *Meandros med dental j*. 2018;19:99-105. doi: 10.4274/meandros.88598
 29. Queiroz PM, Santaella GM, Groppo FC, Freitas DQ. Metal artifact production and reduction in CBCT with different numbers of basis images. *Imaging Sci Dent*. 2018;48(1):41-4. doi:10.5624/isd.2018.48.1.41
 30. Rozylo-Kalinowska I. Technical Errors and Artefacts in Dental Radiography. In: *Imaging Techniques in Dental Radiology*. Springer, Cham; 2020. https://doi.org/10.1007/978-3-030-41372-9_7
 31. Choi IGG, Cortes ARG, Arita ES, Georgetti MAP. Comparison of conventional imaging techniques and CBCT for periodontal evaluation: A systematic review. *Imaging Sci Dent*. 2018;48(2):79-86. doi: 10.5624/isd.2018.48.2.79.
 32. Agarwal A, Mathur R. Maxillary Expansion. *Int J Clin Pediatr Dent*. 2010;3(3):139-46. doi: 10.5005/jp-journals-10005-1069
 33. Ueda Y, Shimizu N. Effects of pulse frequency of low-level laser therapy (LLLT) on bone nodule formation in rat calvarial cells. *J Clin Laser Med Surg*. 2003;21(5):271-7. doi: 10.1089/104454703322564479.
 34. Fujiyama K, Deguchi T, Murakami T, Fujii A, Kushima K, Takano-Yamamoto T. Clinical effect of CO₂ laser in reducing pain in orthodontics. *Angle Orthod*. 2008;78(2):299-303. doi: 10.2319/033007-153.1
 35. Santiago VC, Piram A, Fuziy A. Effect of soft laser in bone repair after expansion of the midpalatal suture in dogs. *Am J Orthod Dentofacial Orthop*. 2012;142(5):615-24. doi: 10.1016/j.ajodo.2012.05.015.
 36. Machado MAAM, Sakai VT, Silva TC, Tessarolli V, Carvalho FP, Moretti ABS, et al. Therapeutic laser in surgical procedures of pediatric dentistry. *J Oral Laser Appl*. 2010;10(4):175-80.
 37. Ren C, McGrath C, Yang Y. The effectiveness of low-level diode laser therapy on orthodontic pain management: a systematic review and meta-analysis. *Lasers Med Sci*. 2015;30(7):1881-93. doi: 10.1007/s10103-015-1743-4.
 38. Angelieri F, Franchi L, Cevidanes LH, Bueno-Silva B, McNamara JA Jr. Prediction of rapid maxillary expansion by assessing the maturation of the midpalatal suture on cone beam CT. *Dental Press J Orthod*. 2016;21(6):115-125. doi: 10.1590/2177-6709.21.6.115-125.sar.
 39. Tonello DL, Ladewig VM, Guedes FP, Ferreira Conti ACC, Almeida-Pedrin RR, Capelozza-Filho L. Midpalatal suture maturation in 11- to 15-year-olds: A cone-beam computed tomographic study. *Am J Orthod Dentofacial Orthop*. 2017;152(1):42-48. doi: 10.1016/j.ajodo.2016.11.028.
 40. S Skondra FG, Koletsi D, Eliades T, Farmakis ETR. The Effect of Low-Level Laser Therapy on Bone Healing After Rapid Maxillary Expansion: A Systematic Review. *Photomed Laser Surg*. 2018;36(2):61-71. doi: 10.1089/pho.2017.4278.