

Implant Bed Preparation with an Erbium, Chromium Doped Yttrium Scandium Gallium Garnet (Er,Cr: YSGG) Laser Using Stereolithographic Surgical Guide

Gülin Seymen¹, Zeynep Turgut¹, Gizem Berk², Ayşen Bodur¹

¹Department of Periodontology, Faculty of Dentistry, University of Gazi, 06510 Emek, Ankara, Turkey

²Denta Form, Ankara, Turkey

Abstract:

Background: Implant bed preparation with laser is taken into consideration owing to the increased interest in use of lasers in hard tissue surgery. The purpose of this study is to determine the deviations in the position and inclination between the planned and prepared implant beds with Erbium, Chromium doped Yttrium Scandium Gallium Garnet (Er,Cr: YSGG) laser using stereolithographic (SLA) surgical guides.

Methods: After 3-dimensional (3D) imaging of six sheep lower jaws, computed tomography (CT) images were transformed into 3D models. Locations of implant beds were determined on these models. Two implant beds in each half jaw were prepared with an Er,Cr:YSGG laser system and a conventional drilling method using a total of 12 SLA surgical guides. A new CT was taken to analyze the deviation values between planned and prepared implant beds. Finally, a software program was used to superimpose the images on 3D models, then the laser and conventional drilling groups were compared.

Results: Differences of mean angular deviations between the planned and prepared implant beds were $5.17 \pm 4.91^\circ$ in the laser group and $2.02 \pm 1.94^\circ$ in the conventional drilling group. The mean coronal deviation values were found to be 0.48 ± 0.25 mm and 0.23 ± 0.14 mm in the laser group and conventional drilling group, respectively. While the mean deviation at the apex between the planned and prepared implant beds were 0.70 ± 0.26 mm and 0.26 ± 0.08 , the mean vertical deviations were 0.06 ± 0.15 mm and 0.02 ± 0.05 mm for the laser group and the conventional drilling group, respectively.

Conclusion: It is possible to prepare an implant bed properly with the aid of Er,Cr:YSGG laser by using SLA surgical guide.

Keywords: laser; surgery; computer-assisted; dental implants

Please cite this article as follows:

Seymen G, Turgut Z, Berk G, Bodur A. Implant Bed Preparation with an Er,Cr:YSGG Laser Using Stereolithographic Surgical Guide. *J Lasers Med Sci* 2013; 4(1):25-32

***Corresponding Author:** Gülin Seymen, DDS; Department of Periodontology, Faculty of Dentistry, University of Gazi, Bişkek Caddesi 84, Sokak 06510 Emek, Ankara, Turkey. Fax Number: +312-2239226; E-mail: dtgulinsaymen@hotmail.com

Introduction

Recent improvements in dental implantology have provided the opportunity to rehabilitate edentulous and partially edentulous patients (1). Pre-surgical implant planning is the most critical phase to achieve functional implants as well as successful and esthetic outcome

of implant supported prostheses (2). Before dental implant surgery, in addition to anatomic structures (mandibular canal, maxillary sinus, etc.), the volume and density of jaw bone should be examined to avoid complications. Furthermore, the locations of the implants need to be determined to obtain successful biomechanical, functional and esthetic outcomes (3,4).

The use of stereolithographic (SLA) surgical guides made the diagnosis possible using 3-dimensional (3D) imaging and transferring the exact plan to the surgical area (5,6). SLA surgical guides are manufactured to transfer the depth, angle and precise localization of the planned implant to the operation area (2). Besides, flapless implant surgery could be achieved by using this method. Flapless implant surgery is a minimally invasive surgical approach. The main advantages of flapless implant surgery are decreased operation time, reduced postoperative complications (e.g. pain and swelling) and increased patient comfort after the operation. Despite the benefits, flapless implant surgery has however generally been perceived as a blind procedure because of the lack of visibility of anatomical features and critical structures, such as nerves and blood vessels (7). In addition, uncontrolled removal of keratinized gingiva due to the use of mucotome was notified as a complication of flapless implant approach (8).

StentCad® Beyond (Ay Tasarim Ltd., Ankara, Turkey) is a recently introduced SLA surgical guide system used for accurate implant placement. This SLA surgical guide system has been developed in order to avoid complications as mentioned in previous studies (7,9). With StentCad® Beyond, unlike conventional guide systems, no metal tube is used but handpiece is guided to fix the position of the drill. Thereby, the system is compatible to drills of all implant systems. Also, this method is designed to prevent the friction between the drill and metal tube or surgical guide.

Generally, the bone quality and quantity have been important factors in osseointegration of dental implants (10,11). However; implant macro design, drilling speed and pressure, sharpness and design of the cutting tool, mechanical trauma in the adjacent bone and surgical technique have to be considered to achieve favorable outcomes in implant surgery (12). Hence, implant bed preparation should be performed gently to enhance osseointegration. For this reason, it is of major interest to utilize new techniques for implant bed preparation to improve clinical success.

The use of hard tissue lasers as an alternative and supplementary treatment method in implant dentistry has gained popularity over the past several years. In particular, the applicability of the Erbium, Chromium doped Yttrium Scandium Gallium Garnet (Er,Cr: YSGG) laser hydrokinetic system with a wavelength of 2780 nm in the near infrared spectrum (13) has been investigated for bone ablation during implant

bed preparation (14,15). Er,Cr:YSGG laser allows bone tissue cutting due to the absorption of its laser energy by water droplets (13,16). Bone tissue ablation with Er,Cr:YSGG laser has major advantages such as absence of vibration and bone dust (17), enhanced visualization of the surgical field due to hemostasis, improved patient comfort with less postoperative pain and edema (18). In addition; Er,Cr:YSGG laser has bactericidal effect on bone tissue ablation. Previous reports have shown that Er,Cr:YSGG laser may provide straight, clean and precise bone ablation, and cause minimal thermal damage to the adjacent tissue (19,20). Few studies reported the effects of hard tissue laser on bone ablation during implant bed preparation (12,14,15,22). Nevertheless, depth control during implant bed preparation is still a problem that needs a solution. We hypothesized that using StentCad® Beyond with Er,Cr:YSGG laser may be a feasible method for preparation of implant bed with desired diameter, angle and depth. For this purpose, we examined the deviations in the position and inclination between the planned and prepared implant beds and compared them with those obtained with the conventional drilling method.

Methods

The study was conducted using six sheep lower jaws. As stated in other studies, bone samples were stored in a 10% formalin solution prior to fabrication of guides, possibly minimizing changes in mineral parameters. Preservation of bone by formalin fixation does not adversely affect the drilling efficacy of laser.

After 3D imaging, six jaws with similar bone density and trabecular structure were selected and included into the research among 20 sheep jaws.

The steps below were followed during the study:

Preoperative Computed Tomography (CT) Imaging

Preoperative CT images of sheep lower jaws were obtained using the standard setup of 80 kVp, 150 mA with an exposure time of 16 seconds by CT device (Discovery 16 ST, General Electric, Milwaukee, WI). DICOM slices of 0,625 mm in thickness were transferred to the StentCad® implant simulation software (Media Lab Srl, Via Trieste, Italy) which was used to plan implant bed locations and angles in line with anatomic limitations and prosthetic considerations.

Conversion of CT Images to 3D Models by Software

The axial cross-sections obtained after CT imaging were exported in DICOM 3.0 format. The images kept in DICOM format were reconstructed to 3D models in StentCad® software.

3D Computer-Aided Simulation

After obtaining 3D models, locations of implant beds were determined. In order to prepare two implant beds with 3 mm diameter and 8 mm length to each half jaw, SLA guides were prepared after the simulation of implant beds on 3D bone images. For each jaw, two surgical guide systems were fabricated. For one half of each jaw, guides adapted to laser handpiece and for the other halves, guides adapted to drilling handpiece were prepared.

Preparation of Implant Beds with Er,Cr:YSGG Laser and Conventional Drill

Once the surgical guides were fabricated, the implant beds were prepared with the aid of the Er,Cr:YSGG laser and the drill. Two implant beds in each half jaw – in total 4 implant beds with 3 mm diameter and 8 mm length – were prepared with Er,Cr:YSGG laser and drill using StentCad® Beyond.

In the study; an Er,Cr:YSGG laser (Waterlase MD, Biolase Technology, San Clemente, CA, USA) emitting photons with a wavelength of 2.78 μm , with a pulse duration of 140 μs and a repetition rate of 30 Hz was used. The ablation was performed in a non-contact mode, with the sapphire tip which is 600 μm in diameter and 8 mm in length (MG6). The parameters were determined with the pilot study performed before the experiment. Therefore, the Er,Cr:YSGG laser was employed at 5.0 W with a 80% water and 90% air spray during irradiation. The energy density was in the range of 16.6 to 22.41 J/cm² for 166 mJ pulse energy. The sapphire tip was kept perpendicular to the irradiated bone surface. The distance between the sapphire tip and the target tissue was maintained at 2 mm by using SLA guide. Handpiece apparatus can proceed up to 6 mm depth in base part (Figure 1). The other 12 implant beds' locations were drilled according to manufacturer's drilling sequence (BioHorizons Implant, BioHorizons Inc, USA). The drill with diameter of 3 mm was used in order to prepare implant




Figure 1. SLA surgical guide adapted to Er,Cr:YSGG laser. StentCad® Beyond surgical guide consists of two parts: handpiece apparatus and base plate. Handpiece apparatus fits into anguldruva with exact conformity. The distance between the tip and the target tissue is 2 mm. Handpiece apparatus can proceed up to 6 mm depth in base part. beds with conventional drilling procedure using SLA surgical guide.

Postoperative CT Imaging and Matching Procedure

3D models obtained from the tomographic images taken after preparing the beds and the models used for preoperative planning were superimposed with registration method using VR-Mesh software (VR-Mesh Studio, Bellevue City, WA, USA). While superimposing the preoperative and postoperative 3D models, 3D components, which allow the visualization of the planned and prepared 3D implant beds in different colors, were utilized (Figure 2). After removing the bone volume from a 3D reconstructed model, only these 3D components remained. Values of angular, apical, coronal and vertical deviations between the vectors crossing from the center points of these 3D components were measured in VR-Mesh software (Figure 3).

Statistical Analysis

Data analysis was performed by using Statistical Package for Social Sciences (SPSS) version 11.5 software (SPSS Inc., Chicago, IL, USA). Shapiro-Wilk test was used to test the normality of the distribution for continuous variables. The data were expressed as mean \pm standard deviation. Whether the differences between laser and conventional drilling groups regarding angular, coronal, apical and vertical deviation measurements were statistically significant or not was evaluated by using the Bonferroni Adjusted



Figure 2. 3D model with 3D components

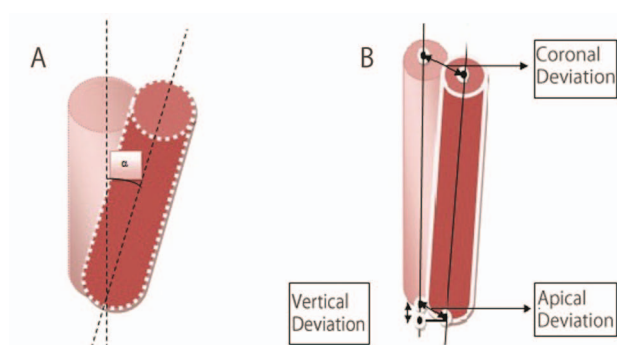


Figure 3. (A) Angular Deviation (α); the angle between the vectors crossing from the centers of the planned and the prepared implant beds. (B) Coronal Deviation; distance between the coronal centers of the planned and prepared implant beds. Apical Deviation; distance between the apical centers of the planned and prepared implant beds. Vertical Deviation; distance between the center tip of the planned and prepared implant beds.

multiple comparison test with Repeated Measures of ANOVA method. A p value less than 0.05 was considered statistically significant.

Results

Table 1 shows the deviations between the planned and prepared implant beds for Er,Cr:YSGG laser and conventional drilling group.

Compared to the planning, the mean angular deviation of Er,Cr:YSGG laser group and conventional

Table 1. Deviations of Prepared Implant Beds with Er,Cr:YSGG Laser Using SLA Surgical Guide ($P < 0.05$)

Deviations	Er,Cr:YSGG Laser	Conventional Drill	P Value
Angular deviation ($^{\circ}$)	5.17±4.91	2.02±1.94	0.060
Coronal deviation (mm)	0.48±0.25	0.23±0.14	0.031*
Apical deviation (mm)	0.70±0.26	0.26±0.08	0.005*
Vertical deviation (mm)	0.06±0.15	0.02±0.05	0.408

*Statistically significant.

drilling group were $5.17 \pm 4.91^{\circ}$ and $2.02 \pm 1.94^{\circ}$, respectively. The angular deviation values did not differ significantly between the laser and drill groups ($P > 0.05$) (Figure 4). For Er,Cr:YSGG laser and conventional drilling groups, the mean deviations in distance between the coronal centers of the planned and prepared implant beds were 0.48 ± 0.25 and 0.23 ± 0.14 mm, respectively. The mean coronal deviation values of laser group were significantly higher than the conventional drilling group ($P < 0.05$). When the implant beds prepared with Er,Cr:YSGG laser and conventional drill were matched with the planned implant beds, the average apical deviation values were 0.70 ± 0.26 mm and 0.26 ± 0.08 mm, respectively. In general, the largest distance between the planned and prepared implant beds was observed in apical deviation for laser group. For the apical deviation parameter, a statistically significant difference was found between two groups ($P < 0.05$). The vertical deviation between planned and prepared implant beds for Er,Cr:YSGG laser and conventional drilling group were 0.06 ± 0.15 mm and 0.02 ± 0.05 mm, respectively. No statistical difference was observed between these two groups ($P > 0.05$) (Figure 5).

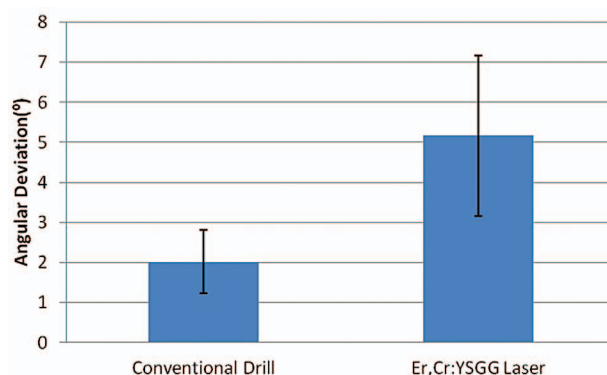


Figure 4. Angular deviations of conventional drill and Er,Cr:YSGG laser groups

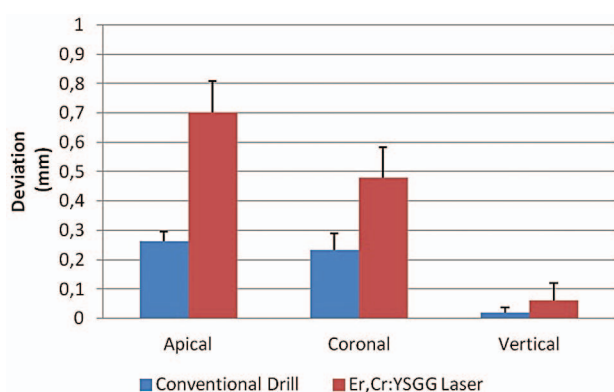


Figure 5. Apical, coronal and vertical deviations of conventional drill and Er,Cr:YSGG laser groups

Discussion

Pre-surgical 3D implant planning is necessary for better esthetical and biomechanical properties. 3D implant planning also makes it possible to rehabilitate the edentulous jaw bone with insufficient bone size or poor bone density (23). Reconstruction of 3D images of the jaw bone and the fabrication of the stereolithographic guides is possible by use of CT data (24).

The use of conventional drilling method in implant surgery has some disadvantages, including thermal necrosis, aerosolized particle release, vibration and bone debris formation in operation field (19,20). On the other hand, the use of lasers in implant surgery as an alternative to conventional instruments and methods is expanding dramatically as a result of increasing knowledge about the effects of lasers on dental hard tissues. In many studies, the effects of Er,Cr:YSGG laser irradiation on different tissue surfaces have been evaluated (25,28).

The scope of laser applications in implant dentistry is broad, and includes the manufacture of implants (29), pre-prosthetic hard and soft tissue surgery, uncovering implants (30), correcting soft tissue (31), treating peri-implantitis and disinfecting implant surfaces (32,33) and finally, altering the response of hard and soft tissues through a process termed "biostimulation" (34-36). Many previous studies have demonstrated that the use of Er,Cr:YSGG laser in bone surgery has advantages like providing effective and precise bone ablation with minimal thermal damage to adjacent tissues (19) in comparison with conventional drilling; however, there are only a few studies evaluating the effects of Er,Cr:YSGG laser on implant bed preparation. Lee et al. (14) who

prepared implant cavities in the pig rib bone using an Er,Cr:YSGG laser device and conventional drills, the laser osteotomy resulted in wider peri-implant gaps especially in the apical areas of the cavities. This phenomenon was also reported by Schwarz et al. (22) who prepared implant channels in the lower jaws of beagle dogs using Er:YAG laser device and conventional drills. Three screw-type titanium implants from different manufacturers were randomly inserted. Healing at second and twelfth weeks were analyzed histologically and histomorphometrically. At two weeks, it was observed that Er:YAG laser osteotomy in a focused mode resulted in wide peri-implant gaps particularly in the apical area of the implant supporting bone. A recently published biomechanical and histological study (12) indicate that during the implant bed preparation, a slight angulation of the laser beam direction led to severe bone loss and inappropriate drill geometries in height and diameter of the implant bed. An individual template was used for circular implant design, but depth control was only possible by visual inspection and the use of gauges and dental probes. In the current study; to provide depth control and prepare implant bed at a desired angle, a SLA surgical guide which guided handpiece was used with an Er,Cr:YSGG laser device and conventional drills. By using this SLA surgical guide system with Er,Cr:YSGG laser, the drawbacks mentioned above were eliminated. The current study was the first one to demonstrate Er,Cr:YSGG laser and SLA surgical guide system combination, in vitro.

In many studies, the reliability of SLA surgical guides adapted to drilling handpiece has been proved. The accuracy of many surgical guide systems of different manufacturers has been analyzed by superposing either the implant beds or implants with planning (37-40). The study by Pettersson et al. (41), in which the accuracy of CAD/CAM-guided surgical template was evaluated by placing 145 implants on 17 human cadaver jaws, reported that the mean angular deviation was 2.64° . Di Giacomo et al. (23) conducted a study using 6 SLA surgical guides in 4 patients to determine the applicability of SLA surgical guides. The mean angular deviation between the planned and placed implants was $7.25 \pm 1.77^\circ$. In this study, the mean angular deviation values of implant beds prepared with Er,Cr:YSGG laser system and conventional drilling method were $5.17 \pm 4.91^\circ$ and $2.02 \pm 1.94^\circ$, respectively. The angular deviations found in our study are within the range of these previously reported studies (23,41). In the

study of Barnea et al. (42), in which 8 implants were placed in sheep jaw using laboratory-based guide, the vertical differences between the planned and placed implant positions at the implant shoulder were within 0.04-0.83±0.17 mm interval. In our study, the distances between the coronal of planned and prepared implant beds for the Er,Cr:YSGG laser and conventional methods were 0.48±0.25 mm and 0.23±0.14 mm, respectively. In their studies in which they evaluated the accuracy of StentCad® Beyond, Murat et al. (43) placed 9 implants to 5 cadaver mandibles using 11 tooth/bone supported guides. The researchers reported a range of 0.29 mm to 2.16 mm for apical deviation and 1.06 mm to 1.92 mm for apical depth deviation of implants that were placed with the same guide we used. In our study, the apical deviations of implant beds that were prepared by Er,Cr:YSGG laser and conventional methods were 0.70±0.26 mm and 0.26±0.08 mm, respectively. Also, the mean vertical deviations of our study obtained from Er,Cr:YSGG laser and conventional drill method were 0.06±0.15 mm and 0.02±0.05 mm, respectively. The results that were measured by previous study correspond to the results of our study. Although the differences between planned and prepared implant beds for coronal and apical deviations were statistically significant, deviation values (<2mm) could be clinically negligible. These findings were in accordance with the results of the study of Cassetta et al. indicating the necessity of a safety zone of at least 2 mm to avoid critical anatomical structures (44).

The technique used in our study for implant bed preparation involved Er,Cr:YSGG laser and SLA surgical guide system combination; in addition, the results demonstrated that with significant contribution of SLA guide system, implant beds can be prepared with acceptable outcome.

The present study was performed on a sheep jaw to mimic the in vivo situation unlike previous studies in which plastic or stone models were used. Moreover, the sheep jaws used in this study were denuded so as to eliminate micromovements that could occur depending on the resilience of mucosa. However, this technique has some limitations such as; being used for the first time in this study and lack of previous research done on the subject.

In conclusion, it is demonstrated that implant beds can be prepared with desired angle, diameter and depth with Er,Cr:YSGG laser system using surgical guide system which guided handpiece. Within the limitations

of our study, preparing implant beds with Er,Cr:YSGG laser system can be an alternative to conventional drilling method. However, further clinical studies are required to evaluate its clinical accuracy and limitations.

Acknowledgments

This study was supported by the Scientific Research Foundation of Gazi University (grant 03/2011-11). The authors report no conflicts of interest in relation to any brand, device or entity mentioned in this study.

References

1. Widmann G, Stoffner R, Keiler M, Zangerl A, Widmann R, Puelacher W, et al. A laboratory training and evaluation technique for computer-aided oral implant surgery. *Int J Med Robot* 2009; 5(3):276-83.
2. Ozan O, Turkyilmaz I, Ersoy AE, McGlumphy EA, Rosenstiel SF. Clinical accuracy of 3 different types of computed tomography-derived stereolithographic surgical guides in implant placement. *J Oral Maxillofac Surg* 2009;67(2):394-401.
3. BouSerhal C, Jacobs R, Quirynen M, van Steenberghe D. Imaging technique selection for the preoperative planning of oral implants: a review of the literature. *Clin Implant Dent Relat Res* 2002; 4(3):156-72.
4. D'Haese J, Van De Velde T, Komiyama A, Hultin M, De Bruyn H. Accuracy and Complications Using Computer-Designed Stereolithographic Surgical Guides for Oral Rehabilitation by Means of Dental Implants: A Review of the Literature. *Clin Implant Dent Relat Res* 2010;14(3):321-35.
5. Arisan V, Karabuda ZC, Ozdemir T. Accuracy of two stereolithographic guide systems for computer-aided implant placement: a computed tomography-based clinical comparative study. *J Periodontol* 2010; 81(1):43-51.
6. Van Assche N, van Steenberghe D, Quirynen M, Jacobs R. Accuracy assessment of computer-assisted flapless implant placement in partial edentulism. *J Clin Periodontol* 2010;37(4):398-403.
7. Azari A, Nikzad S, Kabiri A. Using computer-guided implantology in flapless implant surgery of a maxilla: a clinical report. *J Oral Rehabil* 2008; 35(9):690-4.
8. Cassetta M, Stefanelli LV, Giansanti M, Di Mambro A, Calasso S. Depth deviation and occurrence of early surgical complications or unexpected events using a single stereolithographic surgi-guide. *Int J Oral Maxillofac Surg* 2011;40:1377-87.
9. Di Giacomo GA, da Silva JV, da Silva AM, Paschoal GH, Cury PR, Szarf G. Accuracy and complications of computer-designed selective laser sintering surgical guides for flapless dental implant placement and immediate definitive prosthesis installation. *J Periodontol*

- 2012;83(4):410-9.
10. Wakimoto M, Matsumura T, Ueno T, Mizukawa N, Yanagi Y, Iida S. Bone quality and quantity of the anterior maxillary trabecular bone in dental implant sites. *Clin Oral Implants Res* 2011; doi: 10.1111/j.1600-0501.2011.02347.x.
 11. Blanco J, Alvarez E, Munoz F, Linares A, Cantalapiedra A. Influence on early osseointegration of dental implants installed with two different drilling protocols: a histomorphometric study in rabbit. *Clin Oral Implants Res* 2011;22(1):92-9.
 12. Stubinger S, Biermeier K, Bachi B, Ferguson SJ, Sader R, von Rechenberg B. Comparison of Er:YAG laser, piezoelectric, and drill osteotomy for dental implant site preparation: a biomechanical and histological analysis in sheep. *Lasers Surg Med* 2010;42(7):652-61.
 13. Walsh L. The current status of laser applications in implant dentistry. *Aust Dent J* 2003; 48(3):146-55.
 14. Lee SY, Piao C, Heo SJ, Koak JY, Lee JH, Kim TH, Kim MJ, Kwon HB, Kim SK. A comparison of bone bed preparation with laser and conventional drill on the relationship between implant stability quotient (ISQ) values and implant insertion variables. *J Adv Prosthodont* 2010;2(4):148-53.
 15. Kusek ER. The use of laser technology (Er,Cr:YSGG) and stereolithography to aid in the placement of a subperiosteal implant: case study. *J Oral Implantol* 2009;35(1):5-11.
 16. Kimura Y, Yu DG, Fujita A, Yamashita A, Murakami Y, Matsumoto K. Effects of erbium,chromium:YSGG laser irradiation on canine mandibular bone. *J Periodontol* 2001; 72(9):1178-82.
 17. Zhang X, Xie S, Zhan Z, Zhao H, Guo J. Evaluation of Er,Cr:YSGG laser for hard tissue ablation: an in vitro study. *Front Optoelectron China* 2010;(3):163-8.
 18. Yazici AR, Yildirim Z, Antonson SA, Kilinc E, Koch D, Antonson DE, et al. Comparison of the Er,Cr:YSGG laser with a chemical vapour deposition bur and conventional techniques for cavity preparation: a microleakage study. *Lasers Med Sci* 2012; 27(1):23-9.
 19. Lewandrowski KU, Lorente C, Schomacker KT, Flotte TJ, Wilkes JW, Deutsch TF. Use of the Er:YAG Laser for Improved Plating in Maxillofacial Surgery: Comparison of Bone Healing in Laser and Drill Osteotomies. *Lasers Surg Med* 1996;19:40-5.
 20. Wang X, Ishizaki NT, Suzuki N, Kimura Y, Matsumoto K. Morphological changes of bovine mandibular bone irradiated by Er,Cr:YSGG laser: an in vitro study. *J Clin Laser Med Surg* 2002;20(5):245-50.
 21. Wang X, Zhang C, Matsumoto K. In vivo study of the healing processes that occur in the jaws of rabbits following perforation by an Er,Cr:YSGG laser. *Laser Med Sci* 2005;20:21-7.
 22. Schwarz F, Olivier W, Herten M, Sager M, Chaker A, Becker J. Influence of implant bed preparation using an Er:YAG laser on the osseointegration of titanium implants: a histomorphometrical study in dogs. *J Oral Rehabil* 2007;34(4):273-81.
 23. Di Giacomo GA, Cury PR, de Araujo NS, Sendyk WR, Sendyk CL. Clinical application of stereolithographic surgical guides for implant placement: preliminary results. *J Periodontol* 2005;76(4):503-7.
 24. Komiyama A, Pettersson A, Hultin M, Nasstrom K, Klinge B. Virtually planned and template-guided implant surgery: an experimental model matching approach. *Clin Oral Implants Res* 2011; 22(3):308-13.
 25. Hakki SS, Berk G, Dundar N, Saglam M, Berk N. Effects of root planing procedures with hand instrument or erbium, chromium:yttrium-scandium-gallium-garnet laser irradiation on the root surfaces: a comparative scanning electron microscopy study. *Lasers Med Sci* 2010; 25(3):345-53.
 26. Malkoc MA, Tasdemir ST, Ozturk AN, Ozturk B, Berk G. Effects of laser and acid etching and air abrasion on mineral content of dentin. *Lasers Med Sci* 2011; 26(1):21-7.
 27. Cercadillo-Ibarguren I, Espana-Tost A, Arnabat-Dominguez J, Valmaseda-Castellon E, Berini-Aytes L, Gay-Escoda C. Histologic evaluation of thermal damage produced on soft tissues by CO₂, Er,Cr:YSGG and diode lasers. *Med Oral Patol Oral Cir Bucal* 2010;15(6):e912-8.
 28. Ekworapoj P, Sidhu SK, McCabe JF. Effect of different parameters of Er,Cr:YSGG laser on human dentine. *Lasers Med Sci* 2007;22(3):175-82.
 29. Traini T, Mangano C, Sammons RL, Mangano F, Macchi A, Piattelli A. Direct laser metal sintering as a new approach to fabrication of an isoelastic functionally graded material for manufacture of porous titanium dental implants. *Dent Mater* 2008; 24:1525-33.
 30. Arnabat-Dominguez J, Bragado-Novell M, Espana-Tost AJ, Berini-Aytes L, Gay-Escoda C. Advantages and esthetic results of erbium, chromium:yttrium-scandium-gallium-garnet laser application in second-stage implant surgery in patients with insufficient gingival attachment: a report of three cases. *Lasers Med Sci* 2010;25(3):459-64.
 31. Parker S. Surgical laser use in implantology and endodontics. *B Dent J* 2007;202:377-86.
 32. Azzeh MM. Er,Cr:YSGG laser-assisted surgical treatment of peri-implantitis with 1-year reentry and 18-month follow-up. *J Periodontol* 2008; 79(10):2000-5.
 33. Takasaki AA, Aoki A, Mizutani K, Kikuchi S, Oda S, Ishikawa I. Er:YAG laser therapy for peri-implant infection: a histological study. *Lasers Med Sci* 2007) 22(3):143-57.
 34. Jakse N, Payer M, Tangl S, Berghold A, Kirmeier R, Lorenzoni M. Influence of low-level laser treatment on bone regeneration and osseointegration of dental implants following sinus augmentation. An experimental study on sheep. *Clin Oral Implants Res* 2007; 18(4):517-24.
 35. Kim YD, Kim SS, Hwang DS, Kim SG, Kwon YH, Shin SH, et al. Effect of low-level laser treatment after installation of dental titanium implant-immunohistochemical study of RANKL, RANK, OPG: an experimental study in rats. *Lasers Surg Med* 2007; 39(5):441-50.

36. Aleksic V, Aoki A, Iwasaki K, Takasaki AA, Wang CY, Abiko Y, et al. Low-level Er:YAG laser irradiation enhances osteoblast proliferation through activation of MAPK/ERK. *Lasers Med Sci* 2010; 25:559-69.
37. Ozan O, Seker E, Kurtulmus Yilmaz S, Ersoy AE. Clinical application of stereolithographic surgical guide with a handpiece guidance apparatus: A case report. *J Oral Implantol* 2011 Jul 18. [Epub ahead of print].
38. Al-Harbi SA, Sun AY. Implant Placement Accuracy When Using Stereolithographic Template as a Surgical Guide: Preliminary Results. *Implant Dent* 2009; 18:46-56.
39. Van Assche N, van Steenberghe D, Guerrero ME, Hirsch E, Schutyser F, Quirynen M, et al. Accuracy of implant placement based on pre-surgical planning of three-dimensional cone-beam images: a pilot study. *J Clin Periodontol* 2007;34(9):816-21.
40. Abboud M, Wahl G, Guirado JL, Orentlicher G. Application and success of two stereolithographic surgical guide systems for implant placement with immediate loading. *Int J Oral Maxillofac Implants* 2012;27(3):634-43.
41. Pettersson A, Kero T, Gillot L, Cannas B, Faldt J, Soderberg R, et al. Accuracy of CAD/CAM-guided surgical template implant surgery on human cadavers: Part I. *J Prosthet Dent* 2010;103(6):334-42.
42. Barnea E, Alt I, Kolerman R, Nissan J. Accuracy of laboratory-based computer implant guiding system. *Oral Surg Oral Med Oral Pathol Oral Radiol Endod* 2010;109:e6-e10.
43. Murat S, Kamburoglu K, Ozen T. Accuracy of a Newly Developed CBCT-Aided Surgical Guidance System for Dental Implant Placement: An Ex Vivo Study. *J Oral Implantol* 2011; Jul 18. [Epub ahead of print]
44. Cassetta M, Stefanelli LV, Giansanti M, Calasso S. Accuracy of implant placement with a stereolithographic surgical template. *Int J Oral Maxillofac Implants* 2012; 27(3):655-63.