

Evaluation of Fractional CO₂ Laser Efficacy in Acne Scar

Simin Saryazdi, Azadeh Mohebbi

Department of Dermatology, Afzalipour Hospital, Kerman, Iran

Abstract:

Introduction: Acne scar is formed after severe episodes of acne in teen and early adult years. Several treatment options have been used for depressed acne scars such as punch grafting, punch excision carbon dioxide (CO₂) laser etc. Moreover, Studies show that laser skin resurfacing such as CO₂ fractional can effectively treat depressed acne scars. We investigated the efficacy of fractional CO₂ laser in acne scar.

Methods: In this clinical trial; we used CO₂ fractional laser (Unit: eCO₂ Lutronic Korea; FDA approved) in 15 female cases with an age range of 20-40 years old. They underwent 3 sessions of laser resurfacing at one month intervals. In the first session we used laser with a density of 150 and fluency of 70 with a 4mm diameter circular spot in static mode on depressed acne scars, and we exerted laser with density of 100 and fluency 70 with 12 mm diameter square spot in static mode on all involved skin in the other sessions. Photographs were taken before every process. The patients and another dermatologist filled the questionnaire concerning the percent of improvement. Finally, we compared photographs and evaluated the efficacy of CO₂ fractional laser in acne scars.

Results: Objective and subjective improvement was estimated about 20-70% and 30-70%, respectively, without any erythema, permanent hyperpigmentation and other adverse effects. The important point is that, participants returned back to work after 4-7 days.

Conclusion: The Fractional CO₂ laser resurfacing can be used as a safe and efficacious method to treat depressed acne scar.

Keywords: Efficacy; carbon dioxide laser; acne scar.

Please cite this article as follows:

Saryazdi S, Mohebbi A. Evaluation of Efficacy of Fractional CO₂ Laser in Acne Scar: J Lasers Med Sci 2012; 3(2):56-60

*Corresponding Author: Azadeh Mohebbi,MD; Department of Dermatology, Afzalipour Hospital, Kerman, Iran. Tel: +98-9133411060; Fax: +98-3412437422; Email address: mohebbiazadeh@yahoo.com

Introduction

Acne scars are one of the disfiguring side effects of acne. There are several types of acne scar; pitted, depressed, nodular and cystic. The depressed acne is the most common cosmetic concern and is improvable by many modalities, with varying degrees of success. Acneiform scars are caused by compromised collagen production during the natural wound healing process, causing topographical depressions (1). Historically, atrophic acne scars

have been very difficult to treat, thus presenting a therapeutic challenge due to the limitations of available technology. Several modalities have been implicated to cure acne scarring, including surgical techniques such as subcision, punch grafts, excisions and other methods such as; autologous fat transfer, injection of dermal fillers, dermabrasion, chemical peels, and laser therapy (non-ablative, ablative). The efficacy of these methods is limited, and there is currently no gold standard (2).

The CO₂ laser has been effectively proven for

the treatment of a wide range of dermatologic conditions, including treatment of acne scars. High-energy, short duration exposure to 10,600 nm CO₂ laser light vaporizes intra- and extracellular water, causing tissue ablation, rapid enough to limit dermal injury and reduce the likelihood of additional scarring. Removing the epidermis and dermis in this way stimulates wound remodeling with new collagen and elastin formation and subsequent improvement in atrophic scars (1). This method has some drawbacks diminished our treatment by erythema, hyperpigmentation, etc. and the major barrier is the cost of treatment. There is a new CO₂ laser system with a fractional modality, It can perform fractional resurfacing at depths ranging from 20 to 500 laserline (lm) and treating 20%, 40%, or 100% of the area (3). Pulsed CO₂ laser devices are considered highly effective treatment options for skin resurfacing. Furthermore, the high risk for significant treatment complications following traditional CO₂ resurfacing has warranted the development of new treatment modalities (3,4). The aim of this clinical trial was evaluated the efficacy of fractional CO₂ laser resurfacing to treat moderate to severe acne scarring.

Methods

A series of fifteen female participants (Fitzpatrick skin types III–IV) ranged 25–45 years old who had moderate to severe acne scars have been included and put under treatment course from July 2009 to July 2011.

Participants with the following criteria were excluded from the study: active infections, history of keloid scar formation, known allergies to lidocaine, recent accutane use, smoking, pregnancy or cosmetic procedures in the treatment area within last 12 months.

The treatment areas were cleansed (debris, including dirt, makeup, and powder), by using a mild cleanser and 70% isopropyl alcohol. Lidocaine, 2.5%, and prilocaine, 2.5%, cream (Lidocaine-p cream) were applied under close dressing on the entire face. After an hour of application, the anesthetic cream was gently removed and then, to obtain a completely dry skin surface, alcohol was used to degrease the skin.

We used CO₂ Fractional laser, Unit: eCO₂ Lutronic Korea; FDA approved, in 3 sessions at one

month interval. In the first session, we used laser with a density of 150 (10.6%) and pulse energy of 70 (1.65 msec), multiple 2 (That is the set up of the unit), spot size 120μ with 4mm diameter circular spot in static mode on depressed acne scars, and after one month we perform this procedure with a density of 100 (7.1%) and fluency 70 with 12mm diameter square spot in static mode on all the involved skin.

Photographic documentation using identical camera settings, lighting, and patient positioning were obtained at baseline, before each treatment session, and 3 months after the final treatment session.

We compared improvement rate of scars after every sessions at 1 month interval then they referred to clinic to achieve the best fractional CO₂ laser parameters after 3 months. Adverse effects and recovery times were recorded in each session and visit.

We had two questionnaire sheets, one of them filled by the participants and the other one by another dermatologist who evaluated the photographs. We requested them to fill these questionnaires about the scale of clinical improvement as fair (< 30%), good (30%-60%) and excellent (60% <). Immediately, after each treatment session, they also were asked to rate the pain associated with treatment on a 10-point pain scale (0 = very light to 10 = very severe). Finally, data were analyzed and the results were confirmed.

Statistical Analysis

Data were presented as Kendall test for comparison of the three sessions. SPSS software version 18 was used. In the comparison of the different sessions for each participants, we estimated a P-value at most <0.05, consequently, we confirmed the significant difference of statistical analysis in this clinical trial.

Results

Fifteen participants, all women, with mean age of 34.58±2.63 (range 25–45) years with depressed acne scar were enrolled in this study. All the participants completed the three treatment sessions with one month interval.

At the end of each session participants

experienced a reduction in the depth and size of scars. At the first laser session they presented 5-25%, at the second 15-50% and at the third session 20-70% (Figure 1).

All participants felt an ascending improvement rate during and after the course of treatment.

The fractional CO₂ laser showed significant reductions in the scars compared to baseline according to the other dermatologist opinion. At the first session, he expressed 10-20%, at the second laser 25-50% and at the third session 30-70% (Figure 2).

We confirmed significant improvement rate in skin texture after treatment. All participants tolerated the treatment sessions. The mean pain

score was 1.8 (a score of 2.5 is easily tolerated).

It is interesting that, the initial edema and erythema improved after 2-3 days, so they could return to work after few days. There were no pigmentation changes, infections and other immediate adverse effects. No long-term side effects were observed after 6 months of follow-ups and the improvement continued after the last use of laser.

Discussion

This study demonstrated the efficacy of fractional CO₂ laser treatments for moderate to severe acne scarring. Final results in participants

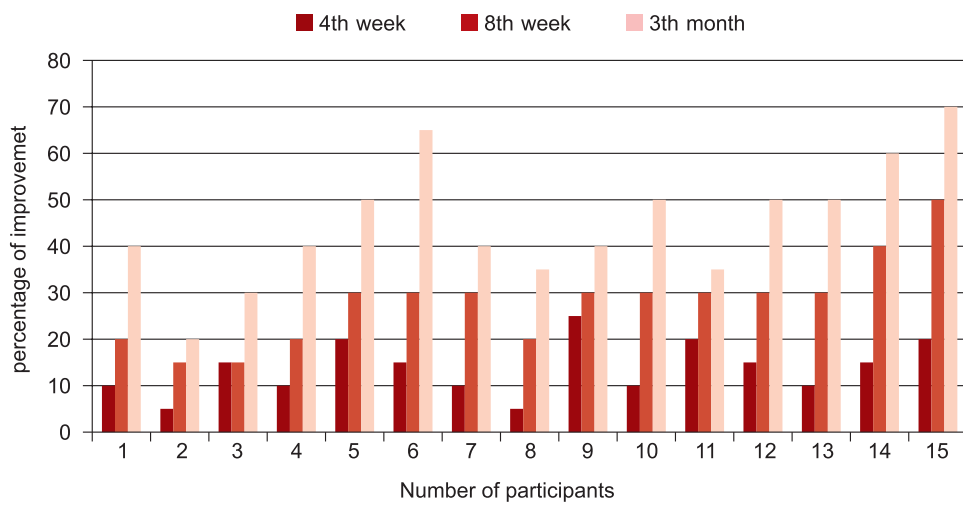


Figure 1. Participant’s scores of improvement of facial depressed lesions for three sessions; at 4th , 8th week and 3th month after completing sessions.

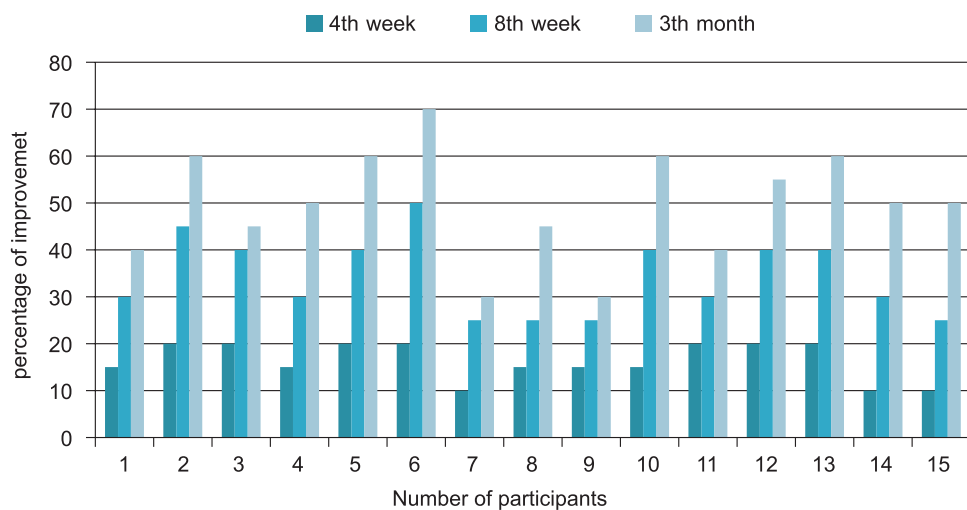


Figure 2. Dermatologist scores of improvement of facial depressed lesions for three sessions; at 4th , 8th week and 3th month after completing sessions.

and dermatologist evaluation was 20%-70% and 30%-70%, respectively (Figure 1,2).

The fractional CO₂ laser is useful in the treatment of scars, wrinkles, nevus, sun damaged skin and etc (5, 6). Theoretically, the mechanisms of action of laser resurfacing include tissue ablation, immediate collagen shrinkage, and dermal collagen remodeling. Columns of microscopic ablated epidermis and dermis after treatment with Fractional CO₂ laser may result in macroscopic epidermal regeneration as evidenced by clinical improvement of scar and skin texture (7).

We did not see any evidence of clinical infection, post-inflammatory hyperpigmentation and erythema. Participants returned back to work after 4-7 days. Considering the recovery time, adverse effects and outcome, Fractional CO₂ laser can be

an alternative treatment technique for acne scar.

In this study, we used laser with a density of 150 and fluency of 70 with 4mm diameter circular spot on depressed acne scars and then with a density of 100 and fluency 70 with 12mm diameter square spot on all involved skin. It seems that this is a reliable setting because it showed less side effects and more efficacy than common setting (Figure 3,4).

Conclusion

Fractional CO₂ laser provides a safe and effective treatment of moderate to severe facial acne scarring but further studies will help define the optimal treatment parameters and other potential indications for this device.

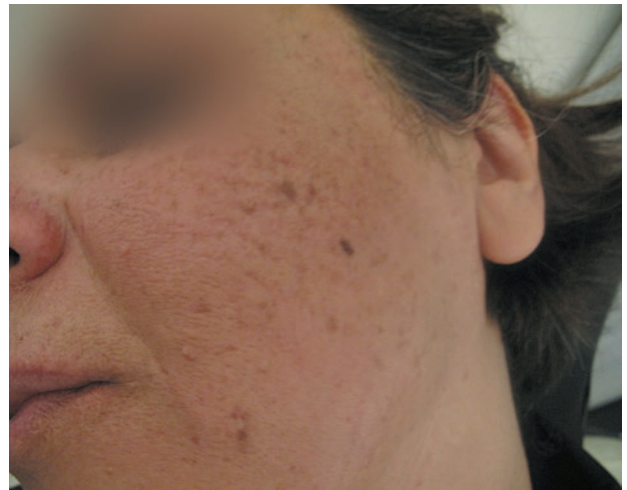
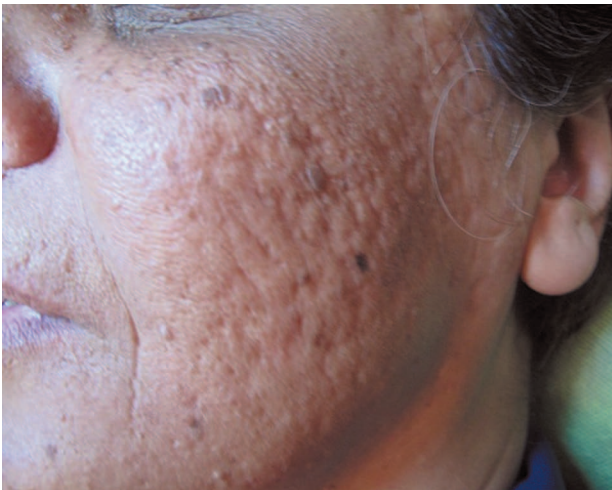
Figure 3. 45-year-old woman with acne scar pre (left) and 6 months after the first session (right).

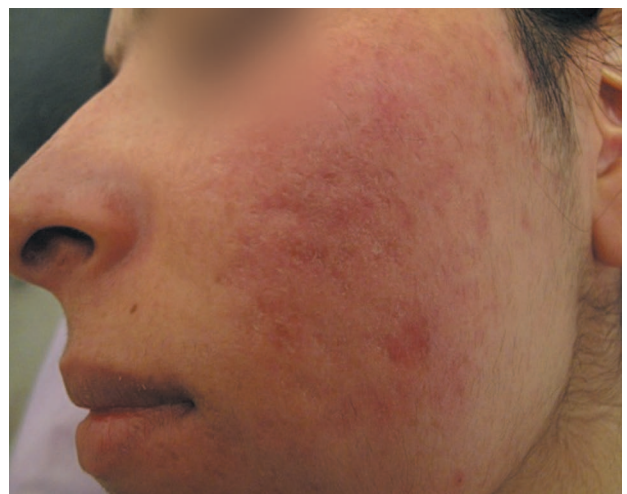
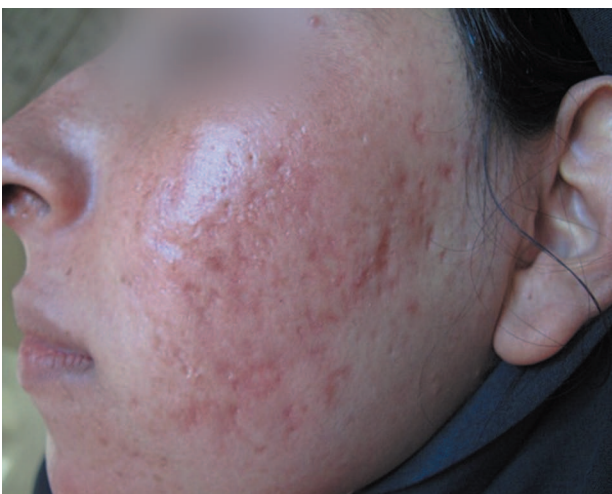
Figure 4. 28-year-old woman with acne scar pre (left) and 6 months after the first session (right).

Some major drawbacks have progressively limited its use: the need for effective anesthesia, the downtime associated with treatment, the risk of hyperpigmentation and scarring, the need for intensive postoperative care, the long-lasting erythema, and the need to avoid sun exposure for extended periods. Pain and cost still serve as barriers.

References

1. Zaenglein AL and Thiboutot DM. Dermatology. In: Bologna JL, Jorizzo JL and Rapini R (Eds). *Acne Vulgaris*. Mosby Publishing; 2008. 213-4.
2. Lawrence CM, Walker NPJ, Telfer NR (Eds). *Rook's Textbook of Dermatology*. In: Burns T, Breathnach S, Cox N, Griffiths C. *Dermatological Surgery*. Blackwell Publishing; 2010;3:13-4.
3. Chapas AM, Brightman L, Sukal S, Hale E, Daniel D, Bernstein LJ. Successful Treatment of Acneiform Scarring With CO₂ Ablative Fractional Resurfacing. *Lasers Surg Med* 2008; 40(6): 381-6.
4. Walgrave SE, Ortiz AE, MacFalls HT, Elkeeb L, Truitt AK, Tournas JA. Evaluation of a Novel Fractional Resurfacing Device for Treatment of Acne Scarring. *Lasers Surg Med* 2009; 41(2):122-7.
5. Gotkin RH, Sarnoff DS, Cannarozzo G, Sadick NS, Alexiades-Armenakas M. Ablative Skin Resurfacing with a Novel Microablative CO₂ Laser. *J Drugs Dermatol* 2009; 8(2): 138-44.
6. Cassuto DA, Sadick NS, Scrimali L, Sirago P. An Innovative Device for Fractional CO₂ Laser Resurfacing: A Preliminary Clinical Study *AJCS* 2008; 25: 97-101.
7. Manuskitti W, Triwongwanat D, Varothai S, Eimpunth S, Wanitphakdeedecha R. Efficacy and safety of a carbon-dioxide ablative fractional resurfacing device for treatment of atrophic acne scars in Asians. *J Am Acad Dermatol* 2010; 63(2): 274-83.