

# Leukoplakia Removal by Carbon Dioxide Laser (CO<sub>2</sub>) Laser

Nasim Chiniforush<sup>1</sup>, Abas Kamali<sup>2</sup>, Sima Shahabi<sup>3</sup>, Seid Hossein Bassir<sup>4</sup>

<sup>1</sup>Laser Research Center of Dentistry, School of Dentistry of Tehran University of Medical Sciences, Tehran, Iran

<sup>2</sup>Periodontist, Tehran, Iran

<sup>3</sup>Laser Research Center of Dentistry, Dental Materials Department, School of Dentistry of Tehran University of Medical Sciences. Tehran, Iran

<sup>4</sup>Dentist, Tehran, Iran

## Abstract:

**Introduction:** Definitive treatment of oral leukoplakia is very important because of its recurrences and malignant transformation depending on the location, clinical feature, degree of dysplasia and etiological factors. There are different kinds of treatment for this lesion, but using high power laser has some advantages like less pain, swelling, prevention of metastasis, edema, less bleeding (dry surgery) and infection.

**Case:** A 53-year-old man with leukoplakia lesion with moderate dysplasia on the left side of the ventral surface of the tongue was selected for treatment with CO<sub>2</sub> laser. The average power is set on 6.2 W with frequency of 20 Hz. The irradiation mode was non-contact. The entire lesion evaporated by the laser with a 2 mm safety margin.

**Result:** In this case, 80% of lesion had disappeared after 5 weeks and the 20% residual was evaporated again with the same parameters than the first time. No significant clinical differences were seen between the normal and laser-treated tissue.

**Conclusion:** Using laser in the treatment of oral lesions has many advantages like selective removal of the affected tissues and minimal damage to surrounding tissue, leading to excellent wound healing with no or minimal scar and good functional results.

**Keywords:** oral leukoplakia; CO<sub>2</sub> laser; dysplasia

---

Please cite this article as follows:

Chiniforush N, Kamali A, Shahabi S, Bassir SH. Leukoplakia removal by CO<sub>2</sub> laser: J Lasers Med Sci 2012; 3(1):33-5

\*Corresponding Author: Nasim Chiniforush, DDS; Laser Research Center of Dentistry, School of Dentistry of Tehran University of Medical Sciences, Tehran, Iran. Tel: +98-2188015017; Fax: +98-2188687471; Email: n-chiniforush@farabi.tums.ac.ir

## Introduction

Oral leukoplakia is considered as a common precancerous lesion of the oral mucosa. It is defined as a white patch or plaque that cannot be characterized clinically or pathologically as any other disease (1). Definitive treatment of oral leukoplakia is very important because of its recurrences and malignant transformation depending on the location, clinical feature, degree of dysplasia and etiological factors (2). There are different

kinds of treatment for this lesion including scalpel excision, electrocautery, cryosurgery, laser surgery and medications. Conventional surgery may be followed by some side effects like scar formation, contraction and stimulating signs of recurrence (3). Carbon dioxide laser have been used in a variety of soft tissue surgical procedures, including excision of malignant and leukoplakic lesions in the oral cavity. Using high power laser has some advantages like less pain, swelling, prevention of metastasis, edema, less bleeding (dry surgery) and infection (4).

**Case**

A 53\_year\_old man with a white lesion on the left side of the ventral surface of the tongue was referred to the laser department of Tehran University of Medical Sciences (Figure 1).

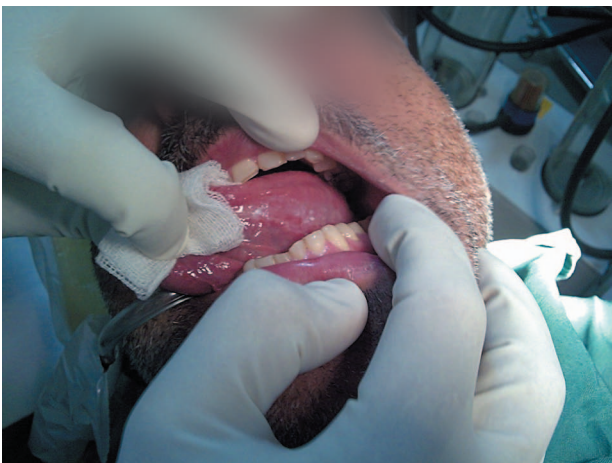The clinical examination showed that the patient had no systemic disease and a history of smoking. The lesion was about 5×3 cm and had a keratotic border. The patient had a burning sense in the region of the lesion. Then, a biopsy was done for histopathological examination, with a diagnosis of leukoplakia lesion with moderate dysplasia. After applying local anesthetics, the CO<sub>2</sub> laser at a wavelength of 10600 nm was selected for excision with an average power of 6.2 W and a frequency of 20 Hz (recommended by manufacturer). The irradiation mode was noncontact and the spot size was about 0.7 cm<sup>2</sup>. The entire lesion was evaporated

by the laser in pulse mode (pulse duration= 10 ms) by a sweeping motion about 1-2 mm above the surface accompanied by high vacuum suction. A 2 mm safety margin was considered (Figure 2,3). The total ablation site was 5.2×3.2 cm. Gelofen 400 mg and 0.2% chlorhexidine mouthwash were prescribed post operatively. Also, the patient was informed to maintain good oral hygiene.

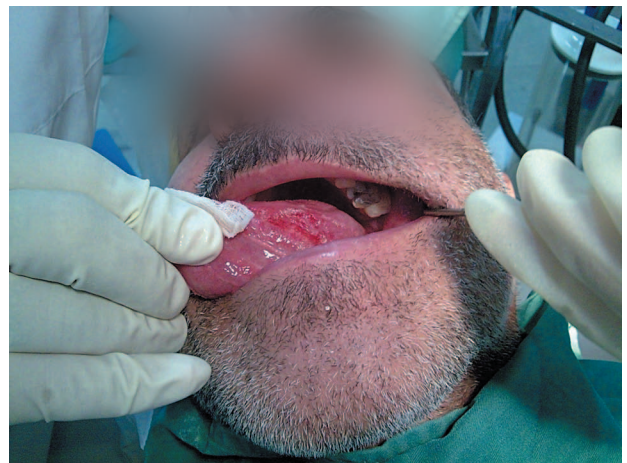**Results**

In this case, 80% of lesion have disappeared after 5 weeks and 20% residual was evaporated again with the same parameters than the first treatment. After 3 months for the second follow up, the lesion had completely disappeared. No significant clinically differences were seen between the normal and laser-treated tissue (Figure 4).

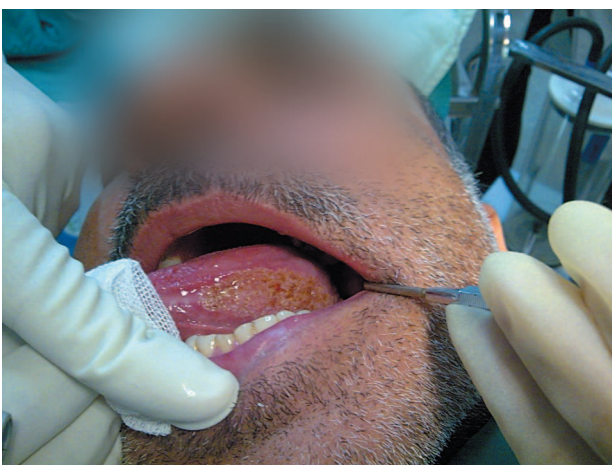Also, the patient did not suffer from any



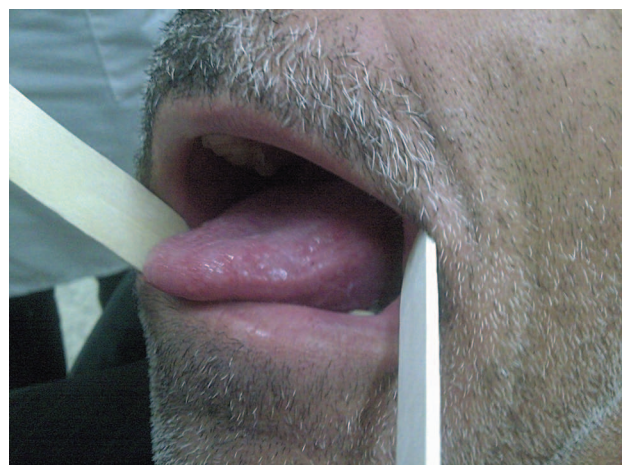
**Figure 1.** Leukoplakia on the ventral surface of the tongue



**Figure 3.** Immediately after procedure



**Figure 2.** The view of ablating surface



**Figure 4.** The follow up session after 3 months

postoperative complications like swelling or sever pain.

## Discussion

In this case, we evaluated the effects of CO<sub>2</sub> laser for the treatment of oral leukoplakia. Many investigators have undertaken the assessment of laser surgery for oral leukoplakia. Yang et al concluded that the absence of complications such as bleeding, paresthesia or anaesthesia and also very low recurrence rates and excellent healing makes the CO<sub>2</sub> laser soft tissue surgery treatment superior to the other methods of treatment for leukoplakia (5).

Syed et al. in assessing the CO<sub>2</sub> laser for excision of leukoplakia in comparison with traditional method concluded that the application of CO<sub>2</sub> laser for surgical removal of lesions are more simple than traditional method for operator and provided great satisfaction for patients by reducing postoperative pain (6).

Laser application for oral surgery shows some advantages such as hemostatic effect which is suitable for the surgical treatment of oral mucosa which is rich in blood vessels. In addition, it produces satisfactory mobility of oral mucosa after surgery and shows a suitable postoperative oral function because of the limited scarring and minimal contraction in contrast to conventional method of surgery. Besides, it can be repeatedly performed which is favorable for recurrent lesions. And finally, thermal damage to adjacent tissue is minimal, which produces a good quality of life for patients by reducing postoperative pain, swelling, edema and infection (7-10).

It was reported that the recurrence rate in laser surgery differs from 7.7% to 38.1% depending on differences in the variety and conditions of the laser beams, the follow-up period and race. Therefore, the regular follow up is obligatory after treatment (11-12).

## Conclusion

Due to the limitations of the different treatment

modalities for leukoplakia removal, laser surgery has gained special attention according to its ability for selective removal of the affected tissues and minimal damage to surrounding tissue leading to excellent wound healing with no or minimal scar and good functional results.

## References

1. Lodi G, Sardella A, Bez C, Demarosi F, Carrassi A. Systematic review of randomized trials for the treatment of oral leukoplakia. *J Dent Educ* 2002; 66:896-902.
2. Lodi G, Porter S. Management of potentially malignant disorders: evidence and critique. *J Oral Pathol Med* 2008; 37:63-9.
3. Chandu A, Smith AC. The use of co<sub>2</sub> laser in the treatment of oral white patches: outcomes and factors affecting recurrence. *Int J Oral Maxillofac Surg* 2005; 34: 396-400.
4. Ishii J, Fujita K, Komori T. Laser surgery as a treatment for oral leukoplakia. *Oral Oncol* 2003; 39(8):759-769.
5. Yang SW, Tsai CN, Lee YS, Chen TA. Treatment outcome of dysplastic oral leukoplakia with carbon dioxide laser-emphasis on the factors affecting recurrence. *J Oral Maxillofac Surg* 2011; 69(6): 78-87.
6. Syed TF, Thukral N. CO<sub>2</sub> Laser Surgery for the Excision of Leukoplakia: A Comparison with the Traditional Technique. *J Oral Laser Applications* 2009; 9(4):213-218.
7. Yalcinkaya S.E, Dumlu A, Olgac V, Ozbayrak S. CO<sub>2</sub> laser management of leukoplakias: A clinical follow up. *J Oral Laser Appl* 2005; 5:91-102.
8. Van der Hem PS, Nauta JM, Van der Wal JE, Roodenburg JLN. The results of co<sub>2</sub> laser surgery in patients with oral leukoplakia: a25 year follow up. *Oral Oncol* 2005; 41(1):31-7.
9. Tuncer I, Ozçakir-Tomruk C, Sencift K, Cöloğlu S. Comparison of conventional surgery and CO<sub>2</sub> laser on intraoral soft tissue pathologies and evaluation of the collateral thermal damage. *Photomed Laser Surg* 2010; 28(1):75-9.
10. Hamadah O, Thomson PJ. Factors affecting carbon dioxide laser treatment for oral precancer: a patient cohort study. *Lasers Surg Med* 2009; 41(1):17-25.
11. Deppe H, Hillemanns M, Hauck W. Recurrence rates of premalignant lesions after CO<sub>2</sub> laser resection. *Med Laser Appl* 2004; 19(1):55-60.
12. Wang CP, Chang SY, Wu JD, Tai SK. Carbon dioxide laser microsurgery for tongue cancer: surgical techniques and long-term results. *J Otolaryngol* 2001; 30(1):19-23.