

Retrograde Holmium- YAG Laser Endopyelotomy

Mohammad Reza Razzaghi¹, Abdollah Razi², Hooman Mokhtarpour²
Mohammad Mohsen Mazloomfard², Behzad Lotfi²

¹Laser Application in Medical Sciences Research Center, Shahid Beheshti University of Medical Sciences, Tehran, Iran

²Shohada Tajrish Medical Center, Shahid Beheshti University of Medical Sciences, Tehran, Iran

Abstract:

Endourologic pyeloplasty is being a substitute of open pyeloplasty in management of ureteropelvic junction obstruction. This procedure can be done in different manners like balloon dilation, cold knife and electro-surgical endoureterotomy, accucise and lasers.

A 47 year old woman referred with history of previous open pyeloplasty.

Hydronephrosis of right kidney with unremarkable T ½ was found in DTPA scan.

A full-thickness lateral incision was done with holmium:YAG laser just below the right UPJ and carried through the stenotic segment until the renal pelvis was reached.

Half-time of radioisotope excretion was 13 min for the right kidney in diuretic renogram 3 months following operation.

Keywords: Ho-YAG laser; Lasers, Solid-State; Endoscopic Pyelotomy; Ureteral Obstruction; Lasers; Laser Therapy

Please cite this article as follows:

Razaghi MR, Razi A, Mokhtarpour H, Mazloomfard MM, Lotfi B. Retrograde Holmium- YAG Laser Endopyelotomy. *J Laser Med Sci.* 2011; 2(1):46-8

*Corresponding Author: Dr. Abdollah Razi; Resident of Urology, Laser Application in Medical Sciences Research Center, Shahid Beheshti University of Medical Sciences, Tehran, Iran. Tel:+98- 21- 22 74 92 21; Email: rezarazaghi@yahoo.com

Introduction

Open pyeloplasty has been considered the gold standard for treating ureteropelvic junction (UPJ) obstructions(1), but now endourological managements are becoming widely used. Modern endourological devices and techniques have promoted endourology as a reliable treatment modality for UPJ obstruction(2-5).

Two types of endopyelotomy approaches were performed, percutaneous (antegrade) or retrograde route stent is used following incision of the narrow segment(2).

Several endourologic techniques have been utilized for treating UPJO including balloon dilation, cold knife and electro-surgical endoureterotomy, accucise™ (Applied medical technologies, loguna, Hills, Calif) and lasers(3-7). Holmium: YAG laser with its incisional properties on tissue is one of the laser type applied for endopyelotomy(7).

Case Report

A 47 year old woman was referred to urology clinic with vague right flank pain without any lower urinary tract symptoms, fever or gross hematuria. She had a history of right side pyeloplasty due to ureteropelvic junction obstruction (UPJO), 5 years ago.

In addition, she had several times history of extra corporal shock wave lithotripsy (ESWL) for renal pelvic stone. Clinically she appeared normal except mild tenderness on right flank and flank scar due to previous pyeloplasty. Renal function tests were normal and there was no evidence to confirm urinary infection, pyuria, or microscopic hematuria in urine analysis and culture. Severe hydronephrosis of the right side pyelocalyceal system without ureteronephrosis in ultrasonography was suggesting for UPJ obstruction.

Intravenous urography visualized a delay in filling of the right side collecting system with the contrast

material and dilation of the collecting system and a duplicated left side pyelocaliceal system. DTPA scanning with diuretic renogramogram revealed hydronephrotic right kidney with cortical loss and decreased perfusion and function probably due to UPJ obstruction. $T_{1/2}$ was unremarkable for the right kidney. Left kidney was mild hydronephrotic with collecting system duplication of collecting system without any abnormal perfusion or function.

Laser Pyelotomy

Intravenous antibiotic was administered preoperatively. After spinal anesthesia, patient was positioned in lithotomy and 10 Fr rigid ureteroscopy was performed for her. Retrograde endopyelotomy was done using the ablative 50-watt Holmium: YAG laser (2140 nm) made by the Atomic Energy Organization of Iran (AEOI). A full-thickness lateral incision was started just below the UPJ and carried through the stenotic segment until the renal pelvis was reached. Operation lasted for 35 minutes with energy delivery of 102 J. After operation a Double-J stent was inserted and patient discharged the day after pyelotomy upon antibiotic and analgesic medication for 3 days. Double-J stent removed three months after first session of laser pyelotomy. There were no postoperative complication including bleeding, pain, leakage, infection, and collections during patient's follow up.

In second DTPA scan performed one month later, hydronephrosis and function of right kidney did not improve (Fig 1A), so second session of Holmium: YAG laser endopyelotomy was applied for her.

Follow Up

The flank pain was relieved after operation. She was evaluated 3 months after the last intervention by diuretic renal scan. Half-time of radioisotope excretion was 13min for the right kidney (Fig 1B).

Discussion

For many years open surgical repair was the gold standard for ureteropelvic junction stenosis(1). The associated morbidity, hospitalization, long recovery and costs of open surgery led to development of minimally invasive approach(8). Inglis and Tolley's

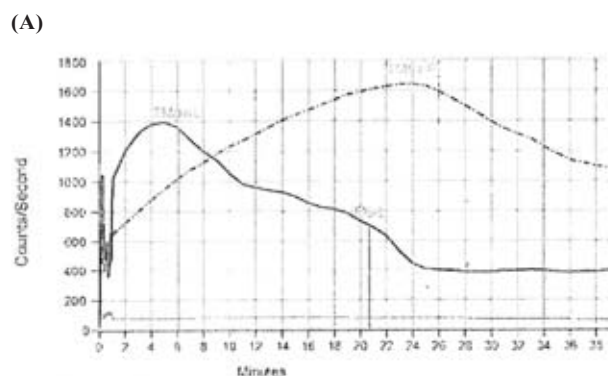
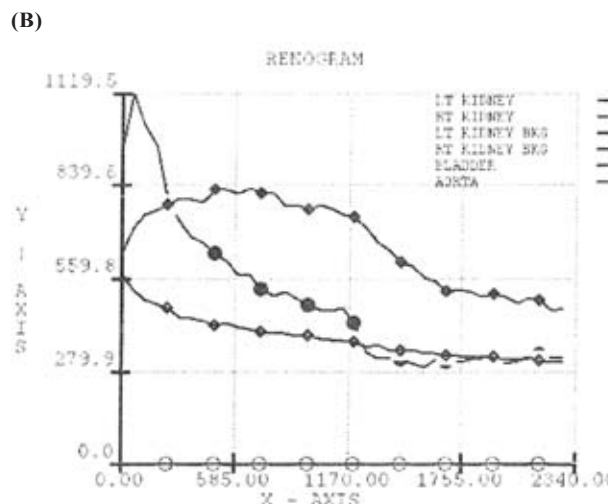


Table of Result Summary

Parameters	Left	Right	Total
Split function (%)	62.6	37.4	
Kidney Counts (cpm)	72958	43678	116636
20 Min Clearance	0.514		
Time of Max (min)	6.001	24.0	
Time of 1/2 Max (min)	20.6		



	Left	Right
Time to Peak (Min)	2.00	12.00
Time to 1/2 Peak	11.00	0.00
Diff Perfusion	60%	40%

Worksheet		
Net Counts	65717.16	43192.48
Raw Counts	84628.75	59479.25
Kidney Pixels	719.00	644.00
Bkg Counts	1999.00	1264.50
Bkg Pixels	76.00	50.00

Figure 1. Radioisotope renogram after first laser endopyelotomy (A) and after second endopyelotomy (B)

described ureteroscopic endopyelotomy using an electrocautery hook was first reported in 1986(2).

Laser energy has been used as an alternative to electrocautery to incise the UPJ during recent years. Laser energy vaporizes the tissue resulting in

an incision. Conlin et al(9) reported 81% success using the Holmium: YAG laser for endopyelotomy and Tawfik et al(10) had 87.5% success using laser for endopyelotomy. Biyani and colleagues revealed 75% success rate for Holmium: YAG laser endopyelotomy(11). Matin(12) et al reported 73.1% success rate using the laser for endopyelotomy.

In a study by El-Nahas and colleagues Laser success rate for endopyelotomy was 85%(7). Altogether, laser success rate for endopyelotomy in several studies reported from 75 to 87(5-12).

Long- standing hydronephrosis may persist despite the relief of functional obstruction. So, diuretic renography can be helpful in functional assessment of outcome.

Using laser endopyelotomy is a safe and feasible technique in patients with recurrent ureteral stricture. Homemade Holmium: YAG laser is a new instrument prepared by AEOI that we offered its application by Iranian urologists.

References

1. Strem SB. Ureteropelvic junction obstruction. Open operative intervention. *Urol Clin North Am.* 1998 May;25(2):331-41.
2. Inglis JA, Tolley DA. Ureteroscopic pyelolysis for pelviureteric junction obstruction. *Br J Urol.* 1986 Jun;58(3):250-2.
3. Richter F, Irwin RJ, Watson RA, Lang EK. Endourologic management of benign ureteral strictures with and without compromised vascular supply. *Urology.* 2000 May;55(5):652-7.
4. Preminger GM, Clayman RV, Nakada SY, Babayan RK, Albala DM, Fuchs GJ, Smith AD. A multicenter clinical trial investigating the use of a fluoroscopically controlled cutting balloon catheter for the management of ureteral and ureteropelvic junction obstruction. *J Urol* 1997 May;157(5):1625-9.
5. Cohen TD, Gross MB, Preminger GM. Long-term follow-up of Acucise incision of ureteropelvic junction obstruction and ureteral strictures. *Urology.* 1996 Mar;47(3):317-23.
6. Giddens JL, Grasso M. Retrograde ureteroscopic endopyelotomy using the holmium-YAG laser. *J Urol.* 2000 Nov;164(5):1509-12.
7. el-Nahas AR, Shoma AM, Eraky I, el-Kenawy MR, el-Kappany HA. Prospective, randomized comparison of ureteroscopic endopyelotomy using holmium:YAG Laser and Balloon catheter. *J Urol.* 2006 Feb;175(2):614-8.
8. Karlin GS, Badlani GH, Smith AD. Endopyelotomy versus open pyeloplasty: comparison in 88 patients. *J Urol.* 1988 Sep;140(3):476-8.
9. Conlin MJ, Bagley DH. Ureteroscopic endopyelotomy at a single setting. *J Urol.* 1998 Mar;159(3):727-31.
10. Tawfik ER, Liu JB, Bagley DH. Ureteroscopic treatment of ureteropelvic junction obstruction. *J Urol.* 1998 Nov;160(5):1643-6; discussion 1646-7.
11. Biyani CS, Cornford PA, Powell CS. Retrograde endoureteropyelotomy with the holmium:YAG laser. Initial experience. *Eur Urol.* 1997;32(4):471-4.
12. Matin SF, Yost A, Strem SB. Ureteroscopic laser endopyelotomy: a single-center experience. *J Endourol.* 2003 Aug;17(6):401-4.