



# The Immediate Pain-Relieving Effects of Non-Thermal CO<sub>2</sub> Laser Therapy on Genital Ulcers of Behcet's Disease: A Case Report

Nasrin Zand<sup>1\*</sup>, Parvin Mansouri<sup>2\*</sup>, Samad Rezaee Khiabanloo<sup>3</sup>, Mohsen Fateh<sup>4</sup>, Leila Ataie-Fashtami<sup>5</sup>, Zahra Safaee Naraghi<sup>6</sup>, Afshan Shirkavand<sup>1,7</sup>

<sup>1</sup>Medical Laser Research Center, Academic Center for Education, Culture and Research, Tehran, Iran

<sup>2</sup>Skin and Stem Cell Research Center, Tehran University of Medical Sciences, Tehran, Iran

<sup>3</sup>Dermatologist, Tehran University of Medical Sciences, Tehran, Iran

<sup>4</sup>Department of Medical Laser, Medical Laser Research Center, Yara Institute, Academic Center for Education, Culture and Research, Tehran, Iran

<sup>5</sup>Department of Regenerative Medicine, Royan Institute for Stem Cell Biology & Technology, Academic Center for Education, Culture and Research, Tehran, Iran

<sup>6</sup>Departments of Dermatology and Pathology, Tehran University of Medical Sciences, Razi Hospital, Tehran, Iran

<sup>7</sup>Laser and Plasma Research Institute, Shahid Beheshti University, Tehran, Iran

## \*Correspondence to

Parvin Mansouri, Tel: +982122215558,

Fax: +982122239264, Email:

[mansorip@sina.tums.ac.ir](mailto:mansorip@sina.tums.ac.ir);

Nasrin Zand, Tel: +982122339949-53,

+989129359096,

Email: [zand\\_nas@yahoo.com](mailto:zand_nas@yahoo.com)

Published online January 18, 2020



## Abstract

Behçet's disease (BD) is a chronic, relapsing, systemic vasculitis of unknown etiology. Oral and genital aphthous ulcers are considered as the hallmarks of BD. The genital ulcers of BD may be extremely painful and often refractory to multiple treatments. In addition, they exert a negative impact on the patient's quality of life. Some investigations have demonstrated the significant and immediate pain-relieving effects of NTCLT (non-thermal CO<sub>2</sub> laser therapy) on some oral lesions with no visible adverse effects. In this paper, we report a case of BD whose painful genital ulcers were irradiated with NTCLT and the patient's pain caused by the ulcers relieved immediately and significantly with no visible complications.

**Keywords:** Behçet's disease; Genital ulcers; CO<sub>2</sub> laser; Non-thermal CO<sub>2</sub> laser therapy (NTCLT); Pain-relieving effects; Photobiomodulation.

## Introduction

Behçet's disease (BD) is a chronic, systemic vasculitis which can affect almost all vascularized systems. BD has a chronic, relapsing course, progressing by attacks and remissions.<sup>1-6</sup> It is most common in the countries along the "ancient Silk Road" with the highest prevalence in Japan, China, Korea, Iran and Turkey.<sup>7</sup> Mucocutaneous lesions are considered as the hallmarks of BD. Genital ulcers which develop in 57%-93% of the patients<sup>6</sup> are punched-out ulcers with a white yellowish necrotic base, surrounded with an erythematous halo. These lesions morphologically resemble oral aphthous ulcers; however, they are usually larger, deeper, more painful, heal more slowly and recur less frequently with a much more scarring tendency.<sup>4,8</sup> These ulcers may be giant, destructive and refractory to multiple treatments. The severe and giant ulcers may even lead to vulva destruction.<sup>9</sup> These ulcers may be extremely painful with a negative impact on the patient's quality of life.<sup>9,10</sup> It is quite rational to develop new therapeutic approaches for pain control of the genital

lesions of BD during conventional systemic therapy.

Photobiomodulation (low-level laser or light therapy, LLLT, or laser phototherapy) is an efficient, non-invasive therapeutic option used to reduce pain, stimulate wound healing, and reduce inflammation.

The CO<sub>2</sub> laser as a valuable high-power thermal laser has been widely used in surgery for decades. Some studies have established that CO<sub>2</sub> laser can also be applied as a low-level (photobiomodulative) laser to achieve immediate and significant pain relief in some oral lesions without any visible thermal complications even erythema.<sup>11-18</sup> This process has been pain-free with no need for anesthesia. No kind of thermal complications have been observed after laser treatment. In this procedure, the rapid scan of the lesion with the defocused laser handpiece and the irradiation of the lesions through a thick layer of gel containing high water lead to a significant reduction in the final beam power at the surface of the lesion to the range of low-level phototherapeutic lasers.<sup>13</sup> This procedure, which was initially called non-ablative CO<sub>2</sub> laser therapy

(NACLTL), was termed non-thermal CO<sub>2</sub> laser therapy (NTCLTL) afterwards to avoid its confusion with fractional non-ablative CO<sub>2</sub> lasers used for skin rejuvenation. In this paper, we report a case of BD whose painful giant genital aphthous ulcers responded to the analgesic effects of NTCLTL immediately and dramatically.

### Case Report

A 23-year-old female patient with giant, extremely painful genital aphthous ulcers of one month's duration was referred from hospital to our clinic for pain reduction in her genital lesions by NTCLTL. There were giant, extremely painful aphthous ulcers in her vulva (Figure 1). The ulcers were so painful, which disturbed her physical activities such as sitting, walking, sleeping, and especially urinating with a great influence on her quality of life. The severe pain of the lesions didn't respond to the conventional analgesic agents. The non-contact visual analogue scale (VAS) pain scores of the right-sided and left-sided genital ulcers were 6 and 8 respectively. The contact pain in the ulcers of both sides was 10. Histologically, a biopsy specimen taken from the genital lesion revealed diffuse dense infiltration with neutrophilic predominance and multiple focal abscesses composed of lymphocytes, eosinophils, and nuclear dusts. There were vascular proliferation, endothelial swelling, and thickening of blood vessel walls (Figure 2).

She fulfilled the International Criteria for Behcet's Disease (ICBD) with a 5-year history of recurrent

oral aphthous ulcers with high frequency, a positive pathergy test, and genital aphthous ulcers. The patient was hospitalized and referred to our service for pain relief of her genital ulcers by NTCLTL. Before signing the informed consent, she was briefed on the process and its investigational nature. She was advised that NTCLTL might have an impact only on pain reduction in her genital lesions with no beneficial effect on the natural history of her disease. She was also well informed about the necessity of continuing her systemic treatment.

To perform the NTCLTL procedure, at first, the lesion and its surrounding tissue were covered with a thick (3-4 mm) layer of high water content (87.5%), transparent, non-anesthetic gel. The patient and the surgical staff used protective eyeglasses during NTCLTL. The CO<sub>2</sub> laser beam ( $\lambda = 10\,600\text{ nm}$ ; Lancet-2, Russia) was illuminated (power: 1 W, continuous mode with a de-focused handpiece, 5-6 mm distant from the mucosal surface, and a rapid scan over the lesion with a circular motion) through the gel. In any part of the lesion, the laser beam was irradiated to a circle area of the ulcer (with a diameter of approximately 1 cm) for 5 seconds in each pass and repeated immediately if the contact pain of the lesion persisted. In any part of the lesions, between the passes, the prior gel was wiped gently and a new layer of gel was placed on the lesion to prevent a reduction in the water content of the gel and a tissue burn.

Immediately after NTCLTL, the pain of the lesions relieved, so that she could even walk up and downstairs with no problems. No kind of thermal adverse effects such as destruction, ablation or aggravation of the lesions was observed following NTCLTL. The procedure was painless and anesthesia was not required. This analgesic effect continued during the healing period of the ulcers. She reported no problem in daily functions and required no analgesics. She just reported mild burning with urination for the first 3-4 days. Treatment with prednisolone 30 mg and colchicine 2 mg was started after result of biopsy (one day after NTCLTL). It was interesting to observe that the depth of the genital ulcers slightly decreased just 2 days after NTCLTL. The healing period of the ulcers was about 9-11 days, which seemed to be shorter than what was expected. She was discharged from the hospital with prednisolone 25 mg and colchicine 2 mg daily. She was visited every 2 weeks for 2 months. She had no problem or sensory loss in the laser-treated areas. The ulcers healed with a very fine scar in spite of the giant size of the ulcers (Figure 3B).

Six months later, she was referred to our service again for pain reduction in her new genital aphthous ulcer by NTCLTL. She had discontinued her medications one month before arbitrarily because of poor compliance (Figure 3). The use of prednisolone 30 mg and colchicine 2mg daily was initiated again for her in the hospital. The non-contact and contact VAS pain scores of the ulcer were 6 and 8 respectively. The pain of the lesions eased immediately.

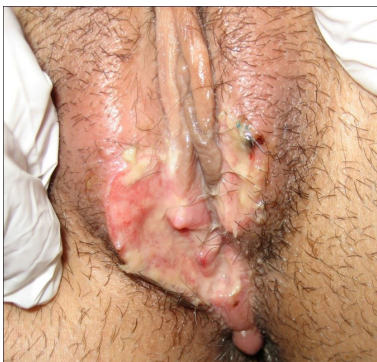

Figure 1. The Patient's Genital Aphthous Ulcer Before NTCLTL.

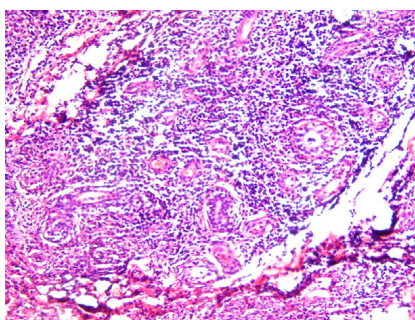
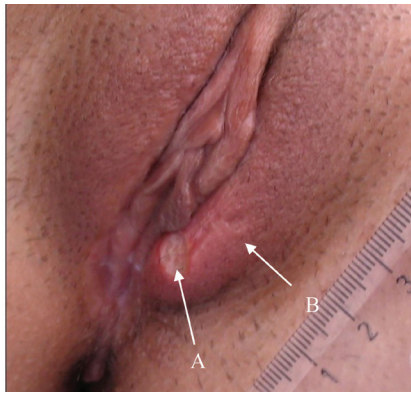


Figure 2. Histological Feature of the Patient's Genital Aphthous Ulcer.



**Figure 3.** (A) The new genital aphthous ulcer, (B) Notice to the fine scar of the prior giant genital ulcer which had already been irradiated with NTCLT.

Similar to the first NTCLT session, anesthesia was not required and there was no complication following NTCLT. The ulcer healed completely within five days. It was interesting to notice that prior giant genital ulcers which had been already irradiated with NTCLT had left excellent cosmetic results with very fine scars (Figure 3). The patient was discharged from the hospital with prednisolone 20 mg and colchicine 2 mg daily. She was visited every two weeks for up to three months. She had no visible side effects or sensory deficits in the NTCLT-treated areas.

She returned to our laser department because of a minor relapse of the genital ulcer in spite of continuing systemic treatment after one year. No scar was observed at the site of her last year's genital ulcer. The non-contact and contact VAS pain scores of her new genital ulcer were 3 and 6 respectively. NTCLT was performed and the pain of her lesions eased immediately with no complications.

### Discussion

The results of this case report propose that NTCLT (as a photobiomodulative laser) could be potentially considered as an alternative option for immediate and significant pain relief in genital aphthous ulcers of BD with no complications.

Photobiomodulation has been used as a safe and valuable option for pain relief, improving the wound healing process and anti-inflammatory effects. In addition to the conventional photobiomodulative lasers (such as semiconductor lasers), surgical lasers can also be applied for photobiomodulation. As Tuner stated, "when high power lasers are used for biomodulation, one only needs to make the beam wide enough not to burn. An alternative is to scan rapidly over the lesion with a narrow beam. Therefore, the power density or average power is kept low enough to avoid burning, and their incident energy and power density are set within the low intensity laser therapy range". The exciting experiment of Endre Mester with a low-powered ruby laser illumination on the shaved skin of the mice and faster regrowth of the hairs can be

regarded as the primary evidence of photobiomodulation by a surgical laser.<sup>19,20</sup>

Some articles highlighting the pain-relieving effects of non-thermal CO<sub>2</sub> laser irradiation in some oral lesions have been published.<sup>11-18</sup> In order to apply the high power, a surgical CO<sub>2</sub> laser as a low-power, photobiomodulative instrument for NTCLT, rapid scanning of the lesion with the defocused laser handpiece, and the illumination of the lesions through a thick layer of gel containing high water reduces the final beam power at the surface of the lesion by a factor of 200-500.<sup>13</sup> By these amounts of attention, the CO<sub>2</sub> laser has been used as a photobiomodulative laser to achieve immediate and significant pain relief ( $P < 0.001$ ) in some oral lesions with no adverse effects.<sup>11-18</sup> Following careful application of NTCLT, the patients have reported no warmth in their lesions during NTCLT and there have been no reports of thermal adverse effects on the oral mucosa or the aggravation of the existing lesions.<sup>11-18</sup> This laser technique was initially termed NACL, but after proving its non-thermal nature, it was called NTCLT to avoid its confusion with high-power fractional non-ablative CO<sub>2</sub> lasers used for skin rejuvenation. In fact, NTCLT as a valuable photobiomodulative protocol is quite different from traditional surgical CO<sub>2</sub> laser application and should not be mistaken for fractional non-ablative CO<sub>2</sub> lasers which are thermal, high power lasers too.

In order to help the protection of the physician's eyes against the reflected beam from the surface of the gel, we highly recommend the physicians to wear eyeglasses not only matched to the 10600 nm wavelength, but also matched to the wavelength of the guiding beam of the laser.

The results of this report propose that NTCLT could be potentially considered as a promising laser technique for immediate and remarkable pain relief of genital aphthous ulcers of caused by BD with no visible thermal side effects. Regardless of the giant size of the genital ulcers of the patient on the first visit, they healed sooner than was supposed and left excellent cosmetic results with a very fine scar (Figure 3). The anti-inflammatory and accelerating effects of conventional photobiomodulation therapies on wound healing have been demonstrated.<sup>21-25</sup> Although in a pilot RCT, Zand et al suggested the accelerating effects of NTCLT on wound healing of minor aphthous ulcers, the pain-relieving effect of NTCLT ( $P < 0.001$ ) was much more significant than its promoting healing effects on miRAS ( $P = 0.02$ ).<sup>17</sup>

Since BD is a serious multisystem disease with long-term mortality and morbidity, the patients should be warned that in spite of the immediate and significant analgesic effects of NTCLT, they should continue their conventional systemic treatment of their disease. The absence of previous reports describing such an analgesic effect on genital aphthous ulcers of BD makes this report of special interest to dermatologists, rheumatologists, and gynecologists. Well-designed controlled studies with

appropriate sample sizes are clearly required to confirm the analgesic effect of NTCLT on genital aphthous ulcers of BD. These kinds of trials will also be able to find out whether NTCLT can optimize the wound healing process and prevent scar formation in these lesions or not. In addition, such studies will determine whether or not additional NTCLT sessions are necessary for pain relief and accelerating wound healing in genital aphthous ulcers of BD (especially the giant lesions).

Furthermore, we recommend that, in further clinical studies, the analgesic effects of NTCLT and conventional photobiomodulative lasers (such as diode

### Ethical Considerations

An informed consent was obtained from the patient for publication of this report.

### Conflict of Interests

The authors declare no conflict of interest.

### References

- Davatchi F, Chams-Davatchi C, Shams H, Shahram F, Nadji A, Akhlaghi M, et al. Behçet's disease: epidemiology, clinical manifestations, and diagnosis. *Expert Rev Clin Immunol*. 2017;13(1):57-65. doi: 10.1080/1744666X.2016.1205486.
- Alpsoy E. Behçet's disease: A comprehensive review with a focus on epidemiology, etiology and clinical features, and management of mucocutaneous lesions. *J Dermatol*. 2016;43(6):620-32. doi: 10.1111/1346-8138.13381.
- Alpsoy E, Donmez L, Bacanli A, Apaydin C, Butun B. Review of the chronology of clinical manifestations in 60 patients with Behçet's disease. *Dermatology*. 2003;207(4):354-6. doi: 10.1159/000074113.
- Davatchi F, Shahram F, Chams C, Chams H, Nadji A. Behçet's disease. *Acta Medica Iranica*. 2005;43(4):233-242.
- Kurokawa MS, Yoshikawa H, Suzuki N. Behçet's disease. *Clin Exp Med*. 2004;4(1):10-20.
- Zeidan MJ, Saadoun D, Garrido M, Klatzmann D, Six A, Cacoub P. Behçet's disease physiopathology: a contemporary review. *Auto Immun Highlights*. 2016;7(1):4. doi: 10.1007/s13317-016-0074-1.
- Davatchi F. Behçet's disease. *Int J Rheum Dis*. 2018;21(12):2057-2058. doi: 10.1111/1756-185X.13465.
- Lin P, Liang G. Behçet disease: recommendation for clinical management of mucocutaneous lesions. *J Clin Rheumatol*. 2006;12(6):282-6. doi: 10.1097/01.rhu.0000249894.03016.de.
- Mansur AT, Kocaayan N, Serdar ZA, Alptekin F. Giant oral ulcers of Behçet's disease mimicking squamous cell carcinoma. *Acta Derm Venereol*. 2005;85(6):532-4. doi: 10.1080/00015550510036685.
- Kasugai C, Watanabe D, Mizutani K, Masuda Y, Zako M, Mukai T, et al. Infliximab treatment of severe genital ulcers associated with Behçet disease. *J Am Acad Dermatol*. 2010;62(1):162-4. doi: 10.1016/j.jaad.2009.02.044.
- Elad S, Or R, Shapira MY, Haviv A, Galili D, Garfunkel AA, et al. CO<sub>2</sub> laser in oral graft-versus-host disease: a pilot study. *Bone Marrow Transplant*. 2003;32(10):1031-4. doi: 10.1038/sj.bmt.1704272.
- Sharon-Buller A, Sela M. CO<sub>2</sub>-laser treatment of ulcerative lesions. *Oral Surg Oral Med Oral Radiol Endod*. 2004;97(3):332-4. doi: 10.1016/j.tripleo.2003.11.012.
- Zand N, Ataie-Fashtami L, Djavid GE, Fateh M, Alinaghizadeh MR, Fatemi SM, Arbabi-Kalati F. Relieving pain in minor aphthous stomatitis by a single session of non-thermal carbon dioxide laser irradiation. *Lasers Med Sci*. 2009;24(4):515-20. doi: 10.1007/s10103-008-0555-1.
- Zand N, Ataie-Fashtami L, Fateh M, Mansoori P, Esmaeeli DG, Fatemi SM, et al. Analgesic effects of single session of Non-Ablative CO<sub>2</sub> Laser Therapy (NACL) in major aphthous ulcers: (a preliminary study). *Lasers Med*. 2009;6(4):6-12.
- Zand N, Mansouri P, Fateh M, Ataie-Fashtami L, Rezaee Khiabanloo S, Safar F, et al. A new approach to relieve pain in oral lesions of pemphigus vulgaris using the nonablative, Non-Thermal, CO<sub>2</sub> Laser Therapy (NTCLT): preliminary results. *J Lasers Med Sci*. 2017; 8(1):7-12. doi: 10.15171/jlms.2017.02.
- Prasad R.S, Pai A. Assessment of immediate pain relief with laser treatment in recurrent aphthous stomatitis. *Oral Surg Oral Med Oral Pathol Oral Radiol*. 2013;116(2):189-93. doi: 10.1016/j.oooo.2013.02.011.
- Zand N, Fateh M, Ataie-Fashtami L, Djavid GE, Fatemi SM, Shirkavand A. Promoting wound healing in minor recurrent aphthous stomatitis by non-thermal, nonablative CO(2) laser therapy: a pilot study. *Photomed Laser Surg*. 2012;30(12): 719-23. doi: 10.1089/pho.2012.3301.
- Zand N. Non-thermal, Non-Ablative CO<sub>2</sub> Laser Therapy (NACL): A new approach to relieve pain in some painful oral diseases. In: Dumitras DC, ed. *CO<sub>2</sub> laser: optimization and application*. Croatia: InTech-Open Access Publisher; 2012. p. 387-414.
- Tuner J, Hode L. Biostimulation, Laser therapy with high output lasers. In: *The New Laser Therapy Handbook*. Sweden: Prima books; 2010. p. 67-147.
- Tuner J, Hode L. Some basic laser physics, therapeutic lasers. In: *The New Laser Therapy Handbook*. Sweden: Prima books; 2010. p. 1-47.
- Solmaz H, Ulgen Y, Gulsoy M. Photobiomodulation of wound healing via visible and infrared laser irradiation. *Lasers Med Sci*. 2017;32(4):903-910. doi: 10.1007/s10103-017-2191-0.
- Fekrazad R, Mirmoezzi A, Kalthori K, Arany P. The effect of red, green and blue lasers on healing of oral wounds in diabetic rats. *J Photochem Photobiol B*. 2015;148:242-245. doi: 10.1016/j.jphotobiol.2015.04.018.
- Thunshelle C, Hamblin MR. Transcranial low-level laser (light) therapy for brain injury. *Photomed Laser Surg*. 2016. 34(12):587-598. doi: 10.1089/pho.2015.4051.
- Basirat M. The effects of low power lasers in healing of oral ulcers. *J Lasers Med Sci*. 2012;3(2): 79-83. doi: 10.22037/jlms.v3i2.3209.
- Qadri T, Miranda L, Tunér J, Gustafsson A. The short-term effects of low-level lasers as adjunct therapy in the treatment of periodontal inflammation. *J Clin Periodontol*. 2005;32(7):714-9. doi: 10.1111/j.1600-051X.2005.00749.x.