

# High Power Laser and Photobiomodulation in Oral Surgery: Case Report



Júlia Gomes Lúcio de Araújo<sup>1</sup>, Erika Michele dos Santos Araújo<sup>2</sup>, Fernanda Cristina Nogueira Rodrigues<sup>2</sup>, Marco Aurélio Benini Paschoal<sup>3</sup>, Andréa Dias Neves Lago<sup>1\*</sup>

<sup>1</sup>Department of Dentistry I, Federal University of Maranhão, Av. Dos Portugueses, 1966, Bacanga, 65080-805, São Luis, MA, Brazil.

<sup>2</sup>Department of Operative Dentistry, School of Dentistry. University of São Paulo (USP), São Paulo, SP, Brazil

<sup>3</sup>PUC Minas University, R. Dom José Gaspar, 804, Coração Eucarístico, 30535-000, Belo Horizonte, MG, Brazil

## \*Correspondence to

Andréa Dias Neves Lago,  
Department of Dentistry I,  
Federal University of Maranhão  
(UFMA).  
Av. dos Portugueses, 1966, Bacanga  
- São Luis - MA  
Zip Code 65080-805;  
Tel: +55 98 3272-8570/ 98 – 99197-  
1411  
Emails: [adnlago@gmail.com](mailto:adnlago@gmail.com),  
[andrea.lago@ufma.br](mailto:andrea.lago@ufma.br)

Published online 15 December 2018



## Abstract

**Introduction:** The labial frenum is a fold of mucous membrane that attaches the lip and the cheek to the alveolar mucosa, the gingiva, and the underlying periosteum. In some cases, its presence can cause a midline diastema, periodontal diseases related to food impaction, or retention of biofilm, among others. In such cases, lip frenectomy is indicated as treatment, which can be performed with a scalpel (conventional method), an electric scalpel, or a surgical laser.

**Objective:** To show a clinical case performed at Laser Extension Project in Dentistry, Federal University of Maranhão grounded in a literature review.

**Case Presentation:** A laser frenectomy was performed on a female patient, aged 20, who had a diastema between the upper central incisors and an indication for frenum removal. The high-power diode laser is excellent for procedures in soft tissue because its wavelength is well absorbed by hemoglobin and other pigments; its use also allows a reduction in the amount of anesthetic and medicines used. The parameters used were 2 W, in a continuous mode, 808 nm infrared emission; with delivery of the beam through optical fiber 300 µm; energy of 120 J; 20 pps.

**Conclusion:** the high power diode laser allowed a satisfactory result, the procedure was safe, the technique was a simple one and of reduced clinical time, as mentioned in the literature. It is worth noting that the technique is dependent on the skill of the professional performing it.

**Keywords:** Diode lasers; Labial frenum; Periodontics.

## Introduction

A lip frenulum is a mucous membrane that attaches the lip and the cheek to the alveolar mucosa, the gingiva, and the underlying periosteum.<sup>1-3</sup> It is regarded as an anatomical formation that, under normal conditions, does not have pathological consequences. However, the presence of improperly inserted lip frenulum can cause orthodontics problems, periodontal diseases related to food impaction, retention of biofilm, difficulty in oral hygiene, and can greatly restrict lip movement.<sup>2-4</sup>

This condition of the labial frenum can be clinically detected by applying tension on it - the papilla lip could be moved or the ischemia of the region may be observed.<sup>1</sup> Therefore, the frenum is considered pathogenic when it is unusually wide or when there is no area of the attached gingiva along the midline or the interdental papilla is displaced due to an extension of the frenum.<sup>1,4</sup> In these cases, frenectomy is indicated as a treatment.

Frenectomy is a surgical procedure that aims to remove the lip frenum, including its ligaments to the underlying

bone.<sup>1,3,4</sup> It can be performed with a scalpel, an electrical scalpel or a surgical laser.<sup>4-6</sup> Laser treatment is often applied as an alternative or adjunct to traditional techniques, due to its effects and properties such as tissue vaporization, hemostasis, and sterilization.<sup>4,7</sup> In addition to surgical treatment, it is often necessary to complement with orthodontic and speech-language therapies to restore the normal physiology of the stomatognathic complex.<sup>8</sup> The mechanism of action of laser light is related primarily to its absorption by the irradiated tissue, which occurs because of its monochromaticity - its wavelength presents specificity for the various biological chromophores.<sup>9-11</sup> There are two types of lasers that can be used in dentistry, Low-Level Laser and High-power Laser. The high-power laser determines actions in the target tissue and can be divided based on their respective effects such as photothermic, photoablative, photomechanical acoustics, and photoionizing.<sup>10-12</sup>

Comparing the use of high power laser with the conventional technique, the former shows some

advantages such as the promotion of disinfection of the operated area, accurate incision of the tissue, minimal damage to adjacent tissues, hemostatic effect, reduction of the operative time, decreased rates of pain, fear, anxiety and adverse events post surgery. Consequently, a more comfortable postoperative recovery is reported in the literature.<sup>4,6,8</sup>

Therefore, the aim of this paper is to present a clinical case based on a review of literature on the use of high power laser for the removal of lip frenum.

### Case Report

A 20-year-old female patient was referred to the Extension Project Laser in Dentistry of the Federal University of Maranhão, with the indication of frenectomy.

Anamnesis and clinical examination were initially performed to confirm the indication for frenectomy. During the anamnesis, it was identified that the patient was normoreactive, did not use any medication and had not previously undergone any oral surgery. During the clinical examination, it was possible to observe ischemia between the upper central incisors when the lip was drawn and a slight movement of the papilla in the same area (Figure 1A).

The patient was informed and all doubts about the procedure were clarified, the advantages as well, disadvantages and possible risks related to the treatment were mentioned. After that, the Informed Consent Form (ICF) was signed and the surgery was performed using the high-power laser technique.

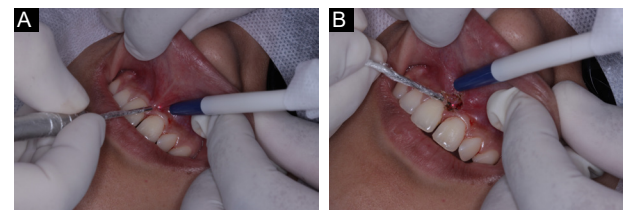
The procedure was performed with the high power laser Thera Lase (DMC, São Carlos, SP, Brazil). The settings used were power output 2 W, continuous mode, wavelength of 880 nm in infrared emission; the beam was delivered by a 300 µm optical fiber; energy level 120 J; 20 pps.<sup>3,13</sup> All measures were taken to maintain an aseptic chain as well as care related to the use of laser devices such as the use of the safety glasses by patient, operator, and assistant; and the fiber was cleaved after the frenectomy. Before starting the frenectomy, a local anesthesia was performed in the buccal vestibule of the upper incisors, using 1/3 of the anesthetic tube with lidocaine 2% (epinephrine 1:100 000) (Figure 1B). The incision was performed with a high-intensity diode laser, used in contact mode with the tensioned upper lip. Then the incision was made from the lip border until the

interincisal papilla (Figure 2A and 2B). After frenectomy was completed, the photobiomodulation (660 nm, 3 J, 100 mW) was performed with the low-level laser (Figure 3A). The postoperative follow up was performed on days 7, 15 and 21 (Figure 4A and 4B).

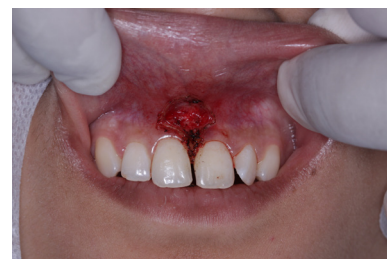### Discussion

The surgical procedure that aims to reduce tension between marginal gingival tissues and eliminate excessive interdental tissue is called frenectomy.<sup>4</sup> It is indicated when the frenulum lip is excessively extensive, in cases where no apparent zone of gingiva is inserted along the midline, and/or when a movement of the interdental papilla is detected.<sup>1</sup> The clinical diagnosis is made by applying tension along the frenum.<sup>1</sup>

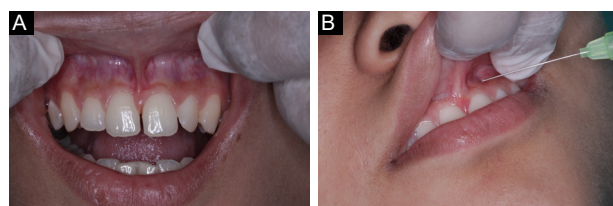
In order to perform the frenectomy, different techniques can be used such as the use of cold-scalpel, electric scalpel or high-power laser, also called surgical laser.<sup>1</sup> For the cold-scalpel, different techniques are used to perform frenectomies, simple or rhomboidal excisions, V-Y-plasties and Z-plasties. The conventional frenectomy technique may expose a large triangular wound area



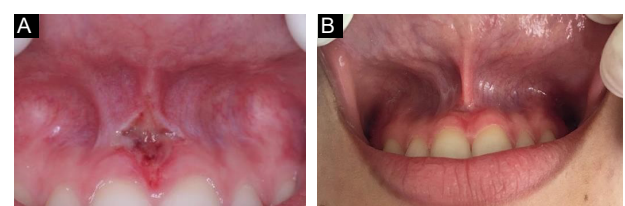
**Figure 2.** (A) Region that will be performed the incision; (B) During the incision. Federal University of Maranhão, 2016.



**Figure 3.** Immediate Postoperative. Federal University of Maranhão, 2016.



**Figure 1.** (A) Superior Lip Tensioned; (B) Local Anesthesia. Federal University of Maranhão, 2016.



**Figure 4.** (A) Postoperative With 7 Days; (B) Postoperative With 14 Days. Federal University of Maranhão, 2016.

that should be sutured at the end of the procedure, as the surgical site may bleed. These sutures should be juxtaposed to the mucosa to avoid their ends to irritate the lip.<sup>5</sup>

Compared to conventional techniques, lasers offer a new perspective of treatment, and it is possible to list some advantages such as a better view of the surgical area due to less bleeding; no need for suture – due to second-intention healing; less or even absent pain and swelling postoperatively; and a reduction in surgical time.<sup>2</sup> According to Pié-Sánchez et al.,<sup>2</sup> it is not recommended to use laser techniques to perform frenectomies in patients with short lips or when deepening of the vestibular sulcus is necessary. In these cases, cold-scalpel Z-plasty should be preferred.

There are different types of lasers, which according to their properties (wavelength, power, frequency, etc), promote different tissue interactions. The affinity between CO<sub>2</sub> laser and tissues with high water content is well documented, as is the affinity between the neodymium-doped and yttrium aluminum garnet (Nd:YAG) laser and pigments such as hemoglobin and melanin.<sup>4</sup> The diode laser has the best absorption in melanin and hemoglobin, compared to other laser systems and it also has a lower cost.<sup>16</sup> For these reasons, it was decided to use the diode laser to perform the frenectomy for this case report.

The high-power diode laser is used as a possible surgical modality in soft tissues in the oral cavity. It has a wavelength ranging from 810 to 980 nm, which is poorly absorbed in water, but extremely by hemoglobin and other pigments, therefore, there is no interaction with hard dental tissues. This laser can be used in continuous or pulsed mode, using a contact or non-contact optical fiber, depending on the clinical approach and treatment method; It is a portable, compact, and low-cost system when compared to other high power lasers.<sup>6,16-18</sup>

During and after surgery it was possible to rely on the advantages of applying the diode laser. The surgical field was clearly visible; the incision was accurate; with better control of infection risk, elimination of edema and minimal scars, reduction of postoperative pain (patient did not use analgesics); minimum dose of anesthetic administered, reduction of surgical time, surgical and postoperative period with bleeding almost absent. Additionally, there was no need for suturing, since the site did not present any bleeding and healing was by second intention.<sup>16,18-20</sup>

In addition, the laser instantaneously disinfects the area of surgery, allows a non-contact incision (thus without mechanical trauma to the tissue),<sup>12,16</sup> there is absence of vibration, vaporization of the lesions; presents anti-inflammatory and biomodulatory properties, tissue destruction accuracy, minimal damage to adjacent tissues, hemostatic effect, reduction of pain and edema and possibility of microscopic and endoscopic control.<sup>12,20</sup> Laser applications also allow patients to enjoy a more

relaxed experience in the dentist's office, reducing their fears and anxieties.<sup>12,18</sup>

In general, high power laser systems, including diode lasers, present few disadvantages compared to the procedures performed with the cold scalpel. They are the delay of repair - which is prominent in larger lesions-, and the carbonization of tissue in minor lesions.<sup>16</sup> In this way, in order to avoid delayed healing, it was decided to use laser therapy associated with high-power laser surgery. The use of low-level laser (photobiomodulation therapy) after surgery is a safe and effective treatment that allows a good healing process, reduces inflammation and guarantees analgesia.<sup>21,22</sup> There is also the possibility to apply a cooling system such as hydrogel to avoid erythema and pain caused by heat exposure.<sup>23</sup>

Thus, to perform the laser frenectomy, the anesthetic technique does not differ from that performed for resection with a cold-scalpel, although the amount of anesthetic salt required is lower.<sup>2</sup> This information was confirmed in this clinical case, because only 1/3 of the anesthetic tube was used. An incision similar to that of the scalpel was made using the optical fiber in contact. It was not necessary to make divulsion of the tissue - at the same time that the laser incised it vaporized tissue. A relevant fact found was the reduction or even absence of medication in the postoperative period.

The postoperative period was characterized by being less painful and without swelling with minimal inflammatory response,<sup>2,19</sup> according to the patient of this case report. This can be explained by the scarce damage caused by the laser to adjacent tissues, the sealing of lymphatic vessels and by the formation of a fibrin clot over the surgical wound, which protects it from external irritation.<sup>2</sup> This allows better comfort for the patient during all periods that involves the surgery since the observed anxiety was little, the pain was not observed and the routine of feeding and communication was maintained; in this way, it was possible to guarantee patient's satisfaction. Therefore, it can be inferred that due to its beneficial effects, the use of a surgical laser is confirmed as an excellent adjuvant in the procedures performed by the dentist.

## Conclusion

The result obtained in this case report was satisfactory, the technique used was simple and made it possible to perform a safe procedure and to reduce clinical time. Photobiomodulation favored a reduction in healing time and a painless postoperative period.

## Ethical Considerations

Informed consent was obtained from the patient for publication this report.

## Conflict of Interests

The authors declare no conflict of interest.

## References

- Devishree, Gujjari SK, Shubhashini PV. Frenectomy: a review with the reports of surgical techniques. *J Clin Diagn Res.* 2012;6(9):1587-1592. doi:10.7860/jcdr/2012/4089.2572
- Pie-Sanchez J, Espana-Tost AJ, Arnabat-Dominguez J, Gay-Escoda C. Comparative study of upper lip frenectomy with the CO2 laser versus the Er, Cr:YSGG laser. *Med Oral Patol Oral Cir Bucal.* 2012;17(2):e228-232.
- Butchibabu K, Koppolu P, Mishra A, Pandey R, Swapna L, Uppada U. Evaluation of patient perceptions after labial frenectomy procedure: A comparison of diode laser and scalpel techniques. *European J Gen Dent.* 2014;3(2):129-133. doi:10.4103/2278-9626.134839
- Medeiros Junior R, Gueiros LA, Silva IH, de Albuquerque Carvalho A, Leao JC. Labial frenectomy with Nd:YAG laser and conventional surgery: a comparative study. *Lasers Med Sci.* 2015;30(2):851-856. doi:10.1007/s10103-013-1461-8
- Akpinar A, Toker H, Lektetur Alpın A, Calisir M. Postoperative discomfort after Nd:YAG laser and conventional frenectomy: comparison of both genders. *Aust Dent J.* 2016;61(1):71-75. doi:10.1111/adj.12333
- Kara C. Evaluation of patient perceptions of frenectomy: a comparison of Nd:YAG laser and conventional techniques. *Photomed Laser Surg.* 2008;26(2):147-152. doi:10.1089/pho.2007.2153
- Andrade Fdo S, Clark RM, Ferreira ML. Effects of low-level laser therapy on wound healing. *Rev Col Bras Cir.* 2014;41(2):129-133. doi:10.1590/S0100-69912014000200010
- Rodrigues dos Santos ES, Imparato JCP, Adde CA, Moreira LA, Pedron IG. Frenectomia a laser (Nd:YAP) em Odontopediatria. *Rev Odonto.* 2007;15(29):107-113. doi:10.15603/2176-1000/odonto.v15n29p107-113
- Christensen GJ. Soft-tissue cutting with laser versus electrosurgery. *J Am Dent Assoc.* 2008;139(7):981-984.
- Parker S. Verifiable CPD paper: laser-tissue interaction. *Br Dent J.* 2007;202(2):73-81. doi:10.1038/bdj.2007.24
- Peavy GM. Lasers and laser-tissue interaction. *Vet Clin North Am Small Anim Pract.* 2002;32(3):517-534, v-vi.
- Cavalcanti TM, Almeida-Barros RQ, Catao MH, Feitosa AP, Lins RD. Knowledge of the physical properties and interaction of laser with biological tissue in dentistry. *An Bras Dermatol.* 2011;86(5):955-960. doi:10.1590/S0365-05962011000500014
- Aras MH, Goregen M, Gungormus M, Akgul HM. Comparison of diode laser and Er:YAG lasers in the treatment of ankyloglossia. *Photomed Laser Surg.* 2010;28(2):173-177. doi:10.1089/pho.2009.2498
- Puthussery FJ, Shekar K, Gulati A, Downie IP. Use of carbon dioxide laser in lingual frenectomy. *Br J Oral Maxillofac Surg.* 2011;49(7):580-581. doi:10.1016/j.bjoms.2010.07.010
- Mathew B, Prasanth S. Lasers in dentistry. *J Oral Maxillofac Pathol.* 2011;2(2):148-50.
- Azma E, Safavi N. Diode laser application in soft tissue oral surgery. *J Lasers Med Sci.* 2013;4(4):206-211.
- Amaral MB, de Avila JM, Abreu MH, Mesquita RA. Diode laser surgery versus scalpel surgery in the treatment of fibrous hyperplasia: a randomized clinical trial. *Int J Oral Maxillofac Surg.* 2015;44(11):1383-1389. doi:10.1016/j.ijom.2015.05.015
- Mazarei Sotoode S, Azimi S, Taheri SA, et al. Diode Laser in Minor Oral Surgery: A Case Series of Laser Removal of Different Benign Exophytic Lesions. *J Lasers Med Sci.* 2015;6(3):133-138. doi:10.15171/jlms.2015.08
- Desiate A, Cantore S, Tullo D, Profeta G, Grassi FR, Ballini A. 980 nm diode lasers in oral and facial practice: current state of the science and art. *Int J Med Sci.* 2009;6(6):358-364.
- Parker S. Lasers and soft tissue: 'loose' soft tissue surgery. *Br Dent J.* 2007;202(4):185-191. doi:10.1038/bdj.2007.128
- Carroll JD, Milward MR, Cooper PR, Hadis M, Palin WM. Developments in low level light therapy (LLLT) for dentistry. *Dent Mater.* 2014;30(5):465-475. doi:10.1016/j.dental.2014.02.006
- Rola P, Doroszko A, Derkacz A. The Use of Low-Level Energy Laser Radiation in Basic and Clinical Research. *Adv Clin Exp Med.* 2014;23(5):835-842.
- Bernardi S, Mummolo S, Zeka K, Pajewski L, Continenza MA, Marzo G. Use and Evaluation of a Cooling Aid in Laser-Assisted Dental Surgery: An Innovative Study. *Photomed Laser Surg.* 2016;34(6):258-262. doi:10.1089/pho.2015.4008