



Laparoscopic Approach to Impalpable Undescended Testes: A Single-Centre Evaluation

Ab Hamid Wani¹, Gurbir Singh^{2*}, Shavi Rayoo³, Nikhil Arya⁴

¹Assistant Professor, Department of Surgery, Government Medical College, Jammu

²Assistant Professor, Department of Surgery, SMVDIME Kakryal.

³Junior Resident, Department of Surgery, Government Medical College, Jammu.

⁴Junior Resident, Department of Surgery, Government Medical College, Jammu

***Address for Corresponder:** Dr Gurbir Singh, Assistant Professor, Department of Surgery, SMVDIME Kakryal. (email: khalsagurbir2510@gmail.com)

How to cite this article:

Wani A, Singh G, Rayoo Sh, Arya N. Laparoscopic Approach to Impalpable Undescended Testes: A Single-Centre Evaluation. Iranian Journal of Pediatric Surgery 2025; 11(12): 207 - 219.

DOI: <https://doi.org/10.22037/irjps.v11i2.48491>

Abstract

Introduction: Undescended testes (UDT) is the congenital anomaly affecting children and is one of the most common anomalies. The failure of the testes either unilateral or bilateral to reach the processus vaginalis or scrotum 10-12 weeks after birth is termed as undescended testes or cryptorchidism. Impalpable undescended testes present diagnostic and management challenges in the pediatric population.

AIM: Evaluating the role of laparoscopy in managing impalpable undescended testes.

received: 24 May 2025

accepted: 13 September 2025

Published online: 29 October 2025

This open-access article is distributed under the terms of the Creative Commons Attribution Non Commercial 3.0 License (CC BY-NC 3.0). Downloaded from: <http://journals.sbm.ac.ir/irjps>

Keywords

- Cryptorchidism
- impalpable undescended testes
- Orchidopexy
- Orchiectomy
- Examination under anaesthesia (EUA)
- Laparoscopy

Materials and Methods: The observational prospective study, conducted in the Department of General Surgery between January 2021 and December 2023. Patients who complained of absent or impalpable testes were clinically assessed and those with impalpable testes were included. Depending on the findings of diagnostic laparoscopy, testes were either brought down to the scrotum in the single- or two-staged procedure (Stephen Fowler) or removed.

Results: 25 patients with impalpable undescended testes were included, and 28 procedures were performed. Of the 25 patients, 14 had right-sided UDT, eight had left-sided UDT, and three had bilateral UDT. All the patients underwent diagnostic laparoscopy. Fourteen (50%) had high intra-abdominal testes, 10(35.7%) had low intra-abdominal testes, 3(10.7%) entered the deep ring with vas and vessels, and one patient had nubbin testis. Fifteen patients underwent single-stage laparoscopic orchidopexy, 7 patients underwent two-staged procedures, three patients had vas and vessels entering the deep ring and underwent open inguinal orchidopexy, while three patients underwent orchiectomy.

Conclusion: Ultrasonography (USG) and magnetic resonance imaging (MRI), are the imaging modalities which play a crucial role in localization of impalpable testes. However, laparoscopy provides the most accurate interventional option by demonstrating anatomy.

Introduction

Undescended testes or cryptorchidism is among the common congenital anomalies affecting about thirty percent of premature

infants and three percent of full-term males.¹ The unilateral or bilateral failure of the testes to get to the bottom of the

scrotum by 10-12 weeks after term is termed as undescended testes.² There are multiple factors which can cause undescended testes, with premature birth being the most common cause. Other factors related to undescended testes are family history with associated genetic mutations and low birth weight for gestational age.³ About 20 per cent of the undescended testes patients, represent impalpable testes on clinical examination.⁴ Impalpable undescended testis is classified as intra-abdominal, intra-canalicular, vanishing testes, and agenesis (atrophic) testes.⁵ Undescended testis can cause significant and severe complications like infertility, torsion, testicular trauma and carcinoma.⁶⁻⁷ Undescended testis causes decreased sperm count, poor quality of sperm, and low fertility rate as compared to normal males. The fertility rate is further decreased with involvement of both sides and increasing age at the time of orchidopexy.⁸ Six months to one year of age is recommended to be the optimum time for orchidopexy.⁹ Various tools to diagnose and detect undescended testes include physical examination, ultrasonography, magnetic resonance imaging, and laparoscopic examination.^{8,10-11} Ultrasound is the most favoured

investigation as it is the least invasive, fast and simple procedure, but with low sensitivity and specificity of approximately 45 per cent and 78 per cent, respectively.¹² Laparoscopy can identify and localize the undescended testis, and treatment can be administered immediately after localization.

Aim: Evaluating the role of laparoscopy in managing impalpable undescended testes.

Materials and Methods

The study is an observational prospective study conducted in the Department of General Surgery, between January 2021 and December 2023. Twenty-five patients with impalpable undescended testes, after obtaining informed written consent from their parents were included in the study. This study was approved by the Institutional Ethics Committee of the authors (IEC/XXX/2121/447).

Inclusion criteria:

- All patients with absent testes reporting to the outpatient department were examined, and Patients with impalpable testes were included in our study.

Exclusion criteria

- Patients having retractile testes.

- Patients with palpable undescended testes.
- Patients with a history of inguinal surgery.

The patients with complaints of absent testes reporting to the outpatient department were assessed by clinical examination and underwent ultrasonography (both abdominal and inguinal). In the study, the patients of impalpable undescended testes on clinical examination and USG-documented intra-abdominal testes were included. The patients were examined in the outpatient department, and post-induction examination (EUA) was performed to exclude patients with palpable testes. Patients with impalpable undescended testes were taken up for Diagnostic Laparoscopy. The 5mm primary port was inserted through the inferior margin of the umbilicus using the open technique, and pneumoperitoneum was created up to 10 mmHg in patients in 30-degree head-down trendelenburg position with the left side up for left-sided undescended testes and right side up for right-sided undescended testes. After inspecting the internal ring area bilaterally, other two trocars (5mm) were inserted under vision of laparoscope into the left and right lumbar regions, in same

horizontal line with the umbilical port. During laparoscopic examination, depending on the findings the testes found were either brought down laparoscopically to the scrotum in a single or two-stage procedure or removed. The inguinal area was inspected first for patency of internal inguinal ring, and then the bilateral iliac areas and pelvis were inspected. The patients with intra-abdominal testis were then classified as high (if more than 2 cm from inguinal ring or above the iliac vessels) and low (within 2 cm of intrernal ring or below the iliac vessels). After gentle traction on the testis, the most distal part of the gubernacular attachment was divided and the testis was mobilized. After adequately mobilizing the testis, for which a stretch maneuver was performed, where the testis was stretched to the contralateral internal ring and dissection was continued in the ipsilateral deep ring to complete the herniotomy. The peritoneal coverage was dissected between the urinary bladder and vas deferens. **(Figure 1)** A tunnel was created after passing the laparoscopic dissector (blunt tip) over the pubic bone through the ipsilateral hemiscrotum and a dartos pouch was developed in the ipsilateral hemiscrotum. The testis was brought down to the scrotal dartos pouch in

the ipsilateral hemiscrotum by grasping the gubernacular tissue. The abdomen was deflated to confirm the length, as releasing the pneumoperitoneum provides an additional length. A chromic catgut or vicryl suture was used to fix testes in the hemiscrotum. In cases of high intra-abdominal testis or in patients in whom adequate mobilization was not possible, a two-stage procedure was performed. In the first stage, diagnostic laparoscopy followed by division of the testicular vessel (Stephen-Fowler stage I) was performed. **(Figure 2 and 3)** In second stage, (Stephen Fowler stage-II) after 3 months, laparoscopic orchidopexy was done. Orchidectomy was performed in patients

with nonviable or atrophic testes. In patients with intra-abdominal blind-ending cord structures on diagnostic laparoscopy, no further intervention was performed, and a diagnosis of a vanishing testis was made. On laparoscopy, open orchidopexy was performed if cord structures were found entering the canal through the deep ring. The abdominal cavity was re-examined and pneumoperitoneum was released. The trocars were removed and the port sites were closed. The patients were discharged on day 1 or 2. Patients were followed-up for 6 months to one year. Data were tabulated in an Excel spreadsheet, and SPSS version 22 was used for statistical analysis.

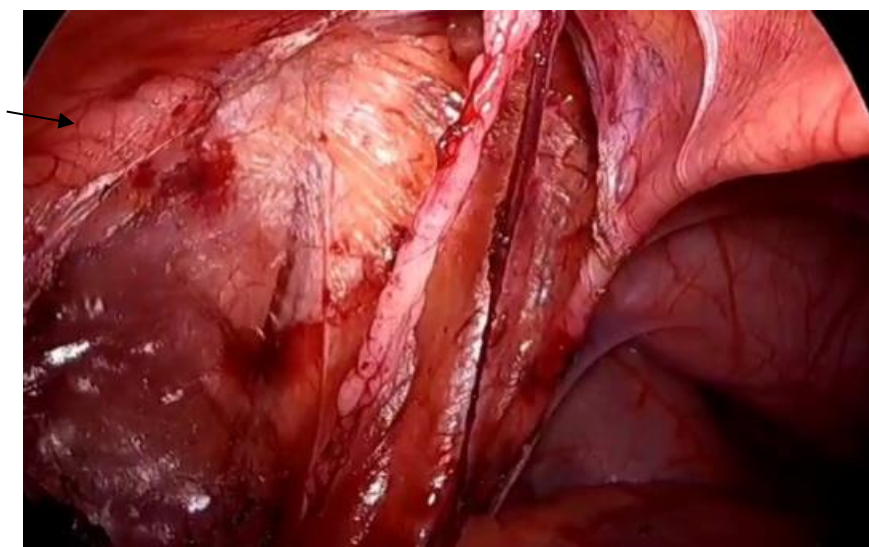


Figure 1: Single stage laparoscopic orchidopexy, arrow showing vas deferens.

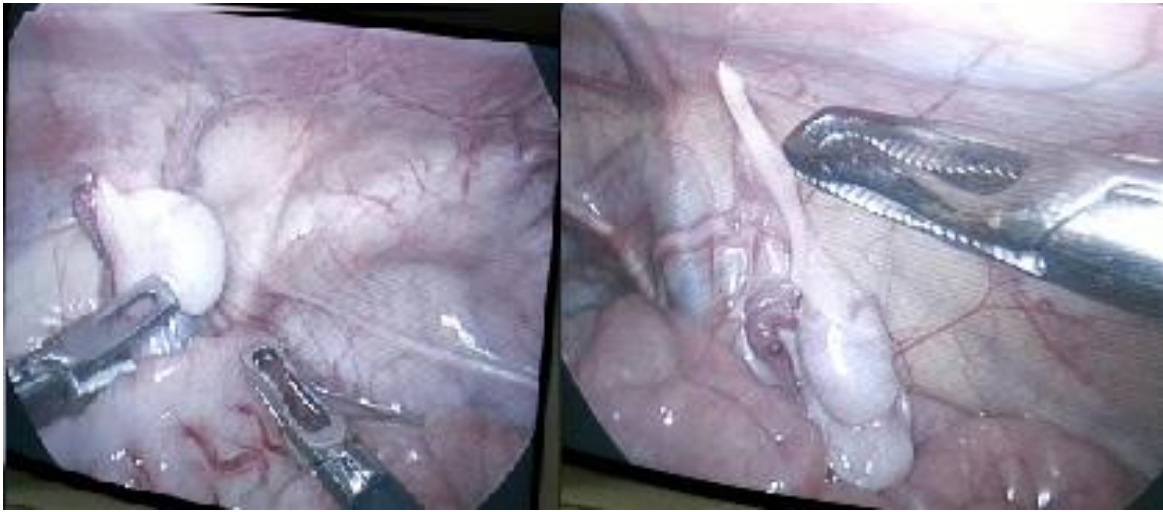


Figure 2: Laparoscopic view of bilateral undescended testis; left view: left undescended testis, right view: right undescended testis.

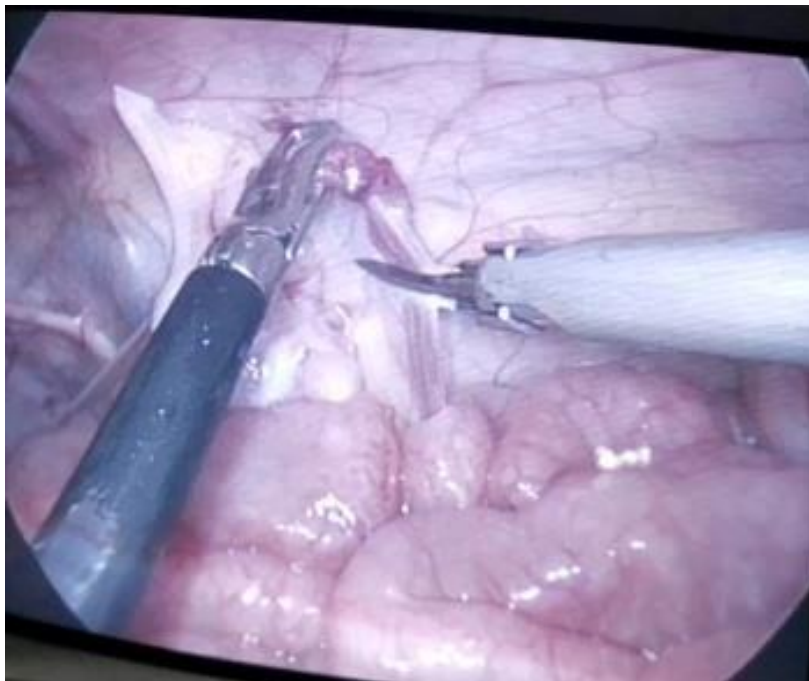


Figure 3: showing division of testicular vessels (Stephen-Fowler stage 1)

Result

Twenty-five patients with impalpable undescended testes were included in our study and underwent 28 procedures, as three patients had bilateral undescended testes. The age of the patients in our study ranged from 1 to 11 years. Of these 25 patients, 14 had right-sided impalpable undescended testes, 8 had left-sided impalpable undescended testes, and 3 had bilateral impalpable undescended testes. **(Figure 4)** All the patients in the study underwent ultrasonography and Intra-

abdominal testes were detected in 15 patients (53.6%). All the patients underwent diagnostic laparoscopy. Fourteen (50%) patients had high intra-abdominal testes, 10(35.7%) patients had low intra-abdominal testes, 3(10.7%) patients had vas and vessels entering the deep ring, and 1 patient had nubbin testis. **(Table 1)** On diagnostic laparoscopy, 15(53.6%) patients had normal testes, 10(35.7%) had hypoplastic testes, two (7.1%) had atrophic testes, and one (3.6%) had blind-ending vas.

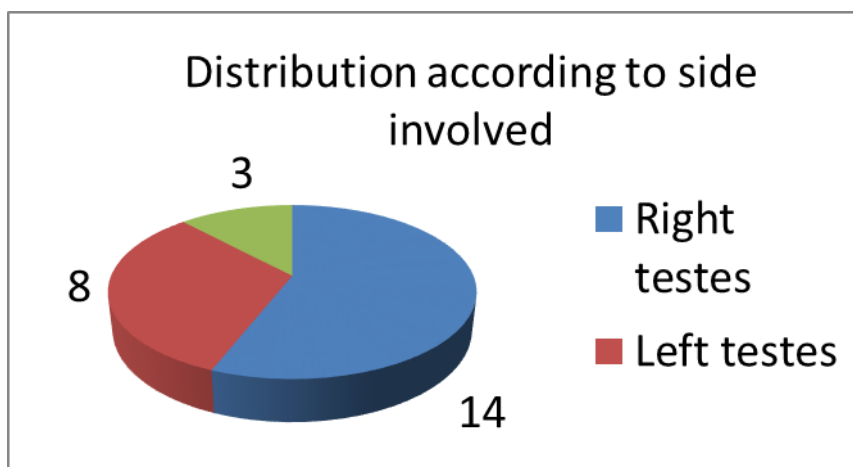


Figure 4: Distribution of patients according to the side involved in undescended testes.

Table 1: Location of impalpable testis on diagnostic laparoscopy.

Position of testis	Number	Percentage
High Intra-abdominal	14	50%
Low Intra-abdominal	10	35.7%
Entering deep ring	3	10.7%
Blind Ending Vas	1	3.6%
Total	28	100

(Table 2) In 15 patients, single-stage laparoscopic orchidopexy was performed as mobilization with adequate lengthening was possible in these patients. A two-stage procedure was performed in 7 patients as in these patients, the testes were high, and

adequate mobilization was not possible. In 3 patients, vas and vessels were entering deep ring, open inguinal orchidopexy was done in these patients while 3 patients underwent orchidectomy with atrophic testis.

Table 2: Morphological findings of impalpable testis during laparoscopy.

Laparoscopic Finding	Number	Percentage
Normal testes	15	53.6%
Hypoplastic	10	35.7%
Atrophic	2	7.1%
Nubbin Testis	1	3.6%
Total	28	100%

(Table 3) No major intraoperative or postoperative complications were noted in any of the patients. One patient had postoperative seroma formation in open

inguinal orchidopexy. No long-term complications such as atrophy were noted in any patient.

Table 3: Operative procedures performed for impalpable undescended testis.

Procedure	Number	Percentage
Single Stage Laparoscopic orchidopexy	15	53.6%
Two stage Laparoscopic Orchidopexy	7	25.0%
Open orchidopexy	3	10.7%
Orchidectomy	3	10.7%

Discussion

In our study, right-sided impalpable undescended testes were more commonly seen in 56% of the patients, whereas bilateral undescended testes were observed in only 12% of the patients. These findings are contrary to the previous study by Dar et al. (42%) and Ismail et al. (13.5%) and Hassan et al. (21%).¹³⁻¹⁵ In a study by Salah et al., the most common side involved was the left side (42%).¹⁶ Ultrasound was done in all patients with intra-abdominal testis

were detected in 53.6% of the patients with undescended testes. Salah et al., in his study reported the detection rate of 31.5%, while in a study by Dar et al., it was reported as 78.7%.^{13,16} There is a significant improvement in the growth and function of UDT with orchidopexy before the age of one year. The diagnostic yield of laparoscopy was 96.4%, as in our study, 27 patients with impalpable undescended testes were localized and managed, while one patient had a vanishing testis or blind-

ended vas. In a study by Dar et al., it was 96.9%, while El-Gohary reported 100% accuracy in the localization of undescended testes.^{13,17} In our study, normal testes were seen in 53.6% of the patients and hypoplastic testes in 35.7% of the patients. These morphological findings on laparoscopy correlate with the location of the testis. The incidence of hypoplasia was high in patients with intra-abdominal testes. These findings are similar to those reported by Dar et al. and Humphrey et al.^{13,18} A total of 25 patients were operated on and underwent 28 procedures. Among these 28 procedures, 15 were single-stage laparoscopic orchidopexy, 7 were two-stage laparoscopic orchidopexy, 3 were open orchidopexy via the inguinal approach after diagnostic laparoscopy, and three patients underwent orchidectomy. Laparoscopic orchidopexy was performed in 78.6% of the patients. This rate is similar to previous studies by Dar et al. and Salah et al.^{13,16} On the contrary, Khan et al., and Masao et al., reported laparoscopic orchidopexy in 35% and 33% of the patients, respectively.^{19,20} This can be due to the reason that, most of the patients in our study were having intra-abdominal testis. There is progressive negative impact on the development of germ cells and

leydig cells, thus increasing the risk of malignant transformation as long as the testis remains undescended after 12 months. Laparoscopy is the gold standard for impalpable testes, as it not only helps to identify, but also provides an opportunity to perform simultaneous orchidopexy of viable testes. It also helps avoid unnecessary groin exploration or negative exploration in patients with a vanishing testis. Considering the cost and time-effective, and sensitivity of localizing the testis, laparoscopy is more superior to other radiological investigations like ultrasound and magnetic resonance imaging for managing the patients with impalpable undescended testis.

Limitations: Low sample size and short-term follow-up period. Some patients were lost to follow-up.

Conclusion

Ultrasonography (USG) and magnetic resonance imaging (MRI), are the imaging modalities which play a crucial role in the localization of impalpable testes. However, laparoscopy provides the most conclusive diagnostic and interventional options by demonstrating the anatomy. It provides

visual information for the diagnosis as well as management of patients with impalpable undescended testes. Furthermore, minimal access surgery is offered to pediatric patients.

Main Points

- Laparoscopy is the most accurate diagnostic and interventional options for this condition.
- Avoids unnecessary groin exploration in patients with vanishing testes.
- Minimal intraoperative and postoperative complications.

Ethical Consideration

Approval was obtained from the Ethics Committee of Government Medical College, Jammu. (No: IEC/GMCJ/2025/2330)

Acknowledgment

Not applicable

Funding/Support

Not applicable

Conflict of interests

There is no conflict of interest

References

1. Acderini CL, Miles HL, Dunger DB, Ong KK, Hughes IA. The descriptive epidemiology of congenital and acquired cryptorchidism in a UK infant cohort. *Arch Dis Child*. 2009;94: 868-72.
2. Cobellis G, Noviello C, Nino F, et al. Spermatogenesis and cryptorchidism. *Front Endocrinol (Lausanne)* 2012; 5:63.
3. Jensen MS, Toft G, Thulstrup AM, Henriksen TB, Olsen J, Christensen K, et al. Cryptorchidism concordance in monozygotic and dizygotic twin brothers, full brothers, and half-brothers. *Fertil Steril*. 2010; 93:124-9.
4. Kirsch AJ, Escala J, Duckett JW, Smith GH, Zderic SA, Canning DA, et al. Surgical management of the nonpalpable testis: The children's Hospital of Philadelphia experience. *J Urol*. 1998; 159:1340-3.
5. Moore RG, Peters CA, Bauer SB, Mandell J, Retik AB. Laparoscopic evaluation of the nonpalpable testis-a prospective assessment of accuracy. *J Urol*. 1994; 151:728-31.
6. Tasian GE, Hittelman AB, Kim GE, DiSandro MJ, Baskin LS. Age at orchiopexy and testis palapability predict germ and leydig cell loss: Clinical predictors of adverse histological features of cryptorchidism. *J Urol*. 2009; 182:704-9.
7. Pettersson A, Richiardi L, Nordenskjold A, Kaijser M, Akre O. Age at surgery for undescended testis and risk of testicular cancer. *N Engl J Med*. 2007;356: 1835-41.
8. Docimo SG, Silver RI, Cromie W. The Undescended testicle: Diagnosis and management. *Am Fam Physician*. 2000; 62:2037-44.
9. Park KH, Lee JH, Han JJ, Lee SD, Song SY. Histological evidences suggest recommending orchiopexy within the first year of life for children with unilateral inguinal cryptorchid testis. *Int J Urol*. 2007; 14:616-21.
10. Patil KK, Gren JSA, Duffy PG. Laparoscopy for impalpable testis. *BJU Int*. 2005;95: 704-8.
11. Ostlie DJ, Gatti JM. The use of laparoscopy in the management of nonpalpable undescended testis. *Curr Opin Pediatr*. 2007; 19:349-53.
12. Elder JS. Laparoscopy for impalpable testes: Significance of the patent processus vaginalis. *J Urol*. 1994; 152:776-8.

13. Dar SA, Bali RS, Zahoor Y, Kema AR, Bhardwaj R. Undescended testes and laparoscopy: Experience from developing world. *Adv Urol*. 2018;1620470.
14. Ismail K, Ashour M, El-Afifi M, Hashish A. Laparoscopy in the management of impalpable testis. *World J Surg*. 2009;33(7):1514-9.
15. Hassan ME, Mustafawi A. Laparoscopic management of impalpable testes in children- new classification; lessons learned and rare anomalies. *J Laparoendosc Adv Surg Tech*. 2010;20(3):265-9.
16. Salah SEE, Ahmed EOE. The role of laparoscopy in nonpalpable undescended testis: Analysis and review of the experience from two cities in Sudan. *Afr J Paediatr Surg*. 2022;19(3):127-32.
17. El-Gohary MA. The role of laparoscopy in the management of impalpable testes. *Pediatr Surg Int*. 1997;12(5-6):463-5.
18. Humphery GME. Laparoscopy in the management of the impalpable undescended testis. *Br J Surg*. 1998;85(7):983-5.
19. Khan SA, Laghari AA, Abbasi MR, Bhatti S. Laparoscopic assisted management of impalpable testis in patients older than 10 years. *JSLs*. 2010;14(2):251-5.
20. Tsujihata M, Miyake O, Yoshimura K, Kakimoto K, Matsumiya K, Takahara S, et al. Laparoscopic diagnosis and treatment of nonpalpable testis. *Int J Urol*. 2001;8(12):692-6.