

## Microcystic Mesenteric Lymphatic Malformation, a Mimicker of Solid Masses in Children

Shamim Tayebi<sup>1</sup> , Masoud Mahdavi Rashed<sup>2</sup>, Majid Shams<sup>1</sup>, Mona Maftouh<sup>1\*</sup> 

<sup>1</sup>Department of Radiology, Faculty of Medicine, Mashhad University of Medical Sciences, Mashhad, Iran.

<sup>2</sup> Akbar and Dr.sheikh Hospital, Mashhad University of Medical Sciences, Mashhad, Iran.

\*Address for Corresponder: Dr. Mona Maftouh, Department of Radiology, Faculty of Medicine, Mashhad University of Medical Sciences, Mashhad, Iran (email: monarch.1171@gmail.com )

How to cite this article:

Tayebi Sh, Mahdavi Rashed M, Shams M, Maftouh M. Microcystic mesenteric lymphatic malformation, a mimicker of solid masses in children. Iranian Journal of Pediatric Surgery 2020; 6(2):113 -117 .

DOI: <https://doi.org/10.22037/irjps.v6i2.27456>

### Abstract

Mesenteric microcystic lymphangioma is a rare benign abdominal mass. It appears as a solid mass which may mimic a solid mesenteric or omental mass. Pure microcystic lesions are ill-defined and hyperechoic due to abundant wall interfaces.

A case of mesenteric microcystic lymphangioma is presented in combination with appendicitis. A 6-year-old boy presented with rapid onset of abdominal pain accompanied by nausea and vomiting. Ultrasound showed a hyperechoic solid mass without vascularity at Doppler evaluation. Computed tomography showed a mass in the small bowel mesentery with attenuation values in the range of water. In the pathologic evaluation, mesenteric lymphangioma with small and medium-sized cysts was reported.

Microcystic lymphatic malformation could be considered in the differential diagnosis of a solid abdominal mass in pediatrics and imaging features can be helpful to differentiate between them.

### Keywords

- Lymphatic Malformation
- Mesenteric Mass
- Microcystic
- Lymphangioma

## Introduction

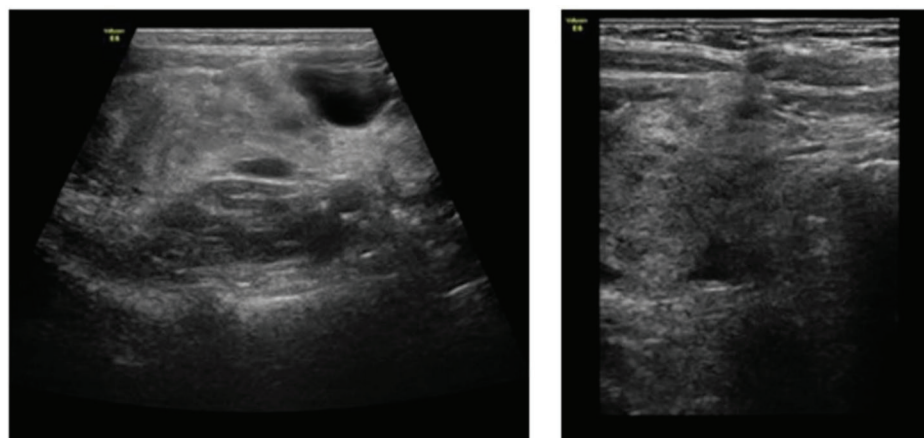
Lymphatic malformations are one of the most common benign vascular masses in pediatrics (ranked second after hemangiomas). They usually occur in the head and neck, axilla and thorax, whether localized or generalized.<sup>1-3</sup> About 5% of benign pediatric masses are lymphangiomas and its prevalence in the abdomen is less than 1%.<sup>4</sup> Mesenteric lymphangioma is uncommon among children and there are few case reports in the medical literature.<sup>4</sup> They are usually found incidentally during an abdominal examination for an unrelated condition. Symptoms can imitate intestinal obstruction, volvulus, intussusception or peritonitis so that clinical diagnosis can be difficult.<sup>3-8</sup> Imaging studies are performed to differentiate between these conditions and can help find the correct diagnosis. Lymphatic malformations may consist of large (macrocytic) or small (microcytic) lesions or both. Macrocytic lymphangioma appears as septated cysts in the imaging, while microcystic lymphangioma appears solid and shows enhancement on post contrast images. These features may mimic a solid

mesenteric or omental mass.<sup>9</sup> Pure microcystic lesions are ill-defined and hyperechoic due to abundant wall interfaces.<sup>10</sup> Here we report, an acute presentation of microcystic mesenteric lymphangioma in a boy.

## Case presentation

A six-year-old boy with the chief complaint of colicky abdominal pain which had started one week ago was referred to our emergency department. The pain gradually worsened, accompanied by nausea and vomiting. He had an acute abdomen with significant abdominal distension, generalized abdominal tenderness with guarding and diminished bowel sounds.

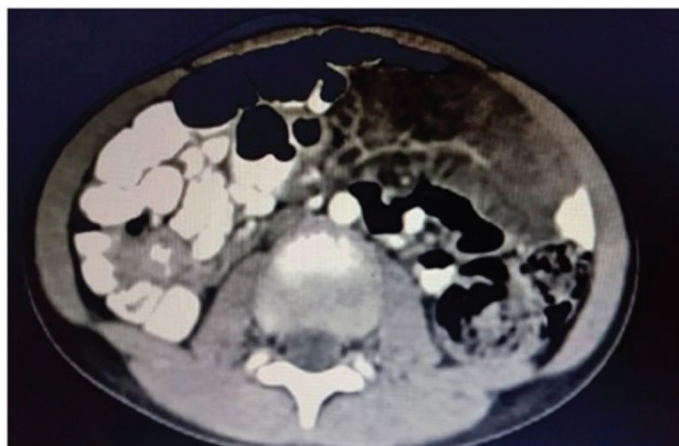
Ultrasound examination showed a hyperechoic heterogeneous solid mass near the terminal ileum, which was measured 8\*5\*6.5 cm, surrounded by a few small anechoic cystic structures. Color Doppler ultrasound was performed and showed no obvious venous and arterial flow. It appeared to be closely related to the adjacent bowel **Figure 1**.



**Figure 1 a, b.** Ultrasound showed a solid heterogeneous hyperechoic mass

No signs of invagination were seen. Computed tomography showed a low-density mass lesion in the small bowel mesentery encasing the mesenteric vessels and multiple satellite small cysts around.

There was a significant mesenteric fat stranding in the right lower quadrant around the terminal ileum **Figure 2**.



**Figure 2:** CT scan showed low-density heterogeneous mass with attenuation values in the range of water in the right lower quadrant of the abdomen.

The patient underwent an emergent laparotomy. There was a well-defined 7× 4 cm mass attached to the mesenteric fat with a multi-cystic (spongy) appearance in the ileal mesentery adjacent to the bowel wall with intraluminal involvement, ranged about 50 cm from the cecum. The mesenteric mass and about 10cm of the ileum were resected and end-to-end anastomosis was done. Also, appendectomy was done due to the presence of appendicolith. The pathologic evaluation reported focal nodular hyperplasia of lymphoid tissue, mesenteric fat with numerous and multi-cystic pattern of small to medium-sized lymphatic and vascular channels, also occasional reactive lymphoid follicles within the wall of the small intestine, which confirmed mesenteric lymphangioma. Furthermore, an

appendix with hyperemic serosa in the specimen was reported. No postoperative complications occurred and he was discharged after six days.

## Discussion

A lymphatic malformation in the mesentery is a cystic type of lymphangioma (according to the classification of Landing and Farber).<sup>11</sup> The exact pathogenesis is unknown. The abnormal development of the lymphatic system has been suggested as the hypothesis of lymphatic malformation, although further studies have proposed the possibility of a relationship between abdominal trauma, surgery, radiation, inflammation, and lymph node degeneration and lymphatic malformation.<sup>1-3</sup> Lymphangioma

represent up to 5% of benign pediatric masses and 1/20,000 of pediatric hospital admissions.<sup>12,13</sup> Males are more involved in the pediatric population, with a reported male-to-female ratio of 1.6 to 3:1.<sup>8,12,13</sup> Lymphangiomas have been categorized as three types of capillary, cystic and cavernous lesions based on histology. Cystic lymphangiomas contain large lymphatic spaces including chylous or serous fluid without normal connection between the contiguous lymphatics. Most of the cystic lymphangiomas discussed in the literature are macrocytic types of lymphangioma and microcystic types are less common.<sup>9</sup>

In our study, we found a hyperechoic mass with small cystic focuses on ultrasound examination. Pure microcystic lymphangiomas are rare ill-defined and hyperechoic lesions on the ultrasound due to numerous wall interfaces. They can be misinterpreted with other masses which have hyperechoic echotexture like lipoblastoma and hemangioma.<sup>9</sup> Microcystic lymphangioma can be differentiated from hemangioma by color Doppler ultrasound. Doppler findings of hemangioma are hyperechoic and/or hypoechoic lesions with marked internal flow due to numerous arteries and veins with low resistance spectral analysis, while microcystic lymphangioma has no vascularity on Doppler ultrasound. Lipoma and lipoblastoma can easily be differentiated from microcystic lymphangioma using densitometry on the CT scan. Lipoma and lipoblastoma have attenuation values in the range of fat, while microcystic lymphangioma has attenuation values in the range of water.<sup>15</sup> According to the appendix serosal inflammation reported in pathologic evaluation after laparotomy,

the microcystic lymphangioma was an incidental finding, because symptoms of the patient could be related to appendicitis.

## Conclusion

Mesenteric lymphatic malformations are rare, but a clinician should consider them in the differential diagnosis of an atypical acute abdomen in children. Microcystic type of lymphangioma is less common than the other types and it can be diagnosed with imaging, preferably ultrasound and CT scan with contrast before surgery. Correct perception of different possible appearances of cystic lymphangioma can lead radiologists to make an accurate diagnosis.

## Acknowledgements

Not applicable

## Funding/Support

Not applicable

## Conflict of interests

There is no conflict of interests

## References

1. Siddique K, Bhandari S, Basu S: Giant mesenteric lymphangioma: a rare cause of a life-threatening complication in an adult. *BMJ Case Rep* 2010.
2. Chung JC, Song OP: Cystic lymphangioma of the jejunal mesentery presenting with acute abdomen in an adult. *Can J Surg* 2009; 52: E286–E288.
3. Chen CW, Hsu SD, Lin CH et al: Cystic lymphangioma of the jejunal mesentery in an adult: a case report. *World J Gastroenterol* 2005; 11: 5,084–5,086.
4. M\_endez-Gallart R, Bautista A, Est\_vez E, et al: Abdominal cystic lymphangiomas in pediatrics: surgical approach and outcomes. *Acta Chir Belg* 2011;111:374–377.
5. Suthiwartnarueput W, Kiatipunsodsai S, Kwankua A, et al: Lymphangioma of the small bowel mesentery: a case report and review of the literature. *World J Gastroenterol* 2012;18:6328–6332.
6. De Vries JJ, Vogten JM, de Bruin PC, et al: Mesentericallymphangiomas causing volvulus and intestinal obstruction. *Lymphat Res Biol* 2007;5:269–273.
7. Luo CC, Huang CS, Chao HC, et al: Intra-abdominal cystic lymphangiomas in infancy and childhood. *Chang Gung Med J* 2004; 27:509–514.
8. Kosir M, Sonnino R, Gauderer M: Pediatric abdominal lymphangiomas: a plea for early recognition. *J Pediatr Surg* 1991;26(11): 1309-13.
9. Dubois J, Alison M: Vascular anomalies: what a radiologist needs to know. *Pediatr Radiol* 2010;40(6):895–905.
10. Candace L. White, Brandon Olivieri, Ricardo Restrepo, et al: Low-Flow Vascular Malformation Pitfalls: From Clinical Examination to Practical Imaging Evaluation-Part 1, Lymphatic Malformation Mimickers. *American Journal of Roentgenology* 2016 206:5, 940-951.
11. Romeo V, Maurea S, Mainenti PP, et al: Correlative imaging of cystic lymphangiomas: ultrasound, CT and MRI comparison. *ActaRadiol Open* 2015;4:1–4.
12. Konen O, Rathaus V, Dlugy E, et al: Childhood abdominal cystic lymphangioma. *Pediatr Radiol* 2002;32:88-94.
13. Steyaert H, Guitard J, Moscovici J, et al: Abdominal cystic lymphangioma in children: benign lesions that can have a proliferative course. *J PedSurg* 1996;31(5):677-80.
14. William E. Shiels II: Lymphatic Malformation: Radiologic-Pathologic-Therapeutic Correlation and Management Implications *J Am Osteopath Coll Radiol* 2012;1(3).
15. Chung EM, Biko DM, Arzamendi AM, et al: Radiographics. Solid tumors of the peritoneum, omentum, and mesentery in children: radiologic-pathologic correlation: from the radiologic pathology archives 2015;35(2):521-46.