

Chronic nonpigmented Villonodular synovitis in a 13 years old girl: A case report

Masoud Yavari¹

Naghmeh Poorpezeshk^{1,2*}

Hamidreza Alizadeh Otaghvar¹

Leily Mohajerzadeh³

¹ 15 Khordad Educational Hospital, Shahid Beheshti University of Medical Sciences, Tehran, Iran

² Department of Surgery, Naft Central Hospital, Petroleum Industry Health Organization, Tehran, Iran.

³ Pediatric Surgery Research Centre, Research Institute for Children Health, Shahid Beheshti University of Medical Sciences, Tehran, Iran

***Address for Correspondence:** Dr. Naghmeh Poorpezeshk, Panzdahe Khordad Educational Hospital, Shahid Beheshti University of Medical Sciences, Tehran, Iran
(email: naghmeh_pr@yahoo.com)

How to cite this article:

Yavari M, Poorpezeshk N, Alizadeh Otaghvar H, Mohajerzadeh L. Chronic nonpigmented Villonodular synovitis in a 13 years old girl: A case report. *Iranian Journal of Pediatric Surgery* 2018; 4(1): 47-53.

DOI: <http://dx.doi.org/10.22037/irjps.v3i3.11966>

Abstract

Keywords

- nonpigmented Villonodular synovitis
 - proliferative disorder
 - pediatric
- Nonpigmented villonodular synovitis is a very uncommon and benign proliferative disorder involving the synovium. It is mostly seen in the knee. Here we present a 13-year old girl with a 2 year history of left wrist mass without any pain, tenderness or limitation in range of motion. We believe it is necessary to consider villonodular synovitis in a child with chronic joint effusion as a differential diagnosis.

Introduction

Nonpigmented villonodular synovitis (non-PVNS) is a benign proliferative disorder which involves the synovium and can involve synovium of the tendon sheath.^{1,2,3} It is a rare condition that is not well recognized and is divided into localized or nodular and diffuse.^{2,4} Histologically, the nodular form is similar to giant cell tumor of the tendon sheath on the other hand the diffuse form mostly affects the

knee.^{3,5} Among the few reported cases in literature, wrist involvement is rare.⁶ Philip Neubauer et al, believed that the pigmented villonodular synovitis should be sought as a differential diagnosis in any child with chronic joint effusion. In a study in China, 237 patients were evaluated. Their outcome showed female predominance, often between 20-40 years mostly affecting the knee and hip, especially knee.⁷ We present a 13-year old girl with a 2 year

received: 12 April 2016

accepted: 31 May 2016

ISSN 2423-5067

history of left wrist mass.

Case report

A 13-year old girl was visited at the clinic with a chief complaint of left wrist mass **Figure 1a, 1b**. She suffered from the mass for two years. She had no complaint of pain or joint mobility restriction. The mass had grown gradually and there was no history of trauma to the wrist. Past medical history was negative so was the familial and drug history. General condition and vital signs were normal so

was the general physical examination. The mass examination showed a firm, non mobile 5×5cm mass, from zone VI extensor to distal of the wrist **Figure 1a, 1b**. It did not involve the skin and there were no tenderness, warmth or redness. Passive and active motions of wrist were normal. Preoperative sonography showed two 12 mm cysts with a thick wall presenting as a synovial cyst **Figure 2**. Blood biochemistry and CBC was normal and operation was planned for mass resection.

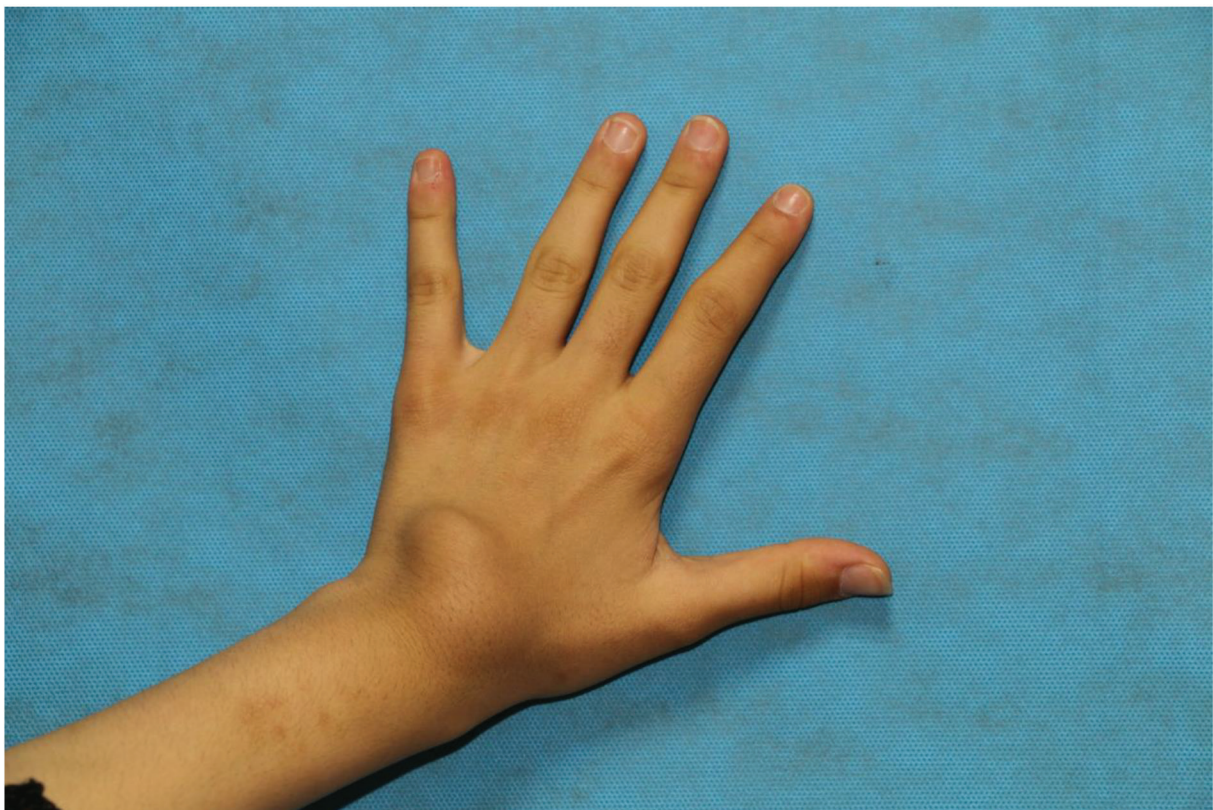


Figure 1a :Preoperative photograph demonstrating the soft tissue mass on the dorsal aspect of the left wrist. Anterior view.

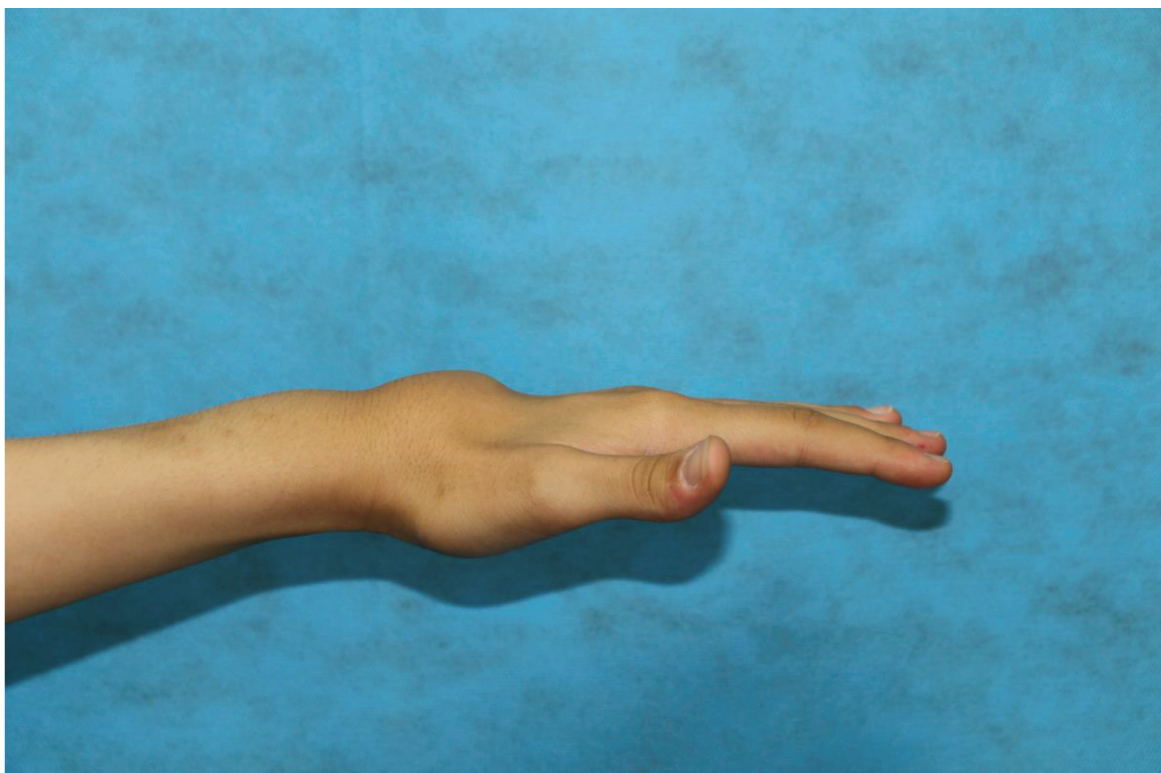


Figure 1b :Preoperative photograph demonstrating the soft tissue mass on the dorsal aspect of the left wrist. Lateral view.

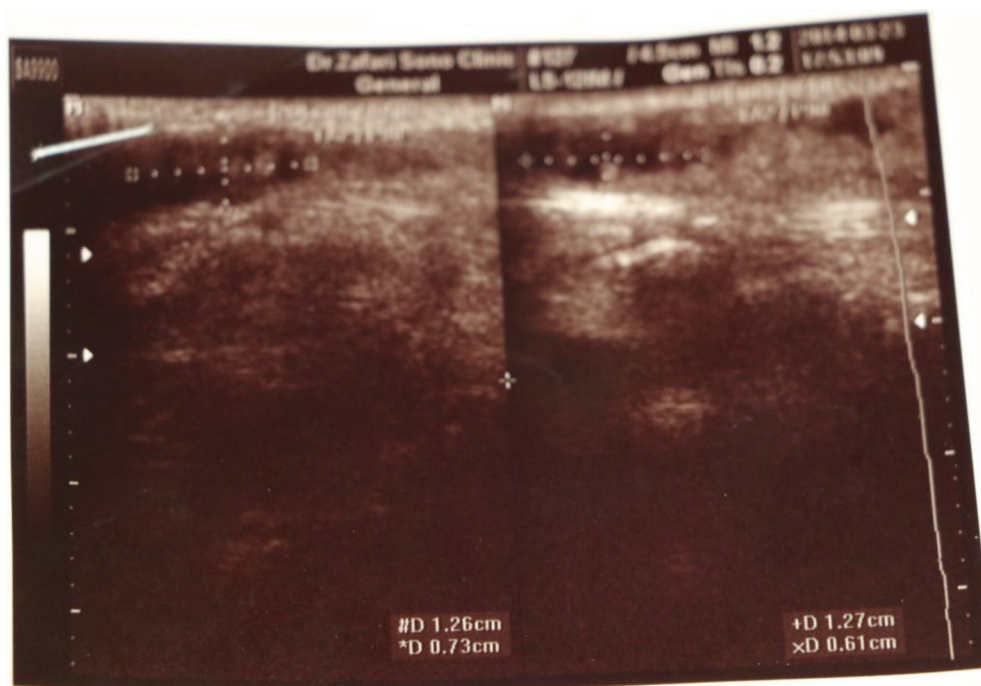


Figure 2 :Preoperative sonography showed two cysts, 12 mm with thick wall presented synovial cyst.

Operation report: After skin preparation and draping under general anesthesia, skin was incised, proximal and distal flaps were elevated and subcutaneous tissue opened. A nonhomogenous and berrylike mass was apparent, which occupied all spaces of the forth extensor compartment **Figure 3a, 3b**. The extensor tendon was surrounded by the mass with no adhesion to floor of the

compartment or any joint synovium. During the operation it was noticed that the mass had spread to the musculotendinous junction so the incision was expanded and total excision was performed. Hemostasis was established, compartment was closed with no tension, penrose drain was placed and the wound was closed with subcuticular sutures.

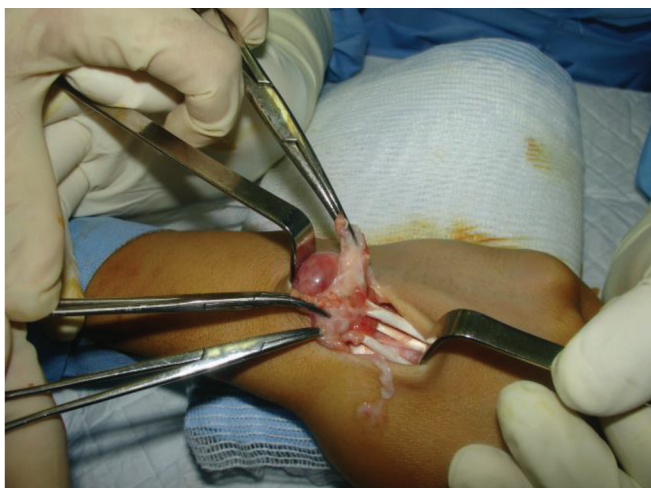


Figure 3a: Dorsal surface of the left wrist depicting nonhomogenous and berrylike mass, occupied all space of forth extensor compartment.

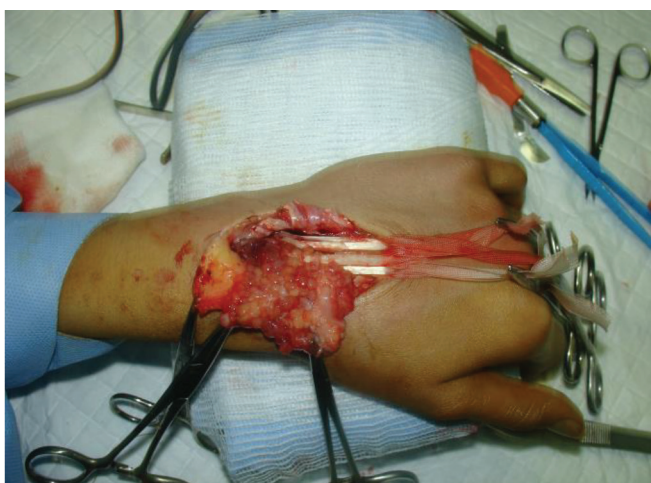

Figure 3b: Dorsal surface of the left wrist, extensor tendon was surrounded by mass.

One day after the operation the penrose drain had no output, so it was removed and the patient was discharged. Passive and active range of motions of wrist were normal but digital extension was restricted to 10 degrees, which was attributed to pain and oral NSAID was prescribed. Thumb extension was normal. Patient was visited a week later, there was no pain, no seroma but digital extension had not recovered completely. Passive range of motion was normal as before. Patient

was referred to a physiotherapist. Two weeks after operation, sutures were removed and the wound was clean with no seroma, drainage and inflammation. Digital extension was recovered to 25 degrees and she was under physiotherapy 3 sessions a week. Finally, one month after surgery, active range of motion became normal and plain x ray was normal, too **Figure 4**. Pathology report confirmed the diagnosis of non pigmented villonodular synovitis **Figure 5a, 5b**.

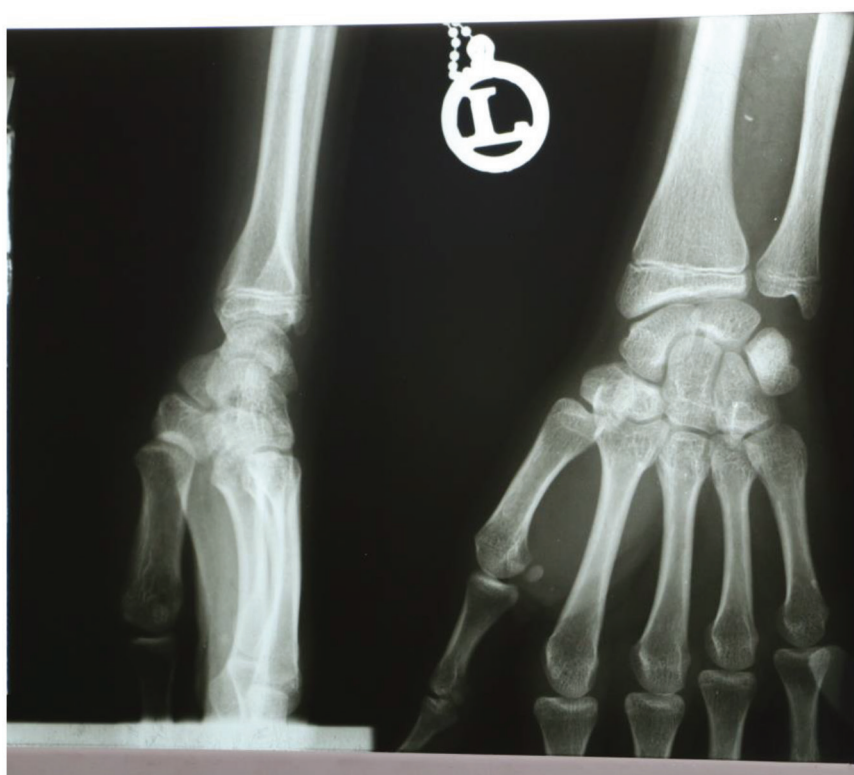


Figure 4: Post-operative anteroposterior and lateral radiographs of the wrist (Normal radiographic views).

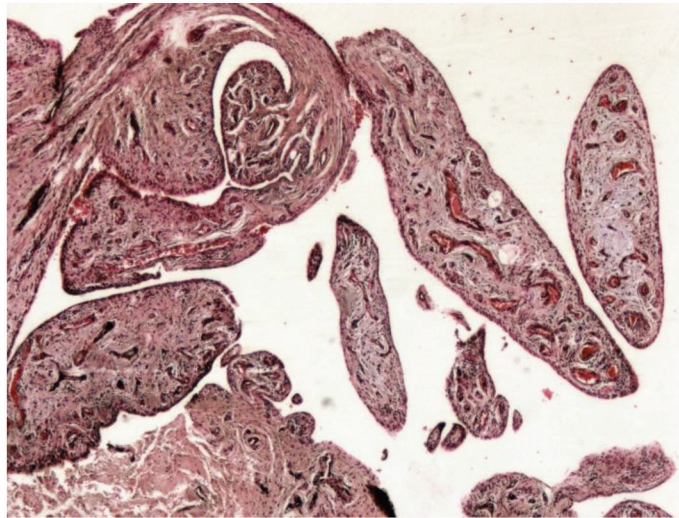


Figure 5a: Pigmented villonodular synovitis. Photomicrograph (H&E, ×40) demonstrates

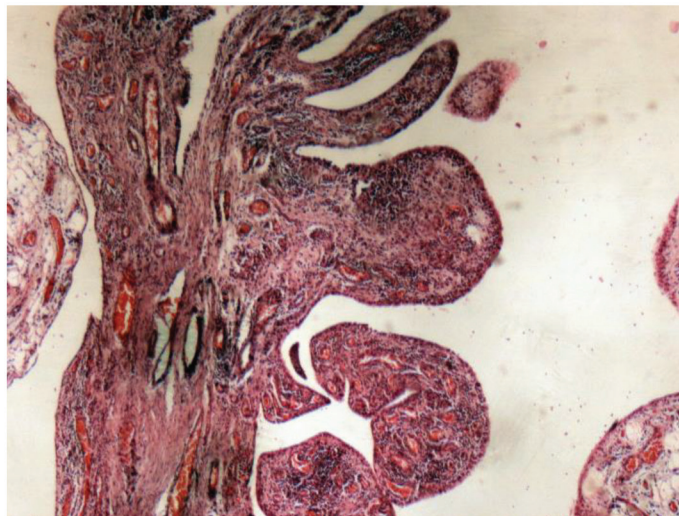


Figure 5b: H&E 100x. A section of some papillary projection of inflamed synovium. At this power proliferating synovial cell nuclei with fibroblasts, histiocytes and a few multinucleated giant cells are seen.

Discussion

Non pigmented villonodular synovitis is a proliferative disease with synovial involvement.⁴ In the past, it was confused with soft tissue sarcoma and was the cause of some amputations.^{8,9} It is a benign lesion with a high recurrence tendency.

Knee is the most common joint involved.^{6,10} In our case, we had a 13-year old girl with a two year history of wrist mass. She underwent operation with the diagnosis of synovial cyst but it was a mass with extensor tendon synovium origion. She had a temporary loss of complete digital extension.

Muscles were intact and active range of motion became normal with physiotherapy one month later. As Neubaur Philip et al.¹⁰ conclude in their article, we believe it is necessary to considere

villonodular synovitis in a child with chronic joint effusion as a differential diagnosis.

Conflict of Interest

There is no conflict of interest.

References

1. Tosun HB, Uludag A, Serbest S, et al: A rare case of extensive diffuse nonpigmented villonodular synovitis as a cause of total knee arthroplasty failure. *Int J Surg Case Rep* 2014; 5:419–423.
2. Burnett RA: A cause of erroneous diagnosis of pigmented villonodular synovitis. *J clin Path* 1976; 29:17-21.
3. Moynagh PD, Lettin AW: Pigmented Villonodular Synovitis of the Wrist Joint. *Proc R Soc Med* 1968;61:670-2.
4. Canale ST, Beaty JH: *Campbell's Operative Orthopaedics*. Twelfth Edition, Volume I, Philadelphia, PA: Elsevier; 2013
5. Dorwart RH, Genant HK, Johnston WH, et al: Pigmented villonodular synovitis of synovial joints: clinical, pathologic and radiologic features. *AJR Am J Roentgenol* 1984;143:877-85.
6. Schwartz GB, Coleman DA: Pigmented villonodular synovitis involving the wrist, a case report. *Iowa Orthop J* 1986;6:129-132.
7. Xie GP, Jiang N, Liang CX, et al: Pigmented Villonodular Synovitis: A Retrospective Multicenter Study of 237 Cases. *PLoS One* 2015;10:e0121451.
8. Schajowicz F, Blumenfeld I: Pigmented villonodular synovitis of the wrist with penetration into bone. *J Bone Joint Surg Br* 1968;50:312-3.
9. Byers PD, Cotton RE, Deacon OW, et al: The diagnosis and treatment of pigmented villonodular synovitis. *J Bone Joint Surg Br* 1968;50B:290-305.
- Neubauer P, Weber K, Miller NH, et al: Pigmented Villonodular Synovitis in Children: A Report of Six Cases and Review of the Literature. *Iowa Orthop J* 2007;27:90-4.