

A 20 Days Visual Follow Up on Herpes Zoster (Shingles): Diagnosis, Treatment and Clinical Outcome

Amir Hossein Aghdaee¹ , Shabnam Tehrani¹, Seyed Mahmoud Hashemi^{2*} 

1. Infectious Diseases and Tropical Medicine Research Center, Shahid Beheshti University of Medical Sciences, Tehran, Iran.
2. Department of Immunology, School of Medicine, Shahid Beheshti University of Medical Sciences, Tehran, Iran.

ABSTRACT

A 44-year-old man with a three-day history of pain in right axilla, subsequently accompanied by the appearance of vesiculopapular rashes on the right portion of his torso, attended a medical facility. The patient had neither reported any special skin contact in that area, nor fever and other symptoms. Upon examination, the examiner revealed the appearance of some other similar vesiculopapular rashes. These two affected sites were located in a linear arrangement, namely, the T7 dermatome. Considering the particular arrangement of rashes and form of manifestation, a clinical diagnosis of herpes zoster was made. The patient underwent empirical treatment of herpes zoster, including Virabex (valaciclovir) tablet 1g TDS, pregabalin capsule once nightly, and hydroxyzine hydrochloride tablet once every night (1, 2). The pain and itching resolved within one week after the prescription, and the rashes mostly disappeared within 20 days. Here, the daily states of rashes are presented to the audience.

ARTICLE INFO

Date Submitted: 15 December, 2023

Date Accepted: 30 December, 2023


KEYWORDS

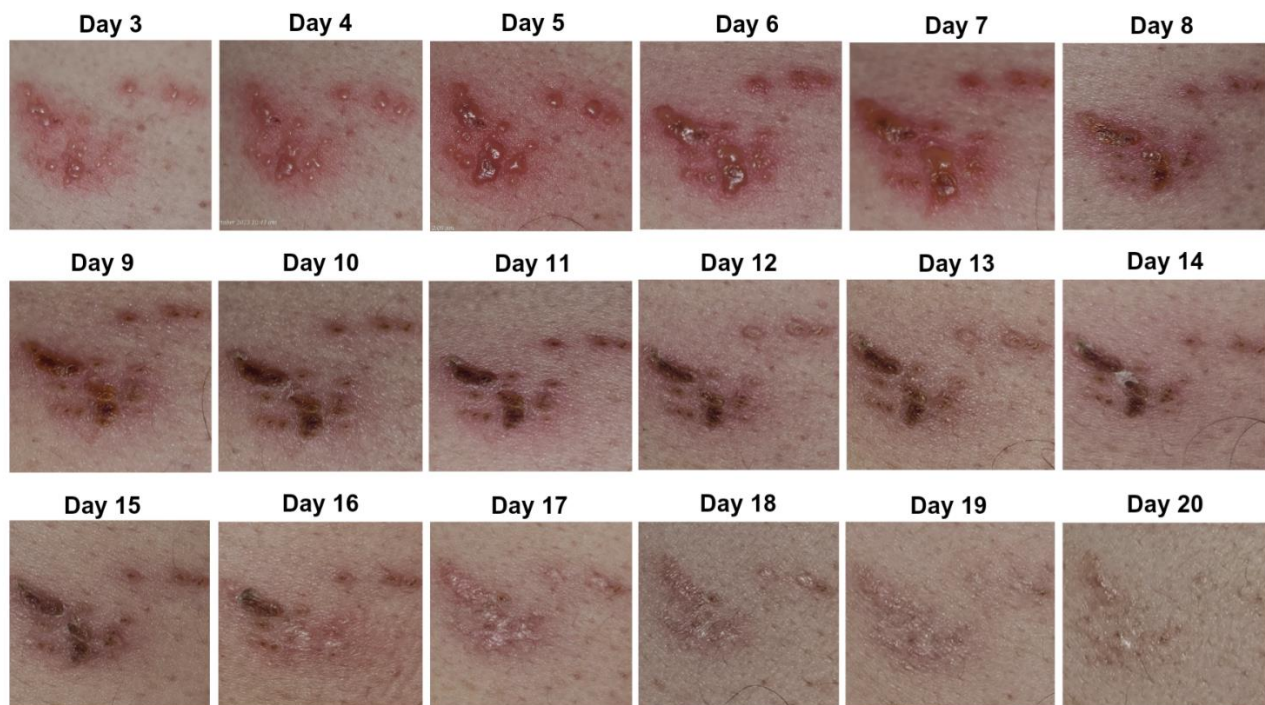
Pain Management; Herpes Zoster; Pregabalin; Valaciclovir; Dermatome; vesiculopapular

*CORRESPONDING AUTHOR

Seyed Mahmoud Hashemi

Email: smmhashemi@sbmu.ac.ir

 0000-0003-1389-5803



Please Cite This Paper As:

Aghdaee AH, Tehrani S, Hashemi SM. A 20 Days Visual Follow Up on Herpes Zoster (Shingles): Diagnosis, Treatment and Clinical Outcome. Sch Med Stud J. 2023;5:e44117.

Open Access Policy: This article is distributed under the terms of the Creative Commons Attribution-Noncommercial 4.0 International License (<https://creativecommons.org/licenses/by-nc/4.0/>), which permits unrestricted use, distribution, and reproduction in any medium, provided you give appropriate credit to the original author(s) and the source and is not used for commercial purposes.





ACKNOWLEDGEMENTS

We sincerely thank Seyed Sobhan Hashemi for his hard work in capturing daily images.

CONFLICT OF INTEREST

The author (s) declared no potential conflicts of interest.

FUNDING

No funding

REFERENCES

1. Rosamilia LL. Herpes Zoster Presentation, Management, and Prevention: A Modern Case-Based Review. *American Journal of Clinical Dermatology*. 2020;21(1):97-107.
2. Al-Ghazawi FM, Ramien ML, Brassard A, Shear NH and Beecker J. Management of Pain Associated with Selected Conditions in Dermatology. *American Journal of Clinical Dermatology*. 2016;17(5):463-74.

