

## Identification of the Unknown: a Case Report

Kumar-Pathak M<sup>1\*</sup>, Gupta M<sup>1</sup>

<sup>1</sup> Department of Forensic Medicine and Toxicology, Institute of Medical Sciences, Banaras Hindu University, Varanasi, India

---

### ARTICLE INFO

*Article Type:*  
Case Report

*Article History:*  
Received: 1 Oct 2015  
Revised: 15 Oct 2015  
Accepted: 22 Oct 2015

*Keywords:*  
Unknown Body  
Identification  
Depressed Comminuted  
Fracture  
Homicide

---

### ABSTRACT

**Background:** Identification is the determination of the individuality of a person based on certain physical characteristics. It is the process of exact fixation of personality. In partial or incomplete identification, certain facts are determined, such as; race, age, sex, stature and etc., while other characteristics are not known.

**Case Report:** Unknown skeleton came to the department of forensic medicine, Institute of Medical Sciences, Banaras Hindu University, and Varanasi in 2015 for the purpose of identification and to determine the cause of death. It was estimated to be a male of age 25-35 years with a depressed comminuted fracture along with two other antemortem fractures in the skull. So, based upon the type of skull fracture found, the most likely cause of death was opined to be coma as a result of head injury. Time since death was estimated to around 3-4 weeks based on the ambient temperature being  $40\pm 5^{\circ}\text{C}$ , entomology and semi-skeletonised condition of the body.

**Conclusion:** The case has been reported in view of the fact that an unknown body with a little history came to us mainly for the purpose of identification had eventually turned out to be a case of possible homicide. Hence, a thorough examination of each and every case is recommended.

Copyright©2016 Forensic Medicine and Toxicology Department. All rights reserved.

---

► *Implication for health policy/practice/research/medical education: Identification of the Unknown*

---

► *Please cite this paper as:* Kumar-Pathak M, Gupta M. *Identification of the Unknown: A Case Report. International Journal of Medical Toxicology and Forensic Medicine.* 2016; 6(2): 99-102.

---

### 1. Introduction:

Identification is the determination of the individuality of a person based on certain physical characteristics. It is the process of exact fixation of personality. In partial or incomplete identification, certain facts are

determined, such as; race, age, sex, stature, and etc., while other characteristics are not known. The identification of a dead body and proof of corpus delicti is important before a sentence is passed in murder trials, as unclaimed, decomposed bodies, or portion of dead bodies, or bones are sometimes produced to support false charges (1).

There are three levels of identification: a) Positive identification, where there can be no reasonable doubt as to the specific person represented; b) Presumptive identification, where details suggest possible or probable

---

*Corresponding author:* Kumar-Pathak M, MD. Associate Professor, Department of Forensic Medicine and Toxicology, Institute of Medical Sciences, Banaras Hindu University, Varanasi, India  
E-mail: mayanknbmc@gmail.com

identification, but without complete certainty; and c) Preclusive identification, when comparison of details indicates that identity is unlikely or impossible (2).

Unlike medical examiner's system, in Indian legal system the direction of any criminal investigation is decided by the police. Forensic expert, due to his training and experience, plays a crucial role in assisting the investigating agency to take a particular path, while investigating a case of suspicious death; and help them to arrive at a certain conclusion regarding the manner of death.

Also, in the early stages of death investigation his opinion may be crucial in initiating or aborting a homicide investigation-a decision which may have serious consequences; if wrong (3).

## 2. Case Report:

Unknown skeleton came to the department of forensic medicine, Institute of Medical Sciences, Banaras Hindu University, Varanasi on 15/5/2015. The information given by police was as mentioned below:

The body was found in the dense bushes besides the railway tracks accidentally. They didn't find any photo identity proof, but they were able to mention that a middle aged male addict was missing from a nearby local village since few months and they suspected that this body might be his.

The clothing in which body was wrapped included one full shirt, one half vest, one inner vest, one black trouser and one raksha (sacred thread on wrist) and one black thread. One small metallic plate and one plastic pouch which contained some greenish material were also recovered from the trouser (Figure 1). The body came to us for the purpose of identification and to determine the cause of death.

### Autopsy Examination

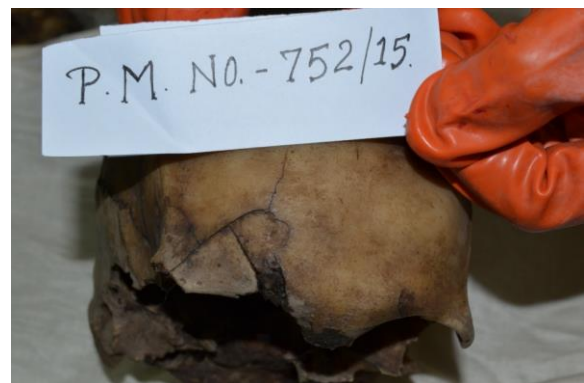
India is a tropical country and at our place i.e. Varanasi, Uttar Pradesh, India the temperature in the month of June varies between temperatures being  $40\pm 5^{\circ}\text{C}$ . The body was partially skeletonised with ligaments still holding the bones together. Foul odour was coming out from it which suggested the stage of advanced decomposition. There were mature maggots;



**Fig. 1.** Metallic plate and plastic pouch which contained some greenish material recovered from the trouser.



**Fig. 2.** Skull fracture of *depressed comminuted* type of size  $5\times 2$  cm on top of the head.



**Fig. 3.** Fracture of frontal bone on the right side.



**Fig. 4.** Fracture of long bones (radius, ulna & humerus).

**Table 1:** Exposures reported with psychiatric agents in 0-5 year-old group

Sl. No.	Finding	Age
1.	Xiphisternum was not found (i.e. not fused with the body)	<40 years
2.	Symphysis Pubis surface was granular with well-formed anterior and posterior margins	25-35 years
3.	All the segments of the body of Sternum were fused	>25 years
4.	Body of all sacral vertebra were fused	>25 years
<b>Calculation of the stature</b>		
5.	Stature (in cm) = Length of Femur (in cm) $\times$ 3.6 + 2.5cm	175.3cm

most of them were in flying stage. All these findings suggests the duration of death to be more than 3 weeks.

Sex is estimated to be 'Male' with sciatic notch index 112, corporo-basal index 45, prominent, Glabella and Supra-orbital ridges.

Age was estimated to be between 25-35 years and stature was found to be 175.3 cm on the basis of the findings mentioned as follows in table 1.

A skull fracture of depressed comminute type of size 5 $\times$ 2 cm was found on top of the head on right parietal area 0.5 cm from sagittal suture and 13 cm from temporo-parietal suture (Figure 2). Also, sutural fracture of anterior 1/3<sup>rd</sup> of sagittal suture and upper half of both sides of the coronal suture was present. Another fracture of frontal bone on the right side 2 cm away and outer to the midline, touching to the right supra-orbital area was also present (Figure 3). Although a visible callus and the condition of the soft tissue around the fracture was not appreciated on naked eye examination due to advanced decomposition of the body, there was staining of the fractured surfaces due to the effusion of blood which indicate that these skull fractures are ante-mortem/peri-mortem in nature.

Fracture of left radius and ulna 6 cm below the elbow joint, fracture of humerus 7 cm above elbow joint and fracture of right tibia and fibula 12 cm above the ankle joint were also found (Figure 4). The fractured surface was devoid of any staining due to blood

suggesting that they were post-mortem fractures.

### 3. Discussion:

Stage of decomposition and presence of maggots in this case indicated the Post Mortem Interval (PMI) to be more than 3 weeks. A study quotes that the beginning of decay stage (PMI 1-3 weeks) is marked by release of gases, corpse deflates and strong odour is present. In the later part of this stage the colliquative putrefaction of organs begins and the odour of decay becomes strong. All stages of insects are seen. The dry stage is the final stage of decomposition was only dry skin, cartilage and Bones are found with PMI around one month. Empty fly puparia were found scattered under and around the corpses (4).

Depressed comminute (signature fracture) is caused by a hard, moderately heavy to heavy blunt weapon with small striking surface and is mostly homicidal. Presence of comminute or depressed comminute fracture indicates the application of a great amount of force as compared to a fissure fracture. The greater the force used, the greater is the force transmitted to the underlying brain causing damage (5). Blunt and sharp weapons were commonly used as reported by Mohanty *et al* (6), Mittal *et al* (7), Gupta *et al* (8), Aggarwal *et al* (9), and Dikshit *et al* (10), Pal *et al* (11), found the use of blunt weapons in 48.3% cases with the head and face as the primary targets. Saurabh Chattopadhyay and Chandrabhal Tripathi from their study on skull fractures concluded that skull fractures to be an important

indicator of severity of trauma in attacks to the head. Multiple bone fractures comminute fractures and base fracture may be considered as high risk factors in attempted homicide cases (12).

In the study conducted by Bruce P Wheatley, he empirically tested and quantified some of the previously recognized features of fracture patterns used in the determination of the chronological time interval of perimortem or post mortem trauma. While the attributes of the fracture patterns used in this study were found to be reliable at differentiating peri-mortem fractures from post mortem fractures at the statistical level, they were unreliable at differentiating a perimortem fracture from a post mortem fracture on a bone for forensic investigation. He suggested that a peri-mortem determination should therefore be made with caution and it should include many of the other important features not tested in this study to make such a determination such as, differential staining or colour differences between the fracture surface and the outer cortical surface, hinging, hematoma stains and greenstick fractures (13). All of the skull fractures in this case are ante mortem injuries. Other fractures were post mortem on nature.

So, based upon the type of skull fracture found, the most likely cause of death was opined to be coma as a result of head injury. Time since death was estimated to around 3-4 weeks based on entomology and stage of the skeletonisation of the body.

#### 4. Conclusion:

The case has been reported in view of the fact that an unknown body with a little history came to us mainly for the purpose of identification had eventually turned out to be a case of *possible homicide*, which therefore will change the course of further investigation to be done by the police.

Hence, a thorough examination of each and every case, even it seems very simple and

straightforward, is recommended to ensure that the justice is served to everyone.

#### 5. References:

1. Narayan-Reddy K. The essential of forensic medicine and toxicology, 33rd edition, K. Suguna Devi. 2012;57.
2. Lee RS. The Testimony of Teeth. Charles C Thomas. Springfield, Illinois. 1988;7.
3. Saukko P, Knight B. Knight's Forensic Pathology, 3rd edition. London: Edward Arnold Publishers Ltd. 2004;236.
4. Singh H, Venketasan M, Aggarwal OP, Raj S. Use of maggots for the estimation of time since death. J Punjab Acad Forensic Med Toxicol. 2014;14(1):22-6.
5. Vij K. Textbook of forensic medicine and toxicology: principles and practice, 6th edition. Reed Elsevier India Private Limited. 2014;40-50.
6. Mohanty MK, Mohanty S, Acharya S. Circumstances of crime in homicidal deaths. Med Sci Law. 2004;44(2):160-4.
7. Mittal S, Chanana A, Rai H, Dalal JS. Medicolegal study of mechanical injuries in culpable homicides (excluding deaths due to rash and negligent act). Journal of Indian Academy of Forensic Medicine. 2005;27(4):226-30.
8. Gupta A, Rani M, Mittal AK, Dikshit PC. A study of homicidal deaths in Delhi. Med Sci Law. 2004;44(2):127-32.
9. Aggarwal N, Bansal A, Agarwal B. Trends of homicides in the capital city of India. Medicolegal Update. 2004;4(2):41-5.
10. Dikshit P, Dogra T, Chandra J. Comprehensive study of homicides in South Delhi. Med Sci Law. 1986;26(3):230-4.
11. Pal V, Paliwal P, Yadav D. Profile of regional injuries and weapons used in homicidal victims in Harayana. J For Med and Toxicol. 1994;11(2):42-4.
12. Chattopadhyay S, Tripathi Ch. Skull fracture and haemorrhage pattern among fatal and nonfatal head injury assault victims – a critical analysis. J Inj Violence Res. 2010;2(2):99-103.
13. Bruce P. Perimortem or postmortem bone fractures? An experimental study of fracture patterns in deer femora. J Forensic Sci. 2008;53(1):69-72.