



Case Report

Neurotoxic Consequences of Bromadiolone Exposure: A Case Report of Toxic Encephalopathy

Fadhly Azis^{1*}, Prasillia Ramadhani¹, Ahmad Yudianto¹, Yudha Erik Prabowo², Seno Fauzi Alyanugraha³

1. Department of Forensic Medicine and Medicolegal Study, Universitas Airlangga, Surabaya, Indonesia.

2. Faculty of Medicine, Universitas Kristen Petra Surabaya, Surabaya, Indonesia.

3. Faculty of Dental Medicine, Universitas Muhammadiyah Surabaya, Surabaya, Indonesia.

Citation: Azis F, Ramadhani P, Yudianto A, Prabowo YE, Alyanugraha SF. Neurotoxic Consequences of Bromadiolone Exposure: A Case Report of Toxic Encephalopathy. *International Journal of Medical Toxicology and Forensic Medicine*. 2025; 15(3):E48995.

<https://doi.org/10.22037/ijmtfm.v15i03.48995>

Article info:

Received: 05 July 2025

First Revision: 16 July 2025

Accepted: 29 July 2025

Published: 23 Sep 2025

Keywords:

Neurotoxin, Bromadiolone exposure, Toxic encephalopathy, Forensic medicine

ABSTRACT

Background: Rat poisoning is often used as a method of murder in Indonesia.

Case Presentation: In this case, a woman died from bromadiolone intoxication caused by her ex-husband. Bromadiolone is an anticoagulant poison that works by inhibiting the action of vitamin K, causing bleeding and damage to central nervous cells as it reduces the carboxylase in the brain, causing lowered sulfatide synthetase, which is important in forming myelin sheaths.

Conclusion: Triad of asphyxia was found in external examination, and the widening of vessels as a sign of toxic encephalopathy was found in the examination. Bromadiolone was found in the remains of melon juice drunk by the victims.

* Corresponding Author:

Fadhly Azis, MD

Address: Department of Forensic Medicine and Medicolegal Study, Universitas Airlangga, Surabaya, Indonesia.

E-mail: dr.fadly13@gmail.com



Copyright © 2025 The Author(s).

This is an open access article distributed under the terms of the Creative Commons Attribution License (CC-BY-NC: <https://creativecommons.org/licenses/by-nc/4.0/legalcode.en>), which permits use, distribution, and reproduction in any medium, provided the original work is properly cited and is not used for commercial purposes.

Introduction

Rodenticide is a chemical agent specifically designed to eliminate rodents, particularly those commonly found in residential environments, such as mice and rats. These substances often contain potent anticoagulant or neurotoxic compounds that disrupt the biological functions of targeted pests, leading to their death [1]. Despite being formulated for pest control, many rodenticides are widely available and can be purchased over the counter, often without the need for professional oversight. This easy accessibility raises significant concerns regarding safety and misuse. In various settings, especially in low-regulation environments, rodenticides have been implicated not only in accidental poisonings—particularly among children and domestic animals—but also in intentional cases of self-harm and even criminal acts. The intentional use of rodenticide as a method of murder, although relatively rare, has been documented in several forensic cases and poses a diagnostic challenge due to the delayed and often nonspecific presentation of symptoms [2]. These cases highlight the importance of public awareness, tighter regulation, and clinical vigilance in identifying rodenticide poisoning, especially when it manifests with atypical or severe systemic effects [3]. However, it is easy enough to find. Not infrequently, rodenticide is used as one of the murder methods.

Cases of murder involving the use of poison have occurred numerous times in Indonesia, often utilizing everyday consumables such as food or beverages as the delivery medium. One of the most prominent and widely publicized examples is the cyanide coffee case that captured national and international attention in 2016, shedding light on the lethal potential of chemical agents in premeditated homicide [4]. Homicidal poisoning is relatively uncommon in forensic casework. However, it has been consistently reported in case series and review studies, with the distribution

of toxic agents varying across regions and over time. Historically, substances such as arsenic and cyanide were frequently employed. However, more recent epidemiological surveys indicate a shift toward the use of pesticides, pharmaceutical agents, and—in some jurisdictions—rodenticides, particularly in low- and middle-income countries where such compounds remain widely accessible [6]. Retrospective autopsy analyses have highlighted the persistent contribution of pesticide and rodenticide ingestion to fatal poisoning cases, with the choice of agent influenced by high lethality at low doses, ease of procurement, and the ability to mask administration in food or beverages, thereby delaying clinical suspicion [8, 9]. These findings reinforce the importance of public education regarding the hazards of common toxic substances, the implementation of stricter regulations on hazardous chemical distribution, and the advancement of forensic analytical capabilities to enhance the detection and prosecution of poisoning-related homicides [10].

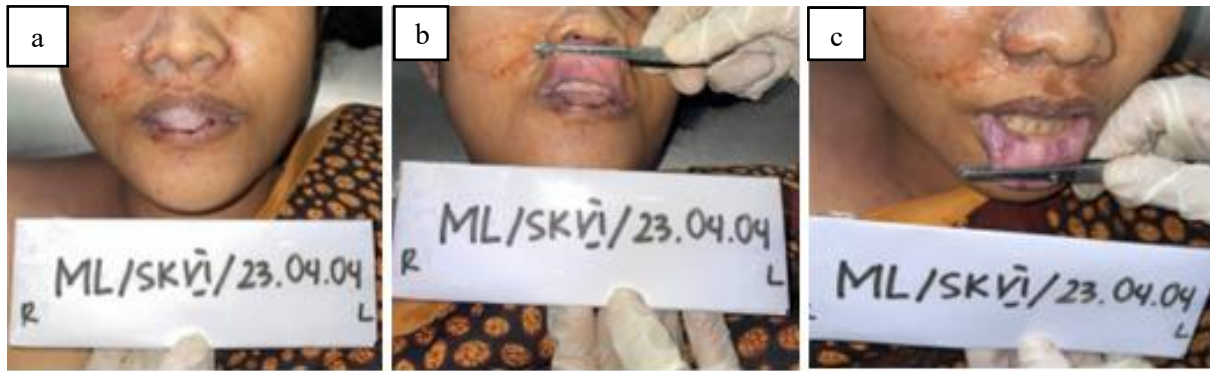
Case Report

On April 16, 2023, at 10:00 PM WIB, a woman arrived at the Emergency Room with complaints of dizziness, nausea, and vomiting that had started 30 minutes prior to her admission. These symptoms followed her consumption of martabak and melon juice provided by her ex-husband. Two hours later, the victim experienced seizures and lost consciousness. Medical personnel spent half an hour performing resuscitation, including gastric lavage, but the woman unfortunately died at 12:30 AM WIB on April 17, 2023. Both external and internal examinations were conducted on the same day at 4:35 PM WIB due to the order for post mortem et repertum: B/121/IV/2023/Reskrim.

The external examination revealed livor mortis on the neck, back, and buttocks, along with rigor mortis present throughout the body. Both eyes exhibited widened blood vessels (Figure 1). The nose appeared foamy, with clear fluid and redness. Abrasions were

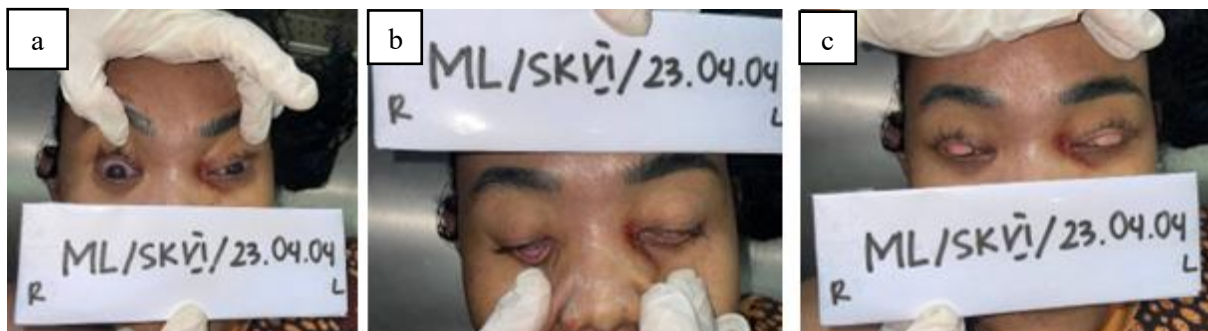

Figure 1. (a) photo of the hard membrane of the eyeball, (b) photo of the mucous membrane of the lower eyelid, (c) photo of the mucous membrane of the upper eyelid.



International Journal of
Medical Toxicology & Forensic Medicine

Figure 2. (a) photo of lips, (b) photo of upper lip mucous membrane, (c) photo of lower lip mucous membrane.



International Journal of
Medical Toxicology & Forensic Medicine

Figure 3. (a) Photo of Teeth, (b) photo of fingertips and fingernails, (c) photo of fingertips and toenails.

noted on the mucous membranes of the lower lips, and the membranes, lips, and gums exhibited a bluish tint (Figure 2).

On the second right and left incisors, there were diamond-shaped tooth ornaments. The tips of the fingers and the fourth nail appeared blue (Figure 3).

An internal examination revealed fine foam in the respiratory tract. Both lungs appeared reddish, and lung slices displayed reddish-white foam (Figure 4).

The heart appears reddish and is covered with fatty tissue. The stomach's surface also appears reddish, along with enlarged blood vessels. The gastric contents are fluid, white, smooth, and have a foul odor (Figure 5).

In the brain, the surface looks like widening blood vessels. The slice shows a bleeding spot (Figure 6).

A vaginal swab was obtained, which contained sperm. The toxicology examination of the stomach



International Journal of
Medical Toxicology & Forensic Medicine

Figure 4. (a) Trachea, (b) lung, (c) lung slice.

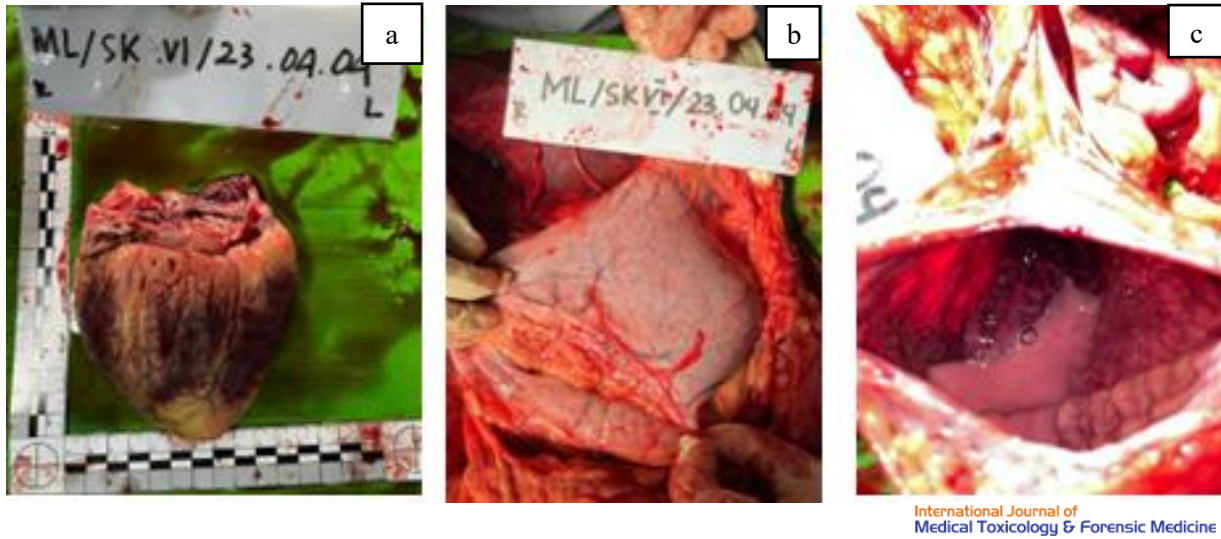


Figure 5. (a) Heart, (b) Surface of the stomach, (c) Contents of the stomach.

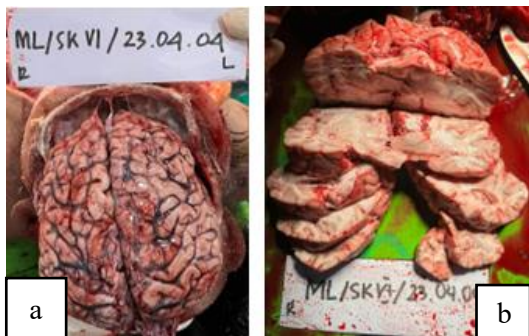

Figure 6. (a) Brain Surface. (b) Brain Section.

contents, blood, and bile did not reveal any toxic substances due to the sample size being insufficient for the required number of tests. However, the toxicology analysis of the melon juice did detect the presence of rodenticide, specifically bromadiolone, at a concentration of 2.62 g/kg.

Histopathological findings indicate signs of asphyxia, characterized by the widening of blood

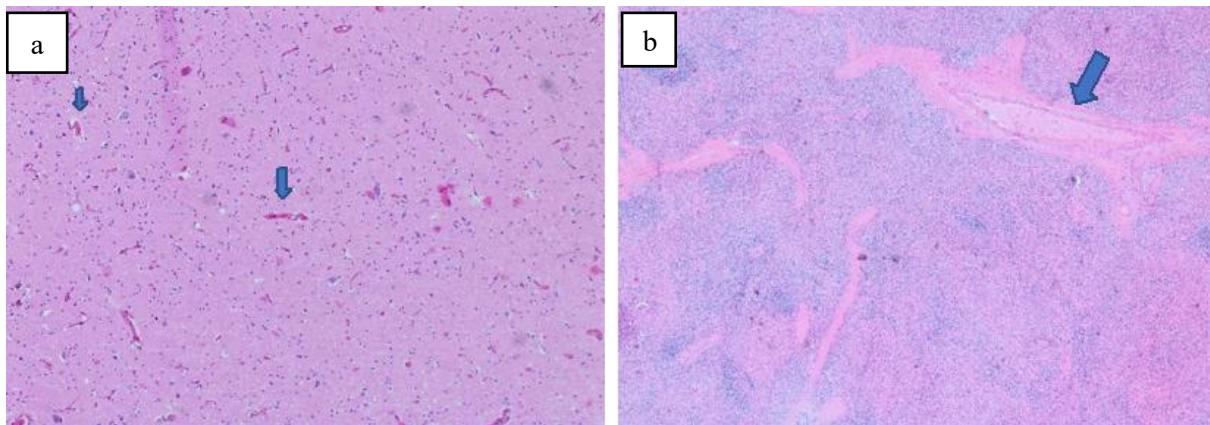


Figure 7. (a) Brain Histopathology, 100x magnification. (b) Spleen Histopathology, 40x magnification.

vessels in the brain, spleen, liver, and kidneys, along with cellular infiltration and inflammation (Figures 7 and 8).

Discussion

Poisoning or intoxication can be defined as the interaction between foreign substances, known as toxins, and the biological system, which results in damage to the organism [12]. In medicine, the term "pharmacokinetics" is used, while in the context of poisoning, we use "toxicokinetics". This field examines the processes of absorption, distribution, metabolism, and excretion of toxins. These processes determine the amount of toxins that interact with the biological system and produce toxic effects (Figure 9). Toxicodynamics is the science that studies the interaction between poisons and tissues. These interactions can lead to functional and metabolic changes that are characteristic of clinical poisoning and are crucial for diagnosis and management [13].

Bromadiolone is an anticoagulant poison, often

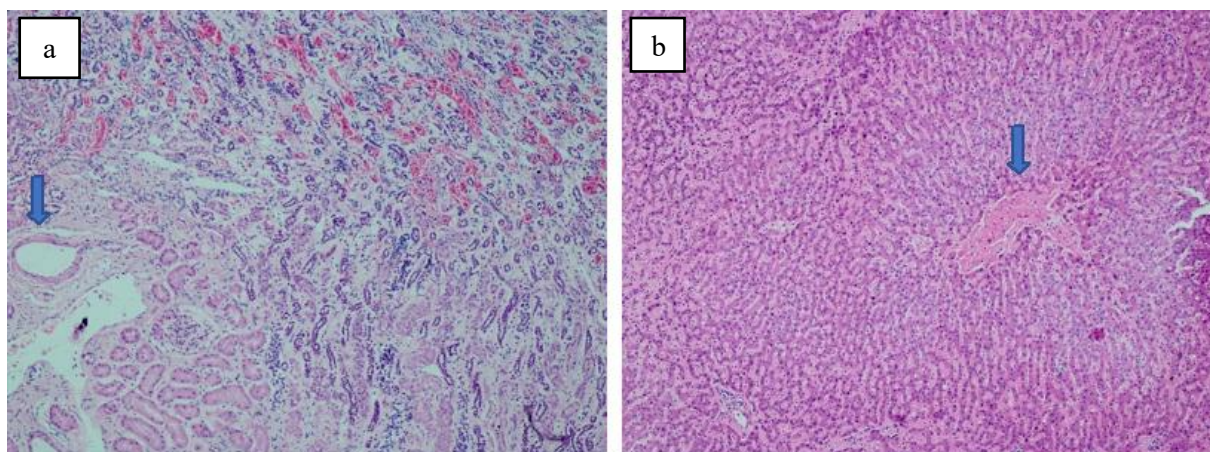


Figure 8. (a) Kidney Histopathology, 100x magnification. (b) Liver Histopathology, 100x magnification.

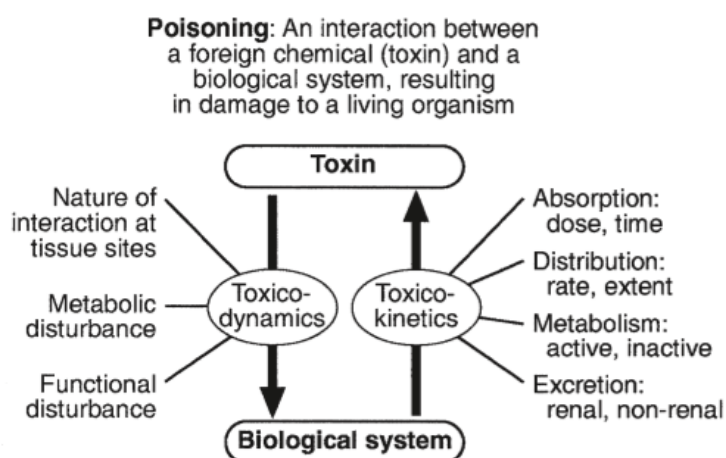


Figure 9. Factors that influence intoxication.

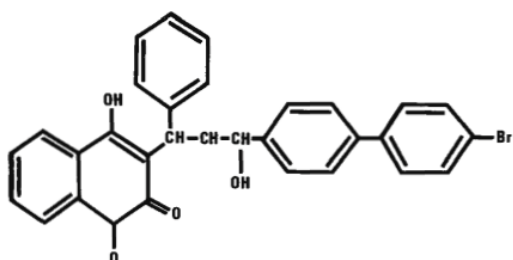


Figure 10. Chain Compound Bromadiolone.

referred to as a super-warfarin, and acts as a vitamin K antagonist. It is a compound derived from the hydroxycoumarin family and is commonly used as a rodenticide [14, 15]. This potent poison affects all types of mammals, with a molecular formula of $C_{30}H_{23}BrO_4$ (Figure 10). Bromadiolone functions by inhibiting the blood clotting process and the synthesis of prothrombin, while also damaging the permeability of blood vessels [16, 17]. The active substance, bromadiolone, leads to various effects such as anorexia, decreased activity and movement, and notable physical symptoms, including red and watery eyes, which may

occur after consumption and can ultimately lead to death [18]. The LD50 (lethal dose for 50% of the population) of this compound ranges from 0.16 to 0.93 mg/kg [19].

This chemical compound reduces the activity of coagulation factors II, VII, IX, and X, which depend on vitamin K, by inhibiting the enzyme vitamin K epoxide reductase. This mechanism is significant in the context of anticoagulants [20]. Generally, symptoms of bromadiolone intoxication include bleeding; however, cases of encephalopathy without bleeding may also occur [21].

Clinical manifestation is the bleeding of tissues and organs. Vitamin K-dependent functions not only in coagulation but also in the Central Nervous System (CNS), which plays an important role in neurons and neuroglia [20]. Vitamin K is a cofactor for the γ -glutamyl carboxylase (GGC) enzyme, which plays an important role in the physiology of the nervous and glial systems. In the CNS, vitamin K deficiency can decrease the carboxylase protein in the brain, which causes decreased sulfatide synthesis. Sulfatide

synthesis plays an important role in the formation of the myelin sheath. Thus, the effect of bromadiolone on the vitamin K cycle may be one of the mechanisms underlying the pathophysiology of toxic encephalopathy [21]. In animal studies, it is shown that toxic super-warfarin affects CNS nerve cells, activating glial inflammation, which causes nerve damage [19]. Glial activation can initiate an inflammatory response cascade and stimulate glutamate release, thereby increasing extracellular glutamate. Increased extracellular glutamate's excitotoxic effect on aquaporins (AQPs) and sodium-potassium pumps, which promote the entry of water molecules into astrocytes and neurons, ultimately causes cytotoxic edema [21].

Asphyxia is a serious condition characterized by a disturbance in the exchange of air during breathing, which leads to decreased oxygen levels in the blood (hypoxia) and an increase in carbon dioxide levels (hypercapnia) [22]. The etiology of asphyxia can be categorized into three main types: natural asphyxia, mechanical trauma (also referred to as mechanical asphyxia), and poisoning from substances that depress the respiratory center [23]

Classic signs of asphyxia: [22]

1. Petechial hemorrhages occur as a consequence of improved venous pressures in I, causing overdistension and rupture of peripheral venous walls, especially in the peripheral tissues.
2. Cyanosis occurs as a consequence of the improvement of the amount of absolutely reduced Hb (Hb that is not bound with O₂).
3. Injected/Congestion, blocked vessels causing an accumulation of blood in the organ, causing disturbance in the circulation in the blood vessels, especially in widening vessels, especially in loose areas.

Murder case with poisoning, quite a lot carried out in Indonesia, in this case, an ex-husband who poisoned his ex-wife using mouse poison with bromadiolone. Bromadiolone itself is a super-warfarin that works by inhibiting the work of vitamin K, which can cause bleeding. In addition to bleeding, a lack of vitamin K can result in damage to the centers of nerve cells, causing toxic encephalopathy, as occurs in cases [15]

Toxic encephalopathy in this case exhibits a triad of asphyxia upon examination: widened blood vessels, blood present in the eyes and internal organs, blue discoloration of the fingertips and nails, and bleeding

spots on the sclera and internal organs [24]. Additionally, histopathological findings support this diagnosis, showing enlarged blood vessels in the spleen, liver, kidneys, and, most significantly, in the brain. Bromadiolone was not detected in the blood, stomach, or urine samples, likely because resuscitation was performed while the patient was still alive, which included gastric lavage and catheterization [25–27]. However, bromadiolone was found in the leftover melon juice consumed by the victim, which should not have contained this substance. Bromadiolone is a potent toxin, and even a small amount present in food or drinks can cause severe harm to an organism's life.

Conclusion

Based on the description provided, this is a planned murder case where the cause of death was rodenticide (bromadiolone) poisoning, leading to damage to the brain. As a result, the corpse was found in a limp state. The estimated time of death is between 10 and 18 hours prior to the examination, specifically between April 16, 2023, at 10:35 PM WIB and April 17, 2023, at 6:35 AM WIB.

Suggestion

Under consideration is the need for direct forensic specialist expertise in crime scene investigation or reconstruction to ensure consistency between findings from field inspections and laboratory analysis.

Conflicts of Interest

The authors report there are no competing interests to declare.

Founding

None.

References

- [1] Bullock J, Lynch A. Rodenticide Toxicity. Textbook of Small Animal Emergency Medicine [Internet]. 2024 June 22 [cited 2025 August 10];2:841–5. [\[Link\]](#)
- [2] Vandembroucke V, Bousquet-Melou A, De Backer P, Croubels S. Pharmacokinetics of eight anticoagulant rodenticides in mice after single oral administration. *J Vet Pharmacol Ther.* 2008 Oct 30;31(5):437–45. [\[DOI: 10.1111/j.1365-2885.2008.00979.x\]](#)
- [3] Silva C D', Krishna B. Rodenticide Poisoning.

- Indian Journal of Critical Care Medicine. 2019. [DOI: 10.5005/jp-journals-10071-23318]
- [4] Mustafa M, Laely NH, Densiana F, Anggreani E, Pitra E. Netflix's Representation in the Case of Cyanide Coffee in the film 'Ice Cold: Murder, Coffee, and Jessica Wongso: Critical Discourse Analysis Fairclough. ELS Journal on Interdisciplinary Studies in Humanities. 2024;7(4):516–31. [DOI: 10.34050/elsjish.v7i4.41834]
- [5] Isnaeni B. The role of forensic autopsy in pursuit of material truth in optical evidence for negative legal proof in the cyanide coffee murder case. Sinergi international journal of law. 2024;2(1):61–71. [DOI: 10.61194/law.v2i1.116]
- [6] Sikary AK. Homicidal poisoning in India: A short review. J Forensic Leg Med. 2019;61:13–6. [DOI: 10.1016/j.jflm.2018.10.003]
- [7] Finnberg A, Junuzovic M, Dragovic L, Ortiz-Reyes R, Hamel M, Davis J, Eriksson A. Homicide by Poisoning. American Journal of Forensic Medicine & Pathology. 2013;34(1):38–42. [DOI: 10.1097/PAF.0b013e31823d2977]
- [8] Gürger M, Vicdanli NH, Türkoğlu A, Börk T, Göçük V, Göktekin MÇ, Ateşçelik M, Gül E. Fatal Poisonings: Autopsy-Based Study. Bezmialem Science. 2023;11(1):79–84. [DOI: 10.14235/bas.galenos.94840]
- [9] Lihua L, Yuning W, Henghui H, Xiang L, Min J, Zehao L, Lianjie L, Qian L. Retrospective analysis of 217 fatal intoxication autopsy cases from 2009 to 2021: temporal trends in fatal intoxication at Tongji center for medicolegal expertise, Hubei, China. Front Public Health. 2023;11. [DOI: 10.3389/fpubh.2023.1137649]
- [10] Eddleston M. Poisoning by pesticides. Medicine. 2020 Mar;48(3):214–7. [DOI: 10.1016/j.mpmed.2019.12.019]
- [11] D'Silva C. Rodenticide Poisoning. Indian Journal of Critical Care Medicine. 2019;23(S4):0–0. [DOI: 10.5005/jp-journals-10071-23318]
- [12] Dear JW. Poisoning. In: Clinical Biochemistry: Metabolic and Clinical Aspects. Elsevier; 2014. p. 787–807.
- [13] Dear JW. Clinical Biochemistry: Metabolic and Clinical Aspects. Third. London: Elsevier; 2014. [Link]
- [14] Feinstein DL, Akpa BS, Ayee MA, Boullerne AI, Braun D, Brodsky S V., Gidalevitz D, Hauck Z, Kalinin S, Kowal K, Kuzmenko I, Lis K, Marangoni N, Martynowycz MW, Rubinstein I, van Breemen R, Ware K, Weinberg G. The emerging threat of super-warfarins: history, detection, mechanisms, and countermeasures. Ann N Y Acad Sci. 2016 Jun 31;1374(1):111–22. [DOI: 10.1111/nyas.13085]
- [15] Kodali S, Rajendran T, Richard IN, Boyapati L, Wong ECC, Avezbakiyev B. Super-warfarin Exposure: An Important Uncommon Cause of Painless Bleeding. J Hematol. 2019;8(4):155–9. [DOI: 10.14740/jh538]
- [16] Revathi K, Yogananda M. Effect of bromadiolone on haematology, liver and kidney in Mus musculus. J Environ Biol. 2006;27(1):135–40. [Link]
- [17] Wang H, Deng L, Sun B, Xing C, Mao H, Wu B. Bromadiolone may cause severe acute kidney injury through severe disorder of coagulation: a case report. BMC Nephrol. 2024;25(1):303. [DOI: 10.1186/s12882-024-03746-0]
- [18] Lasmawan G dwi, Widiyanto T, Utomo B. Pengaruh Berbagai Jenis Kandungan Zat Aktif Dalam Racun Tikus Terhadap Jumlah Dan Waktu Kematian Tikus Mencit Putih (Mus Musculus Strain Albino) Tahun 2019. Poltekkes Semarang. 2019;2–3.
- [19] Kalinin S, Marangoni N, Kowal K. The long lasting rodenticide brodifacoum induces neuropathology in adult male rats. Oxford University Press. 2017;1–35. [DOI: 10.1093/toxsci/kfx134]
- [20] Wang M, Yang Y, Hou Y, Ma W, Jia R, Chen J. Effects of bromadiolone poisoning on the central nervous system. Neuropsychiatr Dis Treat. 2017;13:2297–300. [DOI: 10.2147/NDT.S142375]
- [21] Li Q, Yu W, Qu Y, Wang JQ, Mao N, Kang H. Acute toxic encephalopathy following bromadiolone intoxication: a case report. BMC Neurol. 2021;21(1):2–5. [DOI: 10.1186/s12883-020-02034-2]
- [22] Sauko P, Knight B. Forensic Pathology. Fourth Ed. CRC Press; 2015. 461–73 p.
- [23] Yudianto A. Ilmu Kedokteran Forensik. Surabaya: Scopindo; 2020. 20 p. [Link]
- [24] Osterhoudt KC, Penning TM. Drug toxicity and poisoning. Goodman & Gilman's the pharmacological basis of therapeutics. 2011;12:73–87. [Link]

- [25] Zhou Y, Tong JL, Peng AH, Xu SY. Comparison of drug concentrations in blood and gastric lavage fluid before and after gastric lavage: A case report. *World J Clin Cases*. 2023;11(31):7680–3. [DOI: [10.12998/wjcc.v11.i31.7680](https://doi.org/10.12998/wjcc.v11.i31.7680)]
- [26] Sastre C, Bartoli C, Baillif-Couniou V, Leonetti G, Pelissier-Alicot AL. Post Mortem Redistribution of Drugs: Current State of Knowledge. *Curr Pharm Des*. 2018;23(36). [DOI: [10.2174/1381612823666170622111739](https://doi.org/10.2174/1381612823666170622111739)]
- [27] Menéndez-Quintanal LM, Matey JM, del Fresno González V, Bravo Serrano B, Hernández-Díaz FJ, Zapata F, Montalvo G, García-Ruiz C. The State of the Art in Post-Mortem Redistribution and Stability of New Psychoactive Substances in Fatal Cases: A Review of the Literature. *Psychoactives*. 2024;3(4):525–6. [DOI: [10.3390/psychoactives3040033](https://doi.org/10.3390/psychoactives3040033)]