

## Case Reports

# From Color to Clue, Unraveling the Forensic Significance of Pink Teeth in Postmortem Analysis



Andi Nur Sakina Tri Meilana<sup>1</sup>, Mohammad Ardhan Syaifuddin<sup>2</sup> , Antonius Winoto Suhartono<sup>3</sup> , Michael Ganda<sup>2</sup>, Elza Ibrahim Auerkari<sup>3\*</sup>

1. Department of Oral Biology, Faculty of Dentistry, University of Indonesia, Jakarta, Indonesia.

2. Department of Forensic Medicine and Medicolegal Studies, Faculty of Medicine, University of Indonesia, Jakarta, Indonesia.

3. Department of Oral Biology, Faculty of Dentistry, University of Indonesia, Jakarta, Indonesia.



**Citation** Sakina Tri Meilana AN, Ardhan Syaifuddin M, Winoto Suhartono A, Ganda M, Auerkari EI. From Color to Clue, Unraveling the Forensic Significance of Pink Teeth in Postmortem Analysis. *International Journal of Medical Toxicology and Forensic Medicine*. 2025; 15(2):E47419. <https://doi.org/10.32598/ijmtfm.v15i2.47419>

<https://doi.org/10.32598/ijmtfm.v15i2.47419>

### Article info:

**Received:** 08 Jul 2024

**First Revision:** 18 Dec 2024

**Accepted:** 07 May 2025

**Published:** 08 Jun 2025

### Keywords:

Pink teeth phenomenon (PTP), Postmortem interval (PMI), Decomposition, Forensic odontology, Forensic medicine

## ABSTRACT

**Background:** The postmortem pink teeth phenomenon (PTP) is a notable change in tooth color, resulting in a pinkish hue after death. Observed in various forensic contexts, including drowning, poisoning and physical trauma, the correlation between PTP and specific causes of death has remained ambiguous.

**Case Presentation:** This study discusses two cases involving cadavers exhibiting the PTP, where we conducted an analysis of pink teeth alongside other findings concerning the postmortem interval.

**Conclusion:** A comprehensive analysis of PTP requires consideration of various forensic elements. The phenomenon is closely associated with decomposition processes and is often observed in water immersion cases. A multidisciplinary approach involving forensic medicine and odontology is essential for understanding the physiological changes after death and assessing the potential significance of PTP as a postmortem indicator. By integrating these diverse aspects, forensic investigators can gain deeper insights into the circumstances surrounding death. Although PTP is not pathognomonic for any specific cause of death, it serves as a valuable indicator that can assist in forensic investigations. Further studies are necessary to clarify its implications in various forensic contexts and enhance its application in medico-legal assessments.

### \* Corresponding Author:

**Elza Ibrahim Auerkari, Professor.**

**Address:** Department of Oral Biology, Faculty of Dentistry, University of Indonesia, Jakarta, Indonesia.

**Tel:** +62 (812) 84392420

**E-mail:** [elza.ibrahim@ui.ac.id](mailto:elza.ibrahim@ui.ac.id)



Copyright © 2025 The Author(s);  
This is an open access article distributed under the terms of the Creative Commons Attribution License (CC-BY-NC: <https://creativecommons.org/licenses/by-nc/4.0/legalcode.en>), which permits use, distribution, and reproduction in any medium, provided the original work is properly cited and is not used for commercial purposes.

## Introduction

Understanding the changes in a body after death is crucial for forensic investigations, as various internal and external factors influence the decomposition process. In forensic medicine, the human body responds to death in various ways. Different thanatological findings will be present, ranging from changes in color, shape, temperature, and consistency to undergoing decomposition, mummification, and putrefaction. On the other hand, forensic odontology can also discover various thanatological findings, which is typically known for its function in human identification. One of these is the pink teeth phenomenon (PTP) [1].

The phenomenon of pink teeth, also known as PTP, refers to the finding of a change in tooth color after death, resulting in a pinkish hue [2]. Omas Bell first discussed PTP in 1829. He described pink teeth in individuals who died from hanging or drowning [3]. After several decades of limited study, in 1941, Sakurada et al. conducted observations and found pink teeth in various forensic cases such as fires, poisoning, gunshot wounds, and even natural deaths [4]. Over time, various studies began to report findings of pink teeth in various forensic cases, from natural to unnatural. Therefore, when discussing pink teeth in relation to causes of death, the conclusions become questionable [5–9].

In various studies on postmortem PTP, several key factors have been identified that contribute to this phenomenon. First, environmental conditions such as humidity and temperature are crucial, as they significantly affect the development of PTP. Second, a postmortem interval (PMI) of more than 7 days is often observed, indicating that the biochemical processes responsible for tooth discoloration take time to manifest. Additionally, specific postmortem processes play a role, including decomposition, where the breakdown of tissues occurs due to microbial activity; adipocere formation, which is the transformation of body fat into a waxy substance that alters the environment around the teeth; and putrefaction, which is the decay process affecting proteins and organic materials in the body [7, 10, 11]. From the lack of correlation between pink teeth and the cause of death to the potential postmortem evidence in dental autopsies, our case study will present findings of pink teeth on two corpses, analyze their relationship to the time of death, the environmental conditions in which the bodies were found and other findings related to pink teeth with the aim of forensic investigation

## Case Reports

### Case 1

A 52-year-old male was found dead in a house. According to the forensic examination request letter, the suspected cause of death was illness, with an estimated time of death of approximately 3-5 days ago. External examination revealed that the body arrived with all clothing appearing wet and covered in coffee. The body showed signs of decomposition characterized by abdomen and genital bloating, greenish discoloration, and skin slippage in the lower extremities (Figure 1).

Forensic odontology examination revealed significant oral cavity decomposition, characterized by eye and tongue protrusion, soft tissue degradation, and larval infestation (maggots) measuring approximately 18-19 mm. The larval activity was also observed in the orbital and auricular cavities. Further observation showed significant gingival recession exposing the tooth roots, with generalized tooth mobility and the lower left canine had become dislodged from its socket, a condition known as postmortem tooth loss. This tooth was then examined using the Lamendin method to confirm chronological age through dental age estimation (Figure 2) [12]. The estimated age range is 48.9 to 53.9 years, demonstrating excellent accuracy.

The PTP observed in all anterior teeth of the upper and lower jaws is particularly noteworthy. This finding included the central and lateral incisors, as well as the canines on both sides (Figure 3). When classifying the degree of pink teeth according to Minegishi et al. (2022), this case falls into category score 2, as the pink teeth were observed from the cervical area up to half of the dental crown (Figure 3) [13].

### Case 2

A deceased body without identification was brought to the forensic facility. Due to the lack of identification and family members coming to claim the body, it was subsequently stored in a forensic freezer. One month later, an autopsy was performed on the body. The body's condition had undergone decomposition, indicated by a change in skin color to dark black. The autopsy results showed no signs or symptoms that the deceased had died from drowning, asphyxia, or other trauma.

Significant gingival recession was found during the forensic odontology examination, exposing the tooth roots and generalized tooth mobility. In the dental autopsy, one

tooth was extracted to estimate the age of the deceased, resulting in an estimated age of 53-59 years. This finding aligns with the age estimation made by forensic pathology through cranial suture closure. Further observation revealed “pink teeth” in the anterior maxillary teeth, with the left central incisor displaying the most pronounced pink teeth. When classifying the degree of pink teeth according to Minegishi et al. (2022), this case falls into category score 2, as the pink teeth were observed from the cervical area up to half of the dental crown (Figure 4) [13].

## Discussion

Understanding the changes in a body after death is crucial for forensic investigations, as various internal and external factors influence the decomposition process. External factors include temperature, where higher levels accelerate microbial activity and decomposition; humidity, which promotes microbial growth; and oxygen availability, with low oxygen conditions slowing the process. Internal factors involve age and sex, which can affect decomposition rates due to biological differences; body composition, where individuals with more fat may decompose faster; the cause of death, such as chronic illness or trauma, which influences the body's state at death; and external injuries that can introduce additional microorganisms. These factors are essential for accurately estimating the PMI, the time since death, which is vital in forensic contexts [14, 15].

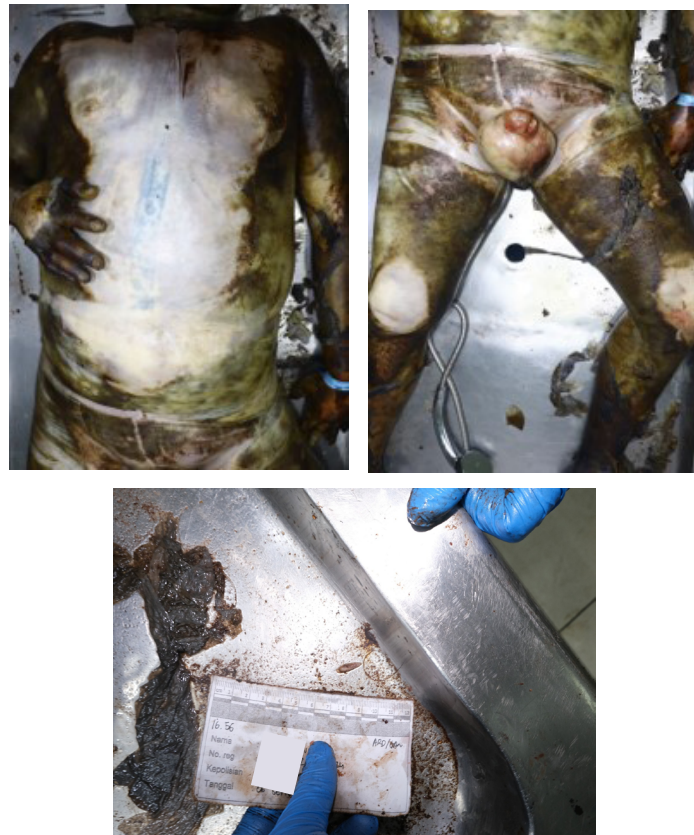After the cessation of the three vital life systems, the interruption of oxygen supply to cells leads to a decrease in oxygen levels, resulting in an anaerobic state within the body. According to Hau et al. decomposition primarily occurs through autolysis and putrefaction. Autolysis involves the breakdown of cells by hydrolytic enzymes, typically occurring in metabolically active cells or those with high water content, with organs such as the brain and liver particularly susceptible to high ATP (adenosine triphosphate) production. In contrast, putrefaction refers to the degradation of tissues caused by microbial activity, primarily from bacteria and fungi that are part of the body's normal flora, especially in the gastrointestinal tract. This microbial action is why decomposition often begins in the abdominal region, where these microorganisms are most concentrated [14].

Mechanically, the process of body decomposition is divided into five stages. The first stage is the fresh stage (1-2 days postmortem). This initial stage begins immediately after death and is characterized by autolysis, where cells break down due to a lack of oxygen. Early changes

include algor mortis, rigor mortis, and livor mortis, with no signs of decomposition yet, although insects like flies start to arrive for oviposition. Then, there is the bloating stage (2-6 days). In this stage, gases produced by bacteria lead to visible swelling of the abdomen and protrusion of the eyes and tongue. The skin may discolor due to hemoglobin transformation, and putrefaction odors become noticeable. After 5-11 days, the body is marked by rapid degradation of soft tissues as ruptured skin allows access to microorganisms and insects. The corpse releases fluids and strong odors, with significant activity from Dipteran larvae consuming soft tissues (active decay). The next stage is advanced decay, also known as black putrefaction. This stage sees further breakdown, where bones begin to be exposed and most soft tissues have decomposed. The odor diminishes to a weaker smell as Dipteran larvae migrate for pupation and are replaced by Coleoptera species. At the last skeletal stage, there is a high exposure of bones with minimal remaining soft tissue. Decomposition slows significantly, taking years or decades for a complete breakdown, influenced by environmental factors [14, 16].

In case one, the body has entered the PMI of 2 to 6 days, which is the bloating stage, characterized by protrusion of the eyes and tongue, abdominal and genital bloating, greenish discoloration, and skin slippage: Soft tissue degradation and larval infestation (maggots). In the second case, the PMI has been influenced by low temperatures due to the storage of the body in a refrigeration unit. Nevertheless, the body has already emitted a strong odor, exhibited black discoloration, and shown insect activity upon removal, indicating that the PMI for the second body has progressed to weeks or even months [16, 17].

From a forensic entomology perspective, larval activity in the first case and pupal activity in the second case indicate a PMI of more than three days following death. Insects typically arrive within 24 hours after death, as the decomposing body emits chemical compounds that attract necrophagous insects, primarily blowflies (family Calliphoridae), which have a high spatial accuracy for detecting odors [18]. These flies are usually the first to colonize the remains, laying their eggs on the body. Different stages of decomposition attract various insect species. The estimation of PMI using this method is frequently employed, especially when death has occurred more than 72 hours prior, as other thanatological methods can yield accurate results within the first 72 hours. Larvae, commonly called maggots, then develop by feeding on body tissues and undergo two molts before forming pupae, which mature into adult flies [19].




International Journal of  
Medical Toxicology & Forensic Medicine

**Figure 1.** Abdomen and genital bloating, greenish discoloration of the abdomen, skin slippage in lower extremities and larva activities in the deceased body

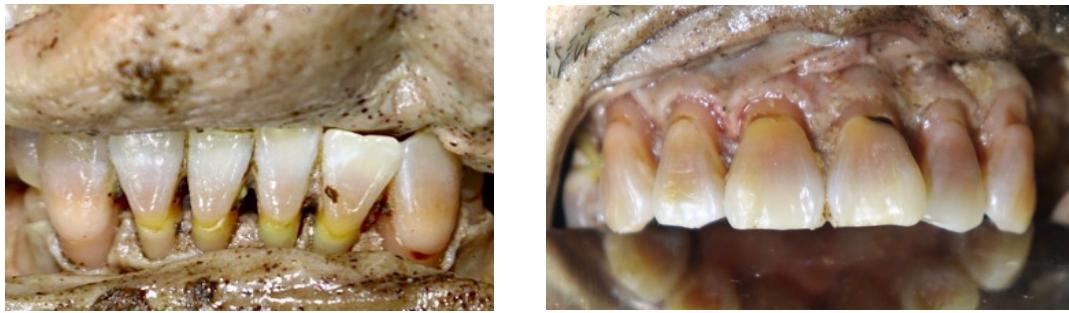
Case one exhibited larvae measuring approximately 19-20 mm (Figure 1), indicating that, from an entomological perspective, the PMI for this case is estimated to have begun 72 hours after death. Wang et al. observed the growth of fly larvae and how their size correlates with the time of death. At 24 hours postmortem, the average

size of the larvae is typically between 4-5 mm; after 48 hours, this size increases to 8-11 mm; by 72 hours, the larvae are approximately 18-19 mm. This growth pattern is critical for forensic entomology as it aids in estimating the time since death based on larval development stages and their respective sizes [20].



International Journal of  
Medical Toxicology & Forensic Medicine

**Figure 2.** The lamendin method used to confirm chronological age



**Figure 3.** The PTP observed in all anterior teeth of the maxilla and mandible

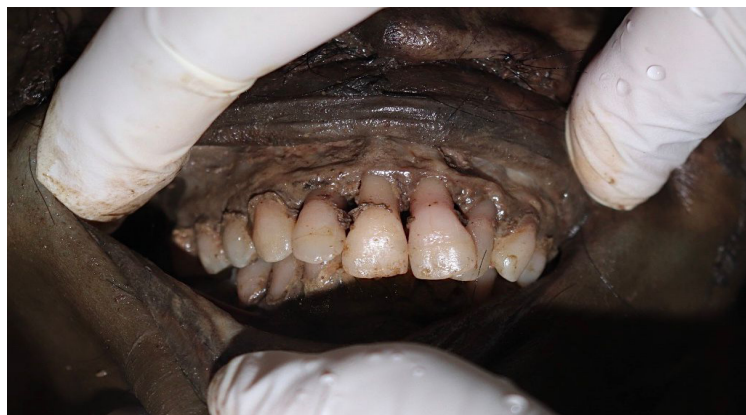International Journal of  
Medical Toxicology & Forensic Medicine

The PTP related to postmortem changes has been discussed in several studies [1, 2, 8, 11, 21, 22]. Regarding the mechanism, postmortem PTP occurs due to congestion/hyperemia of the pulp capillaries, followed by hemolysis, which leads to the release of hemoglobin. This hemoglobin then diffuses into the dentinal tubules. The process demonstrates that hemoglobin and serum proteins can enter the dentin through the dentinal tubules, imparting a pink coloration to the teeth [6]. Minegishi et al. classified the degree of discoloration on pink teeth based on an analysis of 68 cases of pink teeth in cadavers. The degree of discoloration was categorized into three levels: Degree 1 indicates minimal discoloration with a faint pink color, degree 2 indicates moderate discoloration with a regular pink color, and degree 3 indicates severe discoloration with a dark pink color. Furthermore, they differentiated the scores of pink teeth based on the region of discoloration as follows: Score 1 indicates discoloration at the root just below the cervical area of the tooth, score 2 reflects discoloration in the cervical half of the crown and score 3 denotes discoloration in the incisal half of the crown [13].

Various studies have elucidated that the PTP findings are not directly related to the cause of death. However,

these findings can provide insights into the environmental conditions surrounding the corpse, particularly in moist environments, and the processes involved in postmortem decomposition [5–9]. In our cases, the cause of death could not be determined because an autopsy was not performed. However, we would like to highlight that both bodies were in an advanced state of decomposition and were located in a humid environment. In the first case, the deceased was found indoors in South Jakarta in September 2024. During that month, the average rainfall in Indonesia was categorized as moderate, with a rate of 69.3%. However, Java Island experienced above-normal rainfall, ranging between 116% and 200% of the average, with 6 out of 19 extreme rainfall points (>150 mm/day) recorded in West Java. Although specific weather data for the exact location of the incident is unavailable, it can be assumed that South Jakarta had high humidity levels. These conditions likely accelerated postmortem changes, including the degree of decomposition and discoloration of the teeth, such as the PTP observed in the victim [23].

The study conducted by Villalobos León et al. reported that the PTP is observed in cases where the bodies are found in water, exhibiting signs of putrefaction, with



**Figure 4.** The PTP observed in all anterior teeth of the maxilla

International Journal of  
Medical Toxicology & Forensic Medicine

drowning identified as the cause of death and a PMI of three days [24]. Mittal et al. identified PTP in cases involving deaths that occurred in aquatic environments and outdoor settings, with a PMI ranging from 10 to 14 days and asphyxia as the cause of death [25]. Additionally, Franco et al. highlighted that a substantial proportion of PTP cases are associated with the decomposition process, regardless of whether the deaths were due to natural causes, unnatural causes, or undetermined. These studies collectively underscore the relevance of PTP in forensic investigations and its potential implications for understanding postmortem changes [7].

Minegishi et al. reported significant changes in the degree and region of pink teeth in relation to the PMI. Notably, a marked increase in the degradation of pink teeth was observed between 2 to 6 months after death, while cases with intervals of less than one week showed less pronounced discoloration. After 7 months, a significant decrease in degree and region scores was noted. In drowning cases, the degree of discoloration increased significantly within the first-week postmortem. This phenomenon is closely associated with decomposition processes and environmental conditions, particularly in moist environments. Additionally, the study highlighted that pink teeth are more frequently found in the cervical area near the root of the teeth following death. This observation aligns with findings from two case reports where pink teeth were identified in the cervical region at the root and the crown's cervical half. These findings underscore the importance of understanding the relationship between pink teeth and postmortem changes, as well as their potential implications for forensic investigations [13].

According to sex, the two cases we discussed were both males. Franco et al. conducted a study on pink teeth in relation to PMI, finding that seven out of eight cadavers examined were male [7]. This observation aligns with the findings from the study by Brites et al., which noted that pink teeth are more frequently encountered in males than females. This prevalence may be attributed to the higher incidence of violent deaths among adult males, which is often a prerequisite for medico-legal autopsies [7]. On the other hand, Minegishi et al. found no significant differences in the occurrence of pink teeth based on gender and age. Their results suggest that the PTP is more related to environmental conditions and the time since death rather than demographic factors. This finding indicates that pink teeth can appear in various situations, but factors like age and gender do not significantly affect their presence [13]. Nonetheless, several studies indicate that PTP exhibits a biological predilection for occurrence in younger victims, attributed to the larger diameter of dentinal tubules in young teeth than in older individuals [6].

Further discussion reveals that pink tooth discoloration was observed in both cases in anterior teeth, not posterior teeth. This finding is consistent with several studies indicating that PTP is more frequently present in single-rooted teeth compared to multi-rooted posterior teeth [1, 2, 10]. A systematic review by Franco et al. suggests that among the various studies, a total of 331 cases of PTP were identified, with 163 being anterior teeth, 87 classified as premolars and 81 as molars [1]. Kristanto et al. stated that physiological factors such as the morphology of dentinal tubules and the number of roots may also play a role in developing pink teeth, which triggers the rupture of blood vessels from the dental pulp canal [26].

## Conclusion

In conclusion, the phenomenon of pink teeth is a vital postmortem indicator that can offer valuable insights into the circumstances surrounding death. There is a strong correlation between the PMI and the occurrence of pink teeth, particularly in humid environments where cadaveric decomposition is accelerated. Pink teeth typically develop several weeks or even months after death, but they can appear in less than one week under highly humid conditions. While factors such as physical trauma, poisoning, asphyxia, and systemic diseases may contribute to this discoloration, it is crucial to understand that pink teeth cannot be directly linked to the cause of death.

A comprehensive forensic investigation should consider various aspects, including decomposition processes and entomological factors. Collaboration among pathologists, toxicologists, and forensic odontologists is essential for understanding the physiological changes after death. This multidisciplinary approach improves the accuracy of determining the time of death and highlights the significance of pink teeth as a valuable postmortem indicator in forensic science.

## Ethical Considerations

### Compliance with ethical guidelines

This study was approved by the Ethics Committee of Faculty of Dentistry, [University of Indonesia](#), Jakarta, Indonesia (Code: Ref. 14/Ethical Exempted/FGUI/V/2025; Protocol number: 030680525). The study was conducted in accordance with ethical standards respecting the dignity and confidentiality of the deceased, and complied with relevant institutional and national regulations.

## Funding

This research did not receive any grant from funding agencies in the public, commercial, or non-profit sectors.

## Authors' contributions

Examination: Andi Nur Sakina Tri Meilana, Mohammad Ardhian Syaifuddin and Michael Ganda; Data interpretation: Mohammad Ardhian Syaifuddin, Antonius Winoto Suhartono, Elza Ibrahim Auerkari; writing the final manuscript: Andi Nur Sakina Tri Meilana and Elza Ibrahim Auerkari; Revising the manuscript: Mohammad Ardhian Syaifuddin, Antonius Winoto Suhartono, Michael Ganda and Elza Ibrahim Auerkari; Critically reviewing and final approval: All authors.

## Conflict of interest

The authors declared no conflict of interest.

## Acknowledgements

The authors also sincerely appreciate the facilities and support provided by Universitas Indonesia, which made this work possible.

## References

- [1] Franco A, de Oliveira MN, Gomes-Lima LK, et al. Case-specific characteristics of pink teeth in dental autopsies-A systematic review. *Journal of Forensic and Legal Medicine*. 2019; 68:101869. [DOI:10.1016/j.jflm.2019.101869]
- [2] Sumi N, Minegishi S, Ohta J, Utsuno H, Sakurada K. Study on the mechanism of the pink tooth phenomenon using bovine teeth: A pilot study. *Diagnostics*. 2023; 13(16):2699. [DOI:10.3390/diagnostics13162699] [PMID]
- [3] Bell T. *The anatomy, physiology, and disease of the teeth*. Canada: Carey & Lea; 1829. [Link]
- [4] Sakurada K. Effects on oral tissues of asphyxiation caused by cervical compression: The pink teeth phenomenon in Kato's studies (1941). *Legal Medicine (Tokyo)*. 2023; 64:102284. [DOI:10.1016/j.legalmed.2023.102284] [PMID]
- [5] Mittal P. Post Mortem pink teeth and pseudo pink nails in a case of suicidal hanging. *Pathology and Laboratory Medicine*. 2021; 5(1):1. [DOI:10.11648/j.plm.20210501.11]
- [6] Mittal P, Karagwal P, Gupta D. Pink teeth phenomenon and asphyxia: A reassessment and update. *Journal of Forensic Research*. 2021; 12:2021. [Link]
- [7] Franco A, Mendes SDSC, Picoli FF, Rodrigues LG, Silva RF. Forensic thanatology and the pink tooth phenomenon: From the lack of relation with the cause of death to a potential evidence of cadaveric decomposition in dental autopsies - Case series. *Forensic Science International*. 2018; 291:e8-12. [DOI:10.1016/j.forsciint.2018.08.011] [PMID]
- [8] Minegishi S, Utsuno H, Ohta J, Namiki S, Toya M, Sumi N, et al. Sixty-eight cases of postmortem pink teeth observed in dental autopsies of unidentified cadavers. *Journal of Forensic Sciences*. 2022; 67(3):1280-7. [DOI:10.1111/1556-4029.15005] [PMID]
- [9] Brites AN, Rezende Machado AL, Franco A, Alves da Silva RH. Revisiting autopsies of death by mechanical asphyxia in the search for post-mortem pink teeth. *The Journal of Forensic Odonto-Stomatology*. 2020; 38(1):34-8. [PMID]
- [10] Campobasso CP, Di Vella G, De Donno A, Santoro V, Favia G, Introna F. Pink teeth in a series of bodies recovered from a single shipwreck. *American Journal of Forensic Medicine and Pathology*. 2006; 27(4):313-6. [DOI:10.1097/01.paf.0000233544.58567.81] [PMID]
- [11] Charan Gowda B, Sivapathasundharam B, Chatterji A, Chatterji B. Histological appearance of postmortem pink teeth: Report of two cases. *Journal of Forensic Dental Sciences*. 2015; 7(2):168. [DOI:10.4103/0975-1475.156200] [PMID]
- [12] Lamendin H, Baccino E, Humbert JF, Tavernier JC, Nossintchouk RM, Zerilli A. A simple technique for age estimation in adult corpses: The two criteria dental method. *Journal of Forensic Sciences*. 1992; 37(5):1373-9. [DOI:10.1520/JFS13327J] [PMID]
- [13] Minegishi S, Saitoh H, Utsuno H, Ohta J, Namiki S, Toya M, et al. Association of cadaveric factors with the degree and region of discoloration on pink teeth: An approach to serial cases. *Applied Sciences*. 2022; 12(9):4242. [DOI:10.3390/app12094242]
- [14] Hau TC, Hamzah NH, Lian HH, Amir Hamzah SPA. Decomposition process and post mortem changes: Review. *Sains Malays*. 2014; 43(12):1873-82. [DOI:10.17576/jsm-2014-4312-08]
- [15] Lee Goff M. Early post-mortem changes and stages of decomposition in exposed cadavers. *Experimental & Applied Acarology*. 2009; 49(1-2):21-36. [DOI:10.1007/s10493-009-9284-9] [PMID]
- [16] Vij K. *Textbook of forensic medicine and toxicology: Principles and Practice*, 5/e. Amsterdam: Elsevier; 2011. [Link]
- [17] Rao D. An analytical study of decomposed bodies during forensic autopsies. *IP International Journal of Forensic Medicine and Toxicological Sciences*. 2022; 6(4):141-6. [DOI:10.18231/j.ijfmts.2021.030]
- [18] Singh A, Singh Sankhla M, Parihar K, Shiv K. Determining time of death using forensic entomology. *International Medico-Legal Reporter Journal*. 2(3):7-13. [Link]
- [19] Agrawal V, Das G, Mehta HK, Shakya M, Jayraw AK, Jatav GP. Application of forensic entomology to estimating time since death. *Journal of Animal Sciences and Livestock Production*. 5(5):9091. [Link]

- [20] Wang M, Wang Y, Hu G, Wang Y, Xu W, Wu M, et al. Development of *Lucilia sericata* (Diptera: Calliphoridae) under constant temperatures and its significance for the estimation of time of death. *Journal of Medical Entomology* 2020; 57(5):1373-81. [DOI:10.1093/jme/tjaa046] [PMID]
- [21] Braga S, Caldas IM, Dinis-Oliveira RJ. Forensic significance of postmortem pink teeth: A narrative review. *Archives of Oral Biology*. 2025; 169:106092. [DOI:10.1016/j.archoral-bio.2024.106092]
- [22] Hartomo BT, Adrianto AWD, Auerkari EI. Pink teeth as post mortem indicator: A literature review. *AIP Conference Proceedings*. 2019; 2092(1):040021. [DOI:10.1063/1.5096754]
- [23] Badan Meteorologi, Klimatologi, dan Geofisika. Badan meteorologi, klimatologi, dan geofisika [Internet]. 2024 [1 Oktober 2024]. Available from: [Link]
- [24] Villalobos León K, Fernández Chaves JM. Fenómeno de diente rosado en asfixia por sumersión. *Medicina Legal de Costa Rica*. 2016; 33(2):133-7. [Link]
- [25] Mittal P, Mittal M, Sharma G. Pink teeth and the dead: A review with reports of two cases. *Journal of Indian Academy of Forensic Medicine*. 2016; 38(3):366-9. [DOI:10.5958/0974-0848.2016.00092.0]
- [26] Kristanto R, Putri KA, Prestiyanti I, Budhiarta AR, Pinto PV, da Silva RA, et al. Can red coloration of teeth (pink teeth) as post-mortem finding be a consideration in medicolegal investigation? *La Revue de Médecine Légale*. 2023;14(4):100419. [Link]