

Research Paper

Allicin and L-carnitine as Preventive Agents Against Doxorubicin-induced Cardiac Damage in Rats



Ahmed Soliman¹ , Mohamed Alkafafy² , Ehab Yahya Abdelhicee³ , Maram H Abduljabbar⁴ , Suzan Hasan Alotaibi⁵ , Noha M. Gamil⁶ , Mohamed Aboubakr^{7*} 

1. Department of Pharmacology, Faculty of Veterinary Medicine, Cairo University, Giza, Egypt.

2. Department of Biotechnology, College of Science, Taif University, Taif, Saudi Arabia.

3. Department of Forensic Medicine and Toxicology, Faculty of Veterinary Medicine, Matrouh University, Matrouh, Egypt.

4. Department of Pharmacology and Toxicology, College of Pharmacy, Taif University, Taif, Saudi Arabia.

5. Department of Family Medicine, Prince Mansour Military Hospital, Taif, Saudi Arabia.

6. Department of Pharmacology and Toxicology, Faculty of Pharmaceutical Sciences and Drug Manufacturing, Misr University for Science and Technology, Giza, Egypt.

7. Department of Pharmacology, Faculty of Veterinary Medicine, Benha University, Qaliobiya, Egypt.



Citation: Soliman A, Alkafafy M, Abdelhicee EY, Abduljabbar MH, Alotaibi SH, Gamil NM, Aboubakr M. Allicin and L-carnitine as Preventive Agents Against Doxorubicin-induced Cardiac Damage in Rats. *International Journal of Medical Toxicology and Forensic Medicine*. 2024; 14(3):E45510. <https://doi.org/10.32598/ijmtfm.v14i3.45510>

 <https://doi.org/10.32598/ijmtfm.v14i3.45510>

Article info:

Received: 07 Jun 2024

First Revision: 17 Jun 2024

Accepted: 23 Jun 2024

Published: 05 Aug 2024

ABSTRACT

Background: Doxorubicin (DOX) is a potent anthracycline chemotherapy agent widely employed to treat various malignancies, such as cancers and this study sought to determine how allicin (ALC) and/or L-carnitine (LC) affect DOX-induced cardiotoxicity in rats.

Methods: In this study, the possible alleviative role of ALC (20 mg/kg/day orally (PO)) or LC (100 mg/kg/day PO) or the combined treatment of both ALC and LC (with the previously mentioned dosages) was evaluated against the cardiotoxic effect of a widely used chemotherapeutic agent, DOX (20 mg DOX/kg intraperitoneal injection (IP) as a single dose) in rats in 30 days experiment.

Results: The results revealed that ALC and LC significantly suppressed the DOX-induced increment in serum levels of cardiac damage biomarkers, such as lactate dehydrogenase (LDH), creatine kinase (CK) and creatine kinase-megabyte (CK-MB). Moreover, DOX-associated oxidative stress, including the elevation in malondialdehyde (MDA) level and reduced activity of antioxidant enzymes, such as catalase (CAT) and superoxide dismutase (SOD) and the level of reduced glutathione (GSH) was corrected in ALC and/or LC treated groups. Furthermore, DOX-induced cardiomyopathy showed significant pathological changes, including myocyte degeneration, vacuolization, interstitial edema, and focal necrosis. Nevertheless, the histopathological lesions were corrected in the treated groups mostly in the combined treatment with ALC plus LC. Compared to ALC and LC, ALC plus LC was more effective at restoring the cardiac injury biomarkers, inhibiting cardiac oxidative damage and preserving the cardiac architecture.

Conclusions: Conclusively, the study results evidenced the beneficial role of the combined treatment with ALC plus LC in mitigating DOX-induced cardiotoxicity.

Keywords:

Doxorubicin (DOX),
Cardiomyopathy, Allicin
(ALC), L-carnitine (LC),
Oxidative damage

* Corresponding Author:

Mohamed Aboubakr, Professor.

Address: Department of Pharmacology, Faculty of Veterinary Medicine, Benha University, Qaliobiya, Egypt.

Tel: +20 (109) 9874671

E-mail: mohamed.aboubakr@fvtm.bu.edu.eg



Copyright © 2024 The Author(s);

This is an open access article distributed under the terms of the Creative Commons Attribution License (CC-BY-NC: <https://creativecommons.org/licenses/by-nc/4.0/legalcode/en>), which permits use, distribution, and reproduction in any medium, provided the original work is properly cited and is not used for commercial purposes.

Introduction

Doxorubicin (DOX) is a potent anthracycline chemotherapy agent widely employed to treat various malignancies, such as cancers of the breast, uterus, ovary, cervix, and other blood cancers, as well as leukemias and hemophilias [1]. Furthermore, the native state of DOX is an extremely potent antineoplastic agent approved by the Food and Drug Administration (FDA). Several studies have illustrated that DOX endangers vital healthy tissues by promoting oxidative stress and inflammation [2]. Substantial evidence suggests that DOX can lead to cardiotoxicity through various mechanisms involving apoptosis, abnormal intracellular calcium signaling, autophagy, metabolic disruption, endoplasmic reticulum stress, and mitochondrial damage [3]. Compared to the previously mentioned mechanisms, it is widely accepted that cardiomyocytes are more susceptible to oxidative stress, which has been proposed as a key factor in DOX-induced cardiomyopathy pathogenesis [4]. Conversely, DOX inhibits the endogenous enzymatic and nonenzymatic antioxidants. Where a discrepancy exists between reactive oxygen species (ROS) generation and neutralization, oxidative stress can occur and has a greater negative impact on the heart than other organs, such as the kidney and liver [5].

Alliin (ALC) is a bioactive compound found in garlic (*Allium sativum*) with various beneficial properties. ALC is formed when the enzyme alliinase reacts with the precursor compound alliin upon tissue damage or crushing of garlic cloves. ALC is responsible for the strong odor and flavor of garlic. ALC has potent antioxidant properties and anti-inflammatory effects which can protect against oxidative stress-induced damage by scavenging free radicals increasing the activity of endogenous antioxidants and preventing pro-inflammatory cytokine production [5].

L-carnitine (LC) is a natural molecule generated in the kidneys and liver from the amino acids methionine and lysine. Both the cardiac and skeletal muscles have a sizeable concentration of it. Its main function is to make it easier for long-chain fatty acids to enter the matrix of mitochondria, which is the starting point for the β -oxidation of fatty acids. The myocardium gets its energy mostly from this process [6]. Various studies illustrated that LC has diverse biological impacts, involving anti-inflammatory, anti-apoptotic and antioxidant properties [1]. Furthermore, LC can improve the cardiotoxicity induced by different toxicants [7, 8].

Based on all previous knowledge, this study sought to determine how ALC and or LC affect DOX-induced cardiotoxicity in rats.

Materials and Methods

Chemicals

The DOX injectable vial (2 mg/mL) was purchased commercially from Egyptian International Medical Center (EIMC) (EIMC) United Pharmaceuticals, Egypt. ALC (35% powder) was obtained from Delta Vet Center Comp. (Cairo, Egypt). LC was purchased commercially from MEPACO Comp. (Inshas Elraml, Egypt).

Animals and experimental protocol

Forty-nine male Wistar albino rats (175-200 g) were procured from the Egyptian organization for biological products and vaccines. The rats were housed in standard and comfortable hygienic conditions (25 ± 2 °C and a 12 h light/dark cycle) and provided unrestricted access to a standard diet and water. For acclimatization, the rats were kept in the lab for one week before starting the trial. The rats were randomly separated into seven equivalent groups (7 rats/group). The control group was orally dosed with saline only. The ALC-treated group was orally given 20 mg/kg/day ALC for 30 days [9]. The LC-treated group was orally dosed with 100 mg/kg/day LC for 30 days [10]. The DOX-treated group was given saline orally for 30 days, and 24 hours after receiving the last dose of saline, 20 mg DOX /kg was injected IP as a single dose [11]. In the ALC+DOX, LC+DOX and ALC+LC+DOX-treated groups, the rats received ALC, LC and DOX in the same regimen used with the previous three groups.

Blood sampling and serum biochemical markers

All rats had been anesthetized 48 hours after DOX injection with isoflurane. The blood specimens were gathered from the retro-orbital plexus of each rat. The blood was left to clot at room temperature for 20 minutes before being centrifuged at 1200 g for 15 minutes for serum collection to be stored at -20 °C until the future biochemical analysis. The sera levels of the biomarkers of cardiac damage (LDH, creatine kinase (CK) and CK-megabyte [MB]) were assayed according to [12-14], respectively.

Tissue oxidative stress markers

Following the blood specimen collection, the animals were euthanized by decapitation so that the hearts could be rapidly harvested and cleaned using 0.9% Sodium chloride (NaCl) solution. One gram of cardiac tissue was gathered in cold eppendorf tubes and kept at -80°C until used. Using an electrical homogenizer enclosed with ice, the cardiac tissue samples (one gm) were homogenized in 10 mL cold phosphate buffer (pH 7.4). To prevent glutathione (GSH) from oxidizing, the N-ethylmaleimide solution was supplemented directly after homogenization and centrifuged at 5000 rpm for 30 minutes. Based on [15-18] studies, the supernatants were analyzed for catalase (CAT) and superoxide dismutase (SOD) activities, as well as GSH and malondialdehyde (MDA) concentrations. The analytical kit reagents were purchased from the Bio-diagnostics Company (Dokki, Giza, Egypt).

Histopathological examination

According to [19], cardiac tissues were prepared for histopathological analysis. Fiji ImageJ software, version 1.51u) was utilized to analyze the resulting images.

Histopathological scoring of cardiac injury

The method employed to evaluate cardiac pathology in this study involved categorizing changes in degeneration, interstitial expansion and hemorrhage across multiple fields in each group. For each parameter, the presence or absence of pathological changes was recorded using a binary system: Positive (+) for the presence of a change

and negative (-) for its absence. Each field was evaluated individually, and a total score was calculated for each parameter by counting the number of positive responses. The average severity of each condition for each group was then classified into one of four categories based on the proportion of positive fields: No: No positive fields were detected. Mild: Few positive fields were present. Moderate: A moderate number of positive fields, suggesting a noticeable but not overwhelming presence of pathological changes. Severe: Most or all fields are positive, indicating extensive pathological changes.

Statistical analysis

One-way analysis of variance (ANOVA) was used to estimate the results and variation across the groups was exposed using Tukey's post-hoc multiple tests. Significant variations between means were identified at the $P<0.05$ level and stated as Mean \pm SD. GraphPad Prism software, version 9 was used for data analysis and the generation of column charts.

Result

Effect of ALC and or LC treatment on serum biochemical parameters

As revealed in Figure 1, the administration of DOX alone in rats caused a significant ($P<0.05$) increase in the serum levels of LDH, CK and CK-MB, compared to control rats. It should be noted that the administration of ALC, LC and ALC plus LC significantly impacted the improvement of the measured parameters.

Table 1. Semi-quantitative severity scoring of histopathology of cardiac muscle

Groups	Degeneration	Interstitial Expansion	Hemorrhage
Control	0/10 No	0/10 No	0/10 No
ALC	1/10 Mild	0/10 No	0/10 No
LC	1/10 Mild	1/10 Mild	0/10 No
DOX	8/10 Severe	9/10 Severe	7/10 Severe
ALC+DOX	5/10 Moderate	3/10 Mild	3/10 Mild
LC+DOX	2/10 Mild	6/10 Moderate	2/10 Mild
ALC+LC+DOX	2/10 Mild	3/10 Mild	0/10 No

Abbreviations: No: No positive fields detected; Mild: Few positive fields present; Moderate: A moderate number of positive fields, suggesting a noticeable but not overwhelming presence of pathological changes; Severe: A majority or all fields positive, indicating extensive pathological changes.

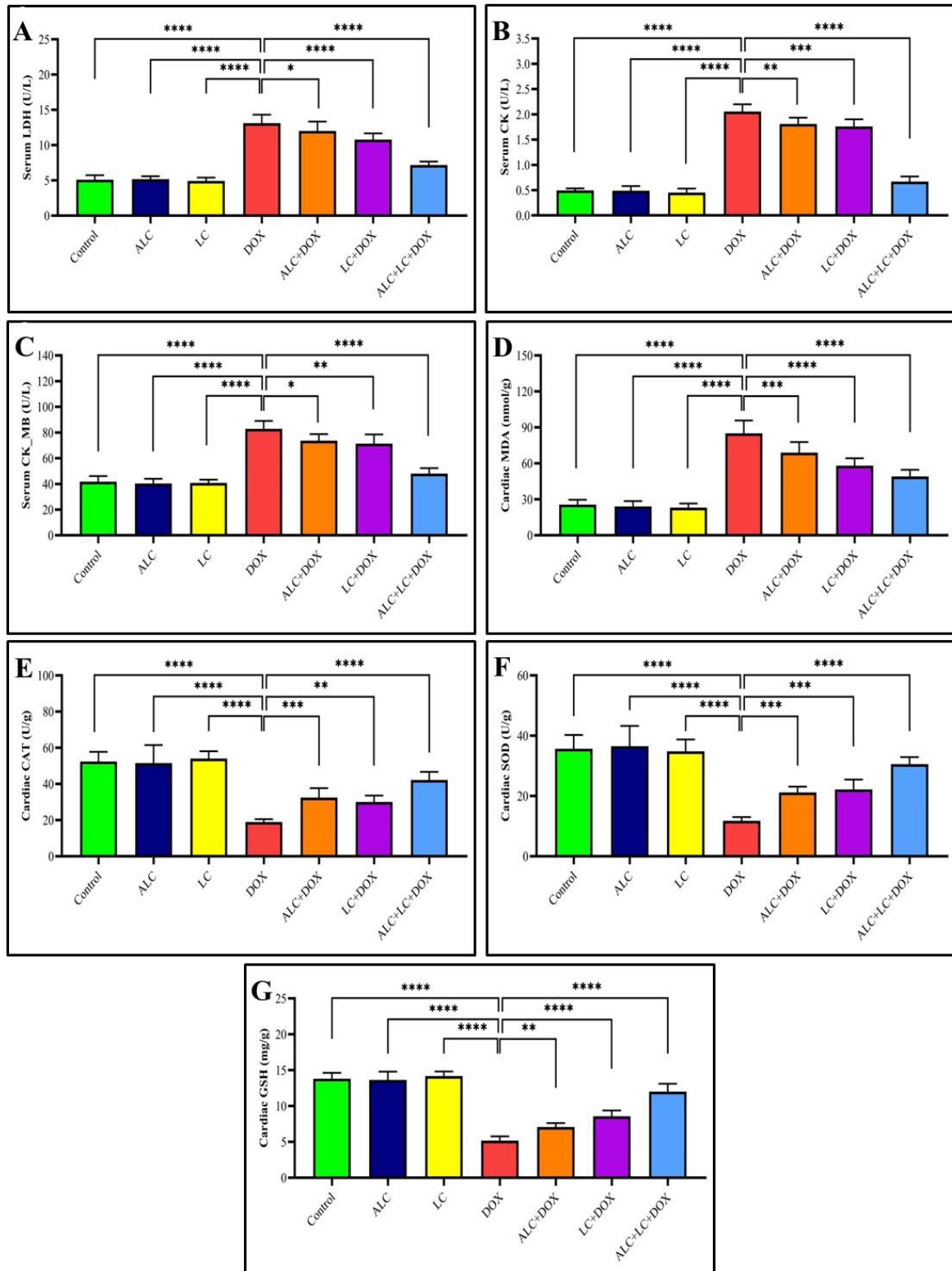


Figure 1. Effect of ALC, LC, DOX on serum biochemical parameters and cardiac antioxidant parameters in rats (n=7)

*<0.05, **<0.01, ***<0.001, ****<0.0001. Values presented as Mean±SD.




Figure 2. Histological analysis of cardiac sections illustrating structural differences across treatment groups

Notes: Preserved cardiac architecture with intact myocardial fibers and centrally located nuclei in the control group (white arrow indicate normal myocardial structures) (A); normal cardiac architecture with no significant alterations in the ALC (B) and LC (C) groups (white arrows indicate normal myocardial structures). DOX-treated group showed focal necrosis (blue arrow) and myocyte degeneration (black arrows) (D). DOX-treated group showed interstitial expansion (green arrows), hemorrhage (red arrow) (E). Varying degrees of tissue preservation in the ALC+DOX showed hemorrhage (red arrow) (F). LC+DOX-treated group showed myocyte degeneration (black arrows) (G). Preserved architecture with minimal structural changes in the ALC+LP+DOX group (white arrow indicate normal myocardial structures) (H); Semi-quantitative scoring of histopathological changes for parameters of myocyte degeneration, interstitial expansion, and hemorrhage (I).

Effect of ALC and or LC treatment on oxidative cascade and lipid peroxidation

Figure 1 presents the oxidative status (CAT, SOD, and GSH) and the lipid peroxidation (MDA) index. DOX treatment provoked significant oxidative stress, as showed by a reduction in CAT and SOD activity as well as the level of GSH, along with elevated MDA compared to control rats. However, the administration of ALC, LC, and ALC plus LC revealed significant promotions in CAT and SOD activities and GSH levels, as well as reduced MDA levels. Remarkably, the combination treat-

ment with ALC and LC revealed the best improvement of the DOX-induced oxidative stress.

Histological analyses of cardiac sections

It revealed distinct architectural differences across the treatment groups: Normal control (Figure 2A), ALC (Figure 2B), LC (Figure 2C) treated groups cardiac architecture was preserved with well-defined myocardial fibers as branched striated cardiac myocytes with acidophilic cytoplasm and centrally located, vesicular, and oval nuclei and intact interstitial structure. The DOX-

treated group showed significant pathological changes, including distorted striations of cardiac muscle, myocyte degeneration, vacuolization, focal necrosis in small clusters of myocardial fibers, interstitial edema, extravasated RBCs and noticeable expansion in interstitial spaces (Figures 2D and E). ALC+DOX: Treatment with ALC attenuated the severity of pathological damage to a certain degree. A reduction in the extravasated RBCs and a slight restoration of myocardial architecture were observed. However, some myocyte degeneration persisted (Figure 2F). LC+DOX; this group showed less interstitial edema and reduced myocyte damage compared to the DOX-only group. A notable reduction was observed in necrotic cardiac muscle fibers and better preservation of myocardial structure (Figure 2G). The combination treatment (ALC+LC+DOX) presented the most preserved cardiac architecture among the treated groups. Minimal cellular degeneration, reduced interstitial edema, and well-preserved myocardial integrity were observed, suggesting potentially synergistic protective effects of ALC and LC when combined with DOX (Figure 2H) (Table 1).

Discussion

DOX is extensively used as a chemotherapeutic medication to treat several malignancies, including lung, stomach, breast, ovary, and childhood cancers [11]. Despite its widespread use, prolonged administration of DOX can lead to severe hostile effects on various normal tissues, particularly the heart [20]. It is believed that increased production of ROS and compromised antioxidant defense systems are the primary mechanisms through which DOX induces cardiotoxicity [21]. A strong attraction to negatively charged phospholipid cardiolipin indicates that it is plentiful in the inner mitochondrial membrane and accumulates within the mitochondria of cardiomyocytes [22]. ALC, a sulfur-containing compound found in garlic, and LC, a crucial nutrient elaborated in energy metabolism, have antioxidant and cardioprotective properties [5, 23]. To the best of our knowledge, the combined treatment with ALC and LC was used for the first time in our study to prevent DOX-induced cardiotoxicity.

Based on the current research results, it was shown that DOX exposure is associated with increased lipid peroxidation and oxidative stress. SOD, an intrinsic antioxidant enzyme, serves as the primary line of defense against oxidative stress by facilitating the dismutation of O_2^- into O_2 and hydrogen peroxide (H_2O_2) [24]. Moreover, as a scavenger of superoxide and as a moderator of oxidant balances within tissues, SOD plays a critical role

throughout the cardiovascular system [25]. Additionally, CAT plays a vital role in converting hydrogen peroxide into oxygen and water vapor. The non-enzymatic antioxidant GSH plays a crucial role in scavenging various ROS, such as peroxynitrite, hydroxyl radical, lipid peroxyl radical, and hydrogen peroxide (H_2O_2), along with other free radicals [26]. Nonetheless, the heightened oxidative stress induced by DOX within the myocardium can have detrimental impacts due to the heart's limited antioxidant defense mechanism [27].

In the present study, ALC, a major component of the sulfur-containing compound of garlic, reduced the levels of MDA and elevated the activity of CAT and SOD and the levels of GSH. It has been suggested that ALC's antioxidant abilities are mainly related to its potency to inhibit ROS generation. These results were consistent with the former study conducted by [5]. Furthermore, LC+DOX treated groups significantly restored the cardiac antioxidant enzymes (CAT and SOD) activity and GSH levels and reduced MDA levels in the heart tissues. In the current study, the most antioxidant-superior results were recorded in the ALC+LC+DOX group due to the strong antioxidant capacity of both ALC and LC.

As anticipated, the amplified lipid peroxidation and oxidative stress caused by DOX exposure disrupt the cardiac tissue and release cardiac enzymes, such as LDH, CK, and CK-MB into the bloodstream, resulting in elevated levels in the serum, as observed in the existing study. Previous studies also reported these results [5, 28] demonstrating that DOX disrupts the rat cardiac tissue. On the contrary, a marked correction in the cardiac injury markers was noticed in the ALC+DOX, LC+DOX, and ALC+LC+DOX groups. Comparably, a reduction in these cardiac markers in a dose-dependent manner of ALC was recorded in the study of [5]. Additionally, [29] found that LC improved cardiac damage by reducing the serum enzymes including LDH and other anti-inflammatory factors, such as tumor necrosis factor-alpha, and serum interleukin-1 beta.

All these results were notably consistent with our histopathological results, as substantial pathologic alterations and severe damage were observed in cardiac tissues in the DOX group. These cardiomyopathy alterations have proposed oxidative stress, lipid peroxidation and apoptosis as the fundamental mechanisms behind these observations [30]. Previously published data has revealed diverse pathways by which Dox-induced cardiomyopathy occurs. These pathways involve inflammation-related signaling, such as the upregulation of NF- κ B expression

and the stimulation of several proinflammatory cytokines, including TNF- α [31].

In the current study, cardiomyopathy impact in DOX-exposed rats was improved by ALC and or LC remediation. Moreover, our study revealed that ALC and or LC remarkably impaired the cardiomyopathy damage as seen in the histopathological results. These results were consistent with a former study [5], and attributed to the antioxidant and anti-inflammatory activity of ALC. Furthermore, several clinical studies have exposed that supplementing with LC can facilitate the mobilization of fat in the myocardium as a result of the increased demand for free fatty acids and their metabolites, and consequently improve the function of the cardiac muscle [32]. As a consequence of these results, ALC and LC can be useful in improving DOX-induced cardiotoxicity by their strong antioxidant and anti-inflammatory properties.

Conclusion

Our results evidenced for the first time that ALC and LC coadministration plays a crucial cardioprotective role against DOX-induced cardiotoxicity at the biochemical, antioxidant, and histopathological levels in adult rats. This cardioprotective impact of ALC and LC is ascribed to its antioxidant properties, along with its potential to restore the normal structure of the damaged cardiac tissues. Therefore, we propose that the combined administration of ALC and LC can be a novel effective preventive approach to avoid DOX-induced cardiomyopathy.

Study limitations

The study used a single dose of DOX, which may not reflect the chronic dosing regimen typically used in cancer treatment. The cardiotoxic effects and the mitigating effects of ALC and LC may differ under a chronic administration schedule. Further research should also explore different dosages and treatment durations to establish a dose-response relationship. This issue provides a more comprehensive understanding of how ALC and LC interact with DOX over extended periods.

Ethical Considerations

Compliance with ethical guidelines

This study was approved by the Ethics Committee of the [Cairo University](#), Giza, Egypt (Code: Vet CU 25122023822).

Funding

This research was financially supported by [Taif University, Taif](#), Saudi Arabia (Project No.: TU-DSPP-2024-109).

Authors' contributions

Methodology: Noha M. Gamil; Experimental protocol design: Ahmed Soliman, Mohamed Aboubakr and Ehab Yahya Abdelhice; Writing: Mohamed Alkafafy, Maram H Abduljabbar and Suzan Hasan Alotaibi; Final approval: All authors.

Conflict of interest

The authors declared no conflict of interest.

Acknowledgements

The authors extend their appreciation to [Taif University](#), Taif, Saudi Arabia, for supporting this work.

References

- [1] Fang Y, Yang W, Cheng L, Meng F, Zhang J, Zhong Z. EGFR-targeted multifunctional polymersomal doxorubicin induces selective and potent suppression of orthotopic human liver cancer in vivo. *Acta Biomaterialia*. 2017; 64:323-33. [DOI:10.1016/j.actbio.2017.10.013] [PMID]
- [2] Tai P, Chen X, Jia G, Chen G, Gong L, Cheng Y, et al. WX50 mitigates doxorubicin-induced cardiotoxicity through inhibition of mitochondrial ROS and ferroptosis. *Journal of Translational Medicine*. 2023; 21(1):823. [DOI:10.1186/s12967-023-04715-1] [PMID] [PMCID]
- [3] Pai VB, Nahata MC. Cardiotoxicity of chemotherapeutic agents: Incidence, treatment and prevention. *Drug Safety*. 2000; 22(4):263-302. [DOI:10.2165/00002018-200022040-00002] [PMID]
- [4] Wang Y, Chao X, Ahmad FUD, Shi H, Mehboob H, Hassan W. Phoenix dactylifera Protects against Doxorubicin-Induced Cardiotoxicity and Nephrotoxicity. *Cardiology Research and Practice*. 2019; 2019:7395239. [DOI:10.1155/2019/7395239] [PMID] [PMCID]
- [5] Abdel-Daim MM, Kilany OE, Khalifa HA, Ahmed AAM. Allicin ameliorates doxorubicin-induced cardiotoxicity in rats via suppression of oxidative stress, inflammation and apoptosis. *Cancer Chemotherapy and Pharmacology*. 2017; 80(4):745-53. [DOI:10.1007/s00280-017-3413-7] [PMID]
- [6] Wang ZY, Liu YY, Liu GH, Lu HB, Mao CY. L-Carnitine and heart disease. *Life Sciences*. 2018; 194:88-97. [DOI:10.1016/j.lfs.2017.12.015] [PMID]

- [7] Aboubakr M, Elsayd F, Soliman A, Fadl SE, El-Shafey A, Abdelhieb EY. L-Carnitine and vitamin E ameliorate cardiotoxicity induced by tilimicosin in rats. *Environmental Science and Pollution Research International*. 2020; 27(18):23026-34. [DOI:10.1007/s11356-020-08919-6] [PMID]
- [8] Mansour HH, El Kiki SM, Ibrahim AB, Omran MM. Effect of L-carnitine on cardiotoxicity and apoptosis induced by imatinib through PDGF/PPAR γ /MAPK pathways. *Archives of Biochemistry and Biophysics*. 2021; 704:108866. [DOI:10.1016/j.abb.2021.108866] [PMID]
- [9] Aboubakr M, Farag A, Elfadadny A, Alkafafy M, Soliman A, Elbadawy M. Antioxidant and anti-apoptotic potency of allicin and lycopene against methotrexate-induced cardiac injury in rats. *Environmental Science and Pollution Research International*. 2023; 30(38):88724-33. [DOI:10.1007/s11356-023-28686-4] [PMID]
- [10] Elkomy A, Abdelhieb EY, Fadl SE, Emam MA, Gad FA, Sallam A, et al. L-Carnitine mitigates oxidative stress and disorganization of cytoskeleton intermediate filaments in cisplatin-induced hepato-renal toxicity in rats. *Frontiers in Pharmacology*. 2020; 11:574441. [DOI:10.3389/fphar.2020.574441] [PMID] [PMCID]
- [11] AlAsmari AF, Ali N, Alharbi M, Alqahtani F, Alasmari F, Almoqbel D, et al. Geraniol ameliorates doxorubicin-mediated kidney injury through alteration of antioxidant status, inflammation, and apoptosis: Potential roles of NF- κ B and Nrf2/Ho-1. *Nutrients*. 2022; 14(8):1620. [DOI:10.3390/nu14081620] [PMID] [PMCID]
- [12] Buhl SN, Jackson KY. Optimal conditions and comparison of lactate dehydrogenase catalysis of the lactate-to-pyruvate and pyruvate-to-lactate reactions in human serum at 25, 30, and 37 degrees C. *Clinical Chemistry*. 1978; 24(5):828-31. [DOI:10.1093/clinchem/24.5.828]
- [13] Neumeier D, Prellwitz W, Würzburg U, Brundobler M, Oibermann M, Just H-J, et al. Determination of creatine kinase isoenzyme MB activity in serum using immunological inhibition of creatine kinase M subunit activity. Activity kinetics and diagnostic significance in myocardial infarction. *Clinica Chimica Acta; International Journal of Clinical Chemistry*. 1976; 73(3):445-51. [DOI:10.1016/0009-8981(76)90146-7] [PMID]
- [14] Szasz G, Waldenström J, Gruber W. Creatine kinase in serum: 6. Inhibition by endogenous polyvalent cations, and effect of chelators on the activity and stability of some assay components. *Clinical Chemistry*. 1979; 25(3):446-52. [DOI:10.1093/clinchem/25.3.446] [PMID]
- [15] Aebi H. Catalase in vitro. *Methods in Enzymology*. 1984; 105:121-6. [DOI:10.1016/S0076-6879(84)05016-3] [PMID]
- [16] Habig WH, Pabst MJ, Jakoby WB. Glutathione S-transferases. The first enzymatic step in mercapturic acid formation. *The Journal of Biological Chemistry*. 1974; 249(22):7130-9. [DOI:10.1016/S0021-9258(19)42083-8] [PMID]
- [17] Mihara M, Uchiyama M. Determination of malonaldehyde precursor in tissues by thiobarbituric acid test. *Analytical Biochemistry*. 1978; 86(1):271-8. [DOI:10.1016/0003-2697(78)90342-1] [PMID]
- [18] Nishikimi M, Appaji N, Yagi K. The occurrence of superoxide anion in the reaction of reduced phenazine methosulfate and molecular oxygen. *Biochemical and Biophysical Research Communications*. 1972; 46(2):849-54. [DOI:10.1016/S0006-291X(72)80218-3] [PMID]
- [19] Bancroft JD, Gamble M. *Theory and Practice of Histological Techniques*. Amsterdam: Elsevier Health Sciences; 2013.
- [20] Shivakumar P, Rani MU, Reddy AG, Anjaneyulu Y. A study on the toxic effects of Doxorubicin on the histology of certain organs. *Toxicology International*. 2012; 19(3):241-4. [DOI:10.4103/0971-6580.103656] [PMID] [PMCID]
- [21] Songbo M, Lang H, Xinyong C, Bin X, Ping Z, Liang S. Oxidative stress injury in doxorubicin-induced cardiotoxicity. *Toxicology Letters*. 2019; 307:41-8. [DOI:10.1016/j.toxlet.2019.02.013] [PMID]
- [22] Parker MA, King V, Howard KP: Nuclear magnetic resonance study of doxorubicin binding to cardiolipin containing magnetically oriented phospholipid bilayers. *Biochimica et Biophysica Acta (BBA) - Biomembranes*. 2001; 1514(2):206-16. [DOI:10.1016/S0005-2736(01)00371-6]
- [23] Khedr NF, El-Feky OA, Werida RH. L-carnitine mitigates trazadone induced rat cardiotoxicity mediated via modulation of autophagy and oxidative stress. *Cardiovascular Toxicology*. 2022; 22(9):831-41. [DOI:10.1007/s12012-022-09759-1] [PMID] [PMCID]
- [24] Fukai T, Folz RJ, Landmesser U, Harrison DG. Extracellular superoxide dismutase and cardiovascular disease. *Cardiovascular Research*. 2002; 55(2):239-49. [DOI:10.1016/S0008-6363(02)00328-0] [PMID]
- [25] Fattman CL, Schaefer LM, Oury TD. Extracellular superoxide dismutase in biology and medicine. *Free Radical Biology & Medicine*. 2003; 35(3):236-56. [DOI:10.1016/S0891-5849(03)00275-2] [PMID]
- [26] Fang YZ, Yang S, Wu G. Free radicals, antioxidants, and nutrition. *Nutrition*. 2002; 18(10):872-879. [DOI:10.1016/S0899-9007(02)00916-4] [PMID]
- [27] Xiong C, Wu YZ, Zhang Y, Wu ZX, Chen XY, Jiang P, et al. Protective effect of berberine on acute cardiomyopathy associated with doxorubicin treatment. *Oncology Letters*. 2018; 15(4):5721-9. [DOI:10.3892/ol.2018.8020]
- [28] Wei J, Yang Q, Lin L, Zhu C, Wei J. [Metformin mitigates doxorubicin-induced cardiotoxicity via the AMPK pathway (Chinese)]. *Journal of Southern Medical University*. 2023; 43(10):1682-8. [DOI:10.12122/j.issn.1673-4254.2023.10.05] [PMID]
- [29] Mustafa HN, Hegazy GA, Awdan SAE, AbdelBaset M. Protective role of CoQ10 or L-carnitine on the integrity of the myocardium in doxorubicin induced toxicity. *Tissue & Cell*. 2017; 49(3):410-26. [DOI:10.1016/j.tice.2017.03.007] [PMID]
- [30] Yalçın E, Oruç E, Cavuşoğlu K, Yapar K. Protective role of grape seed extract against doxorubicin-induced cardiotoxicity and genotoxicity in albino mice. *Journal of Medicinal Food*. 2010; 13(4):917-25. [DOI:10.1089/jmf.2009.0162] [PMID]
- [31] Wang S, Kotamraju S, Konorev E, Kalivendi S, Joseph J, Kalyanaraman B. Activation of nuclear factor-kappaB during doxorubicin-induced apoptosis in endothelial cells and myocytes is pro-apoptotic: The role of hydrogen peroxide. *The Biochemical Journal*. 2002; 367(Pt 3):729-40. [DOI:10.1042/bj20020752] [PMID] [PMCID]
- [32] Malone JJ, Cuthbertson DD, Malone MA, Schocken DD. Cardio-protective effects of carnitine in streptozotocin-induced diabetic rats. *Cardiovascular Diabetology*. 2006; 5:2. [DOI:10.1186/1475-2840-5-2] [PMID] [PMCID]