

Research Paper: Role of Prophylactic Antibiotic Administration in Growth of Methicillin Resistant Staphylococcus Aureus in Rhinoplasty



Nader Akbari Dilmaghani^{1,2*}, Masoumeh Navidinia³, Latif Gachkar^{4,5}, Shima Arastou²

1. Department of Otolaryngology, Head and Neck Surgery, Loghman Hakim Hospital, School of Medicine, Shahid Beheshti University of Medical Sciences, Tehran, Iran.

2. Hearing Disorders Research Center, Loghman Hakim Hospital, Shahid Beheshti University of Medical Sciences, Tehran, Iran.

3. Department of Medical Laboratory Sciences, School of Allied Medical Sciences, Shahid Beheshti University of Medical Sciences, Tehran, Iran.

4. Department of Infectious Diseases, Loghman Hakim Hospital, School of Medicine, Shahid Beheshti University of Medical Sciences, Tehran, Iran.

5. Infectious Diseases and Tropical Medicine Research Center, Loghman Hakim Hospital, School of Medicine, Shahid Beheshti University of Medical Sciences, Tehran, Iran.



Citation: Akbari Dilmaghani N, Navidinia M, Gachkar L, Arastou Sh. Role of Prophylactic Antibiotic Administration in Growth of Methicillin Resistant Staphylococcus Aureus in Rhinoplasty. International Journal of Medical Toxicology and Forensic Medicine. 2019; 9(3):109-116. <https://doi.org/10.32598/ijmtfm.v9i3.25228>

<https://doi.org/10.32598/ijmtfm.v9i3.25228>



Article info:

Received: 05 Dec 2018

First Revision: 29 Dec 2018

Accepted: 10 Apr 2019

Published: 01 Jul 2019

Keywords:

Rhinoplasty, MRSA, Staphylococcus Aureus, Antibiotic

ABSTRACT

Background: Septoplasty and septorhinoplasty are common surgical procedures in modern surgical practice. Pre or postoperative antibiotic administration has raised concerns about the possible increase in the antibiotic-resistant species. The aim of this study was to evaluate the role of postoperative antibiotic prophylaxis in increasing Methicillin-Resistant Staphylococcus Aareus species (MRSA) in patients, who underwent septoplasty or septorhinoplasty in Loghman Hakim Hospital in Tehran, Iran.

Methods: A total of 102 patients, who were planned to undergo septoplasty or septorhinoplasty, participated in this double-blind randomized clinical trial. The patients were divided into the case (n=60, mean age of 28.2 years) and control (n=38, mean age of 28.9 years) groups. Overall, 98 patients participated in the study. The case group received a preoperative injection of cephalothin (1g) and postoperative oral cephalixin regimen (500mg 4 times a day for 7 days). The control group only received a preoperative injection of cephalothin (1g). Vestibular nasal swab cultures were obtained preoperatively and on postoperative day 7. The samples were, then, quickly transferred to the laboratory and cultured on proper media. The results indicated that five MRSA species in the case group and tow MRSA species in the control group were present, postoperatively.

Results: The findings of this study suggest that oral antibiotic prophylaxis may lead to a statically non-significant increase in MRSA infection in patients, who require this treatment.

Conclusion: Further knowledge of the endogenous nasal flora and the microbiology of common pathogens in patients undergoing septorhinoplasty will help reduce the incidence of infectious complications to a greater level.

* Corresponding Author:

Nader Akbari Dilmaghani, PhD.

Address: Department of Otolaryngology, Head and Neck Surgery, Loghman Hakim Educational Hospital, School of Medicine, Tehran, Iran.

Tel: +98 (912) 3450082

E-mail: nadakbari@sbmu.ac.ir

1. Introduction

Nowadays, septoplasty and septorhinoplasty are common surgical procedures. In clinical practice, the administration of pre and postoperative antibiotics to prevent postoperative infection after septoplasty or rhinoplasty is a standard procedure used by otolaryngologists, although its necessity is controversial [1-6]. On the other hand, one of the most serious concerns regarding antibiotic consumption is the increased antibiotic-resistant organisms, such as Methicillin-Resistant *Staphylococcus Aureus* (MRSA).

Previous reports have demonstrated that the infection rate after elective nasal surgery is very low, making routine antibiotic prophylaxis-redundant [1-6]. Systemic antibiotics are administered as the preventive treatment in patients with the prolonged placement of nasal packs, who undergo complicated revision rhinoplasties, as well as the patients who are susceptible to infections [7]. It has been demonstrated that (66%) of the American Rhinologic Society members use antibiotics as a routine practice in the postoperative period of septoplasties [5, 6]. The indiscriminate use of antibiotics may also result in severe complications, such as toxic reactions, reduced antibody production stimuli, and unnecessary costs [8, 9].

The incidence of allergic reactions and fatal anaphylaxis are approximately (0.7-10%) and 1.25000 cases, respectively [10]. *Staphylococcus aureus* is a well-known commensal of the anterior nares, which is commonly cultured from nasal swabs of a healthy patient, who may carry these organisms intermittently or persistently. Although the exact reason for persistent colonization is yet to be determined, it seems to form a protective barrier against the colonization of other strains of *Staphylococci* at least during hospitalization [11]. Antibiotic consumption in these persistent or intermittent carriers may result in the elimination of Methicillin-Sensitive *Staphylococcus Aureus* (MSSA) and allows the proliferation of MRSA [12].

The aim of this study was to investigate if postoperative antibiotic administration increases the incidence of MRSA colonization in nasal flora in patients, who underwent septoplasty or septorhinoplasty.

2. Materials and Methods

Patients

This study was performed from June 2013 to September 2014 in Loghman Hakim Hospital, Tehran, Iran. A total of

102 patients, who were planned to undergo septoplasty or septorhinoplasty, participated in this research based on their clinical presentations, otorhinolaryngological examination, and nasal endoscopy results.

Patients with any type of immune deficiencies, sign of sinonasal or upper respiratory infection, history of antibiotic consumption in the last three months prior to the study, hospital admission during the last year prior to the study, history of allergic reaction to cephalexin or cephalothin, previous nasal surgeries, and chronic rhinosinusitis or allergic rhinitis with or without nasal polyps, as well as patients with positive preoperative MRSA cultures of vestibular nasal swab, were excluded from the study. The eligible patients were, then, randomly divided into two groups; the case group that received a preoperative injection of cephalothin (1g) at the beginning of the surgery and postoperative oral cephalexin (500 mg 4 times a day for seven days), and the control group that only received preoperative injection of cephalothin (1g). No antibiotic ointment was administered postoperatively.

Both the surgeon and the patient were blind to the participant's groups. The operations were performed by one surgeon, the same method, and at the same hospital. The patients in both groups underwent a classical septoplasty or septorhinoplasty without applying any allograft or synthetic material; moreover, the intranasal dressing was not applied at the end of the surgery. Vestibular nasal swab cultures from both nostrils were obtained preoperatively and on postoperative day Seventh. The patients were followed-up for three months for the signs of sinonasal infection, septal abscess, or purulent discharge.

Detection protocol for MRSA isolates

In this study, 102 swabbed nostril samples were obtained from the participants and were transferred in transport media to the Loghman Hakim Hospital Laboratory in Tehran, Iran, between June 2013 and September 2014. The specimens were obtained by inserting a sterile moistened swab into each nostril to an approximate depth of 1cm, which was, then, rotated five times. Four patients were excluded from the study since they did not return for postoperative sampling on time. The samples were, then, quickly transferred to the laboratory and inoculated onto a Mannitol Salt Agar (MSA) medium in order to isolate *S. aureus*. Blood agar and MacConkey agar were used for primary isolation of the other bacteria. All the culture media were, then, incubated at 37°C.

For better isolation of *S. aureus*, the inoculated MSA were incubated at 35°C overnight. The isolates were identified, using morphological and biochemical tests according to the microbiological diagnostics methods. For *S. aureus* iden-

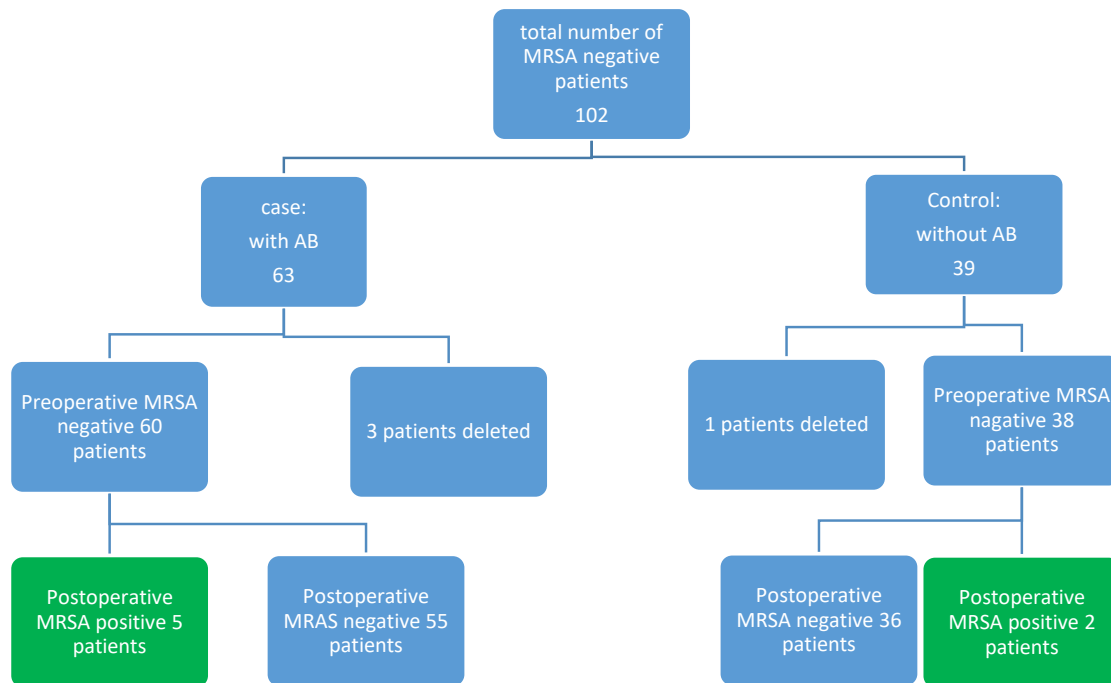


Figure 1. Flow chart of the participants

tification, diagnostic tests, including DNase test (Merck, Germany), mannitol salt agar fermentation (Merck, Germany), gram staining using a gram-staining kit (77730 Sigma-Aldrich), catalase test using (3%) hydrogen peroxide, and coagulase test using lyophilized citrate or EDTA-treated rabbit plasma were performed. All *S. aureus* strains were screened for methicillin-resistance, using oxacillin (1µg) and cefoxitin (30µg) disk diffusion tests based on standard guidelines [13-15].

Statistics

The SPSS V. 22 software (SPSS Inc. Chicago, IL, USA) was used to analyze the data. For a comparison of nominal variables, the Chi-squared test was used. P values of less than 0.05 were considered significant.

3. Results

Overall, 60 patients in the case group (38 males and 22 females) with a mean age of 28.2 years (age range of 19-48 years) and 38 patients in the control group (11 males and 27 females) with a mean age of 28.9 years (age range of 18-39 years) participated in the study (Figure 1). In total, three patients of the case and one patient of the control groups were excluded from the study since they did not return on time for postoperative sampling.

All the preoperative nasal swab cultures were negative for MRSA in both groups. As shown in Table 1, no bacterial growth was preoperatively detected in 23 patients of the case group. However, other organisms, such as MSSA, Coagulase Negative Staphylococci (CoNS), streptococci spp., as well as both gram-negative and positive bacilli were isolated from the samples of 37 patients of the case group. The results of the postoperative evaluation indicated the presence of five MRSA species in the case group and two MRSA species in the control group. There was no significant difference between the case and control groups regarding various bacteria, in particular, MRSA (Table 2). During the follow-up period, none of the patients presented sinonasal infection, septal abscess, or purulent discharge.

4. Discussion

The first study that investigated the prophylactic administration of antibiotics in surgical procedures was conducted in 1938; since then, several management regimes have been proposed [8]. Infections following septoplasty or septorhinoplasty are rare, possibly due to the redundant blood supply and highly vascular structure of the nose [5]. Despite the lack of evidence of the efficacy of antibiotics prophylaxis in preventing complications after septoplasty or septorhinoplasty, the administration of antibiotics in nasal surgery is a common practice [3, 8, 10, 16, 17].

Table 1. Prevalence of isolated bacteria from participants of both groups

Preoperative Culture			
Case		Control	
Staphylococcus aureus: 6(37.5)	Staphylococcus aureus: 6(42.85)	Staphylococcus aureus: 12(32.43)	Staphylococcus aureus: 12(46.15)
Negative culture 22	Negative culture 24	Negative culture 23	Negative culture 34
CoNS: 3(18.75)	CoNS: 2(14.28)	CoNS: 6(16.21)	CoNS: 3(11.53)
Bacillus spp.: 1(6.25)	Bacillus spp.: 0	Bacillus spp.: 2(5.4)	Bacillus spp.: 2(7.6)
E.coli: 1(6.25)	E.coli: 1(7.14)	E.coli: 4(10.8)	E.coli: 2(7.6)
Enterobacter aerogenes: 1(6.25)	Enterobacter aerogenes: 1(7.14)	Enterobacter aerogenes: 2(5.4)	Enterobacter aerogenes: 1(3.8)
Klebsiella pneumonia: 1(6.25)	Klebsiella pneumonia: 1(7.14)	Klebsiella pneumonia: 3(8.1)	Klebsiella pneumonia: 1(3.8)
Citrobacter freundii: 1(6.25)	Citrobacter freundii: 1(7.14)	Citrobacter freundii: 2(5.4)	Citrobacter freundii: 1(3.8)
Viridans streptococci: 2(12.5)	Viridans streptococci: 2(14.28)	Viridans streptococci: 6(16.21)	Viridans streptococci: 4(15.38)
MRSA: 0	MRSA: 2	MRSA: 0*	MRSA: 5*
MSSA: 6	MSSA: 4	MSSA: 12*	MSSA: 7*

International Journal of
Medical Toxicology & Forensic Medicine

MRSA: Methicillin-Resistance Staphylococcus aureus; MSSA: Methicillin-Sensitive Staphylococcus aureus; CoNS: Coagulase Negative Staphylococci

Table 2. Comparison of both groups considering the culture results

Group/ Bacteria	Culture Result: N (%)		P
	Control	Case	
Staphylococcus aureus	6(42.85)	12(46.15)	0.580
MRSA*	2(14.28)	5	0.331
MSSA*	4(28.57)	7	0.219
CoNS	2(14.28)	3(11.53)	0.865
Bacillus spp	0(0.00)	2(7.6)	0.206
E. coli	1(7.14)	2(7.6)	0.708
Enterobacter aerogenes	1(7.14)	1(3.8)	0.861
Klebsiella pneumonia	1(7.14)	1(3.8)	0.861
Citrobacter Freundii	1(7.14)	1(3.8)	0.374
Viridans streptococci	2(14.28)	4(15.38)	0.728
Negative culture in Case	22	34	-
Total number of patients	38	60	-

International Journal of
Medical Toxicology & Forensic Medicine

MRSA: Methicillin-Resistance Staphylococcus Aureus; MSSA: Methicillin-Sensitive Staphylococcus aureus; CoNS: Coagulase Negative Staphylococci

The extended use of antibiotics may result in complications, such as toxic reactions, reduced antibody production stimuli, as well as unnecessary costs [1, 8]. The incidence of allergic reactions following antibiotic consumption may vary from (0.7-10%); moreover, fatal anaphylaxis occurs in 1 out of 25000 patients [10]. It has been revealed that most of the members of the American Rhinologic Society apply prophylactic antibiotics to prevent postoperative infection (60.4%), toxic shock syndrome (31.5%), and legal-medical issues (4.9%) [3, 17].

Post-septorhinoplasty infections can lead to undesired scar formation, drooping tip, or saddle nose deformity, which might affect the surgical outcomes. Local wound infections, such as stitch infections, suture granulomas, and vestibulitis are considered common infectious complications. Septal abscesses and sinusitis have resulted from prolonged nasal packing and tight splinting [8, 18-20]. Unusual infections, including toxic shock syndrome, septicemia, endocarditis, meningitis, cavernous sinus thrombosis, and even brain abscess are rarely reported after septorhinoplasty [20, 21]. In this study, *Staphylococcus aureus* was the most common isolated organism from nasal swabs. The anterior nares are considered the primary ecological reservoir of these bacteria.

Up to (60%) of the general population are intermittent carriers of MSSA with an additional (20%) persistent carriers [11]. MSSA acts as a protective barrier against MRSA colonization [22]. The major concern about prophylactic antibiotic consumption is the reduction or eradication of MSSA in anterior nares. Nonetheless, (1.5%) of the general population in the United States were recolonized with MRSA [23]. The displacement of MSSA, by the administration of the broad-spectrum antibiotics, facilitates the nasal colonization with MRSA [22]. Indeed, MRSA nasal colonization is respectively established in (4.2%) and over (20%) of the patients once admitted to the hospital and after an average length of hospitalization [24]. Healthcare workers are at an increased risk of MRSA colonization.

A recent study has identified that (6.7%) of the examined healthcare workers were colonized with MRSA. Within this cohort, nurses demonstrated the highest MRSA prevalence of (10.4%) because of their frequent direct contact with patients. The prevalence of MRSA may be even higher among those, who work in intensive care environments [23]. Based on the medical literature, MRSA infections following septoplasty or septorhinoplasty are exceedingly rare; however, these types of infections may be under-diagnosed or under-reported. The rarity of MRSA infections following septoplasty

or septorhinoplasty has been highlighted in a review by Sharma et al. (2007); the reason might be owing to the fact that the patients undergoing these types of interventions are generally young patients without prior hospital admission, who are not at risk for MRSA colonization and infection [25].

Individuals at risk for MRSA colonization and infection include those, who work in the healthcare settings and their household members, patients over 60 years, HIV-infected individuals, and those with recent hospital admission or antibiotic consumption [26-28]. In this study, patients over 60 years, those with a history of recent hospital admission or antibiotic consumption or any kind of immunodeficiency were excluded. Avoiding antibiotic abuse results in the reduced pharmacological costs of medical treatments, prevents antibiotic-induced allergic reactions, and reduces the development of antibiotic-resistant bacteria [6]. Antibiotic prophylaxis in septoplasty or rhinoplasty surgeries should be assigned to particular cases, such as patients with cardiac valvulopathy or/and immunodepression in order to avoid the possible evolution of bacteremia, endocarditis, arthritis, and osteomyelitis [6, 10, 29-31].

5. Conclusion

This study was carried out to investigate the increase in the colonization of MRSA in patients, who underwent septoplasty or septorhinoplasty followed by postoperative prophylactic oral antibiotic administration. The results indicated that MRSA cultures were positive in few patients in the case group and two patients in the control group. Therefore, further studies are required to analyze the increased incidence of MRSA colonization after antibiotic therapy. The main limitation of the current study was the small sample size. Future studies on a larger population are advised to confirm the findings of the present study. Moreover, further analysis is recommended to be performed on the patients with *S. aureus* colonization in anterior nares, since four patients of this study, who tested positive for postoperative MRSA, were also positive for preoperative *S. aureus* cultures. Furthermore, *S. aureus* can be normal flora of the nose.

Ethical Considerations

Compliance with ethical guidelines

The protocols used in this study were approved by the Research Ethics Committee of Shahid Beheshti University of Medical Sciences and written informed consent was obtained from all the patients prior to their par-

ticipation in the study (Code of medical ethics: SBMU. REC.1392.26).

Funding

This research did not receive any specific grant from funding agencies in the public, commercial, or not-for-profit sectors.

Author's contributions

Conceptualization, methodology and supervision: Nader Akbari Dilmaghani; Writing and editing: Nader Akbari Dilmaghani, Masoumeh Navidinia, Shima Arastou; Microbiological assessment: Masoumeh Navidinia; Scientific works: Masoumeh Navidinia, Shima Arastou; Software, validation, formal analysis: Latif Gachkar.

Conflict of interest

The authors declared no conflict of interest.

References

- [1] Perrotti JA, Castor SA, Perez PC, Zins JE. Antibiotic use in aesthetic surgery: A national survey and literature review. *Plastic and Reconstructive Surgery*. 2002; 109(5):1685-93. [DOI:10.1097/00006534-200204150-00035] [PMID]
- [2] Rajan GP, Fergie N, Fischer U, Romer M, Radivojevic V, Hee GK. Antibiotic prophylaxis in septorhinoplasty? A prospective, randomized study. *Plastic and Reconstructive Surgery*. 2005; 116(7):1995-8. [DOI:10.1097/01.prs.0000191181.73298.b3] [PMID]
- [3] Rechtweg JS, Paolini RV, Belmont MJ, Wax MK. Postoperative antibiotic use of septoplasty: A survey of practice habits of the membership of the American Rhinologic Society. *American Journal of Rhinology*. 2001; 15(5):315-20. [DOI:10.1177/194589240101500506] [PMID]
- [4] Schwab JA, Pirsig W. Complications of septal surgery. *Facial Plastic Surgery*. 1997; 13(1):3-14. [DOI:10.1055/s-2008-1064461] [PMID]
- [5] Angelos PC, Wang TD. Methicillin-resistant *Staphylococcus aureus* infection in septorhinoplasty. *Laryngoscope*. 2010; 120(7):1309-11. [DOI:10.1002/lary.20966] [PMID]
- [6] Barry AL, Jones RN. Bacterial antibiotic resistance before and after clinical application in the United States. *Bulletin of the New York Academy of Medicine*. 1987; 63(3):217-30. [PMID] [PMCID]
- [7] Leonard D, Thompson D. Unusual septoplasty complication: *Streptococcus viridans* endocarditis. *Ear, Nose & Throat Journal*. 1998; 77(10):827-31. [DOI:10.1177/01455613980770109]
- [8] Weimert TA, Yoder MG. Antibiotics and nasal surgery. *Laryngoscope*. 1980; 90(4):667-72. [DOI:10.1288/00005537-198004000-00014]
- [9] Yoder M, Weimert T. Antibiotics and topical surgical preparation solution in septal surgery. *Otolaryngology-Head and Neck Surgery*. 1992; 106(3):243-4. [DOI:10.1177/019459989210600307] [PMID]
- [10] Slavin SA, Rees TD, Guy CL, Goldwyn RM. An investigation of bacteremia during rhinoplasty. *Plastic and Reconstructive Surgery*. 1983; 71(2):196-8. [DOI:10.1097/00006534-198302000-00008] [PMID]
- [11] Noble W, Williams R, Jevons MP, Shooter R. Some aspects of nasal carriage of staphylococci. *Journal of Clinical Pathology*. 1964; 17:79-83. [DOI:10.1136/jcp.17.1.79] [PMID] [PMCID]
- [12] Kluytmans J, Van Belkum A, Verbrugh H. Nasal carriage of *Staphylococcus aureus*: Epidemiology, underlying mechanisms, and associated risks. *Clinical Microbiology Reviews*. 1997; 10(3):505-20. [DOI:10.1128/CMR.10.3.505] [PMID] [PMCID]
- [13] Mahon CR, Lehman DC, Manuselis GJ. *Textbook of diagnostic microbiology*, 5th edition. London: Elsevier Health Sciences; 2014.
- [14] Armin S, Fallah F, Navidinia M, Vosoghian S. Prevalence of blaOXA-1 and blaDHA-1 AmpC β -Lactamase-Producing and Methicillin-Resistant *Staphylococcus aureus* in Iran. *Archives of Pediatric Infectious Diseases*. 2017; 5(4):e36778.
- [15] Clinical & Laboratory Standards Institute. Performance standards for antimicrobial susceptibility testing; twenty-second informational supplements. *Clinical & Laboratory Standards Institute*. 2013; 31(3):70-88.
- [16] Mäkitie A. Postoperative infection following nasal septoplasty. *Acta Oto-Laryngologica*. 2000; 120(543):165-6. [DOI:10.1080/000164800454297]
- [17] Silk KL, Ali MB, Cohen BJ, Summersgill JT, Raff MJ. Absence of bacteremia during nasal septoplasty. *Archives of Otolaryngology-Head and Neck Surgery*. 1991; 117:54-5. [DOI:10.1001/archotol.1991.01870130060016]
- [18] Caniello M, Passerotti GH, Goto EY, Voegels RL, Butugan O. Antibiotics in septoplasty: Is it necessary? *Brazilian Journal of Otorhinolaryngology*. 2005; 71:734-8. [DOI:10.1016/S1808-8694(15)31241-6]
- [19] Lawson W, Kessler S, Biller HF. Unusual and fatal complications of rhinoplasty. *Otolaryngology-Head and Neck Surgery*. 1983; 109(3):164-9. [DOI:10.1001/archotol.1983.00800170030008]
- [20] Fairbanks D. Complications of nasal packing. *Otolaryngology-Head and Neck Surgery*. 1986; 94(3):412-5. [DOI:10.1177/019459988609400337] [PMID]
- [21] Hull HF, Mann JM, Sands CJ, Gregg SH, Kaufman PW. Toxic shock syndrome related to nasal packing. *Archives of Otolaryngology-Head and Neck Surgery*. 1983; 109(9):624-6. [DOI:10.1001/archotol.1983.00800230060015] [PMID]
- [22] Taasan V, Wynne JW, Cassisi N, Block AJ. The effect of nasal packing on sleep-disordered breathing and nocturnal oxygen desaturation. *Laryngoscope*. 1981; 91(7):1163-72. [DOI:10.1288/00005537-198107000-00015] [PMID]

- [23] Philpott C, Sharma A, McKiernan D. Does methicillin-resistant *Staphylococcus aureus* have a significant role in the peri-operative course of patients undergoing rhinological surgery? *The Journal of Laryngology and Otology*. 2009; 123(2):191-4. [DOI:10.1017/S0022215108002855] [PMID]
- [24] Elie Turenne MC, Fernandes H, Mediavilla JR, Rosenthal M, Mathema B, Singh A, et al. Prevalence and characteristics of *Staphylococcus aureus* colonization among health-care professionals in an urban teaching hospital. *Infection Control and Hospital Epidemiology*. 2010; 31(6):574-80. [DOI:10.1086/652525] [PMID]
- [25] Sharma A, Philpott C, Pope L, McKiernan D. Methicillin resistant *Staphylococcus aureus*: Is it a problem for nasal surgery? *The Journal of Laryngology and Otology*. 2007; 121(5):415-8. [DOI:10.1017/S0022215106002763] [PMID]
- [26] Kuehnert MJ, Kruszon-Moran D, Hill HA, McQuillan G, McAllister SK, Fosheim G, et al. Prevalence of *Staphylococcus aureus* nasal colonization in the United States, 2001-2002. *The Journal of Infectious Diseases*. 2006; 193(2):172-9. [DOI:10.1086/499632] [PMID]
- [27] Lucet JC, Chevret S, Durand-Zaleski I, Chastang C, Regnier B. Prevalence and risk factors for carriage of methicillin-resistant *Staphylococcus aureus* at admission to the intensive care unit: results of a multicenter study. *Archives of Internal Medicine*. 2003; 163(2):181-8. [DOI:10.1001/archinte.163.2.181] [PMID]
- [28] Lucet JC, Grenet K, Armand-Lefevre L, Harnal M, Bouvet E, Regnier B, et al. High prevalence of carriage of methicillin-resistant *Staphylococcus aureus* at hospital admission in elderly patients: Implications for infection control strategies. *Infection Control and Hospital Epidemiology*. 2005; 26(2):121-6. [DOI:10.1086/502514] [PMID]
- [29] Kaygusuz I, Kizirgil A, Karlidag T, Yalçın S, Keles E, Yakupogullari Y, et al. Bacteriemia in septoplasty and septorhinoplasty surgery. *Rhinology*. 2003; 41(2):76-9.
- [30] Ricci G, D'Ascanio L. Antibiotics in septoplasty: Evidence or habit? *American Journal of Rhinology & Allergy*. 2012; 26(3):194-6. [DOI:10.2500/ajra.2012.26.3755] [PMID]
- [31] Georgiou I, Farber N, Mendes D, Winkler E. The role of antibiotics in rhinoplasty and septoplasty: A literature review. *Rhinology*. 2008; 46(4):267-70. [PMID]

This Page Intentionally Left Blank
