

# Case Report: Serial Seizures Due to the Pesticide Poison Strychnine, Refractory to High Doses of Benzodiazepines



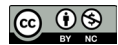Abbas Aghabiklooei<sup>1</sup> , Meysam Abolmaali<sup>2\*</sup>

1. Firoozgar General Hospital, School of Medicine, Iran University of Medical Sciences, Tehran, Iran.

2. Student Research Committee, School of Medicine, Iran University of Medical Sciences, Tehran, Iran.



**Citation** Aghabiklooei A, Abolmaali M. Serial Seizures Due to the Pesticide Poison Strychnine, Refractory to High Doses of Benzodiazepines. International Journal of Medical Toxicology and Forensic Medicine. 2018; 8(4):157-160.



## Article info:

**Received:** 25 Jan 2018

**First Revision:** 20 Feb 2018

**Accepted:** 15 Jul 2018

**Published:** 01 Oct 2018

## Keywords:

Seizure, Strychnine, Poisoning, Suicide, Benzodiazepines

## ABSTRACT

Drugs and poisons are the most common causes of new cases of seizure at emergency wards, a fact that can be easily missed unless physicians consider its likelihood in mind. In this report, we describe a case of recurrent seizures due to intentional ingestion of a pesticide poison (strychnine) that was refractory to very high doses of benzodiazepines and other anticonvulsants. Our patient suffered from 12 times tonic seizures and generalized muscular spasms, until he underwent anesthesia to control the seizures. Finally, he was discharged without any serious complications.

## 1. Introduction

**S**trychnine is an alkaloid poison with highly potential toxic effects that can be found in both vermin poisons and herbal remedies. It is also used as adulterant in street drugs like heroin due to its Central Nervous System (CNS) stimulator effects. Toxicity with strychnine is not common and in the absence of history of ingestion, poisoning by it may be missed. In this report, we describe a case of deliberate strychnine poisoning, admitted in an Emergency Department (ED) with uncontrollable serial convulsions and the occurrence of multiple awake seizures.

## 2. Case Report

A 22-year-old man was brought to our ED with complaint of serial seizures. He was a chronic abuser of amphetamine and also received quetiapine as the treatment of his sleep disorder. In initial physical examination, his vital signs were as follows: blood pressure 110/80 mm Hg, heart rate 82 beats/min, respiratory rate 16 breaths/min, and temperature 37.2°C. He had normal respiration with clear chest, without heart murmur, and 97% O<sub>2</sub> saturation in pulse oximetry. Patient had no fever or respiratory distress. He was awake and fully oriented without any signs of head trauma and CNS infection until he experienced more than 7 times repeated seizures

### \*Corresponding Author:

**Meysam Abolmaali, MD, Student**

**Address:** Student Research Committee, School of Medicine, Iran University of Medical Sciences, Tehran, Iran.

**Tel:** +98 (937) 4443163

**E-mail:** dr.meysam.a@gmail.com

with open eyes in an awake situation that were resistant to high doses of benzodiazepine drugs (Diazepam 140 mg IV and midazolam 100 mg IV).

Based on patient's body weight (91 kg), the starting dose of diazepam (10 mg) could not stop the seizures at ED, so it repeated every 2-4 minutes up to 50 mg when seizure stopped temporarily. During the first 24 h of admission, our patient experienced multiple and recurrent convulsions in four courses with interval periods of 4-6 h, so that he received totally 140 mg diazepam. In addition, because of severe agitation associated with seizures, he also received a total of 100 mg of midazolam during this period. He also showed no response to single dose of sodium valproate 400 mg IV, propofol 500 mg IV, and phenobarbital with a dose of 20 mg/kg intravenously. Finally, the seizures were controlled by general anesthesia and patient underwent tracheal intubation.

Cerebrovascular accident such as subarachnoid hemorrhage or ICH (Intracerebral Hemorrhage)-related to amphetamine overdose and CNS infections were ruled out by normal brain CT-scan and lumbar puncture. Blood sugar, renal function tests, liver aminotransferase, and serum  $\text{Ca}^{2+}$  and  $\text{Mg}^{2+}$  were normal, so that metabolic causes were also ruled out. The patient was under mechanical ventilation for the first 2 days of admittance in intensive care unit and also remained hospitalized for a total of 4 days due to aspiration pneumonia. In addition, multiple severe seizures on the day of admittance raised the patient's Creatinine Phosphokinase (CPK) serum-level up to 12000 mcg/L on the second day of hospital-

ization. Thus, the patient received adequate hydration to decrease the risk of acute renal failure associated with rhabdomyolysis (Figure 1).

During this time, he experienced 3 times more seizures in which he received multiple high doses of benzodiazepines to control rigidity and seizures. Finally, the patient was extubated without any sequels on the second day of admittance. When he became fully awake and conscious, he told that he was intentionally (as a suicide attempt) ingested two tea spoonful of a crystalline white powder. The analysis of powder with Thin Layer Chromatography (TLC) confirmed that it contained strychnine poison.

### 3. Discussion

Strychnine is a highly toxic, white, bitter crystalline alkaloid used as rodenticide, pesticide, mole/gopher repellent, herbal medicine, and laboratory chemical. It is first extracted from a plant seed called *Strychnos nuxvomica*, originated from Southeast Asia used for herbal therapy [1]. Strychnine poisoning is rare but most cases of its poisoning, today, result from the adulteration of heroin, cocaine, and amphetamines [2]. Poisoning due to ingestion of a strychnine-containing rodenticide is also rare but sometimes it is abused for suicide attempts in Iran. Our patient had bought a glass of pure strychnine from a smuggler on the street. The lethal dose of strychnine noted to be as low as 20 mg. It is not only absorbed well by gastrointestinal tract, but it also may be absorbed

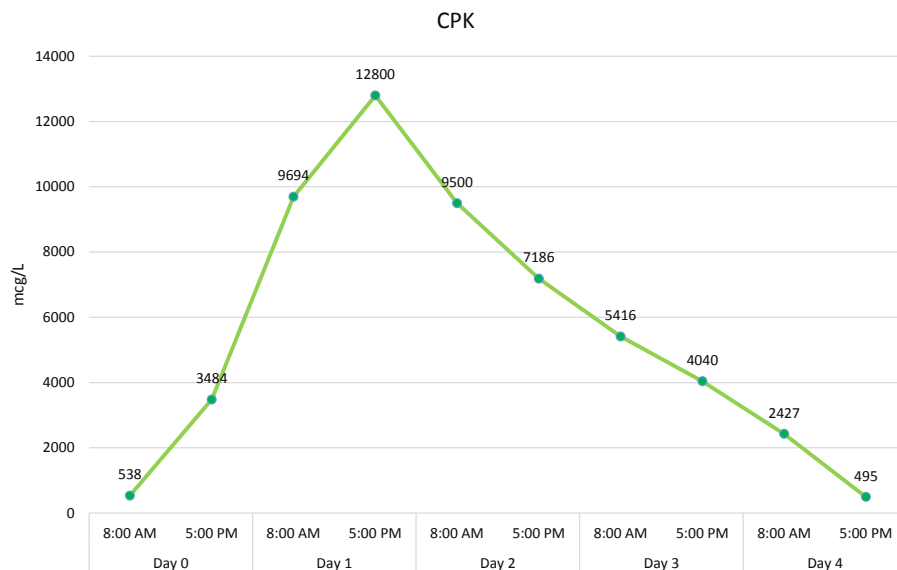


Figure 1. Trends in Creatine Phosphokinase (CPK) serum-level for patient during hospitalization in ICU and toxicology ward

from some other mucosal membranes such as conjunctiva and respiratory airways [3].

The absorption of strychnine is fast and after oral exposure, signs and symptoms may appear within 5-60 min; however, studies point that the presence of food in the stomach can delay the onset of symptoms. In our case, the first seizure occurred 30 minutes after ingestion, when he had been experiencing 9 episodes of convulsions during the first 12 hours of poisoning. In fact, he had generalized muscular spasms (tonic seizure) and simultaneously had open eyes with wakefulness. Strychnine competitively antagonizes the ventral horn of motor-neuron postsynaptic receptor sites for glycine; which is a major inhibitory neurotransmitter in the spinal cord. Strychnine also reduces the receptor's affinity for glycine and would induce a stimulant effect in the spinal cord and medulla [4].

Seizures related to strychnine characteristically have tonic contraction of skeletal muscles and intermittent tense muscular spasms (tonic seizure) that may present itself with lockjaw and sardonic smile. These symptoms and signs are the same as what we can see in tetanus but there was no proof of tetanus, so this differential diagnosis was also ruled out. Contraction of the respiratory muscles and or pharyngeal muscles may lead to respiratory failure or upper airway obstruction that will cause a need for tracheal intubation, as it was in our case, and the patient was finally put under mechanical ventilation.

One of the most life-threatening poisonings is strychnine poisoning so an early aggressive treatment of strychnine intoxication is mandatory. The most important aspect of managing this case is to focus on immediate cessation of the convulsions and securing the airways [5]. According to previous studies, benzodiazepines as the anticonvulsant drugs must be the first choice in the management of strychnine-induced muscular hyperactivity with repeated doses of IV diazepam 5-10 mg until the cessation of these hyperactivities [6]. However in cases of severe toxicity, a second line of therapy such as barbiturates and propofol must be used and when the muscular hyperactivities become refractory to such medications, use of anesthetics and intubation must be the last resort [7-9]. Kidneys function must be assessed carefully in order to prevent acute renal failure due to patient's massive rhabdomyolysis [10].

#### 4. Conclusion

Acute poisoning with strychnine is a dangerous toxicological emergency that may present itself as serial sei-

zures at ED. Early diagnosis can be life-saving in these cases. Poisoning by it should be kept in mind in every new case of seizure at ED with unknown origin, especially in patient with multiple awake convulsions, and in the presences of positive risk factors of suicidal attempts. A recurrent convulsion may need a prescription of very high doses of benzodiazepines. Some cases may be refractory to benzodiazepines and may need general anesthesia to control the seizures.

#### Ethical Considerations

##### Compliance with ethical guidelines

All procedures performed in this study were in accordance with the ethical standards of the institutional and national research committee and with the 1964 Helsinki Declaration. In addition, informed consent was obtained from the patient involved in this case report.

##### Funding

This research did not receive any specific grant from funding agencies in the public, commercial, or not-for-profit sectors.

##### Authors contributions

All authors contributed in preparing this article.

##### Conflict of interest

The authors declared no conflict of interest.

##### Acknowledgements

We appreciate Firoozgar Hospital authorities for their support and cooperative attitude.

#### References

- [1] Lindsey T, O'Hara J, Irvine R, Kerrigan S. Strychnine overdose following ingestion of gopher bait. *Journal of Analytical Toxicology*. 2004; 28(2):135-7. [DOI:10.1093/jat/28.2.135] [PMID]
- [2] Singhapricha T, Pomerleau AC. A case of strychnine poisoning from a southeast Asian herbal remedy. *The Journal of Emergency Medicine*. 2017; 52(4):493-5. [DOI:10.1016/j.jemermed.2016.10.007] [PMID]
- [3] Shadnia S, Moiensadat M, Abdollahi M. A case of acute strychnine poisoning. *Veterinary and Human Toxicology*. 2004; 46(2):76-9. [PMID]

- [4] Chan TY. Herbal medicine causing likely strychnine poisoning. *Human & Experimental Toxicology*. 2002; 21(8):467-8. [DOI:10.1191/0960327102ht259cr] [PMID]
- [5] Van Berlo-Van De Laar IR, Arbouw ME, Bles CM. [Strychnine poisoning: uncommon, but does still happen (Dutch)]. *Nederlands Tijdschrift voor Geneeskunde*. 2015; 159:A8877. [PMID]
- [6] Makarovsky I, Markel G, Hoffman A, Schein O, Brosh-Nissimov T, Tashma Z, et al. Strychnine-a killer from the past. *Israel Medical Association Journal*. 2008; 10(2):142-5. [PMID]
- [7] Wood DM, Webster E, Martinez D, Dargan PI, Jones AL. Case report: Survival after deliberate strychnine self-poisoning, with toxicokinetic data. *Critical Care*. 2002; 6(5):456-9. [DOI:10.1186/cc1549] [PMID] [PMCID]
- [8] Smith BA. Strychnine poisoning. *Journal of Emergency Medicine*. 1990; 8(3):321-5. [DOI:10.1016/0736-4679(90)90013-L]
- [9] Edmunds M, Sheehan TM, Van't Hoff W. Strychnine poisoning: Clinical and toxicological observations on a non-fatal case. *Journal of Toxicology: Clinical Toxicology*. 1986; 24(3):245-55. [DOI:10.3109/15563658608990462] [PMID]
- [10] Burn DJ, Tomson CR, Seviour J, Dale G. Strychnine poisoning as an unusual cause of convulsions. *Postgraduate Medical Journal*. 1989; 65(766):563-4. [DOI:10.1136/pgmj.65.766.563] [PMID] [PMCID]