

Prenatal Diagnosis and Management of a Fetus with Double Aortic Arch: A Case Report and Literature Review

Alireza Golbabaee¹, Mahsa Naemi², Maasoumeh Saleh^{3,*}

¹ Assistant Professor of Pediatric Cardiology, Department of Perinatology and fetal Cardiology, Shariati Hospital, Tehran University of Medical Sciences, Tehran, Iran

² Assistant Professor of Gynecology, Department of Obstetrics and Gynecology, Shariati Hospital, Tehran University of Medical Sciences, Tehran, Iran

³ Perinatology Fellowship, Department of Obstetrics and Gynecology, Shariati Hospital, Tehran University of Medical Sciences, Tehran, Iran

* Corresponding author: Maasoumeh Saleh, Perinatology Fellowship, Department of Obstetrics and Gynecology, Shariati Hospital, Tehran University of Medical Sciences, Tehran, Iran. E-mail: Salehmaasoumeh@yahoo.com

DOI: 10.29252/ijcp-32469

Submitted: 05-10-2020

Accepted: 29-12-2020

Keywords:

Double Aortic Arch
Echocardiography
Computed Tomography
Angiography

© 2020. International Journal
of Cardiovascular Practice.

Abstract

Double aortic arch is a congenital vascular abnormality in which the connected segments and their branches course between and compress the trachea and esophagus, often resulting in invariable airway compression and gastrointestinal presentations. A 2-month girl with a history of double aortic arch diagnosis in fetal echocardiography was admitted to our hospital with recurrent pneumonia. The double aortic arch was confirmed by computed tomography angiogram. After surgery, the patient was followed for one year of age and had no problem. Our study showed early diagnosis and treatment of a double aortic arch might prevent chronic, irreversible complications.

INTRODUCTION

The vascular ring, which comprises less than 1% of congenital heart disease (CHF), was first introduced by Gross in 1945 [1]. Congenital abnormalities of the aortic arch and its major branches result in vascular rings around the trachea and esophagus with varying degrees of compression [2]. Double aortic arch is the most frequent variation of this abnormality. In this type of anomaly, the ascending aorta is divided into the right and left-sided arch [3]. These connected segments and branches can compress the trachea and esophagus [4, 5].

These aberrations are the result of either abnormal persistence or involution of embryonic vascular segments. Clinically, these malformations can be asymptomatic in their detection, mostly when imaging is performed for some other reason. However, these can be symptomatic in the form of breathing or swallowing difficulties [2]. Its related signs and symptoms usually manifested within childhood and included cough, dyspnea, and upper respiratory infections. The diagnosis of this anomaly can be performed by echocardiography, computed tomography (CT scan),

or magnetic resonance imaging (MRI) [6, 7]. These malformations can be isolated or associated with other intra-cardiac and chromosomal defects. Imaging plays a significant role in detecting these anomalies and thus helps many inaccurate preoperative surgical decisions [2].

In severe symptomatic cases, bronchoscopy can be helpful to determine the degree of airway narrowing. In these subjects, surgery is recommended [8]. The double aortic arch diagnosis is typically made because of the symptoms caused by tracheal or esophageal compression. Children always present with cough, biphasic stridor, wheezing, recurrent respiratory infections, and dysphagia [9]. It is a case report of a patient with a double aortic arch presented with recurrent pneumonia.

CASE PRESENTATION

A 33-year-old pregnant woman at 32 weeks of gestation was referred for fetal echocardiography because of a history of a congenital cardiac anomaly in a previous child. The patient underwent a fetal cardiac ultrasound

that shows an isolated double aortic arch without any other fetus anomalies (Fig 1). No intervention was done

for the patient, and she followed by her fetal respiratory complication after birth with assurance.

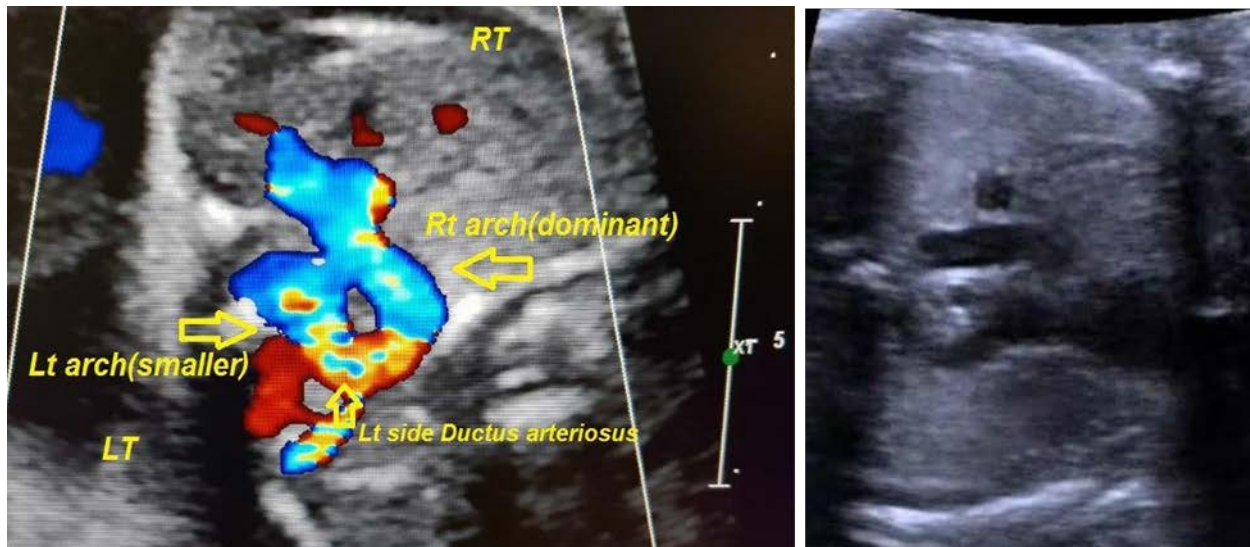


Figure 1. Left) The axial view shows a double aortic arch with a right-side dominant arch, a small left side arch, and a left side ductus arteriosus. Right) The same view in 2D echocardiography.

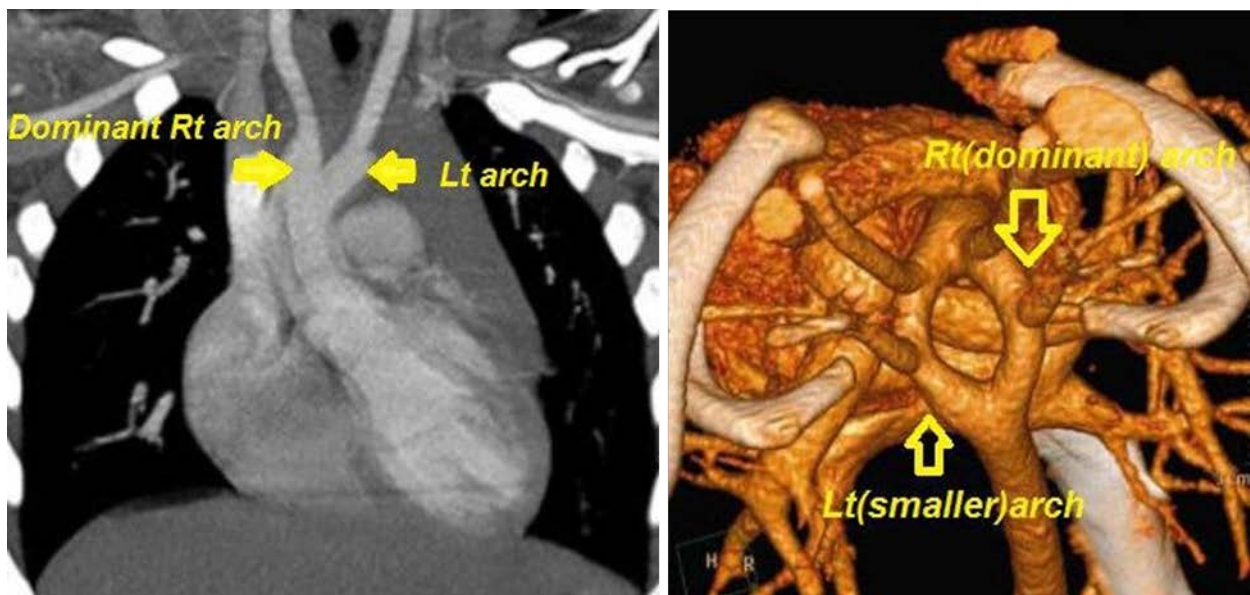


Figure 2. Left) CT angiography (frontal view) shows double aortic arch, right arch dominance, and smaller left arch. Right) Reconstructive CT angiography shows Right and left side aortic arch

The baby was born by expected delivery at 40 weeks of gestation. Her birth weight was 2750 grams. Clinical examination revealed that first and second heart sounds and lung auscultation were normal. She did not have cyanosis or wheezing. Echocardiography, after birth, confirmed the diagnosis. She also underwent CT angiography to validate the diagnosis (Fig 2). She had no signs or symptoms until the age of 3 months. At the age of three months, she presented with severe and frequent pneumonia and a surgery candidate. She had no post-surgical complications, and the procedure was successful. Post repair echocardiography showed a normal right side aortic arch with no apparent residual lesion from resected small left side aortic arch (Fig 3).

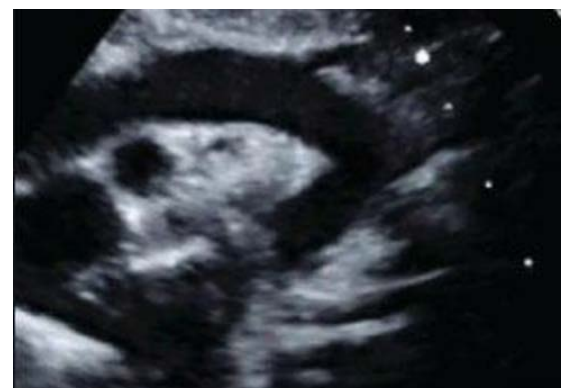

Figure 3. The post-repair echocardiography shows a normal right side aortic arch with no apparent residual lesion from resected small left side aortic arch.

We followed up with the patient for one year. She had a normal growth pattern and symptom-free without medication treatment.

DISCUSSION

One of the less common etiologies of pneumonia aspiration and dysphagia in younger children is vascular rings. Congenital abnormalities of the aortic arch and its main branches lead to vascular ring formation around the trachea and esophagus and apply different compression effects [10]. A double aortic arch constitutes a vascular ring when either the left and right fourth pharyngeal arcuate arteries originating from the aorta, or the eighth segment of the dorsal aorta, do not regress. Double aortic arch anomalies account for about 42% of vascular rings [11] and manifest in neonates and infants with respiratory symptoms, including respiratory distress and pneumonia aspiration and dysphagia. The right aortic arch is dominant in 80% of cases, the left aortic arch is prevalent in 10%, and the contribution is balanced by 10% [12]. We presented a case of the isolated double aortic arch with right-sided arch dominance and rare manifestation. Compared to other case reports and case series, the gastrointestinal symptoms are not usual, and most of the previously published cases are presented by respiratory manifestation.

The double aortic arch's diagnostic methods have evolved from chest radiography, esophagocardiogram, echocardiography, CT scan, and magnetic resonance imaging (MRI). Flexible bronchoscopy would be the first line of investigation for the patients typically present with respiratory symptoms. Typical compression of the trachea was visualized by bronchoscopy, which was indicated for respiratory. The nature of extramural obstruction would be best shown by a spiral CT scan, MRI, or color-coded three-dimensional [13]. Double aortic arch is usually found as an isolated cardiovascular malformation. Associated cardiac anomalies occurred only in eight patients (7%) in an extensive study of 113 patients with Double aortic arch [12]. They appeared in 14 patients (17%) in another study of 81 patients with Double aortic arch [14]. In our patient, no associated cardiac abnormality was noted.

As the diagnostic modalities for vascular rings, Backer et al. prefer CT imaging to magnetic resonance imaging (MRI). CT imaging gives a clearer picture of the tracheal anatomy and requires a shorter period to obtain than MRI. They recommend an ultrasound in all patients with a vascular ring because there is a 12% incidence of associated cardiac pathology [12]. Surgical repair is associated with no mortality in patients with a double aortic arch, and 0-1.3% of these patients required reoperation [11, 14]. Regarding this case, fetal echocardiography in suspicious pregnant women is necessary and following up, these patients after diagnosis should be considered.

CONCLUSION

A double aortic arch might lead to persistent nonspecific complaints to life-threatening respiratory signs or gastrointestinal complaints in infants. In these patients, the airway is precarious and complete cooperation between the pediatric cardiologist and cardiac surgeon is essential. Moreover, fetal echocardiography is necessary for patients with previous positive familial history of CHF.

Conflicts of Interest

None.

REFERENCES

1. Abbasi Tashnizi M, Joudi M, Izanloo A, Soltani G, Hasanazadeh R, Fathi M. Three Cases of a Rare Association: Double Aortic Arch. *Int J Pediatr*. 2016;4(2):1319-21.
2. Priya S, Thomas R, Nagpal P, Sharma A, Steigner M. Congenital anomalies of the aortic arch. *Cardiovasc Diagn Ther*. 2018;8(Suppl 1):S26-S44. doi: 10.21037/cdt.2017.10.15 pmid: 29850417
3. Uchida DA. Late presentation of double aortic arch in school-age children presumed to have asthma: the benefits of spirometry and examination of the flow-volume curve. *Respir Care*. 2009;54(10):1402-4. pmid: 19796421
4. Liang Y, Zhou Q, Chen Z. Double aortic arch with ascending aortic aneurysm and aortic valve regurgitation. *Ann Thorac Surg*. 2014;97(2):e43-5. doi: 10.1016/j.athoracsur.2013.09.111 pmid: 24484842
5. Santos FC, Croti UA, Marchi CH, Hassem Sobrinho S. Double Aortic Arch Associated with Pulmonary Atresia with Ventricular Septal Defect. *Braz J Cardiovasc Surg*. 2016;31(1):63-5. doi: 10.5935/1678-9741.20160008 pmid: 27074277
6. Seo HS, Park YH, Lee JH, Hur SC, Ko YJ, Park SY, et al. A case of balanced type double aortic arch diagnosed incidentally by transthoracic echocardiography in an asymptomatic adult patient. *J Cardiovasc Ultrasound*. 2011;19(3):163-6. doi: 10.4250/jcu.2011.19.3.163 pmid: 22073330
7. An HS, Choi EY, Kwon BS, Kim GB, Bae EJ, Noh CI, et al. Airway compression in children with congenital heart disease evaluated using computed tomography. *Ann Thorac Surg*. 2013;96(6):2192-7. doi: 10.1016/j.athoracsur.2013.07.016 pmid: 24070697
8. Svetanoff WJ, Zendejas B, Smithers CJ, Prabhu SP, Baird CW, Jennings RW, et al. Great vessel anomalies and their impact on the surgical treatment of tracheobronchomalacia. *J Pediatr Surg*. 2020;55(7):1302-8. doi: 10.1016/j.jpedsurg.2019.08.001 pmid: 31422856
9. Juraszek AL, Guleserian KJ. Common aortic arch anomalies: diagnosis and management. *Curr Treat Options Cardiovasc Med*. 2006;8(5):414-8. doi: 10.1007/s11936-006-0046-2 pmid: 16939680
10. Fogel MA, Pawlowski TW, Harris MA, Whitehead KK, Keller MS, Wilson J, et al. Comparison and usefulness of cardiac magnetic resonance versus computed tomography in infants six months of age or younger with aortic arch anomalies without deep sedation or anesthesia. *Am J Cardiol*. 2011;108(1):120-5. doi: 10.1016/j.amjcard.2011.03.008 pmid: 21679782
11. Backer CL, Monge MC, Popescu AR, Eltayeb OM, Rastatter JC, Rigsby CK. Vascular rings. *Semin Pediatr Surg*. 2016;25(3):165-75. doi: 10.1053/j.sempedsurg.2016.02.009 pmid: 27301603
12. Backer CL, Mavroudis C, Rigsby CK, Holinger LD. Trends in vascular ring surgery. *J Thorac Cardiovasc Surg*. 2005;129(6):1339-47. doi: 10.1016/j.jtcvs.2004.10.044 pmid: 15942575

13. Woods RK, Sharp RJ, Holcomb GW, 3rd, Snyder CL, Lofland GK, Ashcraft KW, et al. Vascular anomalies and tracheoesophageal compression: a single institution's 25-year experience. *Ann Thorac Surg.* 2001;72(2):434-8; discussion 8-9. **doi:** [10.1016/s0003-4975\(01\)02806-5](https://doi.org/10.1016/s0003-4975(01)02806-5) **pmid:** [11515879](https://pubmed.ncbi.nlm.nih.gov/11515879/)
14. Ruzmetov M, Vijay P, Rodefeld MD, Turrentine MW, Brown JW. Follow-up of surgical correction of aortic arch anomalies causing tracheoesophageal compression: a 38-year single institution experience. *J Pediatr Surg.* 2009;44(7):1328-32. **doi:** [10.1016/j.jpedsurg.2008.11.062](https://doi.org/10.1016/j.jpedsurg.2008.11.062) **pmid:** [19573656](https://pubmed.ncbi.nlm.nih.gov/19573656/)