

Rare Cor Triatrium Complications: Case Series

Machtache Rihab ^{1,*}, Drighil Abdenasser ¹

¹ Department of Cardiology, Ibn Rochd University Teaching Hospital, Hassan II University, Casablanca, Morocco

* Corresponding author: Machtache Rihab, Department of Cardiology, Ibn Rochd University Teaching Hospital, Hassan II University, Casablanca, Morocco. E-mail: rihabmachtache@hotmail.fr

DOI: 10.29252/ijcp-28467

Submitted: 02-01-2020

Accepted: 05-08-2020

Keywords:

cor triatrium

Pulmonary Embolism

Tricuspid Valve

© 2020. International Journal
of Cardiovascular Practice.

Abstract

Cor triatrium sinister is a congenital cardiac anomaly involving a fibromuscular membrane that divides even the left atrium or the right into two chambers. This abnormality has been reported in only 0.1% to 0.4% of patients with congenital heart disease. Most patients are diagnosed with the condition in infancy or childhood; adult cases are rare. We describe three rare complications of cor triatrium. The first case is about pulmonary embolism complicating a cor triatrium dextran in a 44-year-old man, which has never been reported, at least to the best of our knowledge. He underwent curative resection of the membrane and was asymptomatic after that. The second case is about sudden death on a cor triatrium sinistrum 9-month-old infant. The last one is an about 45-year-old male patient admitted with atrial fibrillation revealing cor triatrium.

INTRODUCTION

Cor triatrium (or triatrial heart) is defined as a congenital heart anomaly where the left atrium (cor triatrium sinistrum) or the right atrium (cor triatrium dextrum) is subdivided by a membrane, leading to three atrial chambers. Its frequency is rare between all congenital cardiac malformations and may be associated with other cardiac defects in half of the cases.

Most cases present during infancy, but some others remain asymptomatic until a late age, and their diagnosis might be missed. Clinically both infant and adult patients present mostly with symptom mimicking mitral stenosis due to the obstructive intra atrial membrane. There is only a few reports of complications related to the cor triatrium. We report three cases of cor triatrium complications that remain rare.

CASES PRESENTATION

First Case

The first case is a pulmonary embolism complicating a cor triatrium dextrum. A 44-year-old Moroccan patient suffering from dyspnea was admitted to our tertiary care hospital. He had no previous medical history at the time of hospitalization.

A computed tomography angiogram was performed and revealed pulmonary trunk dilatation with a large thrombus in the right pulmonary artery and a small thrombus in the right interlobar artery. An

anticoagulation treatment was started. The transthoracic echocardiography was performed to stratify the patient's risk and showed a presence of a relatively stenosing perforated membrane with a mean gradient at four mmHg with a minimal tricuspid leak with systemic pulmonary artery pressure at 31mmHg associated with a thrombus lining the lateral wall of the right atrium. A magnetic resonance imaging was realized to describe this lesion better [Fig 1A, 1B]. The patient had benefited from intra right atrial membrane and thrombus resection

Second Case

The second case is sudden death on a patient with a cor triatrium sinistrum. We received in our unit of a 9-month-old infant from a non-consanguineous marriage, with fatigability during feedings physical examination. The case showed typical facies, sternal protrusion, 96 percent of oxygen saturation, weight 9kg, diastolic murmur 3/6, peripheral pulses perceived and symmetrical, and no sign of heart failure.

Echocardiography showed cor triatrium sinistrum with severe obstruction, dilated pulmonary veins draining into a posterosuperior chamber that opens through a small orifice in the left atrium with a mean gradient at 29 mmHg, right ventricular hypertrophy with conserved function, minimal tricuspid insufficiency to estimate systemic pulmonary artery pressure at 120 mm hg and no interatrial communication or interventricular

communication or persistence of the atrial canal [Fig 2, 3, 4]. The patient was referred to a cardiothoracic

surgeon for excision of the membrane but unfortunately died before the operation.

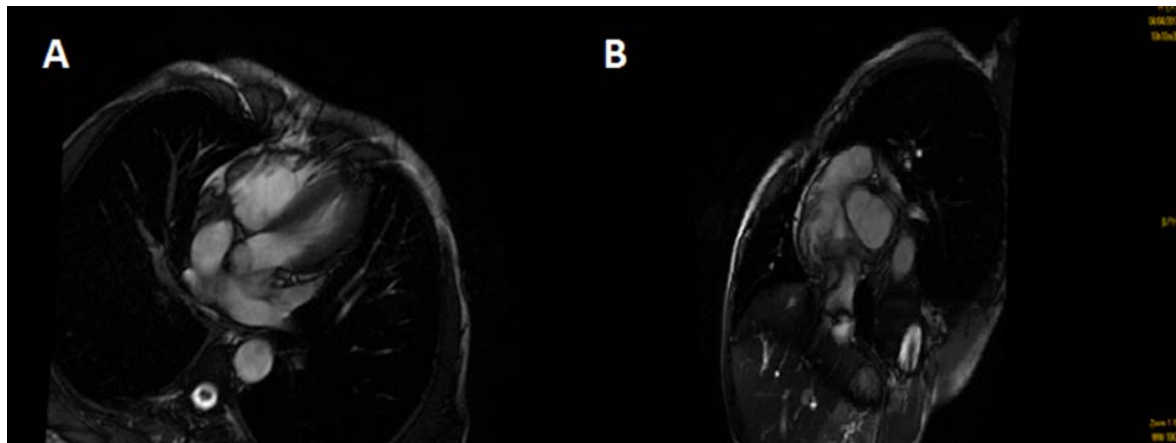


Figure 1. A, B: MRI objectifying Cor Triatrium

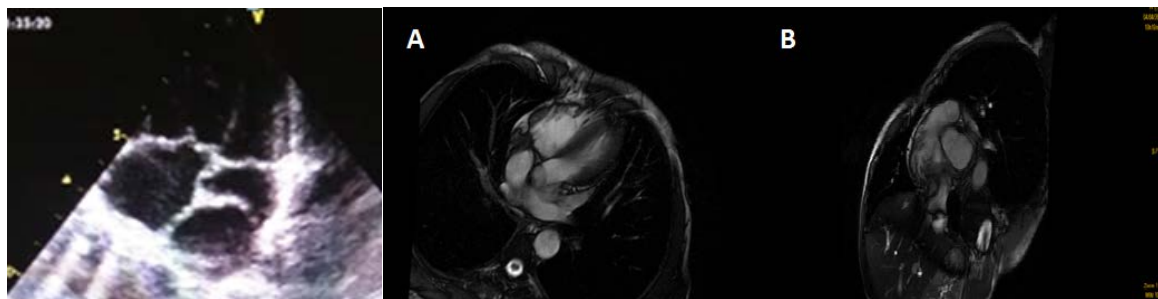


Figure 2. Transthoracic echocardiogram (apical 4-chamber view) shows a membranous structure subdividing the left atrium

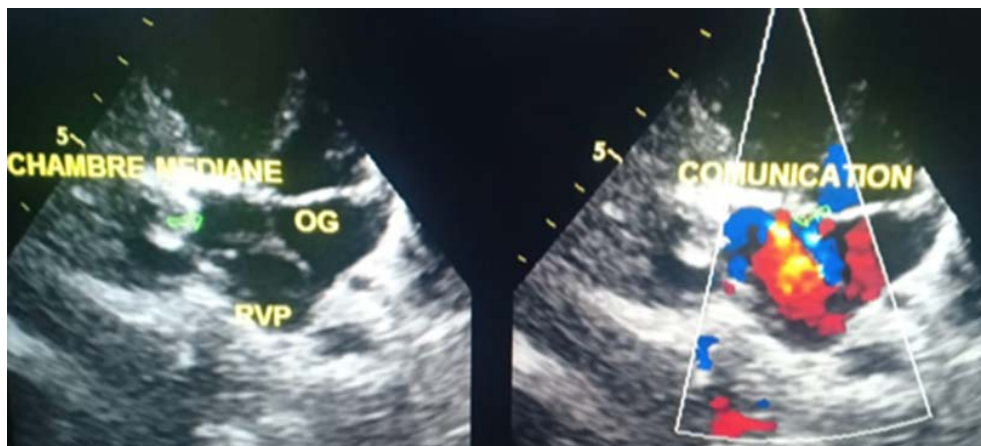


Figure 3. Transthoracic echocardiography: Apical section showing a triatrial sinistum heart with a severe obstruction between the pulmonary veins and the left atrium in color Doppler (OG: Left ventricle, RVP: pulmonary venous return)

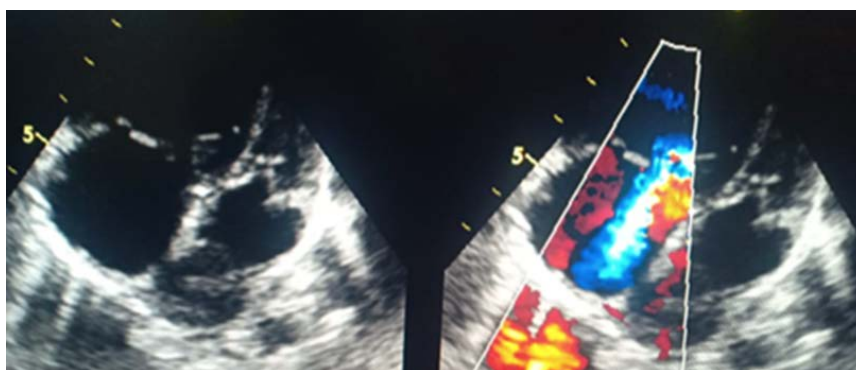


Figure 4. Transthoracic echocardiography: apical section with color doppler showing a flow of pulmonary insufficiency with dilation of the right cavities

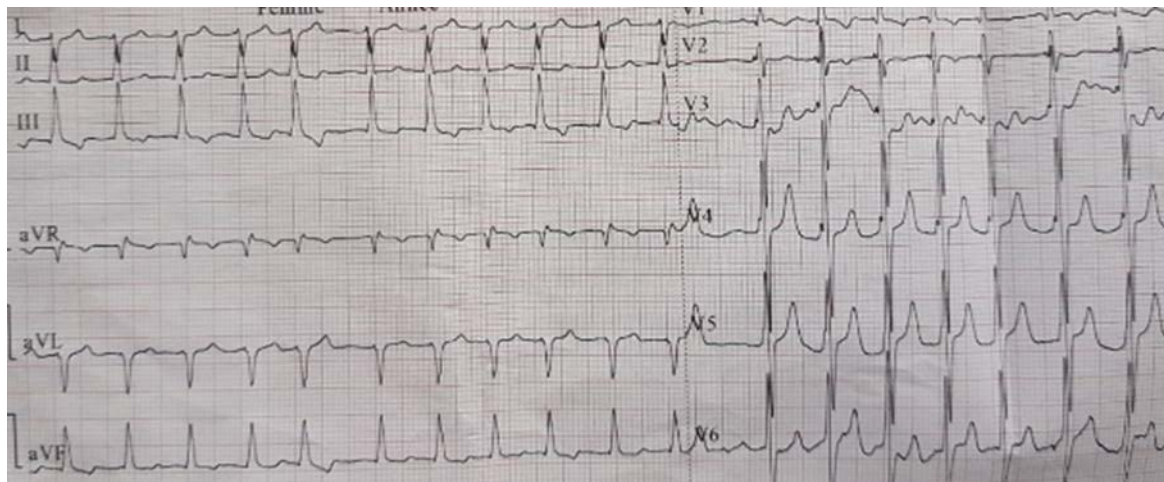


Figure 5. Electrocardiography revealed Atrial Fibrillation

Third Case

The third case was atrial fibrillation on an adult male patient with cor triatrium sinistrum. A 45-year-old male patient with no personal or family history of cardiac diseases admitted with atrial fibrillation [Fig 5]. His heart rate was irregular, about 140 bpm, blood pressure about 134/77 mmHg. Clinical exam and chest x-ray have shown pulmonary edema. Transthoracic echocardiogram demonstrated a dilated left atrium with cor triatriatum sinister. Continuous-wave Doppler showed continuous flow across the membrane with a mean gradient of 5 mmHg. The left ventricle was dilated, and the ejection fraction was 48%.

We discussed acute and long-term management of AF and anticoagulation in the setting of cor triatriatum. The patient remained hemodynamically stable, and medical treatment was started. Based on the gradients across the membrane, the obstruction was considered not severe. The patient was discharged with a follow-up in our cardiac unity.

DISCUSSION

Cor triatrium is a rare congenital anomaly (incidence 0.1 to 0.4%) [1, 2], which is described as an imperforated diaphragm or with a small fenestration that divides the atrium into two chambers. The causes of this affection are still not established. The three main embryological theories described are malseptation, entrapment, and misincorporation [3, 4].

Cor triatriatum most commonly manifests itself in childhood or infancy, but in some rare cases, it appears later and discovered in adulthood. The most common symptoms present in adults are respiratory symptoms, dyspnea, hemoptysis [5]. The syncope has been reported but is not typically associated with cor triatriatum. Heart failure can be the first presentation on the same undiagnosed patients.

The transthoracic echography remains the main mean of diagnosis of cor triatrium; it allows to differentiate it from its principal differential diagnosis, which is mitral stenosis. Magnetic resonance imaging is now considered as a gold standard for anatomical

characterization and helps to hemodynamic understanding [6].

Cor triatriatum is frequently associated with other cardiac abnormalities [7]. In adults, the most common abnormalities associated with cor triatriatum are mitral regurgitation, atrial septal defect, and the presence of left superior vena cava with unroofed coronary sinus. Less common associated abnormalities include an anomalous partial pulmonary venous connection. Here we present three cases about sudden death, a case about atrial fibrillation, and another rare case about pulmonary embolism on cor triatrium in adults.

Complications related to this type of membrane can be multiple: those directly related to the Obstructive character of the membrane (hypertension pulmonary artery, right heart failure), those related to secondary consequences on the valve mitral, and finally, those related to associations with other malformations (CIA, etc.). Finally, late complications are also to be feared, such than sinus tachycardias, fibrillations auricular, thrombogenic risks.

The primary treatment described in the literature is a surgical correction, but some successful balloon catheter dilatation may lead to some functional changes. The severity of obstructive symptoms should undergo fast surgical correction [8]. Reported long terms to the result of surgery are excellent with a useful life expectancy [9]. The most-reported deaths are due to complex associated anomalies for both classic and atypical cor triatrium.

CONCLUSION

Because exact diagnosis and surgical treatment is feasible, we suggest that a cor triatriatum is a rare but potentially treatable source of embolism in adult patients. Actual investigations such as transesophageal echocardiography, computed tomography, and magnetic resonance imaging would increase in the reported frequency of cor triatriatum. A multidisciplinary team approach, including a referring cardiologist, ultrasonographer, operating surgeon, and

anesthesiologist, is needed for successful cardiac surgery.

INTEREST CONFLICT

None

REFERENCES

1. Kacnelonen R, Decoodt P. Biplane transesophageal echocardiographic diagnosis of cor triatriatum. *Chest*. 1994;105(2):601-2. [doi: 10.1378/chest.105.2.601](#) [pmid: 8306771](#)
2. Krasemann Z, Scheld HH, Tjan TD, Krasemann T. Cor triatriatum: short review of the literature upon ten new cases. *Herz*. 2007;32(6):506-10. [doi: 10.1007/s00059-007-2882-6](#) [pmid: 17882376](#)
3. Fowler J. Membranous band in the left auricle. *Trans Pathol Soc Lond*. 1881;33:74-94.
4. Gharagozloo F, Bulkley BH, Hutchins GM. A proposed pathogenesis of cor triatriatum: impingement of the left superior vena cava on the developing left atrium. *Am Heart J*. 1977;94(5):618-26. [doi: 10.1016/s0002-8703\(77\)80132-4](#) [pmid: 910700](#)
5. Niwayama G. Cor triatriatum. *Am Heart J*. 1960;59:291-317. [doi: 10.1016/0002-8703\(60\)90287-8](#) [pmid: 14427395](#)
6. Sakamoto I, Matsunaga N, Hayashi K, Ogawa Y, Fukui J. Cine-magnetic resonance imaging of cor triatriatum. *Chest*. 1994;106(5):1586-9. [doi: 10.1378/chest.106.5.1586](#) [pmid: 7956425](#)
7. Oglietti J, Cooley DA, Izquierdo JP, Ventemiglia R, Muasher I, Hallman GL, et al. Cor triatriatum: operative results in 25 patients. *Ann Thorac Surg*. 1983;35(4):415-20. [doi: 10.1016/s0003-4975\(10\)61594-9](#) [pmid: 6188419](#)
8. van Son JA, Danielson GK, Schaff HV, Puga FJ, Seward JB, Hagler DJ, et al. Cor triatriatum: diagnosis, operative approach, and late results. *Mayo Clin Proc*. 1993;68(9):854-9. [doi: 10.1016/s0025-6196\(12\)60693-4](#) [pmid: 8371603](#)
9. Arciniegas E, Farooki ZQ, Hakimi M, Perry BL, Green EW. Surgical treatment of cor triatriatum. *Ann Thorac Surg*. 1981;32(6):571-7. [doi: 10.1016/s0003-4975\(10\)61801-2](#) [pmid: 7316591](#)