IEJ
Iranian Endodontic Journal

Clinical and Radiographic Outcomes of Protooth versus MTA, TheraCal, and Ferric Sulfate in Primary Molar Pulpotomy: A Randomized Controlled Trial

Shirin Hassanpour[a], **Ali Vafaei**[a], **Zeinab Torab**[a], **Leila Vahedi**[b], **Parviz Hassanpour**[c], **Leila Erfanparast**[a*]

a Department of Pediatric Dentistry, Faculty of Dentistry, Tabriz University of Medical Sciences, Tabriz, Iran; b Road Traffic Injury Research Center, Tabriz University of Medical Sciences, Tabriz, Iran; c Department of Parasitology and Mycology, School of Public Health, Tehran University of Medical Sciences, Tehran, Iran

Article Type: **Clinical Trial**

Received: 12 Sep 2026
Accepted: 02 Nov 2026
Published: 24 Nov 2026
Doi: *10.22037/iej.v21i1.53131*

***Corresponding author**: Leila Erfanparast, Department of Pediatric Dentistry, Faculty of Dentistry, Tabriz University of Medical Sciences, Tabriz, Iran.

E-mail: leilaerfanparast28@gmail.com

Abstract

Introduction: Pulpotomy is a commonly performed vital pulp therapy for maintaining primary molars with carious pulp exposure. This randomized controlled/clinical trial compared the clinical and radiographic outcomes of four pulpotomy protocols: Angelus mineral trioxide aggregate (MTA), Protooth, TheraCal, and ferric sulfate (FS). **Materials and Methods:** One hundred children aged 4–8 years with deep carious primary molars requiring pulpotomy were randomly allocated to four groups (n=25 each). Standardized pulpotomy protocols were followed, with stainless steel crown restorations. An examiner blinded to treatment allocation assessed outcomes at 6 and 12 months. Radiographic success was the primary outcome, clinical success was secondary, and overall treatment success was an additional composite outcome. Available-case analysis was performed, with a sensitivity analysis classifying all missing 12-month outcomes as failures. **Results:** Ninety-nine participants were evaluated at 6 months and 92 at 12 months; eight participants lacked a 12-month assessment. At 6 months, clinical success was 100%, 100%, 96.0%, and 100% in the MTA, Protooth, TheraCal, and FS groups, respectively; radiographic success was 96.0%, 92.0%, 92.0%, and 91.7%, respectively. At 12 months, clinical success was 100% (24/24), 95.6% (22/23), 95.8% (23/24), and 100% (21/21), and radiographic success was 95.8% (23/24), 91.3% (21/23), 91.7% (22/24), and 90.5% (19/21) in the MTA, Protooth, TheraCal, and FS groups, respectively. No statistically significant between-group differences were detected in clinical or radiographic success at either follow-up assessment. Overall treatment success, an additional composite outcome, was 92.4% (85/92) at 12 months. Radiographic failures were more frequent than clinical failures across treatment groups. **Conclusion:** All four protocols demonstrated high observed clinical and radiographic success rates over 12 months. Protooth showed favorable outcomes, providing preliminary clinical evidence for further evaluation. However, these findings do not establish equivalence, non-inferiority, or comparable effectiveness. Larger, adequately powered randomized trials with longer follow-up are warranted.

Keywords: Ferric Sulfate; Mineral Trioxide Aggregate; Primary Molars; Protooth, TheraCal; Pulpotomy

Introduction

Dental caries is the most common chronic disease in children, frequently leading to pulpal involvement of primary molars if untreated [1, 2]. The preservation of primary teeth until their natural exfoliation is essential to maintain arch integrity, proper mastication, phonetics, and guidance of erupting permanent successors. When the radicular pulp remains vital after carious exposure, pulpotomy is the preferred treatment, aiming to remove the inflamed coronal pulp while preserving the vitality of the radicular tissue [3-5]. The success of pulpotomy depends on accurate diagnosis, meticulous technique, and the biological compatibility of the medicament applied to the pulp stump [6, 7]. Previous randomized clinical studies published in the Iranian Endodontic Journal have similarly emphasized the importance of evaluating both clinical and radiographic outcomes when comparing pulpotomy techniques in primary molars [8].

This open-access article has been distributed under the Creative Commons Attribution-NonCommercial-ShareAlike 4.0 International (CC BY-NC-SA 4.0).

Formocresol has long been regarded as the standard pulpotomy agent; however, its potential mutagenicity, cytotoxicity, and systemic distribution have raised safety concerns, leading to the exploration of more biocompatible alternatives [9-11] Ferric sulfate (FS) acts as a hemostatic agent, forming a protein clot over the pulp tissue. Although it provides acceptable short-term success, internal root resorption and variable radiographic stability remain its limitations [12]. Previous randomized clinical trials have also compared FS with other pulpotomy approaches in primary molars using both clinical and radiographic outcomes, supporting the need for radiographic follow-up when assessing its performance [13]. Mineral trioxide aggregate (MTA) is a calcium silicate-based material [14] recognized as the gold standard due to its biocompatibility, superior sealing ability, and ability to induce hard tissue barrier formation through cytokine stimulation [15-18]. MTA also promotes odontoblastic differentiation and dentinogenesis, ensuring functional regeneration of the pulp-dentin complex [19].

Clinical and radiographic studies have reported favorable outcomes following MTA pulpotomy in primary molars, including follow-up extending to 30 months [20]. Nevertheless, its drawbacks include long setting time, handling difficulties, potential discoloration, and high cost [21, 22]. TheraCal, a light-cured resin-modified calcium silicate material, was introduced to overcome some limitations of MTA. It releases calcium ions, stimulates secondary dentin formation, and demonstrates antibacterial and alkaline effects on the pulp tissue [23, 24]. Its advantages include ease of application and immediate setting, but concerns remain regarding the cytotoxicity of unpolymerized resin components and variable long-term radiographic outcomes [25]. Protooth, a novel fast-setting calcium silicate cement, has been developed as a bioactive material for vital pulp therapy. It has been reported to possess favorable sealing and biological characteristics, including calcium-ion release and potential stimulation of hard-tissue formation [26]. The bioactivity, biocompatibility, ion-release characteristics, and apatite-forming potential of calcium-silicate-based materials have been investigated extensively [27]. Despite these promising characteristics, clinical evidence regarding its long-term performance in primary molar pulpotomy remains limited, and direct comparisons with established materials are scarce. Recent clinical trials have reported encouraging outcomes with Protooth [28]; however, high-quality randomized controlled trials specifically evaluating Protooth in primary molar pulpotomy remain limited. Comparative clinical and radiographic evaluations are therefore important for determining its short- and medium-term clinical performance in relation to established pulpotomy materials. Therefore, the present randomized controlled trial aimed to compare the clinical and radiographic outcomes of four pulpotomy treatment protocols Protooth, MTA, TheraCal, and FS) in primary molars over 12 months. The study was planned as a randomized four-group clinical comparison; however, the original documentation required to verify the prespecified sample-size assumptions was unavailable. Fig. 1 illustrates the overall design and workflow of the present randomized controlled trial, including patient allocation, intervention protocols, follow-up periods, and outcome assessment procedures.

Materials and Methods

Study design and ethical approval

This randomized controlled trial was conducted at the Department of Pediatric Dentistry, Faculty of Dentistry, Tabriz University of Medical Sciences. Participant recruitment took place from January 19 to February 27, 2025. Clinical and radiographic outcomes were scheduled for assessment at 6 and 12 months after treatment. The study was approved by the Ethics Committee of Tabriz University of Medical Sciences (Approval No. IR.TBZMED.DENTISTRY.REC.1403.016) and was conducted in accordance with the Declaration of Helsinki. Written informed consent was obtained from the parents or legal guardians of all participants before enrollment. The trial was prospectively registered with the Iranian Registry of Clinical Trials (IRCT; Registration No. IRCT20100125003168N8, Available at https://fa.irct.ir/) on December 15, 2024.

Study participants and eligibility criteria

The study included 100 children aged 4–8 years who attended the Department of Pediatric Dentistry, Faculty of Dentistry, Tabriz University of Medical Sciences, for routine dental treatment and presented with deep carious primary molars indicated for pulpotomy. To ensure independence of observations and avoid intra-subject clustering, eligibility was restricted to one primary molar per child; when multiple teeth met the inclusion criteria, only one tooth per participant was selected for treatment and follow-up. The inclusion criteria were: (a) written informed consent from parents or legal guardians; (b) children aged 4–8 years in good general physical and mental health; (c) deep carious lesions with potential pulp exposure in primary molars; (d) clinically and radiographically healthy periodontium and periapical tissues (absence of pathological mobility, spontaneous pain, redness or swelling of the gingiva, draining sinus tract, tenderness to percussion, periodontal ligament widening, internal or external root resorption, or furcal/periapical radiolucency); (e) no systemic diseases or medical history

This open-access article has been distributed under the Creative Commons Attribution-NonCommercial-ShareAlike 4.0 International (CC BY-NC-SA 4.0).

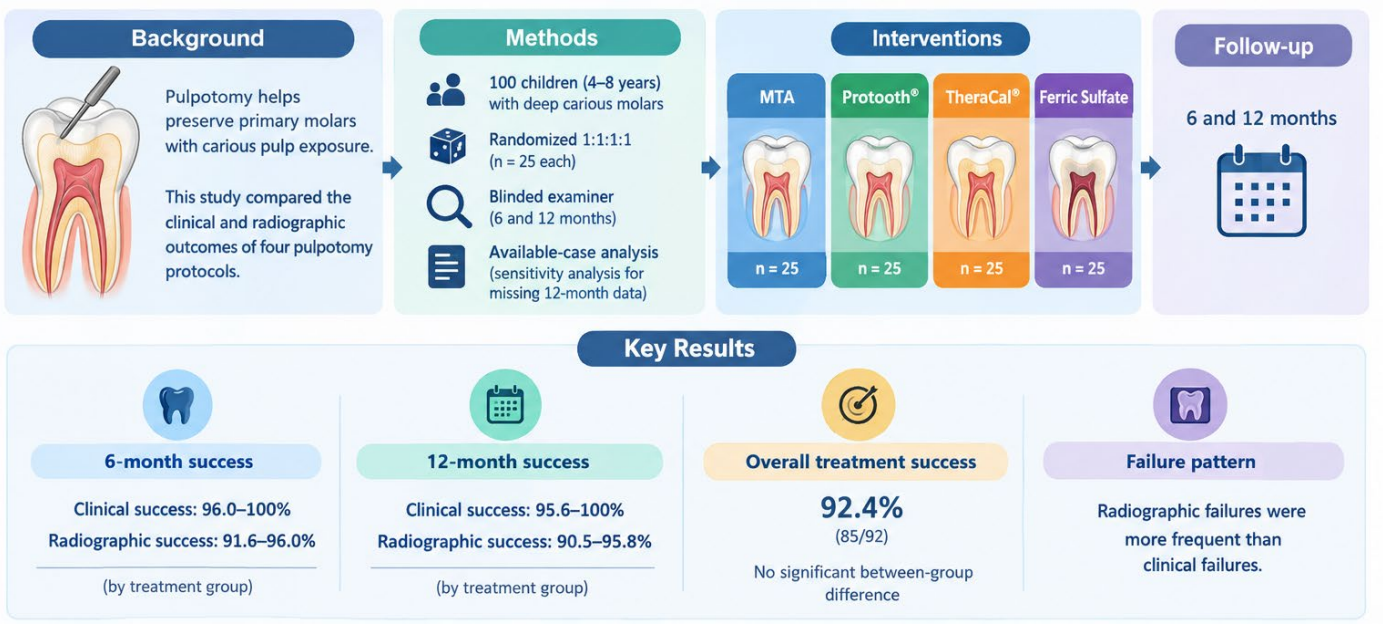

Figure 1. Overview of the randomized controlled trial comparing the clinical and radiographic efficacy of four pulpotomy medicaments (Angelus MTA, Protooth, TheraCal, and ferric sulfate) in primary molars over 6- and 12-month follow-ups

affecting pulp physiology; (f) no history of dental trauma or allergies. All parents/legal guardians signed a written informed consent form before participation and were informed about the study procedures, possible risks, discomforts, and expected benefits. They also agreed to comply with scheduled follow-up visits at 6 and 12 months after treatment. Participants had the right to withdraw from the study at any stage of the research by notifying the research team.

Randomization, allocation concealment, and blinding

Participants were randomly assigned to four groups using a computer-generated randomization sequence with a block size of 4. The randomization sequence was generated before patient enrollment. Allocation concealment was achieved using sequentially numbered, sealed envelopes. The available trial protocol describes 100 numbered envelopes containing randomly arranged assignments to groups A–D, with 25 participants planned for each group; however, the protocol does not explicitly specify the block size. The reported block size of four reflects the procedure used in the trial. The available documentation did not permit independent verification of the identities of the individuals responsible for sequence generation and envelope preparation; therefore, no specific individual is identified as responsible for these procedures. The envelopes were opened only at the time of intervention. The randomization process was conducted to ensure balanced group allocation and minimize selection bias. Although the trial was registered as double-blind, the operator could not be blinded because of the visible differences in material handling and application. The outcome assessor was blinded to treatment allocation; further details of the blinding procedures and their limitations are provided in Section 2.4.

Outcome assessor and blinding

Due to the nature of the interventions, blinding of the operator was not feasible. Clinical and radiographic outcome assessments were performed independently by an examiner who was not involved in the treatment procedures and was blinded to treatment allocation. Radiographs were identified using study codes rather than treatment-group labels, and the examiner did not have access to the randomization list during outcome assessment. Standardized and predefined clinical and radiographic criteria were used for all follow-up assessments. A formal calibration exercise and prospective intra-examiner reliability assessment using a statistical agreement coefficient such as Cohen's kappa were not performed. Although the examiner was blinded to treatment allocation, complete masking could not be guaranteed because some pulpotomy materials may have distinctive radiographic appearances. Thus, the blinding procedures were intended to minimize detection bias, although the possibility of inferring treatment allocation from radiographic characteristics could not be excluded.

Sample size calculation

The original sample-size calculation was performed during the initial planning of the study; however, the underlying

This open-access article has been distributed under the Creative Commons Attribution-NonCommercial-ShareAlike 4.0 International (CC BY-NC-SA 4.0).

computational record, including the software output and complete statistical assumptions, was not retained and is no longer available. Consequently, the original calculation cannot be reliably reconstructed retrospectively without introducing assumptions that were not documented at the time of study planning. We therefore do not report a reconstructed sample-size formula or post-hoc power calculation. The study ultimately enrolled and randomized 100 participants, with 25 participants allocated to each of the four treatment groups, according to the approved study plan. Given the absence of verifiable sample-size assumptions and the small number of observed treatment failures, the present study has limited statistical precision. It was designed as a randomized clinical comparison of four treatment protocols, not as an equivalence or non-inferiority trial, and therefore cannot establish equivalence or non-inferiority between the treatment protocols. The limitation related to the unavailable original sample-size documentation is acknowledged in the Discussion.

Clinical procedures and interventions

All pulpotomies were performed in a single visit by a postgraduate pediatric dentistry student under specialist supervision, following a standardized protocol. Local anesthesia with 2% lidocaine containing 1:80,000 epinephrine (DarouPakhsh, Tehran, Iran) was administered. Isolation was achieved using either a rubber dam or cotton rolls according to clinical circumstances. This pragmatic variation represents a potential source of procedural heterogeneity and was considered when interpreting the findings. The operative field was disinfected with 1% sodium hypochlorite. Caries removal was performed with a high-speed fissure bur under water spray, followed by low-speed carbide burs for complete excavation. The pulp chamber roof was removed with a diamond bur, and coronal pulp tissue was extirpated using a sharp spoon excavator. The pulp chamber was irrigated with 2.5% sodium hypochlorite followed by 0.2% chlorhexidine, and hemostasis was achieved with gentle pressure of a saline-moistened sterile cotton pellet [29, 30]. The assigned pulpotomy material was then applied according to the respective clinical protocol: MTA group (MTA Angelus, Londrina, Brazil) was placed in a 2-mm thickness over the pulp stumps and covered with a light-cured glass ionomer liner (Fuji II LC, GC, Tokyo, Japan) [31, 32]. Protooth group (Dentosolve, Aarhus, Denmark) was prepared according to the manufacturer's instructions, applied in a 2-mm thickness, and covered with a moist cotton pellet for 3 min to allow initial setting [33]. TheraCal group (BISCO, Schaumburg, IL, USA) was applied in a 1-mm layer directly over the pulp tissue and light-cured for 20 sec [23, 32]. FS group: A cotton pellet soaked in 15.5% FS solution (Ultradent Products, South Jordan, UT, USA) was placed for 15 sec and subsequently rinsed with saline. After hemostasis was confirmed, a zinc oxide eugenol base (Zonalin, Kemdent, UK) was applied) [34]. All teeth were finally restored with stainless steel crowns (3M ESPE, St. Paul, MN, USA). Immediate postoperative periapical radiographs were obtained and served as baseline reference images for subsequent follow-up assessments. Because the four materials were applied according to their respective clinical protocols, including differences in material thickness, setting procedures, and associated liners or bases, the present study should be interpreted as a comparison of four clinical treatment protocols rather than a comparison of the intrinsic properties of the materials under identical experimental conditions.

Clinical and radiographic evaluation

Clinical and radiographic assessments were performed at baseline and at 6- and 12-month follow-up visits. Clinical success was defined as the absence of spontaneous or persistent pain, swelling, sinus tract, tenderness to percussion, and pathological mobility. Radiographic success was defined as the absence of periodontal ligament widening, internal or external root resorption, and furcal or periapical radiolucency. Overall treatment failure was defined as the presence of at least one predefined clinical or radiographic failure criterion. Accordingly, a tooth was considered an overall failure if either a clinical or a radiographic failure criterion was present. When clinical and radiographic findings occurred in the same tooth, that tooth was counted only once as an overall failure**.** Standardized periapical radiographs were obtained at follow-up using the same radiographic equipment and exposure parameters. Clinical findings were recorded on structured case report forms, and radiographic findings were recorded using the predefined diagnostic criteria.

Statistical analysis

Data were analyzed using SPSS version 26.0 (IBM Corp., Armonk, NY, USA). The individual child, with one treated tooth per child, was considered the unit of analysis. Continuous variables were summarized as means and standard deviations, and categorical variables as frequencies and percentages. Baseline characteristics were described by treatment group without formal hypothesis testing, consistent with the randomized study design. Clinical, radiographic, and overall treatment success were assessed at 6 and 12 months. Radiographic success at 6 and 12 months was the primary outcome, clinical success was a secondary outcome, and overall treatment success was evaluated as an additional composite outcome. Analyses were based on available outcome data at each follow-up visit; participants without an assessment were excluded from the denominator and were not classified as treatment failures. Missing 12-month outcomes were not imputed, and a conventional intention-to-treat analysis was not performed. Eight of 100 randomized participants lacked a 12-month assessment, and because the reasons for missing data

This open-access article has been distributed under the Creative Commons Attribution-NonCommercial-ShareAlike 4.0 International (CC BY-NC-SA 4.0).

were not systematically recorded and losses were not evenly distributed across groups, the potential for attrition bias was considered when interpreting the results. Success proportions were reported with exact 95% confidence intervals (Clopper–Pearson) for the clinical, radiographic, and overall treatment outcomes. Absolute risk differences and risk ratios were calculated for Protooth, TheraCal, and FS using MTA as the reference category, with confidence intervals estimated using the Newcombe and score-based methods, respectively. Because only seven unique overall failures occurred and assessments were limited to scheduled 6- and 12-month visits, survival and cure-model analyses were not considered sufficiently reliable and were therefore not performed. A two-sided *P*-value<0.05 was considered statistically significant.

Results

Participant flow and baseline characteristics

A total of 100 children, each contributing one treated primary molar, were enrolled and randomly allocated to four treatment groups: MTA, Protooth, TheraCal, and FS, with 25 participants in each group. The study population comprised 58 girls and 42 boys, with a mean age of 6.4±1.05 years. Baseline demographic and clinical characteristics are presented descriptively in Table 1. The mean age was 6.65±1.05 years in the MTA group, 6.4±1.05 years in the Protooth group, 6.9±1.05 years in the TheraCal group, and 5.8±1.05 years in the FS group.

The distributions of gender, tooth type, dental arch, and type of anesthesia are also presented by treatment group. No formal hypothesis testing was performed to assess baseline comparability, and baseline characteristics were not used to select covariates for adjustment.

Of the 100 randomized participants, 99 were available for the 6-month assessment and 92 for the 12-month assessment. The number of participants without a 12-month assessment was one in the MTA group (4.0%), two in the Protooth group (8.0%), one in the TheraCal group (4.0%), and four in the FS group (16.0%). Thus, loss to follow-up was not evenly distributed across treatment groups. The reasons for the missing 12-month assessments were not systematically recorded; therefore, the possibility of attrition bias could not be excluded. The available-case analysis at each follow-up included only participants who completed that assessment; participants without a 12-month assessment were not classified as treatment failures. No adverse events related to the pulpotomy procedures or materials were reported during the follow-up period. The participant flow is presented in the CONSORT flow diagram (Fig. 2).

Clinical and radiographic outcomes

Clinical and radiographic outcomes at 6 and 12 months are summarized in Table 2. In accordance with the trial registration, radiographic success at 6 and 12 months was the primary outcome, whereas clinical success was a secondary outcome. Overall treatment success was evaluated as an additional composite outcome. Percentages were calculated using the number of participants assessed at each respective follow-up visit. At 6 months, 98 of 99 assessed participants (98.9%) demonstrated clinical success, while 92 of 99 (92.9%) demonstrated radiographic success. Clinical success was observed in 25/25 participants (100%) in the MTA group, 25/25 (100%) in the Protooth group, 24/25 (96.0%) in the TheraCal group, and 24/24 (100%) in the FS group. Radiographic success was observed in 24/25 (96.0%), 23/25 (92.0%), 23/25 (92.0%), and 22/24 (91.7%) participants in the MTA, Protooth, TheraCal, and FS groups, respectively. No statistically significant between-group difference was detected in clinical or radiographic success at 6 months (*P*=0.30 and *P*=0.90, respectively). At 12 months, 90 of 92 assessed participants (97.8%) demonstrated clinical success, whereas 85 of 92 (92.4%) demonstrated radiographic success. Clinical success was observed in 24/24 participants (100%) in the MTA group, 22/23 (95.6%) in the Protooth group, 23/24 (95.8%) in the TheraCal group, and 21/21 (100%) in the FS group. Radiographic success was observed in 23/24 (95.8%), 21/23 (91.3%), 22/24 (91.7%), and 19/21 (90.5%) participants in the MTA, Protooth, TheraCal, and FS groups, respectively. No statistically significant between-group difference was detected in clinical success at 12 months (*P*=0.50), and no statistically significant between-group difference was detected in radiographic success (*P*=0.90). These findings indicate that statistically significant between-group differences were not detected within the available sample and follow-up period; they should not be interpreted as evidence of equivalence, non-inferiority, or clinical interchangeability. Comparative effect estimates for the registered primary outcome, radiographic success at 12 months, are presented in Table 3. Overall treatment success was also evaluated as an additional composite outcome. Relative to MTA, the absolute risk difference in radiographic success was −4.5 percentage points (95% confidence interval (CI), −23.0 to 12.7) for Protooth, −4.2 percentage points (95% CI, −22.0 to 13.0) for TheraCal, and −5.4 percentage points (95% CI, −25.0 to 12.1) for FS. The corresponding risk ratios were 0.953 (95% CI, 0.756–1.163), 0.957 (95% CI, 0.766–1.167), and 0.944 (95% CI, 0.734–1.155), respectively. The wide confidence intervals indicate limited precision of these estimates As an additional composite outcome, overall treatment success at 12 months was observed in 23/24 participants (95.8%) in the MTA group, 21/23 (91.3%) in the Protooth group, 22/24 (91.7%) in the TheraCal group, and 19/21 (90.5%) in the FS group.

This open-access article has been distributed under the Creative Commons Attribution-NonCommercial-ShareAlike 4.0 International (CC BY-NC-SA 4.0).

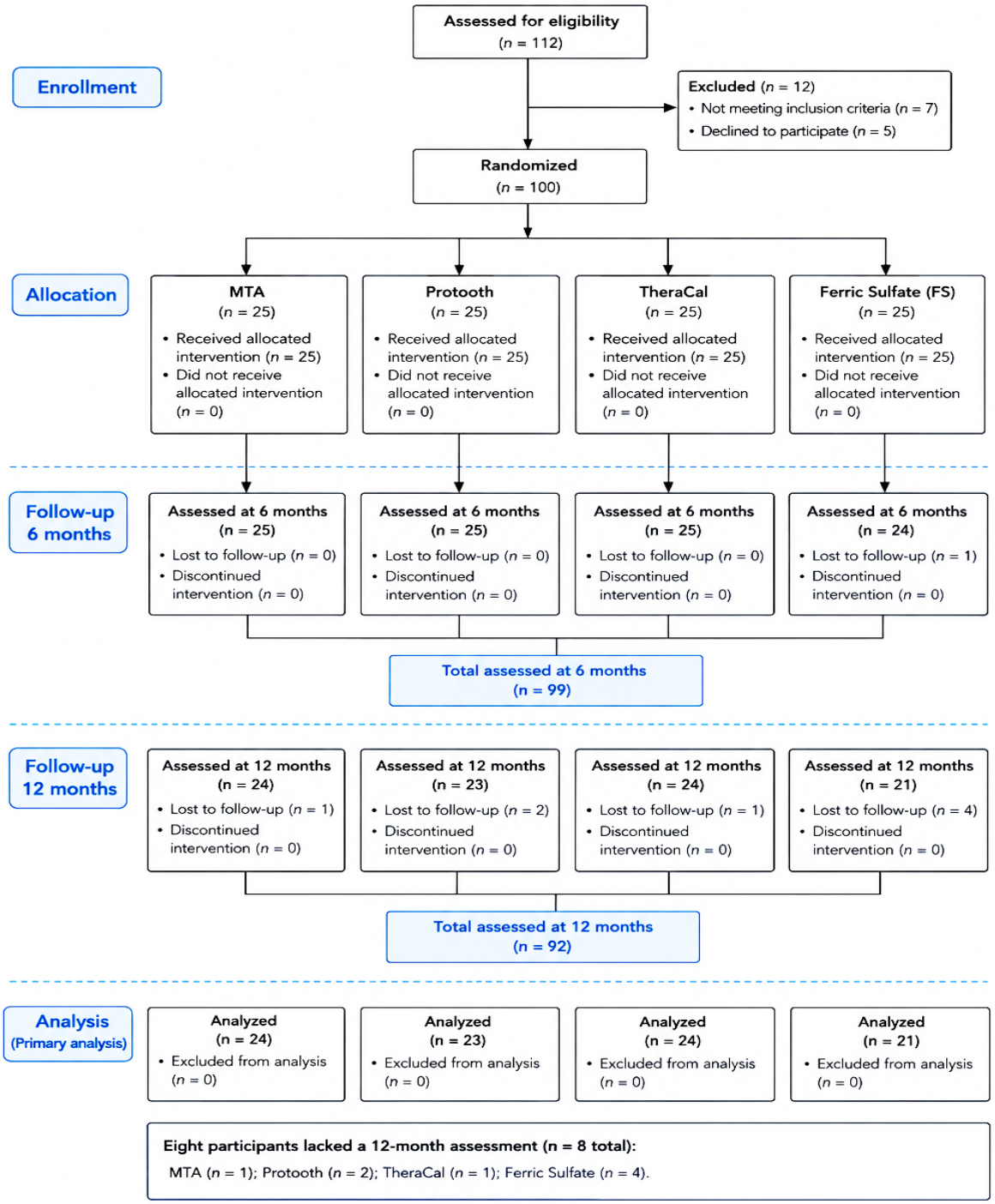

Figure 2. CONSORT flow diagram of participants through enrollment, allocation, follow-up, and analysis

Overall treatment success and failure patterns

Overall treatment failure was defined as the presence of at least one predefined clinical or radiographic failure criterion. Accordingly, a tooth with either a clinical or radiographic failure was classified as an overall treatment failure, whereas teeth with neither type of failure were classified as having overall treatment success. At 6 months, seven unique treatment failures were identified among the 99 participants assessed, corresponding to an overall treatment success rate of 92/99 (92.9%). At 12 months, seven unique treatment failures were identified among the 92 participants assessed, corresponding to an overall treatment success rate of 85/92 (92.4%). The detailed distribution of clinical and radiographic failure findings is presented in Table 4.

This open-access article has been distributed under the Creative Commons Attribution-NonCommercial-ShareAlike 4.0 International (CC BY-NC-SA 4.0).

At 6 months, one radiographic failure was recorded in the MTA group and consisted of furcation radiolucency. In the Protooth group, two radiographic failures involving furcation radiolucency were observed. In the TheraCal group, one clinical failure characterized by a sinus tract and mobility, together with two radiographic failure findings consisting of periodontal ligament widening and radiolucency involving the periapical and furcation regions, was recorded. One tooth in the TheraCal group met both clinical and radiographic failure criteria and was counted only once among the overall failures. In the FS group, two radiographic failures due to internal root resorption were observed.

At 12 months, one radiographic failure due to furcation radiolucency was recorded in the MTA group. In the Protooth group, one clinical failure involving increased mobility and two radiographic failures involving furcation radiolucency were observed. One tooth in the Protooth group met both clinical and radiographic failure criteria and was counted only once among the overall failures. In the TheraCal group, one clinical failure characterized by a sinus tract and mobility and two radiographic failure findings involving root resorption were recorded .One tooth in this group met both clinical and radiographic failure criteria and was counted only once among the overall failures. In the FS group, two radiographic failures due to internal root resorption were observed.

Overlap between clinical and radiographic failure findings occurred in the Protooth group at 12 months and in the TheraCal group at both 6 and 12 months. In each of these assessments, one tooth met both clinical and radiographic failure criteria and was counted only once in the total number of overall failures. Accordingly, the total number of overall failures represents the number of unique teeth with at least one failure criterion, rather than the sum of clinical and radiographic failure findings. These overlaps are marked with an asterisk in Table 4.

Table 1. Baseline characteristics of participants and treated teeth by treatment group.

Baseline data	MTA (*n*=25)	Protooth (*n*=25)	TheraCal (*n*=25)	FS (*n*=25)	Total (*n*=100)
Age years (SD)	6.65 (1.05)	6.40 (1.05)	6.90 (1.05)	5.80 (1.05)	6.44 (1.11)
Boys	11	12	9	10	42
Girls	14	13	16	15	58
First molar	7	16	11	8	42
Second molar	18	9	14	17	58
Maxilla	10	10	6	13	39
Mandible	15	15	19	12	61
General Anesthesia	0	4	2	2	8
Local Anesthesia	25	21	23	23	92

MTA: mineral trioxide aggregate; FS: ferric sulfate; SD: standard deviation. Note: Baseline characteristics are presented descriptively by treatment group. No formal hypothesis testing was performed to assess baseline comparability or to determine covariate adjustment.

Table 2. Clinical, radiographic, and overall treatment success at 6 and 12 months, with sensitivity analysis for missing 12-month outcomes

Treatment group	Clinical success, 6 months, n/N (%)	Clinical success, 12 months, n/N (%)	Radiographic success, 6 months, n/N (%)	Radiographic success, 12 months, n/N (%)	Overall treatment success, 6 months, n/N (%)	Overall treatment success, 12 months, n/N (%) [95% CI]	Sensitivity analysis, 12 months, n/N (%) [95% CI]
MTA	25/25 (100%)	24/24 (100%)	24/25 (96.0%)	23/24 (95.8%)	24/25 (96.0%)	23/24 (95.8%) [78.9–99.9]	23/25 (92.0%) [74.0–99.0]
Protooth	25/25 (100%)	22/23 (95.6%)	23/25 (92.0%)	21/23 (91.3%)	23/25 (92.0%)	21/23 (91.3%) [72.0–98.9]	21/25 (84.0%) [63.9–95.5]
TheraCal	24/25 (96.0%)	23/24 (95.8%)	23/25 (92.0%)	22/24 (91.7%)	23/25 (92.0%)	22/24 (91.7%) [73.0–99.0]	22/25 (88.0%) [68.8–97.5]
Ferric sulfate (FS)	24/24 (100%)	21/21 (100%)	22/24 (91.7%)	19/21 (90.5%)	22/24 (91.7%)	19/21 (90.5%) [69.6–98.8]	19/25 (76.0%) [54.9–90.6]
Total	98/99 (98.9%)	90/92 (97.8%)	92/99 (92.9%)	85/92 (92.4%)	92/99 (92.9%)	85/92 (92.4%)	85/100 (85.0%)

MTA, mineral trioxide aggregate; FS, ferric sulfate; CI, confidence interval. ***Notes:*** *The registered primary outcome was radiographic success at 6 and 12 months. Clinical success was a secondary outcome, and overall treatment success was evaluated as an additional composite outcome. Percentages for observed outcomes were calculated using the number of participants assessed at each follow-up. Overall treatment success was defined as the absence of any predefined clinical or radiographic failure criterion. A tooth meeting both clinical and radiographic failure criteria was counted only once when determining overall treatment success. The 12-month sensitivity analysis classified all eight participants without a 12-month assessment as treatment failures; the denominator was therefore 100. Exact binomial (Clopper–Pearson) 95% confidence intervals are reported for the group-specific proportions. This sensitivity analysis is an analytical assumption and does not establish that participants with missing outcomes actually experienced treatment failure. Between-group P-values were 0.30 for 6-month clinical success, 0.90 for 6-month radiographic success, 0.50 for 12-month clinical success, and 0.90 for 12-month radiographic success. For the sensitivity analysis,* χ^2*=2.75, P=0.433.*

This open-access article has been distributed under the Creative Commons Attribution-NonCommercial-ShareAlike 4.0 International (CC BY-NC-SA 4.0).

Overall, radiographic findings accounted for most of the observed failures, whereas clinical failures were less frequent. Some teeth demonstrated radiographic abnormalities in the absence of clinical signs or symptoms. When clinical and radiographic findings occurred in the same tooth, the tooth was counted only once as an overall treatment failure. Therefore, clinical and radiographic failure counts should not be summed directly to calculate the number of unique teeth classified as overall treatment failures. Representative radiographic outcomes are shown in Figs. 3 and 4.

Follow-up analysis and sensitivity analysis

The primary analysis used the available outcome data at each prespecified follow-up visit. Participants who did not attend a particular follow-up assessment were excluded from the denominator for that time point and were not classified as treatment failures. At 12 months, outcome data were available for 92 of the 100 randomized participants. Because the trial was designed as a superiority trial rather than a non-inferiority or equivalence trial, the absence of statistically significant between-group differences was interpreted as failure to detect a statistically significant difference within the study sample and follow-up period, rather than as evidence that the treatment protocols were equivalent. As a conservative sensitivity analysis, all eight missing 12-month outcomes were classified as treatment failures. Under this assumption, overall treatment success was 92.0% (23/25; 95% CI, 74.0–99.0) for MTA, 84.0% (21/25; 95% CI, 63.9–95.5) for Protooth, 88.0% (22/25; 95% CI, 68.8–97.5) for TheraCal, and 76.0% (19/25; 95% CI, 54.9–90.6) for FS. The corresponding overall success rate across all 100 randomized participants was 85.0% (85/100). The between-group comparison remained statistically non-significant (χ^2=2.75, P=0.433). This sensitivity analysis represents a conservative assumption regarding missing outcomes and should not be interpreted as evidence that the participants without 12-month assessments actually experienced treatment failure.

Discussion

This randomized controlled clinical trial compared the clinical and radiographic outcomes of four pulpotomy treatment protocols MTA, Protooth, TheraCal, and FS in primary molars over 12 months. All four protocols demonstrated high observed success rates, and no statistically significant between-group differences were detected at either 6 or 12 months. These findings indicate that no statistically significant differences were detected within the present sample and follow-up period and should not be interpreted as evidence of equivalence, non-inferiority, or clinical interchangeability. The relatively wide confidence intervals around the comparative estimates also indicate limited precision. The present findings are consistent with previous randomized clinical evidence.

Table 3. Between-group effect estimates for radiographic success at 12 months

Treatment group	Radiographic success at 12 months, n/N (%)	Absolute risk difference *vs.* MTA, percentage points (95% CI)	Risk ratio *vs.* MTA (95% CI)
MTA	23/24 (95.8)	Reference	Reference
Protooth	21/23 (91.3)	−4.5 (−23.0 to 12.7)	0.953 (0.756–1.163)
TheraCal	22/24 (91.7)	−4.2 (−22.0 to 13.0)	0.957 (0.766–1.167)
FS	*19/21 (90.5)*	*−5.4 (−25.0 to 12.1)*	*0.944 (0.734–1.155)*

MTA: mineral trioxide aggregate; FS: ferric sulfate; CI: confidence interval. Note: MTA was used as the reference category solely for comparative effect estimation; all four treatment groups remained part of the randomized comparison. Absolute risk differences were calculated using the Newcombe method based on Wilson score intervals. Risk-ratio confidence intervals were calculated using a score-based method. The wide confidence intervals reflect the limited precision associated with the small number of observed failures and incomplete 12-month follow-up.

Table 4. Clinical and radiographic failure patterns by treatment group and follow-up time

Treatment group	Follow-up, months	Participants assessed, n	Clinical Failures (n, description)	Radiographic Failures (n, description)	Total Failures (n)
MTA	6	25	None (0)	1 (Furcation radiolucency)	1
	12	24	None (0)	1 (Furcation radiolucency)	1
Protooth	6	25	None (0)	2 (Furcation radiolucency)	2
	12	23	1 (Increased mobility)	2 (Furcation radiolucency)	2*
TheraCal	6	25	1 (Sinus tract, Mobility)	2 (PDL widening; periapical/furcation radiolucency)	2*
	12	24	1 (Sinus tract, Mobility)	2 (Root resorption)	2*
FS	6	24	None (0)	2 (Internal root resorption)	2
	12	21	None (0)	2 (Internal root resorption)	2

MTA: mineral trioxide aggregate; FS: ferric sulfate; PDL: periodontal ligament. Overall failures represent unique teeth meeting at least one predefined clinical or radiographic failure criterion. Participants lost to follow-up were not classified as treatment failures. An asterisk indicates that one tooth met both clinical and radiographic failure criteria and was counted only once among the overall failures. This overlap was recorded in the Protooth group at 12 months and in the TheraCal group at both 6 and 12 months.

This open-access article has been distributed under the Creative Commons Attribution-NonCommercial-ShareAlike 4.0 International (CC BY-NC-SA 4.0).

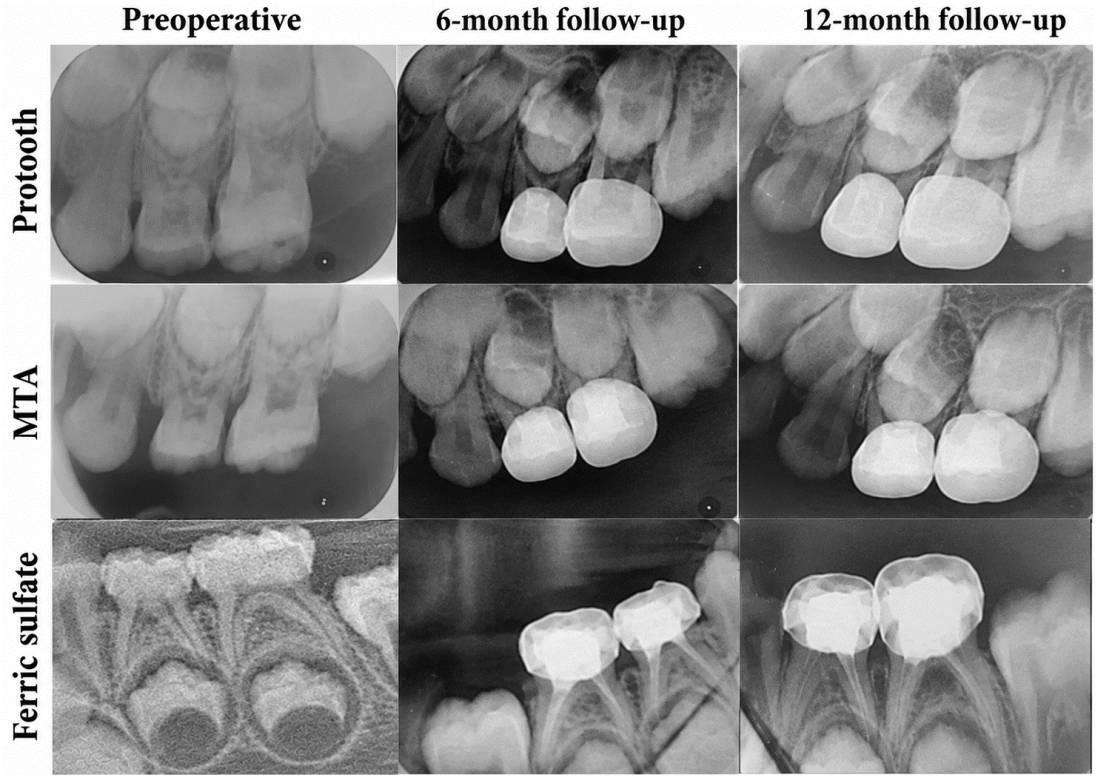

Figure 3. Successful pulpotomy using Protooth, MTA, and Ferric Sulfate at 6- and 12-month follow-ups. All three materials demonstrated clinical and radiographic success, with maintained pulp vitality and absence of periapical or furcal pathology at both follow-up intervals.

Ansari *et al.* [8] reported favorable clinical and radiographic outcomes for four pulpotomy techniques, with no significant differences among treatment groups at one year. MTA showed high clinical and radiographic success in the present study, consistent with previous clinical studies reporting favorable outcomes following MTA pulpotomy in primary molars[20]. Its established biocompatibility, sealing ability, and capacity to promote hard-tissue formation may contribute to its favorable clinical performance [35-37]. However, the present study was not designed to establish superiority, and numerical differences should therefore be interpreted descriptively.

A principal contribution of this study is the prospective evaluation of Protooth in primary molar pulpotomy. At 12 months, Protooth demonstrated clinical and radiographic success rates of 95.6% and 91.3%, respectively, with no statistically significant difference compared with the other protocols. These findings provide preliminary randomized clinical evidence regarding Protooth; however, the comparative estimates should be interpreted cautiously because of the limited sample size and imprecision of the estimates. Vafaei *et al.* [33] reported favorable 12-month outcomes for Protooth compared with MTA in direct pulp capping of primary molars; however, differences in treatment indication and study design limit direct comparison with the present pulpotomy trial. Previous studies have also reported favorable biological characteristics of Protooth, including low solubility, favorable handling, fluoride release, and potential apatite formation [38]. Nevertheless, these properties were not directly evaluated in the present study and should not be considered demonstrated clinical advantages. Similarly, favorable findings were reported for Protooth in apexogenesis of immature permanent teeth[39]. These findings provide supportive background evidence but cannot be considered direct evidence for primary molar pulpotomy. Further appropriately designed trials are therefore required.

TheraCal demonstrated clinical and radiographic success rates of 95.8% and 91.7%, respectively, at 12 months. This is broadly consistent with Hassanpour *et al.* [24] who found no significant difference between TheraCal and MTA after 12 months of pulpotomy in primary molars. Although concerns regarding the resin-modified formulation of TheraCal have been raised[40], the present study was not designed to assess its long-term biological behavior or material-specific advantages.

FS showed 100% clinical and 90.5% radiographic success at 12 months, with internal root resorption accounting for the observed radiographic failures. Previous clinical studies have reported favorable outcomes following FS pulpotomy in primary molars[13], and Sajjadi *et al.* [34] found no significant difference between FS and calcium-enriched mixture cement at 6 months.

This open-access article has been distributed under the Creative Commons Attribution-NonCommercial-ShareAlike 4.0 International (CC BY-NC-SA 4.0).

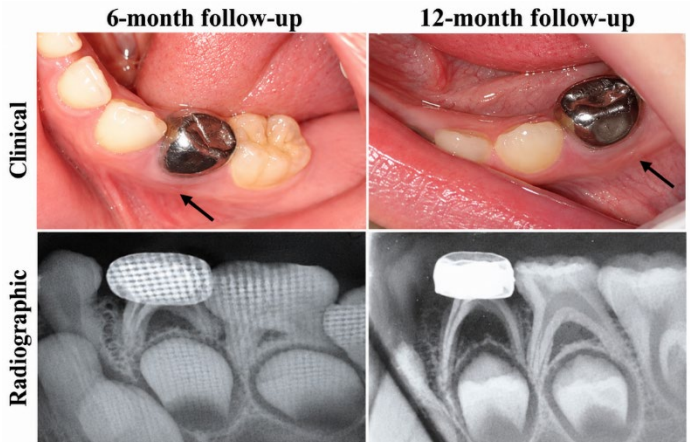

Figure 4. Pulpotomy failure with TheraCal, shown at 6- and 12-month follow-ups. Radiographic signs of pulpotomy failure, including furcal radiolucency and internal and external root resorption, with clinical indication of a buccal soft tissue parulis (highlighted by the black arrow)

The present findings nevertheless emphasize the importance of radiographic surveillance when evaluating FS and other pulpotomy protocols. An important finding was the difference between clinical and radiographic outcomes. At 12 months, clinical success was 97.8%, whereas radiographic success was 92.4%. Thus, some clinically asymptomatic teeth demonstrated radiographic abnormalities such as furcal radiolucency or root resorption. This supports previous evidence emphasizing the complementary value of clinical and radiographic assessment in pulpotomy studies[8, 13], as reliance on clinical findings alone may overestimate treatment success. The four interventions should also be considered as complete clinical treatment protocols rather than isolated material comparisons. Differences in material thickness, setting procedures, and associated liners or bases may have influenced outcomes. In addition, the use of rubber-dam or cotton-roll isolation according to clinical circumstances introduced some procedural heterogeneity. Therefore, observed differences cannot be attributed solely to the intrinsic properties of the materials.

The baseline distribution of first and second primary molars differed among groups; however, baseline characteristics were considered descriptively and were not used for post-randomization hypothesis testing or covariate selection. Given the randomized design, the observed baseline imbalance was therefore interpreted as a descriptive characteristic rather than evidence of treatment-related confounding. The unequal loss to follow-up at 12 months should be considered when interpreting the findings. Eight participants were unavailable for the 12-month assessment: one in the MTA group (4.0%), two in the Protooth group (8.0%), one in the TheraCal group (4.0%), and four in the FS group (16.0%). The reasons for missing follow-up were not systematically recorded; therefore, the potential relationship between missingness and treatment outcomes cannot be established. The primary analysis was based on available outcome data, and participants with missing assessments were not classified as treatment failures. Although the sensitivity analysis classified all eight missing 12-month outcomes as treatment failures, this extreme-case assumption does not eliminate the possibility of attrition bias. Given the unequal loss to follow-up across groups and the uncertainty surrounding the missing outcomes, attrition may have influenced the observed success rates and between-group comparisons. The findings should therefore be interpreted with appropriate caution.

Strengths and limitations

The strengths of this study include randomized allocation, the use of sealed envelopes for allocation concealment, and use of one treated tooth per participant, standardized clinical procedures, independent outcome assessment, and simultaneous evaluation of clinical and radiographic outcomes. The study also provides prospective randomized clinical evidence regarding Protooth in primary molar pulpotomy, an area in which direct evidence remains limited.

Several limitations should be considered. The 12-month follow-up and single-center design limit assessment of long-term outcomes and generalizability. Formal examiner calibration and prospective intra-examiner reliability assessment were not performed; therefore, no reliability coefficient such as Cohen's kappa was available. Although the outcome examiner was blinded to treatment allocation, complete masking could not be guaranteed because different materials may have distinctive radiographic appearances. These limitations are particularly relevant because radiographic findings accounted for most of the observed treatment failures. The absence of formal reliability data and the possibility of partial unmasking reduce confidence in the consistency of outcome classification and should be considered when interpreting the observed success rates and between-group comparisons. The interventions also represented material-specific clinical protocols rather than identical experimental conditions. Finally, the original computational record and complete assumptions underlying the sample-size calculation were unavailable, preventing reliable retrospective reconstruction or a post-hoc power calculation. Consequently, the adequacy of the sample size for detecting clinically meaningful between-group differences could not be independently verified. Only seven unique overall treatment failures were observed at the 12-month assessment, resulting in

This open-access article has been distributed under the Creative Commons Attribution-NonCommercial-ShareAlike 4.0 International (CC BY-NC-SA 4.0).

limited precision of the comparative estimates. The confidence intervals around the between-group effect estimates were wide, and clinically meaningful differences between treatments cannot be excluded. Therefore, the absence of statistically significant differences should not be interpreted as evidence of equivalence, non-inferiority, or comparable effectiveness. In addition, because only seven unique overall failures occurred and assessments were limited to scheduled 6- and 12-month visits, survival and cure-model analyses were not considered sufficiently reliable and were therefore not performed.

Clinical implications and future research

Clinically, all four protocols demonstrated favorable short-term outcomes under the conditions of this study. The results provide preliminary clinical evidence regarding Protooth but do not establish its equivalence, non-inferiority, or interchangeability with MTA or other established materials. Because the sample-size calculation could not be independently verified and the comparative estimates were imprecise, the findings should be interpreted as preliminary rather than as evidence of comparable effectiveness .Future multicenter randomized trials with larger samples, longer follow-up, standardized operative protocols, and prespecified outcomes are warranted. When clinical comparability with an established material is the objective, appropriately powered non-inferiority or equivalence trials with a clinically justified margin should be performed.

Conclusion

Within the limitations of this randomized controlled clinical trial, all four pulpotomy treatment protocols demonstrated high clinical and radiographic success rates over the 6- and 12-month follow-up periods. Clinical success was consistently higher than radiographic success, with radiographic abnormalities accounting for most observed failures. No statistically significant between-group differences in clinical or radiographic success were detected within the study sample and follow-up period; however, the absence of statistical significance should not be interpreted as evidence of equivalence or non-inferiority. Protooth demonstrated favorable clinical and radiographic outcomes during the 12-month observation period, providing preliminary randomized clinical evidence to support further investigation of this novel bioactive material. However, the small number of treatment failures, wide confidence intervals, and inability to independently verify the original sample-size calculation limit the precision and interpretation of the comparative findings; clinically meaningful differences between treatments cannot be ruled out. Larger, adequately powered multicenter trials with longer follow-up are warranted to determine the comparative clinical performance of Protooth and established pulpotomy materials.

Acknowledgments

The authors would like to thank the Vice-Chancellor of Research and Technology at Tabriz University of Medical Sciences for their support. This article is derived from a specialized thesis.

Conflict of Interest

None.

Funding

None.

Author Contributions

Conceptualization: SH/LV/PH; Methodology: AV/LE; Formal Analysis and Investigation: ZT/LE; Writing-Original draft preparation: SH/AV/LV/PH; Writing-review and editing: AV/ZT/LE; Supervision: AV. All authors read and approved the final manuscript.

References

1. Shuxratovich RRASS. Dental Caries of Primary Teeth and Its Complications in Children. INNUC. 2025;1(1):2-8.
2. Duggal M, Day P. Operative treatment of dental caries in the primary dentition. Paediatr Dent. 2018;3:147-74.
3. Li Y, Sui B, Dahl C, Bergeron B, Shipman P, Niu L, et al. Pulpotomy for carious pulp exposures in permanent teeth: A systematic review and meta-analysis. J Dent. 2019;84:1-8.
4. Parisay I, Ghoddusi J, Forghani M. A review on vital pulp therapy in primary teeth. Iran Endod J. 2015;10(1):6-15.
5. Sanusi SY, Al-Bataynehb OB. Pulp Therapy of Primary Dentition; its Relevance despite Insufficient Histological Evidence: A Review. Iran Endod J. 2023;18(1):15-40.
6. Bjørndal L, Simon S, Tomson P, Duncan H. Management of deep caries and the exposed pulp. Int Endod J. 2019;52(7):949-73.
7. Duncan HF, El-Karim I, Dummer PM, Whitworth J, Nagendrababu V. Factors that influence the outcome of pulpotomy in permanent teeth. Int Endod J. 2023;56:62-81.
8. Ansari G, Morovati SP, Asgary S. Evaluation of four pulpotomy techniques in primary molars: A randomized controlled trial. Iran Endod J. 2018;13(1):7.
9. Issrani R, Prabhu N, Bader AK, Alfayyadh AY, Alruwaili KK, Alanazi SH, et al. Exploring the properties of formocresol in dentistry-a comprehensive review. J Clin Pediatric Dent. 2023;47(3).
10. Bossù M, Iaculli F, Di Giorgio G, Salucci A, Polimeni A, Di Carlo S. Different pulp dressing materials for the pulpotomy of primary teeth: a systematic review of the literature. J Clin Med. 2020;9(3):838.
11. Fallahinejad Ghajari M, Mirkarimi M, Vatanpour M, Kharrazi Fard MJ. Comparison of pulpotomy with formocresol and MTA in

This open-access article has been distributed under the Creative Commons Attribution-NonCommercial-ShareAlike 4.0 International (CC BY-NC-SA 4.0).

primary molars: a systematic review and meta- analysis. Iran Endod J. 2008;3(3):45-9.
12. Bandi M, Mallineni SK, Nuvvula S. Clinical applications of ferric sulfate in dentistry: A narrative review. J Conserv Dent Endod. 2017;20(4):278-81.
13. Gisoure EF. Comparison of three pulpotomy agents in primary molars: a randomised clinical trial. Iran Endod J. 2011;6(1):11.
14. Asgary S, Parirokh M, Eghbal MJ, Brink F. A comparative study of white mineral trioxide aggregate and white Portland cements using X-ray microanalysis. Aust Endod J. 2004;30(3):89-92.
15. de Oliveira NG, de Souza Araújo PR, da Silveira MT, Sobral APV, de Vasconcelos Carvalho M. Comparison of the biocompatibility of calcium silicate-based materials to mineral trioxide aggregate: Systematic review. Euro J Dent. 2018;12(02):317-26.
16. Cordell S, Kratunova E, Marion I, Alrayyes S, Alapati SB. A randomized controlled trial comparing the success of mineral trioxide aggregate and ferric sulfate as pulpotomy medicaments for primary molars. J Dent Child. 2021;88(2):120-8.
17. Shirvani A, Hassanizadeh R, Asgary S. Mineral Trioxide Aggregate vs. Calcium Hydroxide in Primary Molar Pulpotomy: A Systematic Review. Iran Endod J. 2014;9(2):83-8.
18. Asgary S, Parirokh M, Eghbal MJ, Ghoddusi J, Eskandarizadeh A. SEM evaluation of neodentinal bridging after direct pulp protection with mineral trioxide aggregate. Aust Endod J. 2006;32(1):26-30.
19. Cao Y, Song M, Kim E, Shon W, Chugal N, Bogen G, et al. Pulp-dentin regeneration: current state and future prospects. J Dent Res. 2015;94(11):1544-51.
20. Haghgoo R, Abbasi F. Clinical and radiographic success of pulpotomy with MTA in primary molars: 30 months follow up. Iran Endod J. 2010;5(4):157.
21. Pushpalatha C, Dhareshwar V, Sowmya S, Augustine D, Vinothkumar TS, Renugalakshmi A, et al. Modified mineral trioxide aggregate—A versatile dental material: An insight on applications and newer advancements. Front Bioeng Biotechnol. 2022;10:941826.
22. Ravindran V, Jeevanandan G, Marimuthu M, Panda S, Syed AA, Vishwanathaiah S, et al. Comparison of mineral trioxide aggregate and biodentine for open apex management in children with nonvital immature permanent teeth: a systematic review. Euro J General Dent. 2022;11(02):084-93.
23. Wassel MO, Amin DH, Badran AS. Clinical, Radiographic, and histological evaluation of TheraCal pulpotomy in human primary teeth. Egypt Dent J. 2017;63(3-July (Orthodontics, Pediatric & Preventive Dentistry)):2175-85.
24. Hassanpour S, Aminabadi NA, Rahbar M, Erfanparast L. Comparison between the Radiographic and Clinical Rates of Success for TheraCal and MTA in Primary Tooth Pulpotomy within a 12-Month Follow-Up: A Split-Mouth Clinical Trial. Biomed Res Int. 2023;2023(1):8735145.
25. Gandolfi MG, Siboni F, Prati C. Chemical–physical properties of TheraCal, a novel light-curable MTA-like material for pulp capping. Int Endod J. 2012;45(6):571-9.
26. Ranjkesh B, Kopperud HM, Kopperud SE, Løvschall H. Bond strength between dentine and a novel fast-setting calcium silicate cement with fluoride. Euro J Oral Sci. 2019;127(6):564-9.
27. Jafari F, Jafari S, Etesamnia P. Genotoxicity, bioactivity and clinical properties of calcium silicate based sealers: a literature review. Iran Endod J. 2017;12(4):407.
28. Eskandari F, Razavian A, Hamidi R, Yousefi K, Borzou S. An updated review on properties and indications of calcium silicate-based cements in endodontic therapy. Int J Dent. 2022;2022(1):6858088.
29. Karkoutly M, Alnour A, Abu Hasna A, Nam OH, Al Kurdi S, Bshara N. Treatment outcomes of pulpotomy in primary molars utilizing 2.25% sodium hypochlorite gel: a randomized controlled trial. BMC Oral Health. 2025;25(1):1052.
30. Karkoutly M, Alnour A, Alabdullah J, Abu Hasna A, Nam OH, Jalloul D, et al. Analysis of pulp histological response to pulpotomy performed with white mineral trioxide aggregate mixed with 2.25% sodium hypochlorite gel in humans: a randomized controlled clinical trial. Scientific Reports. 2024;14(1):31471.
31. Camilleri J. Hydration characteristics of Biodentine and Theracal used as pulp capping materials. Dent Mater J. 2014;30(7):709-15.
32. Komabayashi T, Zhu Q, Eberhart R, Imai Y. Current status of direct pulp-capping materials for permanent teeth. Dent Mater J. 2016;35(1):1-12.
33. Vafaei A, Azima N, Erfanparast L, Løvschall H, Ranjkesh B. Direct pulp capping of primary molars using a novel fast-setting calcium silicate cement: a randomized clinical trial with 12-month follow-up. Biomater Investig Dent. 2019;6(1):73-80.
34. Sajadi FS, Jalali F, Khademi M. Ferric sulfate versus calcium-enriched mixture cement in pulpotomy of primary molars: a randomized clinical trial. Pesqui Bras Odontopediatria Clín Integr. 2020;21:e0017.
35. Beldar-E-mail TL, Jawdekar-E-mail AM. Success of pulpotomy with MTA in primary teeth: A systematic review and meta-analysis. Bioinformation. 2025;21(8):2574-80.
36. Lin GSS, Chin YJ, Choong RS, Wafa SWaWSST, Dziaruddin N, Baharin F, et al. Treatment outcomes of pulpotomy in primary teeth with irreversible pulpitis: a systematic review and meta-analysis. Children. 2024;11(5):574.
37. Silva EJ, Pinto KP, Torabinejad M, Sarmento EB, Martins JN, Versiani MA, et al. Overall success rate of permanent teeth pulpotomy using ProRoot MTA: A systematic review and meta-analysis of randomized clinical trials. PLoS One. 2025;20(4):e0320838.
38. Ranjkesh B, Ding M, Dalstra M, Nyengaard JR, Chevallier J, Isidor F, et al. Calcium phosphate precipitation in experimental gaps between fluoride-containing fast-setting calcium silicate cement and dentin. Euro J Oral Sci. 2018;126(2):118-25.
39. Vafaei A, Nikookhesal M, Erfanparast L, Løvschall H, Ranjkesh B. Vital pulp therapy following pulpotomy in immature first permanent molars with deep caries using novel fast-setting calcium silicate cement: a retrospective clinical study. J Dent. 2022;116:103890.
40. Silva EJNLD, Pinto KP, Riche FNSJ, Martins JN, Duncan HF, Versiani MA, et al. Success of primary teeth pulpotomy using calcium silicate cements: a systematic review and meta-analysis of randomized clinical trials. Pediatr Dent. 2024;46(6):373-95.

Please cite this paper as: Hassanpour SH, Vafaei A, Torab Z, Vahedi L, Hassanpour P, Erfanparast L. Clinical and Radiographic Outcomes of Protooth versus MTA, TheraCal, and Ferric Sulfate in Primary Molar Pulpotomy: A Randomized Controlled Trial. Iran Endod J. 2026;21(1): e45. Doi: 10.22037/iej.v21i1.53131.

This open-access article has been distributed under the Creative Commons Attribution-NonCommercial-ShareAlike 4.0 International (CC BY-NC-SA 4.0).