



Treatment of Invasive Cervical Resorption in a Central Incisor by Intentional Replantation: A Case Report

Luiz Ricardo Gomes de Caldas Nogueira Filho ^a , Pedro Henrique de Freitas Fernandes ^{a*} , Luiz Ricardo Gomes de Caldas Nogueira ^a , Christianne Tavares Velozo Telles ^a , Rosana Maria Coelho Travassos ^a , Diana Santana de Albuquerque ^a

^a Dental School, Universidade de Pernambuco (FOP/UPE), Professor Luis Freire Avenue, 700, Cidade Universitária, Recife/PE, Brazil

Article Type: Case Report

Received: 12 Aug 2024

Revised: 21 Aug 2024

Accepted: 06 Sep 2024

Doi: 10.22037/iej.v19i4.45212

*Corresponding author: Pedro Henrique de Freitas Fernandes, Dental School, Universidade de Pernambuco (FOP/UPE), Professor Luis Freire Avenue, 700, Cidade Universitária, Recife/PE, Brazil.

E-mail: pedrofreitasff@gmail.com

Invasive cervical resorption (ICR) is an aggressive pathological condition that can affect any permanent tooth. This process is characterized by replacement of the tooth structure with granulomatous fibrovascular or fibro-osseous tissue. Despite its asymptomatic nature, ICR can lead to tooth loss. This study reports a case of ICR in a 15-year-old boy with a history of dental trauma. The patient had a diagnosis of ICR in tooth #21. After considering the risks of an external surgical approach and exclusive endodontic treatment, intentional re-implantation combined with extraoral composite resin restoration and endodontic treatment was proposed. The procedure consisted of atraumatic tooth extraction, removal of granulomatous tissue, restoration of the cavity with composite resin, re-implantation of the tooth in the alveolus, and endodontic treatment. This approach resulted in satisfactory repair of the resorptive lesion observed in over 3 years of follow-up. This case highlights intentional re-implantation combined with appropriate endodontic treatment as a viable treatment option for ICR.

Keywords: Cone-beam Computed Tomography; Endodontics; Root Resorption; Tooth Replantation; Tooth Resorption

Introduction

Invasive cervical resorption (ICR) is a pathological condition characterized by an aggressive resorption process that can affect any permanent tooth. This resorption starts on the external surface of the tooth, above the alveolar bone crest in the cervical region, gradually replacing the mineralized tooth structure with granulomatous fibrovascular or fibro-osseous tissue. Despite its insidious and asymptomatic nature, ICR can lead to tooth loss, a fact that renders this condition a clinical challenge.

The nomenclature of ICR in the literature is diverse and reflects the complexity of this condition, with terms ranging from invasive extra-canal resorption to simply cervical resorption. This variety of terminologies also reflects the lack of consensus and the continued interest of scientists in

understanding the etiology and pathogenesis of this pathology. The number of studies on ICR is small because of its low prevalence; however, some factors have been associated with its occurrence, including dental trauma, previous orthodontic treatment, and periodontal ligament damage [3-1].

An accurate diagnosis and thorough assessment are essential for the successful treatment of ICR. Interpretation of radiographs and tomography scans is crucial due to the subgingival location of these lesions. Treatment varies according to the classification of the lesion and is aimed at inactivating the resorptive process and reconstructing the defect [1-9].

Given these considerations, we report a clinical case in which a patient with difficult-to-access ICR was treated with intentional replantation combined with extraoral composite resin restoration. Endodontic treatment was included as an integral part of the therapeutic approach.



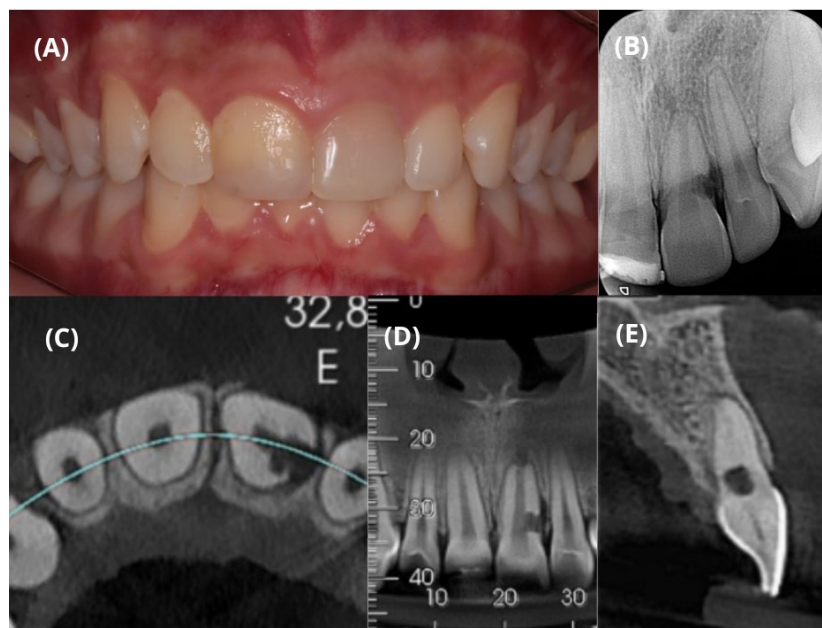


Figure 1. A) Initial clinical appearance of tooth #21; B) Initial radiographic appearance of tooth #21 with invasive cervical resorption; C, D, and E) Initial axial, coronal and sagittal tomography sections, respectively

Case Report

A 15-year-old South American boy visited the dental clinic accompanied by his mother with a history of dental trauma at the age of 13. The patient did not exhibit systemic alterations. The accident caused extrusive luxation of the tooth, which was repositioned. Eighteen months after the trauma, the patient was diagnosed with ICR in tooth #21, confirmed by another professional. The patient had no history of previous orthodontic treatments. Several therapeutic options were considered, including an external surgical approach consisting of a periodontal flap and osteotomy aimed at accessing the lesion and inactivating it. However, this approach would result in irreversible periodontal sequelae, especially in the esthetic region, such as the loss of the papilla between incisors. Furthermore, an exclusive endodontic approach would not be viable because of the distal location of the granulomatous process that would impair complete elimination of the affected tissue. Based on these considerations, intentional replantation combined with composite resin restoration in the area affected by resorption was the treatment of choice.

No typical signs of ICR such as pink spots, bleeding on probing, or pain were observed during clinical examination (Figure 1A). However, the tooth's response to pulp sensibility test using thermal stimulation (Endofrost at -50°C , Roeko, Langenau, Germany) was negative and there was also no change in color (Figure 1A), indicating pulp necrosis. The precise diagnosis of ICR could only be established based on radiographic evaluation,

including periapical radiography (Kavo Focus, Tuusula, Finland) (Figure 1B) and cone-beam computed tomography (Prexion 3D, TeraRecon, Inc., San Mateo, CA, USA) (Figure 1C, 1D and 1E), as well as the patient's history of dental trauma. Based on these findings, a new therapeutic approach was proposed. Considering the risks and limitations of the surgical procedure, informed consent was obtained from the parents and the patient.

The surgical procedure started with the administration of a local anesthetic (4% Articaine, DFL, Taquara, Rio de Janeiro, Brazil), followed by opening of the crown of tooth #21. To avoid obstruction of the root canal with composite resin during the procedure, gutta-percha accessory cones (Dentsply Sirona, Charlotte, NC, USA) were used (Figure 2A and 2B). It is important to highlight that the tooth was necrotic and that there was no pulp tissue in the canal.

Next, atraumatic tooth extraction was performed using a periosteal elevator (Nobel Biocare, Kloten, Switzerland) and #150 forceps (Quinelato, Rio Claro, São Paulo, Brazil) (Figure 2C). The coronal and root surfaces were then meticulously cleaned with 0.9% saline in order to identify the granulomatous tissue present in the lesion. Throughout the procedure, the tooth was supported exclusively on its coronal portion to avoid damage to the periodontal ligament. The granulomatous tissue was removed using a Lucas curette (Quinelato, Rio Claro, São Paulo, Brazil) and an FG #5 carbide bur (Jet, São Paulo, SP, Brazil) cooled with sterile saline (Figure 2D and 2E). The cavity was carefully dried with sterile cotton to optimize adhesion of the composite resin without compromising the periodontal ligament.

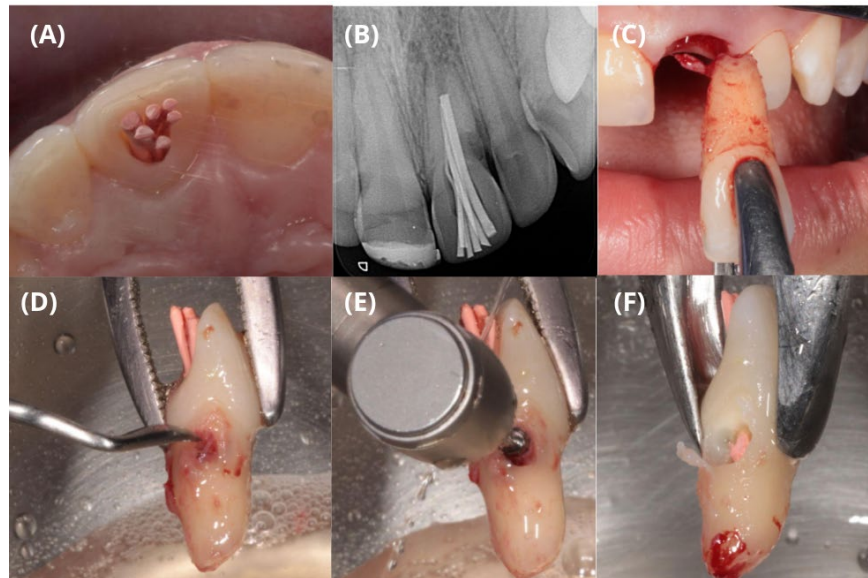


Figure 2. A) Clinical appearance of the root canal filled with gutta-percha cones; B) Radiographic appearance of the root canal filling with accessory gutta-percha cones; C) Atraumatic extraction of tooth #21; D) Removal of granomatous tissue with a curette; E) Removal of resorptive tissue with an FG #5 carbide bur; F) Appearance of the root after removal of the granomatous tissue

The self-etching adhesive system was applied with a micro-applicator (SDI, Victoria, Australia) using universal adhesive (3M, Saint Paul, MN, USA) (Figure 3A). Next, light curing was performed for 15 sec with the Elipar DeepCure light-curing device (3M, Saint Paul, MN, USA) (Figure 3B). Filtek Z350 XT nanoparticle composite resin (shade A1D; 3M, Saint Paul, MN, USA) was inserted using a spatula (Hu-Friedy, Frankfurt am Main, Germany) (Figure 3C). In the last increment, a glycerin-based gel (K-Y, São Paulo, SP, Brazil) (Figure 3D) was applied to cure the last composite resin layer in contact with oxygen since the dentist chose not to perform any polishing in order to avoid possible damage to the periodontal ligament. The tooth was then carefully irrigated with abundant saline (Figure 3E) and gently reinserted into the original socket (Figure 3F). The total extraoral time was 16 min and 30 sec.

Finally, the tooth was stabilized with flexible Twist Flex wire (Morelli, Sorocaba, SP, Brazil) and anchored with Filtek Z350 XT composite resin points (shade A2E; 3M, Saint Paul, MN, USA) to teeth #11, 12, 13, 22, and 23 (Figure 4A), followed by provisional sealing of the crown access with Filtek Z350 composite resin. The patient received prescriptions for postoperative medications, including 875 mg amoxicillin twice daily for 7 days and 600 mg ibuprofen twice daily for 3 days.

Follow-up visits were scheduled at 11 days, 15 days (for endodontic treatment), 1 month, 3 months, 6 months, 1 year, and 3 years after surgery. The following features were evaluated during the follow-up visits: probing depth,

periodontal esthetics, possible ankylosis assessed by percussion tests, and restoration of the periodontal ligament by periapical radiography.

After 14 days of follow-up, the flexible splint was removed. One month later, the probing depth was determined at 3 mm, indicating physiological recovery. After 15 days, the tooth was reopened and absolute isolation was performed for endodontic treatment. With the aid of an operating microscope (Zeiss, Jena, Germany), an R1 Clearsonic Black insert (Helse Ultrasonic, Santa Rosa do Viterbo, SP, Brazil) was used for abundant ultrasonic irrigation (Satelec Ultrasound, Acteon, Indaiatuba, São Paulo, Brazil) with 2.5% sodium hypochlorite to remove the gutta-percha inserted in the first appointment. After complete removal, an apex locator was used to determine the working length, which was 21 mm.

A #80 Hedström file was inserted into the canal, which proved to be loose. A #110 K-type file was then inserted and fitted perfectly, indicating that additional preparation of the canal was not necessary. The complete protocol of agitation of the irrigating solution was carried out using XP Endo Finisher (FKG, La Chaux-de-Fonds, Neuchâtel, Switzerland) (3 cycles of 20 sec with 2.5% sodium hypochlorite) and passive ultrasonic irrigation (3 cycles of 20 sec with 2.5% sodium hypochlorite) with an E1 Irrisonic insert (Helse Ultrasonic, Santa Rosa do Viterbo, SP, Brazil). The canal was cleaned with distilled water before repeating the agitation process with XP Endo Finisher and passive ultrasonic irrigation with 17% ethylenediaminetetraacetic acid.

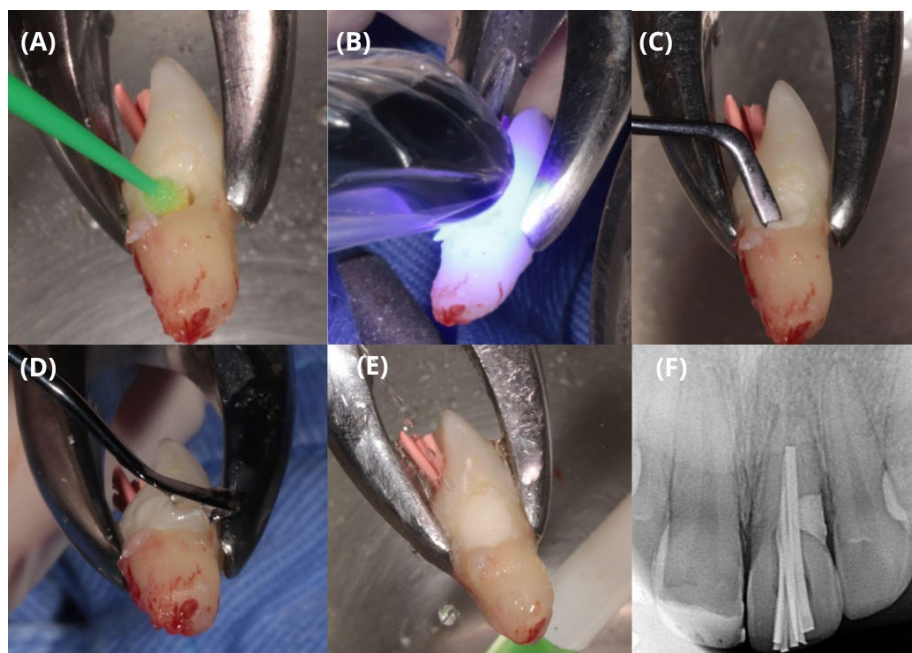


Figure 3. A) Application of self-etching adhesive to the cavity; B) Light-curing of the adhesive system; C) Restoration of the cavity with composite resin; D) Application of glycerin-based gel to the last layer of the restoration; E) Washing of the glycerin gel with 0.9% saline; F) Radiograph obtained immediately after intentional replantation of tooth #21

Calcium hydroxide paste was introduced as intracanal medication and agitated with an E1 Irrisonic insert for 20 sec. The tooth was then restored with composite resin. The intracanal medication was removed after 30 days and the protocol of agitation of the hypochlorite and ethylenediaminetetraacetic acid solution was repeated, followed by saline solution. The root canal was filled with Bio-C Sealer cement (Angelus, Lindóia, Londrina, PR, Brazil), agitated with an E1 Irrisonic insert for 20 sec, together with gutta-percha cones. Due to ICR, a Bio-C Repair plug (MTA cement, Angelus, Lindóia, Londrina, PR, Brazil) (Figure 4B) was applied in the cervical region. Finally, restoration was performed with bulk-fill flow resin (3M, Saint Paul, MN, USA).

Three years after surgery, a follow-up computed tomography scan was requested, which revealed no signs of disease progression (Figure 4D, 4E and 4F), showing the success of the procedure without causing esthetic sequelae despite the patient's unsatisfactory oral hygiene.

Discussion

Conventional low-dose radiography is not sufficient for ensuring an accurate diagnosis, especially in cases of complex anatomy [10], but continues to be the most used imaging method]. On the other hand, cone-beam computed tomography with a small field-of-view provides additional information of the

reconstructed three-dimensional images, which can facilitate diagnosis and planning and improve clinical management.

After the diagnosis had been established, we carefully evaluated the best treatment option for the patient. Given the complete clinical panorama, intentional replantation with atraumatic extraction was the treatment of choice. According to the literature, both direct restorations and raising mucoperiosteal flaps are common options in similar cases-11] [13]. However, these approaches may result in incomplete removal of the resorptive tissue and esthetic periodontal problems, respectively. Studies have shown that minimally invasive extraction techniques allow the removal of severely affected teeth without the need for flap surgery, in addition to reducing the extent of alveolar bone resorption [14, 15]. Furthermore, the application of extrusive forces along the root axis minimizes the harmful effects of lateral forces [16].

There is currently no material that meets all ideal requirements of a cavity located within the supracrestal attachment, where it is susceptible to chronic periodontal problems. Although glass ionomer or resin-modified glass ionomer cements have been advocated as restorative materials for resorption defects due to their desirable properties such as biocompatibility, hydrophilicity, fluoride release, and chemical adhesion to dentin, subgingival placement of these materials may not induce cementum or bone regeneration around them [2]. For this reason, in the present study, we chose to use composite resin

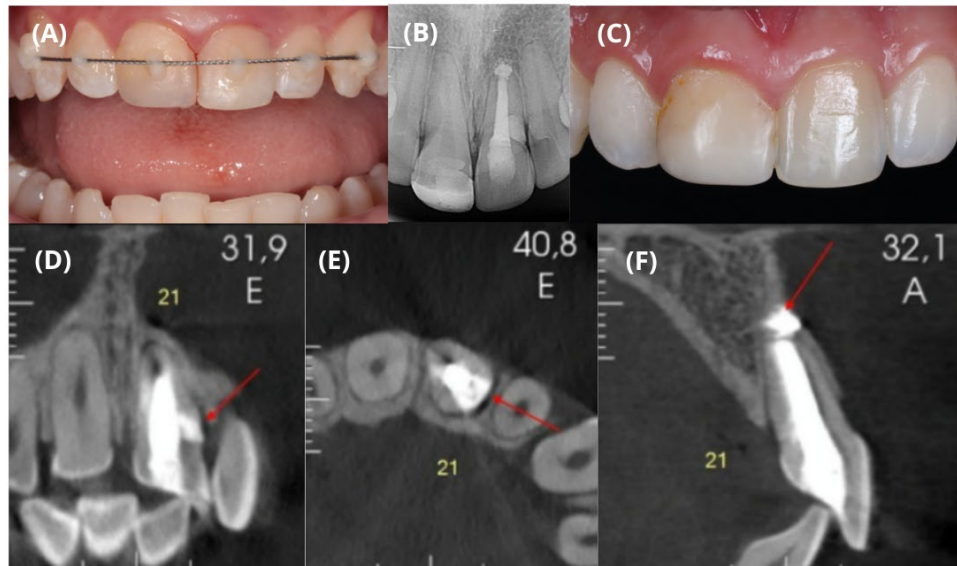


Figure 4. A) Flexible splinting of tooth #21; B) Radiographic appearance 3 years after surgery; C) Clinical appearance 3 years after surgery; D, E, and F) Coronal, axial, and sagittal tomography sections 3 years after surgery, respectively

because it was inserted extraorally under ideal restoration conditions and without compromising the tissue, offering significant advantages. The composite resin can be carefully adapted, resulting in a smooth surface without roughness that could interfere with periodontal adhesion. Although well-polished nanohybrid composites may not be as compatible with periodontal tissues, they reduce biofilm formation when compared to cements, thus providing a successful clinical outcome [18,17,7].

Alternatively, mineral trioxide aggregate (MTA) can also be used as a restorative material. However, its use is restricted to lesions that do not communicate with the oral cavity, *i.e.*, only cases of subcrestal lesions. Additionally, MTA has the disadvantage of a longer setting time. For this reason, MTA was not the material of choice since the amount of time the tooth remains outside the mouth is decisive for the success of treatment [17].

A systematic review analyzed 66 case reports or case series, totaling 95 teeth with ICR that were treated by different therapeutic approaches, including non-surgical external approaches, surgical external approaches with periodontal flap, orthodontic extrusion, intentional replantation, internal approaches, and combinations of these approaches. Clinical and radiographic criteria were established to evaluate the long-term success of the different treatment options for ICR, including physiological or stable periodontal probing depth in the defect area and absence of clinical and radiographic signs of disease progression in the affected tooth. Intentional replantation can be a viable and effective option for the treatment of ICR in selected cases, as long as the biological and technical principles involved in

the procedure are followed. This therapeutic approach allows maintenance of the natural tooth in the dental arch, preserving its shape, color, function, and sensibility. For a long time, intentional replantation has been considered an exceptional treatment that was reserved only for cases in which other therapeutic modalities were unfeasible or unsatisfactory. However, more recent evidence obtained with rigorous treatment protocols based on a better understanding of root resorption and immobilization protocols confirmed that intentional replantation is more predictable than previously thought, and is therefore a viable treatment option in certain cases. It is important to note that intentional replantation requires close long-term monitoring because of the development of late complications that can compromise the tooth's prognosis.

According to the International Association of Dental Traumatology guidelines for the treatment of traumatic dental injuries, calcium hydroxide should be selected as an intracanal medication. This medication can be maintained for up to 30 days due to its effectiveness in controlling the resorption process, thus reducing the risks of acidification and consequently preventing root resorption [6].

In addition to purely clinical features, esthetic and functional characteristics are important for evaluating treatment success. Restoring masticatory function and achieving esthetic harmony are objectives that cannot be underestimated, especially in young patients. This case report demonstrates the long-term success of intentional replantation, with tooth #21 remaining stable after 3 years. No clinical, radiographic, or tomographic signs suggestive of continuation of the resorptive process nor periodontal sequelae were observed.

Conclusion

Intentional replantation combined with endodontic treatment and composite resin restoration resulted in satisfactory repair of the resorptive lesion observed in over 3 years of follow-up. This case suggests intentional replantation combined with appropriate endodontic treatment is an option for treating ICR. However, further studies are needed to develop a standardized therapeutic protocol and evaluate the long-term effectiveness of this procedure. Continued research is key to improving the management of this complex condition.

Acknowledgments

None.

Conflict of interest

None.

Funding support

None.

Authors' contributions

LRGCNF Conceptualized the study and developed the protocol, Research design, PHFF: Acquisition, Analysis, Data interpretation, scientific writing and necessary corrections: LRGC: Obtaining, analyzing, and interpreting data, CTV/RMCT/DSA: Research design, analysis, data interpretation, writing and critical analysis. All authors contributed to the study and approved the final manuscript.

References

1. Asgary S, Dianat O. Invasive Cervical Root Resorption: A Comprehensive Review on Pathogenesis, Diagnosis, and Treatment. *Iran Endod J* 2024;19(1):2-12.
2. Rotondi O, Waldon P, Kim SG. The Disease Process, Diagnosis and Treatment of Invasive Cervical Resorption: A Review. *Dentistry journal*. 2020;8(3).
3. Heithersay GS. Management of tooth resorption. *Aust Dent J*. 2007;52(1 Suppl):S105-21.
4. Heithersay GS. Invasive cervical resorption: an analysis of potential predisposing factors. *Quintessence Int*. 1999;30(2):83-95.
5. Jeng PY, Lin LD, Chang SH, Lee YL, Wang CY, Jeng JH, Tsai YL. Invasive Cervical Resorption-Distribution, Potential Predisposing Factors, and Clinical Characteristics. *J Endod*. 2020;46(4):475-82.
6. Galler KM, Grätz EM, Widbiller M, Buchalla W, Knüttel H. Pathophysiological mechanisms of root resorption after dental trauma: a systematic scoping review. *BMC Oral Health*. 2021;21(1):163.
7. Espona J, Roig E, Durán-Sindreu F, Abella F, Machado M, Roig M. Invasive Cervical Resorption: Clinical Management in the Anterior Zone. *J Endod*. 2018;44(11):1749-54.
8. Bardini G, Orrù C, Ideo F, Nagendrababu V, Dummer P, Cotti E. Clinical management of external cervical resorption: A systematic review. *Australian endodontic journal : the journal of the Australian Society of Endodontology Inc*. 2023;49(3):769-87.
9. Abbott PV. Prevention and management of external inflammatory resorption following trauma to teeth. *Aust Dent J*. 2016;61 Suppl 1:82-94.
10. Patel S, Brown J, Semper M, Abella F, Mannocci F. European Society of Endodontology position statement: Use of cone beam computed tomography in Endodontics: European Society of Endodontology (ESE) developed by. *Int Endod J*. 2019;52(12):1675-8.
11. da Cunha Isaltino M, da Silva Souza C, de Oliveira NG, de Melo Júnior PMR, Velozo Telles CT, de Albuquerque DS. Endodontic and Surgical Management of an Invasive Cervical Resorption in a Maxillary Central Incisor: A Case Report. *I Iran Endod J*. 2023;18(3):168-73.
12. Asgary S, Roghanizadeh L. Successful Management of a Typical Class 3 Invasive Cervical Root Resorption with Modified Pulpotomy: A Case Report. *Iran Endod J*. 2024;19(1):56-60.
13. Asgary S. Management of Pink Spot due to Class IV Invasive Cervical Root Resorption using Vital Pulp Therapy: A Case Report. *Iran Endod J*. 2023;18(2):110-2.
14. Hong B, Bulsara Y, Gorecki P, Dietrich T. Minimally invasive vertical versus conventional tooth extraction: An interrupted time series study. *J Am Dent Assoc*. 2018;149(8):688-95.
15. Plotino G, Abella Sans F, Duggal MS, Grande NM, Krastl G, Nagendrababu V, Gambarini G. European Society of Endodontology position statement: Surgical extrusion, intentional replantation and tooth autotransplantation: European Society of Endodontology developed by. *Int Endod J*. 2021;54(5):655-9.
16. Krug R, Connert T, Soliman S, Syfrig B, Dietrich T, Krastl G. Surgical extrusion with an atraumatic extraction system: A clinical study. *J Prosthet Dent*. 2018;120(6):879-85.
17. Parirokh M, Torabinejad M. Mineral trioxide aggregate: a comprehensive literature review--Part III: Clinical applications, drawbacks, and mechanism of action. *J Endod*. 2010;36(3):400-13.
18. Torabinejad M, Dinsbach NA, Turman M, Handysides R, Bahjri K, White SN. Survival of Intentionally Replanted Teeth and Implant-supported Single Crowns: A Systematic Review. *J Endod*. 2015;41(7):992-8.

Please cite this paper as: Nogueira Filho LRGC, Fernandes PHF, Nogueira LRGC, Telles CTV, Travassos RMC, de Albuquerque DS. Treatment of Invasive Cervical Resorption in A Central Incisor by Intentional Replantation: A Case Report. *Iran Endod J*. 2024;19(4): 296-301. *Doi:* 10.22037/iej.v19i4.45212.