



Revascularization of a Previously Treated Mandibular First Molar with Open Apices: A Case Report

Mojgan Feli ^a , Anita Taheri ^b , Mahgol Mehrabani ^{a*}

^a Department of Endodontics, School of Dentistry, Shahid Beheshti University of Medical Sciences, Tehran, Iran; ^b Dentofacial Deformities Research Center, Research Institute of Dental Sciences, School of Dentistry, Shahid Beheshti University of Medical Sciences, Tehran, Iran

Article Type: Case Report

Received: 10 Jan 2024

Revised: 02 Feb 2024

Accepted: 13 Feb 2024

Doi: 10.22037/iej.v19i2.43321

*Corresponding author: Mahgol Mehrabani, Department of Endodontics, School of Dentistry, Shahid Beheshti University of Medical Sciences, Tehran, Iran.

E-mail: mahgolmehrabani@yahoo.com

In this case report, the regeneration method was used to treat the previously treated first molar, which presented with symptoms of pain during chewing and secondary acute apical periodontitis. Due to the importance of preserving the patient's permanent teeth in order to maintain optimal space and function, the regeneration treatment was performed in two visits and according to the American Association of Endodontists (AAE) guidelines. The continuation of tooth root development, healing of periapical radiolucency and positive response to sensibility test (cold test) were observed during follow-up radiographs at intervals of 6 months, 1 year & 2 year.

Keywords: Immature Permanent Tooth; Open Apex; Previously Treated Tooth; Regenerative Endodontics; Revascularization

Introduction

Treating necrotic immature permanent dental pulp due to factors such as trauma or caries has always been challenging [1]. As a permanent tooth emerges, the root apex of the tooth typically develops within the first three years of eruption. Maintaining the health of the pulp during this period is of utmost importance. Numerous consequences may occur after dental caries or physical trauma, including pulp necrosis and endodontic infection. Due to the open apex in such cases, root treatment can be challenging, and the thin dentin walls make the tooth susceptible to cervical fractures [2].

Endodontic treatments for necrotic immature permanent teeth include apexification with calcium hydroxide, apexification with apical plug, and revascularization/regeneration. Apexification involves creating a calcified barrier along the root of an immature necrotic permanent tooth that cannot develop its root further. These teeth are treated by calcium hydroxide or Mineral trioxide aggregate (MTA) plug; this method is likely to cause root fractures due to the thin, weak walls [3, 4]. Regeneration involves the growth of new pulp tissue and the continuation of root formation by stem cells in immature, noninfectious teeth [5].

Root development is carried out by two types of cells: odontoblasts and epithelial cells of Hertwig's sheath. Epithelial cells of Hertwig's sheath allow the differentiation of stem cells into odontoblasts, which form the dentine of the root [4, 5].

Mesenchymal cells originate from a variety of cells, including stem cells from the apical papilla (SCAP) and stem cells from the remaining pulp tissue (DPSCs). Due to their proximity to periapical tissues with a high blood supply, Hertwig's sheath and SCAP cells can survive despite infection and pulp necrosis [6, 7]. Considering the importance of Hertwig's epithelial root sheath and SCAP cells to the regrowth of roots after pulpal damage, it is vital to protect them during root treatment preparation. Regenerative endodontic treatment (RET) researches are primarily focused on treating immature teeth with necrotic pulp [8]. Despite the similarities between pulped treated teeth and necrotic teeth in their biological bases, there are also substantial differences between them. As a result of the microenvironmental conditions of the root canal, performing regeneration on treated pulped teeth with an open apex and an infected root canal presents more challenges. A number of factors determine the prognosis of the treatment, including the previous pulp treatment on the dentine walls, the accumulation of debris within the

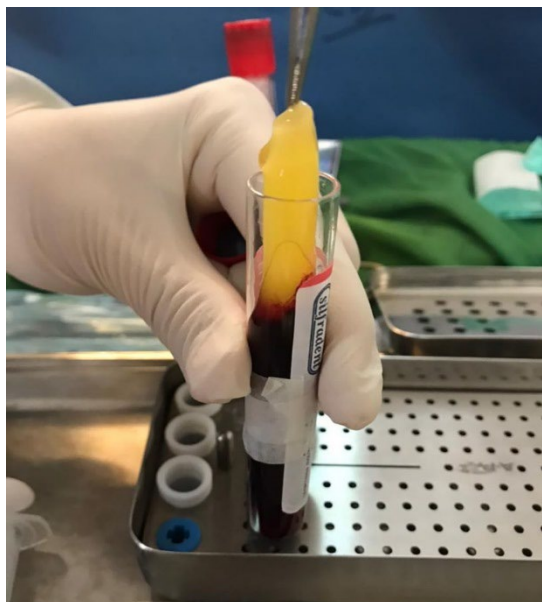


Figure 1. High platelet-rich fibrin (PRF)

canal, and the presence of different microbial flora [9]. According to Nevins and Cymermanvn [10], regeneration was effective in treating the pulp of immature teeth that were previously treated. Since then, numerous reports have been published regarding the successful regeneration of teeth following pulp treatment.

In this report, we present a successful case of a regeneration method for the retreatment of the mandibular permanent first molar in a 9-year-old girl with an infected root canal and secondary acute apical periodontitis who had previously undergone pulpotomy and presented with infected root canals.

Case Presentation

The patient, a healthy 9-year-old girl, was referred to the endodontics department of Shahid Beheshti School of Dentistry to evaluate and treat tooth #30. The patient's chief complaint was "My tooth hurts when I chew." The patient's medical history was normal; she had no particular medical conditions and was not under any medication at the initial visit. The patient's parents have reported a history of pain in tooth #30 that was treated by apexogenesis and a stainless-steel crown (SSC) afterward at the age of 7. However, the child recently experienced pain while chewing again.

In the clinical evaluations, the patient responded negative to the cold test. The electric pulp test (EPT) was invalid due to the presence of the SSC and lack of access to the tooth structure. The tooth was sensitive to percussion and palpation. Periodontal probing length was normal. Abnormal mobility was not seen either. In the assessment of periapical radiography, a radiolucent lesion was seen in the apical region of both roots. The pulp and

periapical condition diagnosis was reported as "Previously treated with an infectious root canal system" and "Secondary acute apical periodontitis". Treatment options were presented to the patient's parents which included apexification with MTA plug or regeneration or extraction. The advantages and disadvantages of each method were explained to the patient, and the patient finally chose the regeneration treatment. Written consent was obtained from the patient's parents for treatment.

After the administration of the local anesthesia via inferior alveolar nerve block containing 2% lidocaine with epinephrine 1/100000 (Darupakhsh Co./Tehran/Iran), isolation was established by rubber dam, and the access cavity was made through the SSC due to better preservation of the isolation. The working length was estimated by periapical radiography, which was as follows (mesiobuccal canal: 16 mm, mesiolingual canal: 16 mm, distal canal: 17 mm).

The canals were irrigated with 20 mL of 1.5% sodium hypochlorite with a #30 gauge side vented needle (Canal clean; Biodent, Korea), one millimeter shorter than the working length. In the end, 20 mL 17% EDTA was used as final irrigation. Then the canals were dried with sterile paper cones, then calcium hydroxide powder (Golchadent/Tehran/Iran) and normal saline mixture with paste consistency was placed inside the canals. The access cavity was filled with glass ionomer (Fuji II LC Gold, GC Corp, Tokyo, Japan).

Patient returned two weeks later to continue the treatment. First, the response to the initial treatment was evaluated. No signs of infection were seen. This time, 3% mepivacaine without vasoconstrictor was used as local anesthetic. After inferior alveolar nerve block injection, isolation was established with a rubber dam. The glass ionomer was removed. The calcium hydroxide inside the canals was removed by gentle irrigation with 20 mL 17% EDTA. Then the canals were dried with sterile paper cone. Platelet-rich fibrin (PRF) was used to form a blood clot. In order to prepare PRF, 9 mL of patient's blood was taken from cubital vein and poured into a sterile tube. The tube was placed in a centrifuge at a speed of 1300 rpm for 8 min. Blood was separated and compressed in the compression box (Figure 1). Then AGM-MTA (Andiseh Gostar Masoud, Tehran, Iran) was placed as a covering material in the coronal third of the root with a thickness of 3 mm. Glass ionomer (Fuji II LC Gold, GC Corp., Tokyo, Japan) with a thickness of 3 mm was placed on the MTA for flooding and cured for 40 sec. Finally, definitive restoration of the remaining cavity was performed with amalgam.

The follow-up for this patient was done clinically and radiographically at intervals of six months, one year, and two years. There was no sign of pain, swelling, or sinus tract. In the 6-month follow-up. A slight increase in the thickness of the root

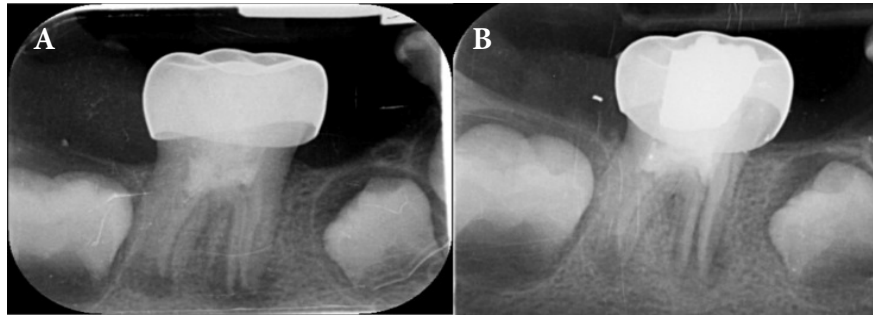


Figure 2. A) Pretreatment; B) Immediately after treatment

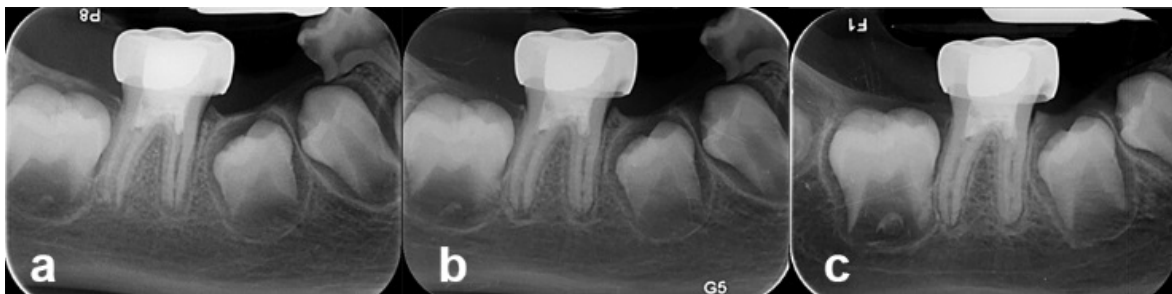

Figure 3. A) Six months follow-up; B) One year follow-up; C) Two years follow-up

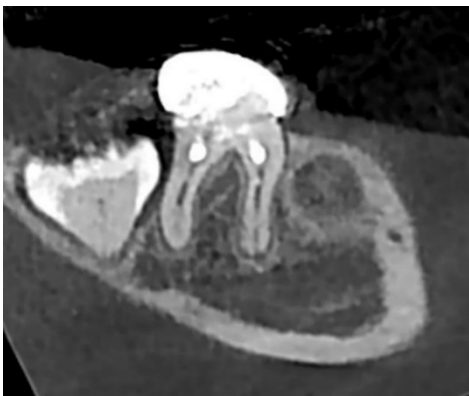

Figure 4. One year follow-up CBCT

walls & increased root length was observed in 1 year follow-up. A minor response to the cold test was observed in the one-year follow-up. The electrical test was not possible due to the presence of the stainless coating. In the one-year follow-up, the periapical radiolucency was resolved entirely (Figures 2-4).

According to our findings, a favorable long-term prognosis is predicted for this treatment.

Discussion

During the process of regeneration, disinfection and cleaning are the most crucial steps [11]. Tissue engineering is adversely affected by bacteria remaining in the root canal [12]. Despite claims that antibiotic pastes with a high consistency (1000

mg/mL) can prevent canal bacteria from growing, there are also disadvantages, including toxicity to SCAPs and the development of antibiotic resistance [13]. Lowering the concentration of antibiotics in the pastes has been suggested to reduce the toxic effect on stem cells, but it does not have the same effectiveness in removing bacteria as the full concentration [14]. In order to preserve the root canal system from contamination and bacteria, an access cavity through the SSC is prepared to create better isolation during treatment.

An animal study has shown that the fracture resistance in immature teeth treated with the regeneration method is higher than untreated immature teeth, which results in higher long-term survival rate [15].

Studies have shown that treating immature teeth with the regeneration method results in higher long-term survival rates, as the open apex allows for continuous blood flow to the root canal space. The diameter of the apex is also related to the success of treatment, as larger diameters (diameter > 1 mm) are more likely to have a successful response [16]. The bacterial population and composition in the root canal system of previously treated immature teeth differ from immature necrotic teeth. In necrotic teeth (primary infection), we are mainly faced with obligate anaerobic Gram-negative bacteria, while in root canals with previous treatment (resistant infection), mostly facultative anaerobic Gram-positive bacteria are seen [17]. In other words, the disinfection of the root canal system in cases with previous treatment and resistant infection faces a more difficult challenge

than the disinfection of canals with primary infection. More *in-vitro* and *ex-vivo* studies are needed to provide a suitable protocol for disinfection.

In the present case, an increase in the thickness and length of the root was observed during the one-year follow-up, contrary to a previous case report by Maria *et al.* where no further development occurred. The use of a lower concentration of sodium hypochlorite during the initial treatment preserved the health of the mesenchymal stem cells; while in the case of Mari *et al.*, high concentration sodium hydroxide was used [17, 18].

A five-part classification for the possible response of an immature tooth under regeneration treatment exists, with this case falling under class I where the thickness of the root canal wall increases and the tooth continues to develop [19, 20].

Regeneration treatment has been proven to be a better option than apexification for necrotic immature teeth, as it allows for an increase in root thickness and length. This method was chosen to re-treat the patient's tooth in order to preserve the permanent tooth, the available space, as well as the width and height of the bone and maintaining the occlusal function. This case report demonstrates the successful re-treatment of a tooth using the regeneration method.

Conflict of interest

None.

Funding support

No funding was received for this study.

Authors' contributions

Mojgan Feli: data collector, author; Mahgol Mehrabani: author, translator; Anita Taheri: editor

References

- Kotloor J, Velmurugan N. Revascularization for a necrotic immature permanent lateral incisor: a case report and literature review. *Int J Paediatr Dent.* 2013;23(4):310-6.
- Rafter M. Apexification: a review. *Dent Traumatol.* 2005;21(1):1-8.
- Chueh LH, Ho YC, Kuo TC, Lai WH, Chen YH, Chiang CP. Regenerative endodontic treatment for necrotic immature permanent teeth. *J Endod.* 2009;35(2):160-4.
- Park M, Ahn BD. Immature permanent teeth with apical periodontitis and abscess treated by regenerative endodontic treatment using calcium hydroxide and MTA: a report of two cases. *Pediatr Dent.* 2014;36(3):107-10.
- Safi L, Ravanshad S. Continued root formation of a pulpless permanent incisor following root canal treatment: a case report. *Int Endod J.* 2005;38(7):489-93.
- Huang GT, Sonoyama W, Liu Y, Liu H, Wang S, Shi S. The hidden treasure in apical papilla: the potential role in pulp/dentin regeneration and bioroot engineering. *J Endod.* 2008;34(6):645-51.
- Sonoyama W, Liu Y, Yamaza T, Tuan RS, Wang S, Shi S, Huang GT. Characterization of the apical papilla and its residing stem cells from human immature permanent teeth: a pilot study. *J Endod.* 2008;34(2):166-71.
- Tong HJ, Sim YF, Berdouses E, Al-Jundi S, El Shahawy O, Nazzal H. Regenerative endodontic therapy (RET) for managing immature non-vital teeth: experiences and opinions of paediatric dental practitioners in the European and Arabian regions. *Eur Arch Paediatr Dent.* 2021;22(2):145-55.
- Nosrat A, Bolhari B, Saber Tahan S, Dianat O, Dummer PMH. Revitalizing previously treated teeth with open apices: A case report and a literature review. *Int Endod J.* 2021;54(10):1782-93.
- Nevins AJ, Cymerman JJ. Revitalization of open apex teeth with apical periodontitis using a collagen-hydroxyapatite scaffold. *J Endod.* 2015;41(6):966-73.
- Fouad AF, Nosrat A. Pulp regeneration in previously infected root canal space. *Endodontic Topics.* 2013;28(1):24-37.
- Torabinejad M, Nosrat A, Verma P, Udochukwu O. Regenerative Endodontic Treatment or Mineral Trioxide Aggregate Apical Plug in Teeth with Necrotic Pulp and Open Apices: A Systematic Review and Meta-analysis. *J Endod.* 2017;43(11):1806-20.
- Ruparel NB, Teixeira FB, Ferraz CC, Diogenes A. Direct effect of intracanal medicaments on survival of stem cells of the apical papilla. *J Endod.* 2012;38(10):1372-5.
- AlSaeed T, Nosrat A, Melo MA, Wang P, Romberg E, Xu H, Fouad AF. Antibacterial Efficacy and Discoloration Potential of Endodontic Topical Antibiotics. *J Endod.* 2018;44(7):1110-4.
- Zhou R, Wang Y, Chen Y, Chen S, Lyu H, Cai Z, Huang X. Radiographic, Histologic, and Biomechanical Evaluation of Combined Application of Platelet-rich Fibrin with Blood Clot in Regenerative Endodontics. *J Endod.* 2017;43(12):2034-40.
- Estefan BS, El Batouty KM, Nagy MM, Diogenes A. Influence of Age and Apical Diameter on the Success of Endodontic Regeneration Procedures. *J Endod.* 2016;42(11):1620-5.
- Miltiadous ME, Floratos SG. Regenerative Endodontic Treatment as a Retreatment Option for a Tooth with Open Apex - A Case Report. *Braz Dent J.* 2015;26(5):552-6.
- Roghanizadeh L, Fazlyab M. Revascularization and Apical Plug in an Immature Molar. *Iran Endod J.* 2018;13(1):139-42.
- Chen MY, Chen KL, Chen CA, Tayebaty F, Rosenberg PA, Lin LM. Responses of immature permanent teeth with infected necrotic pulp tissue and apical periodontitis/abscess to revascularization procedures. *Int Endod J.* 2012;45(3):294-305.
- Hajizadeh S, Youzbashi Zadeh R, Vatanparast N. Pulp Revascularization in Three Immature Permanent Mandibular Molars with Necrotic Pulp: A Case Series. *Iran Endod J.* 2019;14(4):301-5.

Please cite this paper as: Feli M, Taheri A, Mehrabani M. Revascularization of a Previously Treated Mandibular First Molar with Open Apices: A Case Report. *Iran Endod J.* 2024;19(2): 120-3. *Doi:* 10.22037/iej.v19i2.43321.

