









Pulp Canal Obliteration Following Traumatic Dental Injury in an Upper Lateral Incisor: A Case Report with 3-year Follow-up

Marina da Cunha Isaltino ^{a*} , Wesley Viana de Sousa ^a , Luiza de Almeida Souto Montenegro ^a ,
Christianne Tavares Velozo Telles ^a , Marcelly Cristiny Figueredo Cassimiro da Silva ^a , Diana
Santana de Albuquerque ^a 

^a Department of Dentistry, Universidade de Pernambuco (UPE), Recife, Pernambuco, Brazil

Article Type: Case Report

Received: 21 Jan 2024

Revised: 23 Feb 2024

Accepted: 14 Mar 2024

Doi: 10.22037/iej.v19i2.43307

*Corresponding author: Marina da Cunha Isaltino, University of Pernambuco (UPE), Professor Luis Freire Avenue, 700, Cidade Universitária, Recife/PE, Brazil. Zip code: 50740-540.

E-mail: marina.isaltino@upe.br

Endodontic management of teeth afflicted with pulp canal obliteration faces a challenge due to the heightened risk of complications including excessive wear, perforation, and suboptimal chemomechanical preparation. This report aims to elucidate the clinical endodontic strategy employed in addressing pulp canal obliteration after a history of dental trauma and an associated periradicular lesion in an upper lateral incisor. A patient visited the dental emergency department with symptoms of apical swelling, acute persistent pain, and discoloration of tooth 22. Following comprehensive clinical evaluation and cone-beam computed tomography, the diagnosis of pulp canal obliteration involving the cervical and middle thirds of the tooth, alongside an acute periradicular abscess was established. Root canal was accessed using tomographic image planning, augmented by loupe magnification and ultrasonic instrumentation. Precise identification of the access cavity was radiographically confirmed, preceded by thorough irrigation with 2.5% sodium hypochlorite and subsequent cervical and middle third preparation. Verification of the working length by an electronic apex locator ensured precise apical preparation, followed by passive ultrasonic irrigation to optimize disinfection and to enhance penetrability of intracanal calcium hydroxide medication, administered for 15 days to eliminate microbial invasion. Upon resolution of symptoms, root canal obturation employing thermo-mechanical compaction and coronal sealing with composite resin was accomplished. Radiographic assessment after a one-year interval presented evidence of lesion regression and bone repair. Subsequent cone-beam computed tomography imaging at the three-year follow-up confirmed complete healing of the periradicular tissues, attesting to the efficacy of the endodontic intervention.

Keywords: Dentistry; Endodontics; Pulp Canal Obliteration; Traumatic Dental Injury

Introduction

Traumatic dental injury represents a serious clinical concern that can affect the integrity and vitality of teeth. Among the various complications associated with traumatic injuries to the teeth, pulp canal obliteration (PCO) is an intriguing and complex phenomenon that requires clinical and scientific attention [1]. Pulp canal obliteration is the pulpal response to trauma; it is characterized by the rapid deposition of hard tissue in the root canal and pulp chamber. This condition more

frequently develops in teeth after concussion and subluxation injuries [2].

The capacity of the root canal to respond to trauma through obliteration has received little investigation [3]; however, PCO is known to consist of the rapid deposition of mineralized tissue, which results in a significant reduction in the root canal space due to the apposition of dentin over time [4].

Treatment of severely calcified teeth is challenging and complex because of the increased risk of iatrogenic complications such as excessive wear, perforation and ineffective



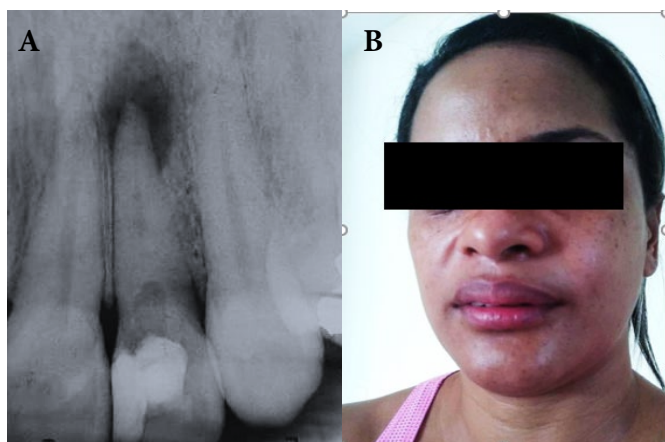

Figure 1. A) Initial periapical radiographic image of tooth #22; indicating the presence of a large radiolucent area in the apical region; B) Facial asymmetry and increased volume on the left side

chemo-mechanical preparation that can result in endodontic treatment failure [5]. The use of resources and technologies such as surgical loupe magnification and ultrasonic inserts, combined with cone-beam computed tomography (CBCT) and guided endodontics, increases the predictability and accuracy of the planning and resolution of these cases [6, 7].

This case report aimed to describe the treatment approach for PCO after a history of dental trauma and periradicular lesion in the upper left lateral incisor.

Case Report

A 40-year-old female patient presented to the dental emergency department with facial swelling. Being aware of the treatment risks, the patient agreed to the proposed procedures by signing the free and informed consent form. The patient also received information about the need for coronal sealing after the completion of treatment and follow-up for the assessment of healing. The data obtained during anamnesis revealed that the patient's medical history would not influence the course of treatment.

During anamnesis, the patient reported that the tooth has suffered trauma, which resulted in a crown fracture that involved enamel and dentin. Later on, the patient underwent unsuccessful endodontic treatment performed by another professional, who referred her to a specialist. Periapical radiographic examination revealed a periradicular lesion and obliteration of the root canal in the cervical and middle thirds (Figure 1A).

Intraoral clinical examination showed a color change in tooth 22, as well as swelling in the apical region and acute persistent pain (Figure 1B). Apical percussion and palpation

tests were positive. Response to a pulp sensibility (cold) test (Endo Ice Spray, Maquira, Maringá, PR, Brazil) was negative. As complementation, periodontal probing was performed (FAVA Millimeter Probe, São Paulo, SP, Brazil) and the result was within the normal range.

Periapical radiography and CBCT were performed to confirm the diagnosis and for better case planning. The tomographic images were obtained in the sagittal, coronal and axial planes and careful assessment showed the presence of PCO in the cervical third and the beginning of middle third (Figures 2A-2C).

Based on the clinical and radiographic findings, the pulp and periapical diagnosis was previously initiated treatment in the presence of PCO and an acute periapical abscess (AAE, 2020)[8, 9]. Therefore, the proposed treatment was regenerative endodontic intervention.

A second procedure was scheduled for treatment continuation. After antiseptics with 0.12% chlorhexidine digluconate mouthwash for 1 min, topical 20% Benzocaine (Benzotop gel; Nova DFL, Rio de Janeiro, RJ, Brazil) was applied as anesthetic, followed by anterior superior alveolar nerve block and palatal anesthesia with 4% articaine with 1:100,000 epinephrine (DFL, Rio de Janeiro, RJ, Brazil). After absolute isolation of the operating field with a #212 clamp, an Ostby arch (Maquira, Maringá, PR, Brazil) and a rubber sheet (All Prime, Aparecida, São Paulo, SP, Brazil), the glass ionomer sealing material was removed and root canal was accessed at a penetration depth of 2-3 mm and parallel to the long axis of the tooth using a magnifying loupe (Zeiss, Jena, Germany) and an E3D ultrasonic insert with a 30% power (Helse, Santa Rosa de Viterbo, SP, Brazil), refrigerated with sterile saline (JP Farma, Ribeirão Preto, SP, Brazil).

After selective wear, an access cavity was identified and a #10K C-Pilot file (VDW, Munich, Germany) was inserted for radiographic confirmation (Figure 3A). Once the root canal was located, 2.5% sodium hypochlorite was chosen as the irrigant solution and was injected into the canal with a 5-mL sterile disposable syringe (Ultradent, Joinville, SC, Brazil) and a NaviTip tip (Ultradent). First, a glide path was created with a #10 C-Pilot file (VDW). Next, a Reciproc Blue 25/0.08 instrument (R25; VDW, Munich, Germany) coupled to an X-Smart Plus motor (Dentsply Maillefer, Ballaigues, Switzerland) was selected for preparation of cervical and middle thirds of the root canal. For confirmation of the working length, electronic odontometry was performed with a Root ZX II locator (J. Morita, Kyoto, Japan) at a 22 mm length, using the incisal border as the reference. For irrigation, passive ultrasonic agitation at the power of 20% was performed with an Irrisonic insert (Helse) for 20 sec.

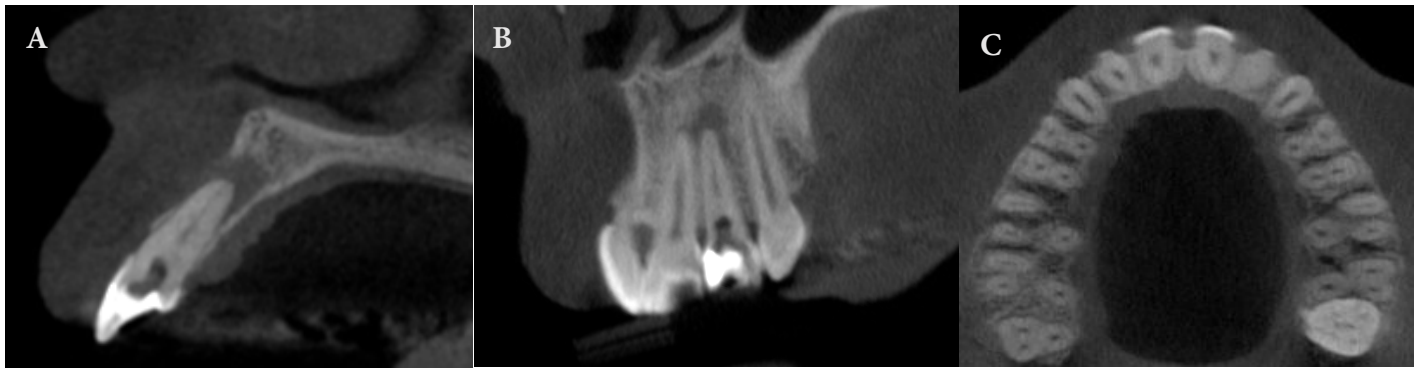

Figure 2. A) Sagittal section showing obliterated canal in the cervical third and rupture of cortical bone through the vestibular; B) Coronal section demonstrating extensive periapical lesion; C) Axial section showing obliteration of the canal in the cervical third

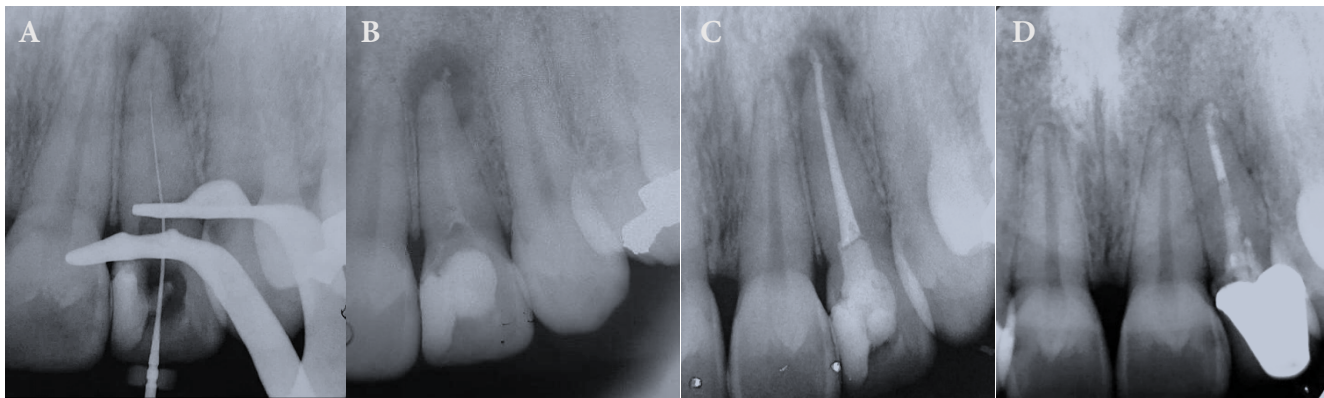

Figure 3. A) Periapical radiograph confirming canal location with #10 k file; B) Periapical radiograph showing the intracanal medication; calcium hydroxide; C) Periapical radiograph immediately after the endodontic treatment of tooth #22; D) Periapical radiograph after one year follow-up

Apical preparation was completed with a Reciproc Blue R25 (VDW) file and agitation of the irrigant solution was performed with an E1 Irrisonic insert (Helse) with a 20% power for three 20-sec cycles, followed by 5 mL of 0.9% saline to inactivate the 2.5% sodium hypochlorite. Next, 5 mL of 17% ethylenediaminetetraacetic acid (Maquira) was injected to remove the smear layer, followed by the same agitation procedure. Final irrigation was performed with 5 mL of 0.9% saline (JP Farma) and the root canal was dried with sterile absorbent paper points (Cell Pack, VDW). Calcium hydroxide (Ultracal XS, Joinville, SC, Brazil) was used as intracanal medication, which was submitted to the same agitation procedure using an E1 insert (Helse). The medication was kept in the canal for 15 days to increase penetrability of the dentinal tubules and to reduce the microbial load (Figure 3B).

In the third session, after full symptom resolution, the intracanal medication was removed by irrigation with 2.5% sodium hypochlorite and the canal was enlarged with a Reciproc Blue 40/0.06 file (R40; VDW). The same final agitation protocol was applied to enhance cleaning and removal of the intracanal

medication. The root canal was filled with gutta-percha by thermomechanical compaction using a 40/0.06 filler cone (VDW), with no need for accessory cones. EndoSequence BC Sealer (Brasseler USA, Savannah, GA, USA) was used as endodontic cement and the crown was sealed with a 3-mm Bulk Fill Flow A3 plug (3M ESPE, Saint Paul, MN, USA), followed by restoration with Z350 A3B resin (3M ESPE) on the palatal surface (Figure 3C).

The patient returned to the office after one year and exhibited a restored tooth with satisfactory occlusion. A follow-up periapical radiograph was obtained to compare regression of the lesion, which revealed evident bone repair (Figure 3D). After 3 years of follow-up, a CBCT scan confirmed repair of the periradicular tissues (Figure 4A and 4C).

Discussion

The present case had an unfavorable prognosis due to its complexity. The challenge lied in the nature of PCO, which originated in the pulp chamber and extended to the middle third

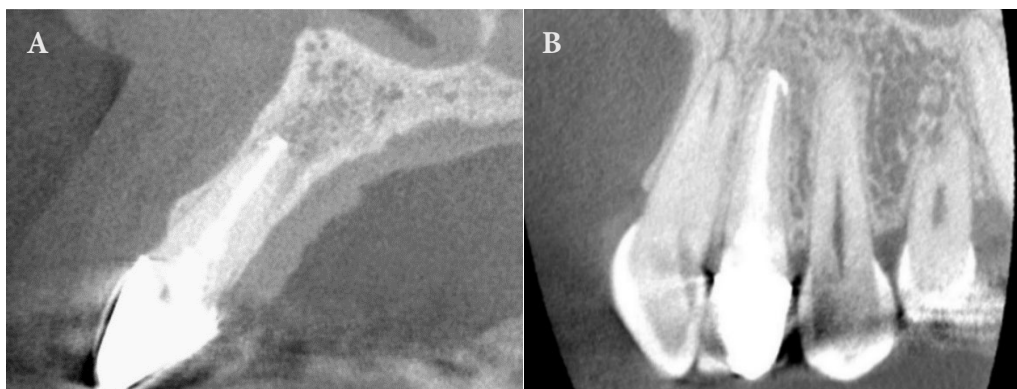

Figure 4. A) Sagittal section confirmed repair of periradicular tissues after three years; B) Coronal section showing the tomographic appearance of tooth #22 demonstrating good sealing of the root canal after 2 years of follow-up

of tooth 22. This scenario was accompanied by painful symptoms, intraoral swelling in the buccal region, and a periradicular lesion that resulted in cortical bone disruption also on the buccal side and required immediate care.

Pulp canal obliteration prevents access to the entrances of the canal, modify its internal anatomy which can cause instrument deviation, and therefore represents a major treatment challenge, especially in cases of pulp necrosis [10, 11]. This condition is a pulpal response associated with a traumatic event and is diagnosed based on the combination of radiographic and clinical-anamnestic data [12]. Systematic reviews [13, 14] support the theory that traumatic dental injury can affect both the pulp and the periodontium and the fate of the pulp tissue will vary according to the intensity of the injury and the stage of root development [15]. Therefore, endodontic intervention is of fundamental importance for the treatment of necrotic teeth and periradicular lesions.

Precise localization of the calcified canals is the key to achieving desirable outcomes and is crucial to minimize the loss of tooth structure, increasing tooth resistance. Guided endodontics emerged as an alternative tool for teeth with partially or completely obliterated canals [11, 16]. The advantages of three-dimensional planning using special software, combined with CBCT and the creation of models that guide the drill to the calcified root canal, include reduction in the size of the access cavity and preservation of the tooth structure, increasing predictability when compared to free-hand techniques. However, failure in fixing the guide model to the bone and inaccuracies generated by manually performing the mesh merger software can cause perforations, which is a limitation of guided endodontics [4].

The present case occurred at the beginning of the COVID-19 pandemic when establishments, businesses, and medical

and dental offices were closed, with only emergency procedures being allowed as in the case reported here. The need of emergency treatment of the presented case within the pandemic scenario impaired the use of guided endodontics. Thus, CBCT and ultrasound were used, which allowed us to determine the direction and length of the initial portion of obliteration and the continuation of endodontic treatment.

Loupe magnification, combined with appropriate illumination and the use of ultrasonic tips is a highly effective approach to explore the pulp chamber at greater depths, increasing reliability in the identification of obliterated canals [11]. The oscillatory movements of ultrasonic inserts permit more conservative preparation, ensuring greater safety and control during cutting [17].

Conclusion

The present study described the emergency treatment of an upper lateral incisor with PCO. The 3-year follow-up results showed that the correct diagnosis associated with modern root canal instrumentation techniques enabled the positive evolution of clinical manifestations. Imaging examinations revealed regression of the periradicular lesion and bone repair.

Acknowledgments

This study was financed in part by the Coordenação de Aperfeiçoamento de Pessoal de Nível Superior, Brasil (CAPES), Finance Code 001

Conflict of interest

None.

Funding support

No funding was received for this study.

Authors' contributions

Data collocation: Marina da Cunha Isaltino, Wesley Viana de Sousa, Luiza de Almeida Souto Montenegro; Authors: Christianne Tavares Velozo Telles, Marceley Cristiny Figueredo Cassimiro da Silva; Editor: Diana Santana de Albuquerque

References

- Reddy LV, Bhattacharjee R, Misch E, Sokoya M, Ducic Y. Dental Injuries and Management. *Facial Plast Surg.* 2019;35(6):607-13.
- McCabe PS, Dummer PM. Pulp canal obliteration: an endodontic diagnosis and treatment challenge. *Int Endod J.* 2012;45(2):177-97.
- Vinagre A, Castanheira C MA, Palma PJ, Ramos JC. Management of pulp canal obliteration-systematic review of case reports.
- Fonseca Tavares WL, de Oliveira Murta Pedrosa N, Moreira RA, Braga T, de Carvalho Machado V, Ribeiro Sobrinho AP, Amaral RR. Limitations and Management of Static-guided Endodontics Failure. *J Endod.* 2022;48(2):273-9.
- Bastos JV, Côrtes MIS. Pulp canal obliteration after traumatic injuries in permanent teeth - scientific fact or fiction? *Braz Oral Res.* 2018;32(suppl 1):e75.
- Moreno-Rabié C, Torres A, Lambrechts P, Jacobs R. Clinical applications, accuracy and limitations of guided endodontics: a systematic review. *Int Endod J.* 2020;53(2):214-31.
- Nabavi S, Navabi S, Mohammadi SM. Management of Pulp Canal Obliteration in Mandibular Incisors with Guided Endodontic Treatment: A Case Report. *Iran Endod J.* 2022;17(4):216-9.
- Rojas-Gutiérrez WJ, Pineda-Vélez E, Agudelo-Suárez AA. Regenerative Endodontics Success Factors and their Overall Effectiveness: An Umbrella Review. *Iran Endod J.* 2022;17(3):90-105.
- Youssef A, Ali M, ElBokk A, Hassan R. Regenerative endodontic procedures for the treatment of necrotic mature teeth: A preliminary randomized clinical trial. *Int Endod J.* 2022;55(4):334-46.
- de Toubes KMS, de Oliveira PAD, Machado SN, Pelosi V, Nunes E, Silveira FF. Clinical Approach to Pulp Canal Obliteration: A Case Series. *Iran Endod J.* 2017;12(4):527-33.
- Llaquet Pujol M, Vidal C, Mercadé M, Muñoz M, Ortolani-Seltenerich S. Guided Endodontics for Managing Severely Calcified Canals. *J Endod.* 2021;47(2):315-21.
- Spinas E, Deias M, Marni A, Giannetti L. Pulp canal obliteration after extrusive and lateral luxation in young permanent teeth: A scoping review. *Eur J Paediatr Dent.* 2021;22(1):55-60.
- Lima TFR, Dos Santos SL, da Silva Fidalgo TK, Silva EJNL. Vitality Tests for Pulp Diagnosis of Traumatized Teeth: A Systematic Review. *J Endod.* 2019;45(5):490-9.
- Vinagre A, Castanheira C MA, Palma PJ, Ramos JC. Management of pulp canal obliteration-systematic review of case reports.
- Krastl G, Zehnder MS, Connert T, Weiger R, Kühl S. Guided Endodontics: a novel treatment approach for teeth with pulp canal calcification and apical pathology. *Dent Traumatol.* 2016;32(3):240-6.
- Wu M, Liu M, Cheng Y, Tang W, Yan P, Jiang H. Treatment of Pulp Canal Obliteration Using a Dynamic Navigation System: Two Case Reports. *J Endod.* 2022;48(11):1441-6.
- Cottle E, Kulild JC, Walker MP. A comparison of dentin cutting efficiency of 4 round-tipped ultrasonic instruments. *J Endod.* 2013;39(8):1051-3.

Please cite this paper as: da Cunha Isaltino M, de Sousa WV, de Almeida Souto Montenegro L, Velozo Telles CT, da Silva MCFC, de Albuquerque DS. Pulp Canal Obliteration Following Traumatic Dental Injury in an Upper Lateral Incisor: A Case Report with 3-year Follow-up. *Iran Endod J.* 2024;19(2): 134-8. *Doi: 10.22037/iej.v19i2.43307.*