



Evaluation of Root Canal Morphology of Mandibular Premolars Using Cone-beam Computed Tomography in Golestan Province, North of Iran

Maryam Sajed ^a , Shiva Alvandifar ^{b*} , Maisa Mallahi ^c

^a Student Research Committee, Dental Faculty, Golestan University of Medical Science, Gorgan, Iran; ^b Departments of Endodontics, Dental Faculty, Golestan University of Medical Science, Gorgan, Iran; ^c Departments of Radiology, Dental Faculty, Golestan University of Medical Science, Gorgan, Iran

Article Type: Original Article

Received: 26 Jan 2024

Revised: 06 April 2024

Accepted: 27 April 2024

Doi: 10.22037/iej.v19i3.40052

*Corresponding author: Shiva Alvandifar, Departments of Endodontics, Dental Faculty, Golestan University of Medical Science, Gorgan, Iran.

E-mail: shiva.alvandifar@gmail.com

Introduction: Successful endodontic treatment depends on completely clearing, shaping, and filling the prepared canals. Knowledge of the common and aberrant varying pulp anatomies is essential for suitable root canal treatment. Since, this anatomy is complex and varies morphologically in different populations. This study aims to determine the number of roots, canals, and evaluation of mandibular premolars canals using cone-beam computed tomography (CBCT) images in one of Iran's northern provinces (Golestan). **Materials and Methods:** CBCT axial, coronal, and sagittal slices of two hundred and twelve mandibular premolars were analyzed to determine the number of roots and canals based on Vertucci type. The images were analyzed in a one-millimeter slice in mesiodistal and buccolingual dimensions based on gender. The data were analyzed using the Chi-square test to compare the components if the defaults were not established. A significance level of 0.05 was considered. **Result:** Of the two hundred twelve teeth evaluated, 130 (61.3%) were first premolars, and 82 (38.6%) were second premolars. Most first premolars (78.5%) and almost all second premolars (97.6%) had one root. Morphological types of root canals were identified based on Vertucci's classification types I, II, III, IV, V, or VIII, and type I was the most frequent. There were no significant associations between number of roots and sex ($P>0.05$). **Conclusion:** Mandibular premolars mostly had one root and type I Vertucci morphology. The frequency of two-canal premolars was higher in the male population. Although the abundance of two or three roots with different morphologies was also observed, the possibility of the presence of an additional root canal should be considered.

Keywords: Bicuspid; Cone-beam Computed Tomography; Dental Pulp; Mandible

Introduction

Root canal treatment is one of the essential treatments in dentistry used to treat teeth damaged due to caries, pulp inflammation/infection and trauma [1]. Tooth growth and development are a dynamic and complex process [2]. Inner and outer enamel epithelial cells form a bilayered epithelial sheath named Hertwig's epithelial root sheath (HERS), which will continue to grow apically and determine the root's shape. This results in increased variations and a varying number of branches and canals in a single-rooted tooth, such as the mandibular second premolar [3-6]. successful endodontic treatment depends on completely clearing infected or necrotic pulp tissues and shaping and filling the prepared canals [7]. Insufficient knowledge of the morphological variations of root canals can result in missing and inadequate instrumentation of root canals [8]. An untreated root

canal can lead to the persistent presence of microorganisms and necrotic tissue inside the canal, accounting for a high rate of root canal failure [1, 9]. Knowledge of the common and aberrant varying pulp morphologies is essential for a suitable treatment plan before beginning root canal treatment [10, 11]. Such variations may include the number of roots and the number and configuration of the root canals [12, 13]. Due to the high variability of root canal configuration that varies among races and geographic regions, especially in mandibular first and second premolars, root canal treatment is challenging and the results may be poor [14-16]. Many studies of different populations have reported an extremely complex canal morphology for the premolar teeth showing additional canals and roots [8]. Mandibular premolars are often considered as single-root and single-canal teeth, but due to many varies morphologies and lack of dentists' knowledge, failure in root treatment occurs. Variation in canal morphology is seen mostly in



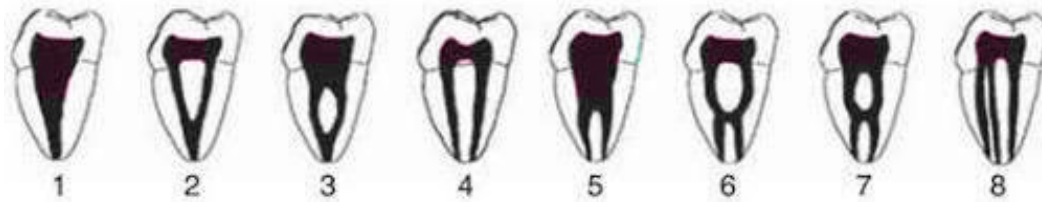


Figure 1. Vertucci classification

mandibular first Premolars [17]. These teeth often present an 8-shaped cross-section with one or up to three roots that may occur fused or separate [14]. Although findings of three-root canals with separate apical foramina in mandibular premolars are relatively rare [18]. Among various classification systems, Vertucci's classification is used widely [1]. He classified the root canal configuration into eight categories: type I (1), type II (1-2), type III (1-2-1), type IV (2), type V (1-2), type VI (2-1-2), type VII (1-2-1-2) and type VIII (3) [19] (Figure 1).

The internal anatomy of a root canal is mostly identified using methods such as tooth clearing, hard tissue section, 2D radiography, *in vitro* macroscopic examination, and cone-beam computed tomography (CBCT) [20-22]. Radiography is essential for diagnosis, treatment plan, follow-up, and treatment outcomes [23]. However, traditional X-ray images have intrinsic deficiencies and provide a two-dimensional image of a three-dimensional structure, which can lead to superimposition, distortion, and magnification, compromising diagnostic accuracy [13, 24, 25]. CBCT is a new technology built for angiography, among other tasks, at Mayo in 1982 and then used for maxillofacial imaging.[26]. This three-dimensional radiographic assessment of teeth and their surrounding structures is eligible for aiding accurate diagnosis, predictable treatment planning and management of complex endodontic problems [27, 28]. CBCT can provide accurate images below the millimeter limit in short scans with lower doses. This method (CBCT) can provide a three-dimensional image of a root canal in the axial, sagittal, and coronal dimensions [8] without the limitations of sample preparation or tooth destruction [1]. Studies of the internal and external anatomy of teeth have shown that anatomic variations can be extremely complex in all types of teeth. Several factors contribute to the variations in ethnicity, age, gender, and study design [19].

However, no CBCT studies have described the anatomy of mandibular premolars in the Golestan Province. Therefore, this study aimed to investigate the root and canal morphology of mandibular premolars, and dentists should be aware of the anatomy of this group of teeth to use appropriate treatment methods to achieve greater success in root canal treatment.

Materials and Methods

The study approval was obtained from the Golestan University of Medical Sciences Ethics Committee (IR.GOUMS.REC.1400.277).

Referring to the study by Razian *et al.* [17], with 95% confidence and 95.7 % frequency of mandibular single-rooted premolars, the number of 80 CBCT images was randomized selected.

This is a retrospective cross-sectional study which the CBCT images of two hundred twelve premolars (76 male, 136 female) of patients who were referred to a radiology department for other purposes (such as implant planning, prosthesis, surgery, orthodontic, or endodontic treatments) in Golestan Province from 2020 to 2021 were collected. The average age of the subjects was 42 Years (range: 16-68). The existing CBCT database was used, and no new scans were required for this study. In order to obtain more comprehensive information, it is proposed to carry out further studies with larger samples.

The images were used to determine the mandibular premolars' root number and canal configurations. Participant age at the time of the scans was recorded, but no information on race or ethnicity was collected. The inclusion criterion was the existence of at least one mandibular premolar with fully formed roots. Exclusion criteria included unclear or distorted CBCT images, previous endodontic treatment, presence of posts or crowns, periapical lesions, and physiological or pathological processes such as calcification and root resorption. CBCT images were performed using Planmeca ProMax 3d (Planmeca, Helsinki, Finland) operating at a voltage of 80 kV, a current of 6 mA, and an exposure time of 12 sec. The voxel size and slice thickness were 200 μ m, and the field of view was 8*11 cm. The CBCT scans were analyzed using romexis viewer software (Planmeca, Helsinki, Finland). All teeth were analyzed in sagittal, axial, and coronal planes to determine the number of roots, root canal configuration, and several root canals in each root based on Vertucci's classification (Figure 2). All images were assessed individually by two evaluators (an endodontist and general dentist) the kappa value for the inter-observer agreement was 0.976. Data were analyzed using SPSS software version 16 (SPSS Inc, Chicago, IL, USA). The Chi-square test was used to study the frequency of various morphologies between different sex and root morphology groups. The significance level was set at $P < 0.05$.

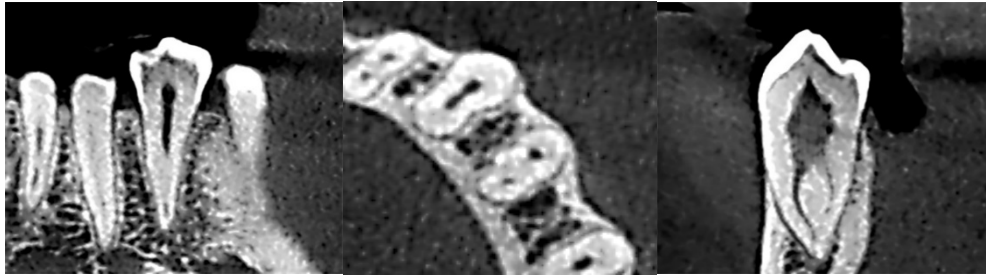


Figure 2. A) The coronal plane of CBCT of mandibular first premolar; B) The axial plane of CBCT image; C) The sagittal plane of CBCT image

Results

Root configurations

The numbers of roots of the maxillary first and second premolars according to sex in this study are described in Table 1.

Mandibular first premolars

Most mandibular first premolars studied had one root (78.5%). The remainder had two (20.8%) or three roots (0.8%). Most males in this study (77.8%) demonstrated one root, with the remainder displaying two (22.2%) roots. In comparison, the majority (78.8%) of all females had one root, while the remaining females had either two (20%) or three roots (1.2%). No statistical differences were found regarding sex and root number for mandibular first premolars ($P>0.05$).

Mandibular second premolars

The vast majority of mandibular second premolars had a single root (97.6%), and the remainder displayed either two (2.4%). The majority of males (93.5%) and all females (100%) displayed a single-root configuration. The remaining males had two (6.5%) roots; no instances of three-rooted configurations were found. No statistical differences were found regarding sex and root number for mandibular second premolars ($P>0.05$).

Canal configurations

The frequency and percentage of the number of canals and canal configurations in mandibular premolars are summarized in Table 2 and Table 3.

Of the mandibular first premolars, 66.9% had one canal, 31.5% displayed two canals, and the remainder had three (1.5%).

The most common canal configuration in the mandibular first premolars was type I (66.2%). Type V (16.9%) and IV (11.5%) were also frequently seen, while types III (3.1%), VIII (1.5%) and II (0.8%) were less commonly identified. The majority of males in this study (62.2%) demonstrated type I, followed by type V (20%) and type IV (13.3%). In comparison, the majority (68.2%) of all females had type I, while the remaining females had type V (15.3%) and type IV (10.6%). No statistical differences were found regarding sex and canal configuration for mandibular first premolars ($P>0.05$).

Mandibular second premolars

Of the mandibular second premolars, 92.7% had one canal, 7.3% had two canals.

The most prevalent configuration found in the mandibular second premolars was type I (92.7%), followed by type V (2%) and type II (2%). The majority of males in this study (87.1%) demonstrated type I, followed by type V (6.5%) and type III (6.5%). In comparison, the majority (96.1%) of all females had type I, while the remaining females had type V (2%) and type II (2%). No statistical differences were found regarding sex and canal configuration for mandibular second premolars ($P>0.05$).

Discussion

In this study, we investigated the root anatomy and root canal morphologies of mandibular premolar teeth among the population of Golestan Province using CBCT. A detailed understanding of tooth morphology and root canal variations is considered important for the clinical success of endodontic procedures [1, 7]. Therefore, the current study chose to analyze the mandibular premolars to explore their diversity among the population of Golestan Province. For this purpose, we analyzed CBCT imaging data from Two hundred and twelve premolars.

The current study showed that mandibular premolars among the Golestan Province population presented with various Vertucci types of canal configurations, similar to other reported studies in different populations. We revealed a higher frequency of 1-rooted mandibular first premolars (78.5%), followed by 2 roots in 20.8% and 3 in 0.8% of teeth. The 1-canal configuration was the most prevalent observation (66.9%), whereas two canals were observed in 31.5%, and 3 canals were seen in 1.5% of teeth.

A lower frequency of single-canal mandibular first premolars, as compared with the results of the present study, has been previously reported in Chinese, Saudi, and Brazil populations [1, 14, 19].

Previous studies have demonstrated that most mandibular second premolars have a single root. The reported prevalence ranged from 78% to 98.8% [14, 17, 19, 29]. The findings of the present study are in agreement with these investigations.

Variations in the root morphology of mandibular second premolars may be attributed to different sample sizes, populations, geographical areas, or methods of evaluation [30].

In this study, high anatomical variation was observed in mandibular first premolars. These variations can reduce the prognosis of endodontic treatment. When abnormal findings are evident in traditional periapical films or variations are detected with magnification in the clinical setting, it may be impossible to evaluate the RCS effectively [19, 20]. In some situations, it is advisable to use CBCT for further diagnosis before or during clinical endodontic treatment [27].

In line with our study, Algarni *et al.* Showed that females had a significantly lower number of two canal premolars than males [20].

Like Rajakeerthi *et al.* [14] the most common Vertucci type in mandibular premolars was type I, followed by type V, and the rarest type was type VII, which was not observed in this study.

In the present study, the highest frequency of canal configuration in mandibular first premolars was type I (66.2%) and then type V (16.9%). In the second premolars, 92.7% were type I; the rest were type V, III, and II, respectively.

Type V was likewise the second most frequently encountered configuration in mandibular first and second

premolars, consistent with earlier research in the Egyptian population [31].

However, in the study conducted by Shemesh *et al.* In the Israeli population [29] and the study conducted by Hosseinpour in the Iranian population [10], type I and type III were the most frequent in both sexes. Racial differences can be the reason for this statistical difference [29].

In this study, the probability of multiple roots and canals of mandibular premolars is higher in males than in females, and the probability of a single canal and single root in the first and second premolars was higher in females. Generally, male and female genders do not show significant differences in the number of the canal and their types. As in the study conducted by Wu *et al.* In the Chinese population [1] and the study conducted by Alfawaz in the Saudi population [19], no significant relationship was observed between gender with the number of roots, the number of canals, and the shape of canals.

The canal systems of mandibular first premolars in a Golestan Province subpopulation showed a lot of variation and complexity. Mandibular second premolars had less variation in root and canal configuration than mandibular first premolars, which agrees with a previous study of a Saudi population [32].

Table 1. Prevalence of roots (% of teeth) according to gender

	One root (%)	Two roots (%)	Three roots (%)	Total
First premolars				
Male	35 (77.8)	10 (22.2)	0 (0.0)	45 (100)
Female	67 (78.8)	17 (20)	1 (1.2)	85 (100)
Total	102 (78.5)	27 (20.8)	1 (0.8)	130(100)
Second premolars				
Male	29(93.5)	2(6.5)	0(0.0)	31 (100)
Female	51(100)	0(0.0)	0(0.0)	51 (100)
Total	80(97.6)	2(2.4)	0(0.0)	82 (100)

Table 2. Prevalence of canals (% of teeth) according to gender

	One canal (%)	Two canals (%)	Three canals (%)	Total
First premolars				
Male	28 (62.2)	17(37.8)	0(0.0)	45 (100)
Female	59 (69.4)	24(28.2)	2(2.4)	85 (100)
Total	87 (66.9)	41(31.5)	2(1.5)	130 (100)
Second premolars				
Male	27 (87.1)	4 (12.9)	0 (0.0)	31 (100)
Female	49 (96.1)	2 (3.9)	0 (0.0)	51 (100)
Total	76 (92.7)	6 (7.3)	0 (0.0)	82 (100)

Table 3. Prevalence of root canal types according to gender

	gender	Type I (%)	Type II (%)	Type III (%)	Type IV (%)	Type V (%)	Type VIII (%)	Total (%)
First premolars	Male	28 (62.2)	0 (0.0)	2 (4.4)	6 (13.3)	9 (2.0)	0 (0.0)	45 (100)
	Female	58 (68.2)	1 (1.2)	2 (2.4)	9 (10.6)	13 (15.3)	2 (2.4)	85 (100)
	Total	86 (66.2)	1 (0.8)	4 (3.1)	15 (11.5)	22 (16.9)	2 (1.5)	13 (100)
Second premolars	Male	27 (87.1)	0 (0.0)	2 (6.5)	0 (0.0)	2 (6.5)	0 (0.0)	31 (100)
	Female	49 (96.1)	1 (2.0)	0 (0.0)	0 (0.0)	1 (2.0)	0 (0.0)	51 (100)
	Total	76 (92.7)	1 (1.2)	2 (2.4)	0 (0.0)	3 (3.7)	0 (0.0)	82 (100)

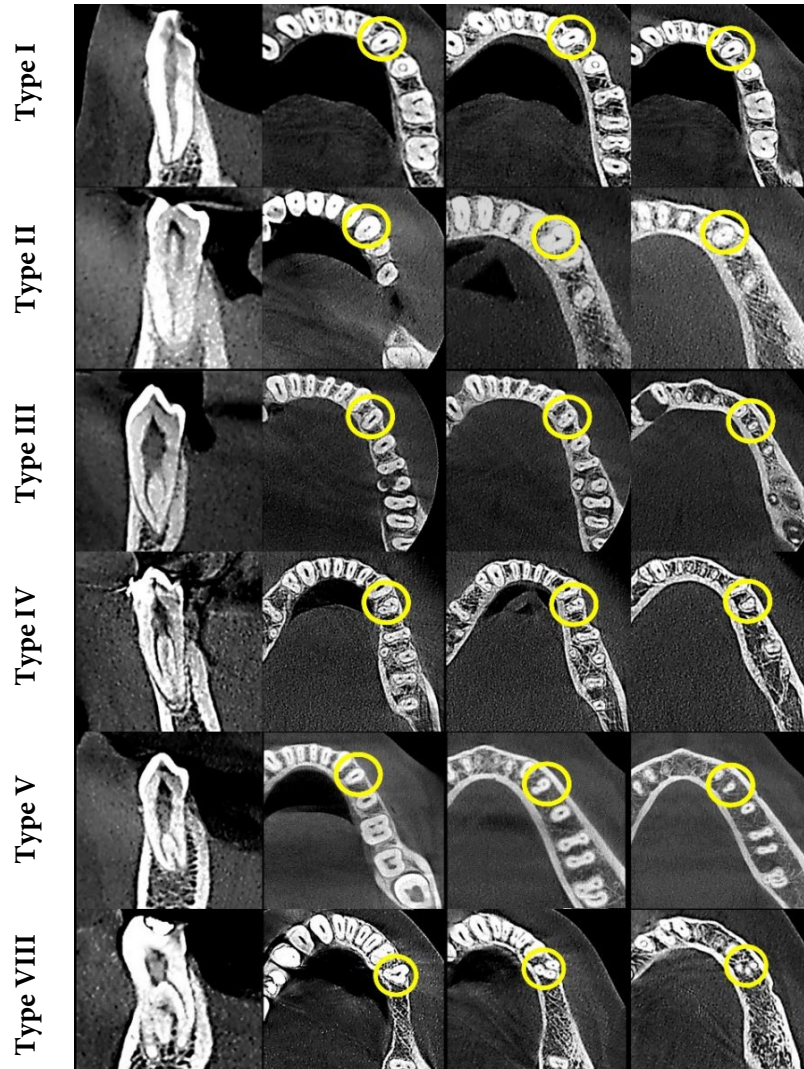


Figure 3. Several common canal configurations are demonstrated using coronal and axial sections of CBCT scans.

Conclusion

This study can guide the root canals of mandibular premolar teeth for the Iranian subpopulation, leading to more optimal diagnosis and treatment planning for Endodontists. According to the findings, the complexity of the root canal system and the number of roots were less observed in females than in males.

Acknowledgements

This article was extracted from the thesis prepared by Maryam Sajed to fulfill the requirements required for earning the Doctor of dental surgery degree. The authors acknowledge the Department of Endodontics, Dental faculty, Golestan University of Medical Sciences.

Conflict of interest

None.

Funding support

None.

Author contributions

Conception and design: Mallahi M, Sajed M; Analysis and interpretation: Alvandifar SH, Sajed M; Data collection: Mallahi M, Alvandifar SH; Writing the article: Sajed M, Alvandifar SH; Critical revision of the article: Sajed M, Mallahi M; Final Approval of the article: Alvandifar SH, Mallahi M Sajed M; Statistical analysis: Sajed M, Alvandifar SH.

References

1. Wu D, Hu D, Xin B, Sun D-g, Ge Z-p, Su JY. Root canal morphology of maxillary and mandibular first premolars analyzed using cone-beam computed tomography in a Shandong Chinese population. *Medicine*. 2020;99.

2. Kumakami-Sakano M, Otsu K, Fujiwara N, Harada H. Regulatory mechanisms of Hertwig's epithelial root sheath formation and anomaly correlated with root length. *Experimental Cell Research*. 2014;325.
3. Newman MG, Takei HH, Klokkevold PR, Carranza FA. Newman and Carranza's clinical periodontology. Thirteenth edition. ed. Philadelphia, PA: Elsevier; 2019.
4. Mahdavisefat E, Kazemi A, Moghtaderi Esfahani E. Endodontic Management of Three-rooted Mandibular First Premolar Using Cone-beam Computed Tomography: A Case Report. *Iran Endod J*. 2023;18(2):122-5.
5. Khorasani M, Nabavi S, Hamed A, Jafarzadeh H. Endodontic Treatment of C-shaped Mandibular Premolars: A Case Report and Review of Literature. *Iran Endod J*. 2021;16(4):244-53.
6. Niavarzi S, Ghabraei S, Malekpour F. Mandibular Second Premolar with Four Canals: A Case Report. *Iran Endod J*. 2022;17(4):209-11.
7. Buchanan GD, Gamielidien MY, Tredoux S, Vally ZI. Root and canal configurations of maxillary premolars in a South African subpopulation using cone beam computed tomography and two classification systems. *J Oral Sci*. 2020;62(1):93-7.
8. Asheghi B, Momtahan N, Sahebi S, Zangooei Booshehri M. Morphological Evaluation of Maxillary Premolar Canals in Iranian Population: A Cone-Beam Computed Tomography Study. *J Dent*. 2020;21(3):215-24.
9. Asgary S, Shadman B, Ghalamkarpour Z, Shahravan A, Ghoddusi J, Bagherpour A, Akbarzadeh Baghban A, Hashemipour M, Ghasemian Pour M. Periapical Status and Quality of Root canal Fillings and Coronal Restorations in Iranian Population. *Iran Endod J*. 2010;5(2):74-82.
10. Hosseinpour S, Kharazifard MJ, Khayat A, Naseri M. Root Canal Morphology of Permanent Mandibular Premolars in Iranian Population: A Systematic Review. *Iran Endod J*. 2016;11(3):150-6.
11. Asgary S. Endodontic therapy in a three canal mandibular second premolar. *Iran Endod J*. 2006;1(1):43-4.
12. Kfir A, Mostinsky O, Elyzur O, Hertzzeanu M, Metzger Z, Pawar AM. Root canal configuration and root wall thickness of first maxillary premolars in an Israeli population. A Cone-beam computed tomography study. *Sci Rep*. 2020;10(1):434.
13. de Lima CO, de Souza LC, Devito KL, do Prado M, Campos CN. Evaluation of root canal morphology of maxillary premolars: a cone-beam computed tomography study. *Aust Endod J*. 2019;45(2):196-201.
14. Rajakeerthi R, Malli Suresh Babu N. Use of Cone Beam Computed Tomography to Identify the Morphology of Maxillary and Mandibular Premolars in Chennai Population. *Braz Dent Sci*. 2019;22:Process.
15. Fournier G, Maret D, Duchesne S, Telmon N, Diemer F, Savall F. Root and canal morphology of the permanent teeth in medieval and current French population. *Arch Oral Biol*. 2022;140:105452.
16. Khorasani M, Nabavi S, Hamed A, Jafarzadeh H. Endodontic Treatment of C-shaped Mandibular Premolars: A Case Report and Review of Literature. *Iran Endod J*. 2021;16(4):244-53.
17. Razian F, Azizi H, Shakeri F, Haghani S, Hoshyari N. Evaluation of Root Canal Morphology of Mandibular Premolars Using Cone Beam Computed Tomography in Northern Cities in Iran During 2018. *J Mashhad Dent Sch*. 2019;43(3):279-86.
18. Georgiev K, Pecheva A. Deviant morphology of the root canal system in mandibular premolars: clinical cases. *Folia medica*. 2022;64(1):176-80.
19. Alfawaz H, Alqedairi A, Al-Dahman YH, Al-Jebaly AS, Alnassar FA, Alsabait S, Allahem Z. Evaluation of root canal morphology of mandibular premolars in a Saudi population using cone beam computed tomography: A retrospective study. *Saudi Dent J*. 2019;31(1):137-42.
20. Algarni YA, Almufarrij MJ, Almohafii IA, Alhayaza HH, Alghamdi N, Baba SM. Morphological variations of mandibular first premolar on cone-beam computed tomography in a Saudi Arabian sub-population. *Saudi Dent J*. 2021;33(3):150-5.
21. Dinakar C, Shetty UA, Salian VV, Shetty P. Root Canal Morphology of Maxillary First Premolars Using the Clearing Technique in a South Indian Population: An In vitro Study. *Int J Appl Basic Med Res*. 2018;8(3):143-7.
22. Khattak M, Ijaz F, Ahmad N, Arbab S, Khattak I, Khattak Y. Root canal configuration of maxillary first premolar teeth in a subpopulation of Peshawar using tooth cross-sectioning method; An invitro study. *J Ayub Med Coll Abbottabad*. 2022;34(3 Suppl 1):623-7.
23. Srbinoska D, Trpevska V, Cadikovska E. Utilization of cephalometric 2d and 3d analysis during diagnosis, treatment plan and case monitoring of impacted teeth-case report. *J Morphol Sci*. 2022(2):183-90%V 5.
24. Bishi H, Smith JBV, Asopa V, Field RE, Wang C, Sochart DH. Comparison of the accuracy of 2D and 3D templating methods for planning primary total hip replacement: a systematic review and meta-analysis. *EFORT Open Reviews*. 2022;7(1):70-83.
25. Naik V, Prakash S, Chuan N, N, Ying O. Frequency of Recommending Cone Beam Computed Tomography in Comparison to Panoramic Radiograph, While Diagnosing a Pathology/Status of Vital Structures Around Mandibular Impacted Third Molar. *J Indian Acad Oral Med Radiol*. 2022;34(3):314-9.
26. Mohan R, Singh A, Gundappa M. Three-dimensional imaging in periodontal diagnosis-Utilization of cone beam computed tomography. *J Indian Soc Periodontol*. 2011;15(1):11-7.
27. Patel S, Brown J, Pimentel T, Kelly RD, Abella F, Durack C. Cone beam computed tomography in Endodontics - a review of the literature. *Int Endod J*. 2019;52(8):1138-52.
28. Chogle S, Zwaiter M, Sarkis R, Saadoun M, Mecham A, Zhao Y. The Recommendation of Cone-beam Computed Tomography and Its Effect on Endodontic Diagnosis and Treatment Planning. *J Endod*. 2020;46(2):162-8.
29. Shemesh A, Lalum E, Ben Itzhak J, Levy DH, Lvovsky A, Levinson O, Solomonov M. Radicular Grooves and Complex Root Morphologies of Mandibular Premolars Among Israeli Population. *J Endod*. 2020;46(9):1241-7.
30. de LIMA CO. Analysis of the root canal morphology of mandibular premolars using cone-beam computed tomography.
31. gawdat s, Abd El Samad A, Sadek H. Cone-Beam Computed Tomographic analysis of Root and Root Canal Morphology of Mandibular Premolars in Egyptian Population. *Egypti Dent J*. 2022;68(3):2813-23.
32. Al-Zubaidi SM, Almansour MI, Alshammari AS, Al Mansour NN, Alshammari AF, Altamimi YS, Madfa AA. Root and Canal Morphology of Mandibular Premolars in a Saudi Subpopulation: A Cone-Beam Computed Tomography Study. *Int J Dent*. 2022;2022:4038909.

Please cite this paper as: Sajed M, Salvandifar SH, Mallahi M. Evaluation of Root Canal Morphology of Mandibular Premolar using Cone Beam Computed Tomography in Golestan Province, North of Iran. *Iran Endod J*. 2024;19(3): 183-8. *Doi:* 10.22037/iej.v19i3.40052.