



Mandibular Second Premolar with Four Canals: A Case Report

Soheil Niavarzi ^a , Sholeh Ghabraei ^a , Fatemeh Malekpour ^{a*}

^a Department of Endodontics, School of Dentistry, Tehran University of Medical Sciences, Tehran, Iran

Article Type: Case Report

Received: 05 Aug 2022

Revised: 02 Sep 2022

Accepted: 18 Sep 2022

Doi: 10.22037/iej.v17i4.38604

*Corresponding author: Fatemeh Malekpour,
Department of Endodontics, School of Dentistry,
Tehran University of Medical Sciences, Tehran, Iran.

Email: malekpour_fatemeh@yahoo.com

The mandibular second premolar can be considered one of the most challenging teeth to treat endodontically; due to the complexity of its root canal morphology and increased incidence of multiple canals. The knowledge of internal anatomy of root canals and their possible variations as well as use of magnification, e.g. operating microscope, radiographic examination and illumination, can increase the chances of finding additional canals and contribute to the success of endodontic treatment. The purpose of the current investigation is to report the successful endodontic treatment of a mandibular second premolar with 4 canals; all of them in one single root.

Keywords: Anatomy; Endodontics; Dental Pulp Cavity, Premolar; Root Canals

Introduction

Since variations in root canal morphology are quite common, an understanding of tooth anatomy and root canal morphology is essential to achieve successful root canal therapy. Root canal treatment may not succeed if the root canal system is not completely identified, which is beneficial for long-term success [1, 2]. Additionally, the anatomies of the root canal system in mandibular premolars have been studied and several anatomical variations have been discovered [3]. The prevalence of anatomical variations in the mandibular second premolars is not the same as that in the first premolars. One of the aforementioned variations is the addition of another one or two canals [4, 5].

Mandibular second premolars typically have one root canal with a reported prevalence of 98.8%. However, it is quite common for the mandibular premolars II to have two canals; with an occurrence range of 1.2% to 29% [6]. Amongst those with three canals, the prevalence varies from 0.4% to 0.5%, and four/five canals have been reported only in case reports [7-9]. Sert and Bayirli's [10] study of Turkish patients found an incidence of two or more canals in 43% of men and 15% of women; with significant differences in gender. The Turkish people, as an ethnic group, demonstrated a higher incidence of multiple canals than the averages of the remaining investigated anatomical studies. Due to

the prevalence of anatomical variations, use of dental loupes, headlights, surgical operating microscopes (SOMs), ultrasonic methods and cone-beam computed tomography (CBCT) helps in the clinical detection of canals [11-13]. The radiographic characteristic of an examined tooth root with multiple canals on a periapical radiograph is a clearly visible coronal canal which seems to abruptly fade out in the apical region, beyond the division of the canal system [1].

The current case report presents the nonsurgical endodontic management of a mandibular right second premolar with four root canals referred by a general dentist.

Case Report

A 50-year-old white male patient was referred for root canal treatment on his mandibular right second premolar by his general dentist. The patient's medical history was noncontributory. The general dentist had begun treating the root canal(s) because the pulp of the tooth had been diagnosed necrotic. However, the general dentist could not complete the process due to the complexity of the root canal system, the patient did not mention any symptoms.

In the clinical examination, the tooth was not sensitive to percussion and there was no tenderness or swelling in the buccal sulcus. Graduated periodontal probing revealed a normal probing



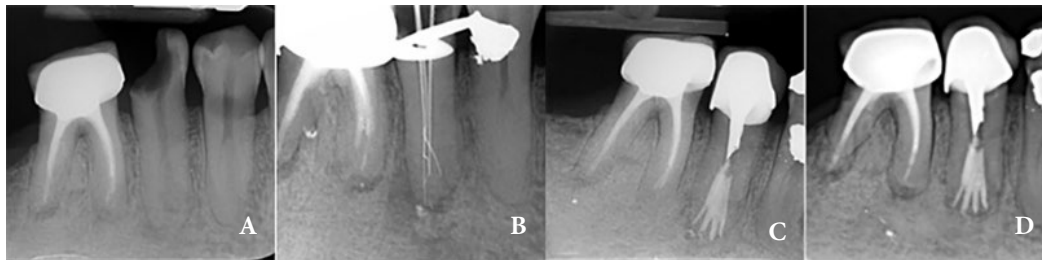


Figure 1. A) Pretreatment periapical radiograph of mandibular right second premolar; B) Working length determination radiograph; working length determination was done by #10 K file; C) Postoperative radiograph shows four canals in the apical third region; D) follow-up radiograph after two years

depth. Evaluation of the periapical radiograph and fading of the canal from the middle of the root revealed the possibility of the presence of extra canals. CBCT was recommended to evaluate the root canal system; however, the patient preferred to complete the treatment without CBCT evaluation (Figure 1A).

Because of the complexity of the root canal system, two sessions were scheduled for root canal treatment. In the first appointment, the tooth was anesthetized with 1.8 mL of 2% lidocaine with 1:100,000 epinephrine (Darupakhsh, Tehran, Iran) using an infra-alveolar nerve block, and then, isolated with a rubber dam. Since the canal branched from one canal to four canals in the apical third region, which could be regarded as one of the complications of treating this tooth, finding canals was easier using a microscope (OPMI Pico Dental Microscope; Zeiss, Oberkochen, Germany). The root lengths were estimated and confirmed using an apex locator (Root ZX; Morita, Tokyo, Japan) and a radiograph (Figure 1B).

Instrumentation was performed using #10 K-file up to #25 K-file (Mani, Tochigi, Japan), with the master apical file an ISO size #25 in all canals. Then, all canals were cleaned and shaped with nickel-titanium rotary instruments (ProTaper Universal; Dentsply, Maillefer, Ballaigues, Switzerland). S1, S2, F1 and F2 rotary files were used respectively accompanied by excessive irrigation with 5.25% Sodium hypochlorite (NaOCl) and then, calcium hydroxide (Ultradent, South Jordan, Utah, USA) was placed in the canals. After a week, canals were rinsed with 5.25% NaOCl and final irrigation was performed for 1 min with 17% Ethylenediaminetetraacetic acid (EDTA) (Coltene-Whaledent, Allstetten, Switzerland) to remove the smear layer. Subsequently, canals were dried using paper points and filled with gutta-percha (Diadent, Chongchong Buk Do, Korea) and AH-Plus sealer (Dentsply DeTrey, Konstanz, Germany) using lateral compaction technique. The access cavity was then temporarily restored with IRM (GC, Tokyo, Japan). Post-operative instructions were provided and the patient was referred to his general dentist for permanent restoration (Figure 1C). At the two year follow-up the treated tooth was functional and asymptomatic; radiographic evaluation showed normal periradicular tissues (Figure 1D).

Discussion

The root canal must be identified, cleaned, and shaped correctly before obturation. Nonetheless, there are several reasons for the failure of endodontic treatment; including an untreated canal, inadequate debridement and incomplete obturation [14]. An untreated root canal may occur because the dentist does not or cannot recognize its presence [15]. To locate and treat the root canal system, clinicians must have all required equipment/instruments at their disposal [16, 17]. Some tools are available to enable the operator to precisely explore and properly treat the radicular canals, e.g. pre-operative radiographs and the endodontic microscope; since magnification and illumination make treatment more accurate and easier [4, 18]. In the presented case, it was difficult to negotiate and instrument the canals due to their locations. In addition, narrowing or obliterating the main canal was a technical challenge. If the canal is moderately curved or severely curved, the difficulty would be added [19-22].

The canals were negotiated using the watch winding motion with #10 K-files, and the apical part of canals was prepared with small files up to #25 to prevent transportation [23]. Copious irrigation with 5.25% NaOCl was used and apical patency with K-file #10 was considered to eliminate the microbial contamination of canals and dentin chips but not to lose working length. The treatment consisted of two sessions due to the complexity of treatment as well as the need to apply intracanal calcium hydroxide dressing for the disinfection and removal of residual organic debris [24]. After irrigation with EDTA solution, lateral compaction obturation with highly-radiopaque material, such as AH-Plus sealer, can sometimes allow sealer to flow into the narrowed but unprepared parts of canal(s). Lack of knowledge of root and canal morphology reduces long-term treatment success. Moreover, Glassman *et al.* reported flare-ups in mandibular premolars with associated paresthesia of the inferior alveolar and mental nerves due to missed root canals [25]. No challenge with previously published articles can be seen.

In the current case, finding the additional canals required careful tactile examination of the buccal wall with appropriate file #10. In addition to the location of these canals, special attention was given to the subsequent biomechanical preparation and the following obturation of canals to achieve a substantive hermetic seal. With good illumination and a dry pulp floor, it is easiest to locate canal orifices. It is typically considered beneficial to magnify with a microscope; however, the dental operating microscope is generally better for detecting orifices [25, 26].

Conclusions

This case report presents the successful endodontic treatment of a mandibular second premolar with Four Canals. It is essential to always consider variations in pulp anatomy and morphology before the beginning of root canal treatment. Utilizing magnification tools, e.g. a microscope, to magnify the internal anatomy of a root canal increases the probability of finding additional canals. Furthermore, radiographic examination is imperative when endodontic treatment is to be successful. If canals are identified and negotiated correctly, complex premolars' anatomy can be treated predictably.

Conflict of Interest: 'None declared'.

References

1. Rotstein I, Ingle JI. *Ingle's endodontics* 7. United States of America 2019. 1-5 pp.
2. Vertucci FJ, Haddix JE. Tooth morphology and access cavity preparation. *Cohen's Pathways of the Pulp*: Elsevier; 2011. pp. 136-222.
3. Borna Z, Rahimi S, Shahi S, Zand V. Mandibular second premolars with three root canals: a review and 3 case reports. *Iran Endod J*. 2011;6(4):179.
4. Al-Shawwa SS, Al-Khairallah Y, Alenazy MS, Al-Dayel O. Endodontic management of mandibular second premolar with Type IX canal configuration using cone-beam computed tomography. *Saudi Endod J*. 2019;9(2):144.
5. Mueller AH. Anatomy of the root canals of the incisors, cuspids and bicuspid of the permanent teeth. *J Am Dent Assoc*. 1933;20(8):1361-86.
6. Yang L, Han J, Wang Q, Wang Z, Yu X, Du Y. Variations of root and canal morphology of mandibular second molars in Chinese individuals: a cone-beam computed tomography study. *BMC oral health*. 2022;22(1):1-12.
7. Awawdeh L, Al-Qudah A. Root form and canal morphology of mandibular premolars in a Jordanian population. *Int Endod J*. 2008;41(3):240-8.
8. Zhang M, Xie J, Wang Y-h, Feng Y. Mandibular first premolar with five root canals: a case report. *BMC oral health*. 2020;20(1):1-5.
9. Molyvdas I, Digka A, Mikrogeorgis G. Root canal treatment of mandibular second premolars with three root canals: report of four rare cases. *Balkan J Dent Med*. 2020;24(1):49-52.
10. Sert S, Bayirli GS. Evaluation of the root canal configurations of the mandibular and maxillary permanent teeth by gender in the Turkish population. *J Endod*. 2004;30(6):391-8.
11. Saati S, Shokri A, Foroozandeh M, Poorolajal J, Mosleh N. Root morphology and number of canals in mandibular central and lateral incisors using cone beam computed tomography. *Braz Dent J*. 2018;29:239-44.
12. Popović M, Papić M, Acović A, Živanović S, Kanjevac T. Cone-beam computed tomography study of root number and root canal configuration of premolars in Serbian population. *Medicinski preglad*. 2018;71(3-4):100-7.
13. Mokhtari H, Niknami M, Zand V. Managing a mandibular second premolar with three-canal and taurodontism: a case report. *Iran Endod J*. 2013;8(1):25.
14. Jain R, Mala K, Shetty N, Bhimani N, Kamath PM. Endodontic management of mandibular anterior teeth and premolars with Vertucci's Type VIII canal morphology: a rare case. *J Conserv Dent*. 2022;25(2):197-201.
15. Prayogo K, Wahjuningrum DA, Subiyanto A. Endodontic retreatment in case of failure: case report. *Conserv Dent J*. 2019;9(2):109-11.
16. Iandolo A, Abdellatif D, Pantaleo G, Sammartino P, Amato A. Conservative shaping combined with three-dimensional cleaning can be a powerful tool: case series. *J Conserv Dent*. 2020;23(6):648.
17. Hosseinpour S, Kharazifard MJ, Khayat A, Naseri M. Root Canal Morphology of Permanent Mandibular Premolars in Iranian Population: A Systematic Review. *Iran Endod J*. 2016;11(3):150-6.
18. Al Shehadat S, Jain P. Digitalization in endodontics. *Digitization in Dentistry*: Springer; 2021. pp. 89-139.
19. Salem S, Agila N, Alkeshher S. Shaping ability of three Ni-Ti rotary systems in curved root canals of extracted teeth. *Khalij-Libya J Dent Med Res*. 2022;6-10.
20. Asgary S. Endodontic therapy in a three canal mandibular second premolar. *Iran Endod J*. 2006;1(1):43-4.
21. Kakkar P, Singh A. Mandibular first premolar with three roots: a case report. *Iran Endod J*. 2012;7(4):207-10.
22. Mohammadi Z, Asgary S, Shalavi S, P VA. A Clinical Update on the Different Methods to Decrease the Occurrence of Missed Root Canals. *Iran Endod J*. 2016;11(3):208-13.
23. Panchal V, Jeevanandan G, Subramanian E. Comparison of instrumentation time and obturation quality between hand K-file, H-files, and rotary Kedo-S in root canal treatment of primary teeth: a randomized controlled trial. *J Indian Soc Pedod Prev Dent*. 2019;37(1):75.
24. Nouroloyouni A, Lotfi M, Milani AS, Nouroloyouni S. Endodontic management of a two-rooted mandibular first premolar with five root canals with cone-beam computed tomography: a case report. *J Dent*. 2021;22(3):225.
25. Hepşenoğlu YE, Erşahan Ş. Endodontic treatment of a mandibular premolar with Vertucci type V root canal morphology: a rare case report. *Case Rep Dent*. 2018.
26. Kim H-S, Jung D, Lee H, Han Y-S, Oh S, Sim H-Y. C-shaped root canals of mandibular second molars in a Korean population: a CBCT analysis. *Restor Dent Endod*. 2018;43(4).

Please cite this paper as: Niavarzi S, Ghabraei SH, Malekpour F. Mandibular Second Premolar with Four Canals: A Case Report. *Iran Endod J*. 2022;17(4): 209-11. *Doi: 10.22037/iej.v17i4.38604*.