

Kazem Ashofteh Yazdi¹ DDS, MS, Mohammad Sabeti² DDS, MA, Pooriya Motahhary³ DDS, MS, Alireza Kolahdouzan⁴ DDS, MS, Mohsen Shayesteh⁵ DDS, MS, Noushin Shokouhinejad^{1,6}✉ DDS, MS

Subcutaneous Tissue Responses to Three Endodontic Irrigants: A Comparative Study

1. Dental Research Center, Department of Endodontics, Dental School, Tehran University of Medical Sciences, Tehran, Iran

2. Department of Endodontics, Dental School, University of Southern California, Los Angeles, California, USA

3. Department of Oral Pathology, Dental School/Dental Research Center, Tehran University of Medical Sciences, Tehran, Iran

4. Department of Endodontics, Dental School, Ghazvin University of Medical Sciences, Ghazvin, Iran

5. Dentist, Tehran, Iran

6. Iranian Center for Endodontic Research, Shahid Beheshti University of Medical Sciences, Tehran, Iran

Introduction: This study aimed to compare the subcutaneous tissue responses to MTAD (mixture of a tetracycline isomer, an acid, and a detergent), 17% EDTA, and 2.6% NaOCl.

Materials and Methods: Thirty-six Wistar albino rats were used for this study. Test solutions were injected subcutaneously into predetermined areas on the animal dorsum. The rats were then randomly divided into three groups of twelve each and sacrificed at 2 hours, 2 days, and 2 weeks. The severity of inflammation induced by each irrigant at different time intervals was assessed histologically. The data were analyzed using Kruskal-Wallis and Friedman tests.

Results: The difference in severity of inflammatory reactions induced by tested irrigants at the different time intervals was statically significant ($P < 0.05$). There was no significant difference between the severity of inflammation induced by MTAD and 2.6% NaOCl at the various time intervals ($P > 0.05$). Subcutaneous tissue responses to MTAD were not different from those observed in 17% EDTA specimens at 2-hour and 2-day intervals ($P > 0.05$).

Conclusion: Under the conditions of this study, MTAD has the same toxicity as 2.6% NaOCl.

Keywords: EDTA; Inflammation; MTAD; Sodium hypochlorite; Subcutaneous Tissue; Toxicity

Received: 06 Apr 2012; **Revised:** 01 Jun 2012; **Accepted:** 14 Jun 2012

✉ Noushin Shokouhinejad, Department of Endodontics, Dental School, Tehran University of Medical Sciences, North Karegar St., Tehran, Iran.
Tel: +98 912 3375410, Fax: +98 21 88015800, Email: Shokouhinejad@yahoo.com

Introduction

Removal of bacteria from the root canal system is necessary for successful root canal therapy. Effective endodontic treatment and consequent healing depends on thorough chemomechanical cleaning and shaping of the root canal system [1]. An ideal root canal irrigant should dissolve vital and necrotic tissues in the canal, flush out debris, have antimicrobial effects, and remove the smear layer [2]. Various types of irrigating solutions are available for endodontic use, such as sodium hypochlorite (NaOCl), chlorhexidine (CHX), ethylenediaminetetraacetic acid (EDTA), iodine potassium iodide (IKI), and MTAD (Dentsply

Tulsa Dental, Tulsa, OK) [1,3-5]. NaOCl is able to dissolve pulpal tissues [6] and act as an antimicrobial agent against most microorganisms and their biofilms [7-9]. However, aside from NaOCl unpleasant taste, NaOCl is toxic [10] and does not remove the smear layer [11].

EDTA, however, does remove the mineralized portion of the smear layer [12]. For effective removal of both organic and inorganic components of the smear layer, combined application of NaOCl and a chelating agent, such as EDTA, is recommended [13,14].

MTAD, introduced by Torabinejad in 2003, is an aqueous solution of 3% doxycycline, a broad-spectrum antibiotic; 4.25% citric acid, a demineralizing agent; and 0.5% polysorbate 80

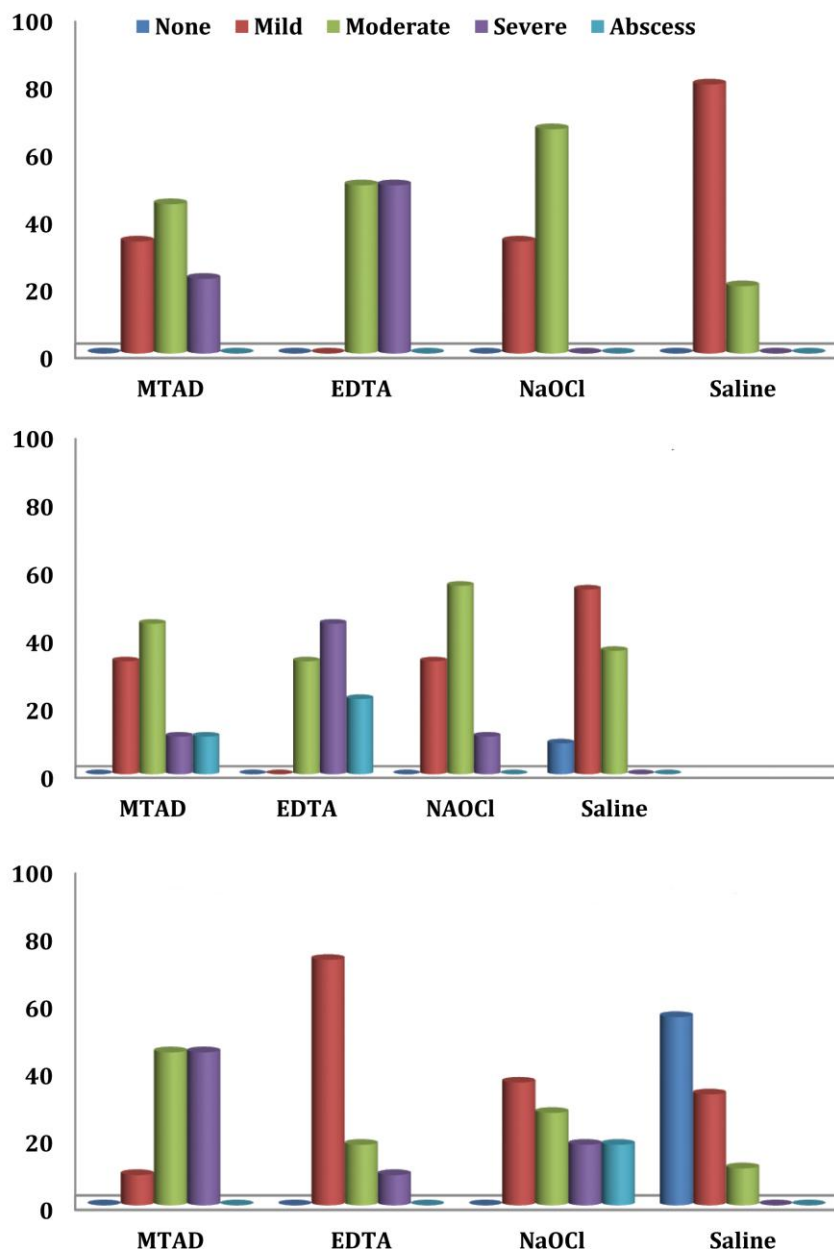


Figure 1. Severity of inflammatory reactions to test irrigants after: *A*) 2 hours; *B*) 2 days; *C*) 2 weeks

detergent (Tween 80) [15]. MTAD final rinse was shown to effectively remove the smear layer with minimal erosive changes to the surface dentin compared with EDTA [3]. Furthermore, MTAD can eliminate *Enterococcus faecalis* [16-18].

Endodontic irrigants can come in contact with periradicular tissues. Use of toxic irrigants can not only cause complications and tissue damage during root-canal treatment but may also interfere with the repair process [2,19]. Therefore, when choosing irrigants during root-canal treatment low toxicity, high

biocompatibility and high efficacy of the irrigants should be considered [19].

Researchers have evaluated the biocompatibility of MTAD and have found that it was less cytotoxic and more biocompatible than other irrigating solutions [20-23]. MTAD has been reported to exhibit a lower cytotoxicity against L929 cells compared to 5.25% NaOCl, EDTA, and Ca(OH)₂ paste [20]. In a study by Ring et al. [21], the cytotoxicity of NaOCl/MTAD was reported to be slightly less than NaOCl/EDTA and NaOCl, indicating that MTAD

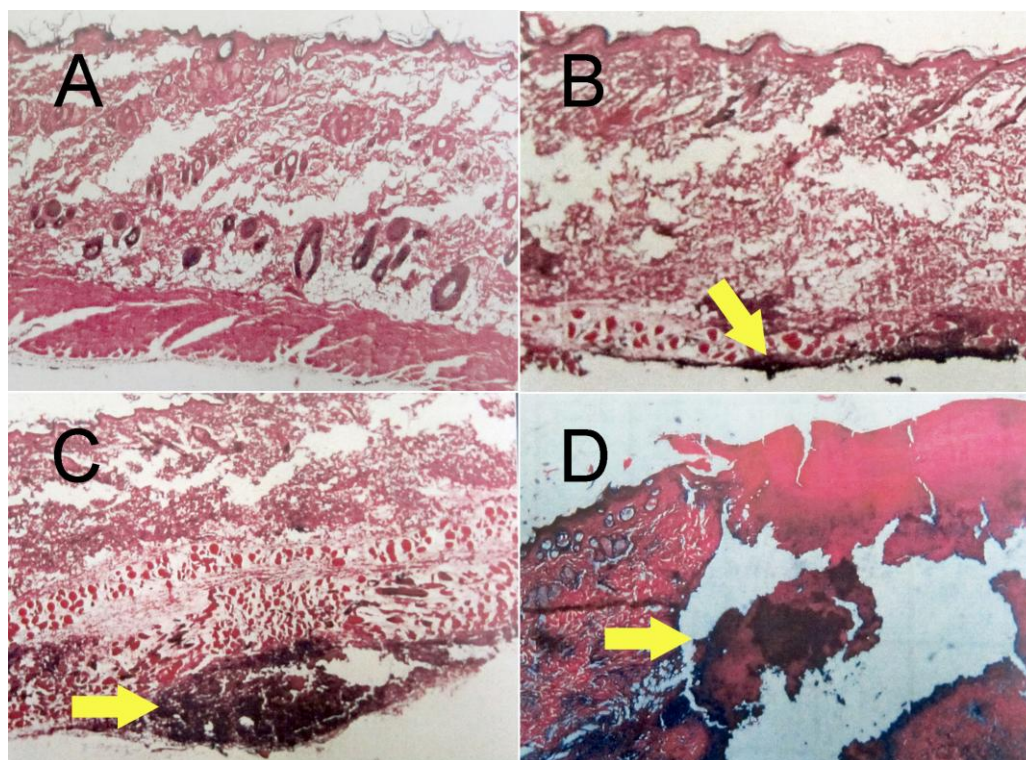


Figure 2. Subcutaneous tissue responses to irrigants: **A)** No inflammatory cells infiltration; **B)** Moderate inflammatory cells infiltration with tissue changes but without necrosis; **C)** Severe infiltration of inflammatory cells; **D)** Abscess formation

was more biocompatible than NaOCl. The present study aimed to compare the subcutaneous tissue responses to three commonly used endodontic irrigants including MTAD, 17% EDTA, and 2.6% NaOCl.

Materials and Methods

The research protocol was approved by the research ethics committee of Tehran University. Thirty-six Wistar albino rats weighing 180-220 g were used for this study. Animals were anesthetized with an intramuscular injection of Ketamine hydrochloride 25 to 44 mg/kg and acetylpromazine 0.75 mg/kg. The back of the rats were shaved and disinfected with 70% ethanol. Four circles with 1.5-2 cm distance from each other were drawn on the dermis of the rat by an indelible marker, two on each side of vertebral column.

A total of 0.1 mL of Biopure MTAD (Dentsply Tulsa Dental, Tulsa, OK), 17% EDTA Solution, 2.6% NaOCl, and 0.9% normal saline as control, were injected subcutaneously into the center of each circle in the back of each rat by an insulin syringe. The rats were then randomly divided into three groups of twelve and sacrificed

at 2 hours, 2 days, and 2 weeks. Samples of dermis, epidermis and parts of the surrounding muscles were removed and fixed in 10% buffered formalin solution for 2 weeks. 5- μ m tissue sections were prepared and stained with haematoxylin and eosin and then evaluated under a light microscope (BX-SI, Olympus, Japan) with different magnifications. A pathologist who was unaware of test groups evaluated the specimens.

According to ISO 7405:1997 standard, the tissue and inflammatory reactions were graded as follows [24]:

1. **None:** No inflammatory cells infiltration
2. **Mild:** Scattered chronic inflammatory cells without tissue changes
3. **Moderate:** Focal inflammatory cell infiltration with tissue changes but without necrosis
4. **Severe:** Severe infiltration of inflammatory cells
5. **Abscess:** Abscess formation

The severity of inflammatory reactions induced by irrigants was analyzed using Kruskal-Wallis test. Friedman test was used for analysis of inflammatory reactions of each irrigant at different time intervals. Statistical analysis was performed with SPSS 11.5 for Windows.

Results

The severity of inflammatory reactions induced by test solutions at different time intervals is shown in Figure 1A-C. The photographs of some subcutaneous tissue responses to test irrigants are presented in Figure 2A-D. The difference in tissue responses to the irrigants at different time intervals was statically significant ($P<0.05$).

At 2-hour interval, no significant difference was found between the inflammatory reactions induced by MTAD and those induced by 2.6% NaOCl and 17% EDTA ($P>0.05$). The difference in inflammatory reactions between 17% EDTA and 2.6% NaOCl ($P=0.006$) and 17% EDTA and normal saline ($P<0.001$) was statistically significant.

There was no significant difference in the degree of inflammatory reactions induced by tested irrigants at 2-day interval ($P=0.061$).

The results showed significant difference in the severity of inflammation between four irrigants at 2-week interval ($P<0.000$). There was a significant difference in the degree of inflammation between MTAD and 17% EDTA ($P=0.005$), and MTAD and normal saline ($P<0.001$); however, the difference between MTAD and 2.6% NaOCl was not significant ($P=0.562$). NaOCl also showed significant difference when compared to normal saline ($P<0.001$); however 17% EDTA did not ($P=0.031$).

The results showed no significant differences between the severity of inflammatory reactions induced by MTAD and 2.6% NaOCl at 2-hour, 2-day, and 2-week intervals ($P>0.05$). The difference between inflammatory reactions of MTAD and 17% EDTA was significant only at 2-week interval ($P=0.005$).

Discussion

In the present study, subcutaneous tissue responses to tested endodontic irrigants were evaluated using rats as an *in vivo* animal model. Yesilsoy *et al.* used guinea pigs as an *in vivo* model to examine subcutaneous local tissue reactions to some irrigants [25].

The findings of this study revealed that the severity of inflammation and subcutaneous tissue responses to MTAD and 2.6% NaOCl was not significantly different at any of the time intervals.

On the contrary, Zhang *et al.* showed that the cytotoxicity of MTAD on L929 fibroblasts was more than that of 2.63% NaOCl after 24 hours [20]. They also demonstrated that MTAD was less cytotoxic than EDTA [20]. However, in the present study, the severity of inflammatory reactions induced by MTAD was not different from that induced by EDTA except at the 2-week interval. The findings of the present study also contradict Yasuda *et al.* who found MTAD to be less cytotoxic on MC3T3-E1 and periodontal ligament cells compared with 5.25% NaOCl and 17% EDTA at 24 hours [23]. These controversial results might be partly attributed to the difference in test subjects which were fibroblast cells in the study by Zhang *et al.* [20], MC3T3-E1 and periodontal ligament cells in the study by Yasuda *et al.* [23] and rats' subcutaneous tissue in the present study.

In contrast to this investigation, Yesilsoy *et al.* in a study on subcutaneous tissue reactions found that 0.5% and 2.5% NaOCl exhibited no inflammation at 2 hours; however, tested solutions induced mild inflammation after 2 days [25].

The variation between the findings of different studies could be attributed to the concentration of tested solutions. It has been shown a correlation between the cytotoxicity of NaOCl and its concentration [20]. Furthermore, the time intervals and design of investigations might affect the results of various studies.

Conclusion

Under the conditions of this animal study, MTAD was as cytotoxic as 2.6% NaOCl. The subcutaneous tissue reaction to MTAD was similar to EDTA after 2 hours and 2 days.

Acknowledgments

This study was supported by a grant from Tehran University of Medical Sciences and Health Services (grant no. 3716).

Conflict of Interest: 'none declared'.

References

- [1] Siqueira JF, Jr., Rocas IN, Santos SR, Lima KC, Magalhaes FA, de Uzeda M. Efficacy of instrumentation techniques and irrigation

- regimens in reducing the bacterial population within root canals. *J Endod.* 2002;28(3):181-4.
- [2] Hauman CH, Love RM. Biocompatibility of dental materials used in contemporary endodontic therapy: a review. Part 1. Intracanal drugs and substances. *Int Endod J.* 2003;36(2):75-85.
 - [3] Torabinejad M, Khademi AA, Babagoli J, Cho Y, Johnson WB, Bozhilov K, Kim J, et al. A new solution for the removal of the smear layer. *J Endod.* 2003;29(3):170-5.
 - [4] Shabahang S, Pouresmail M, Torabinejad M. In vitro antimicrobial efficacy of MTAD and sodium hypochlorite. *J Endod.* 2003;29(7):450-2.
 - [5] Abbaszadegan P A, Khayat P A. Comparison of antimicrobial efficacy of IKI and NaOCl irrigants in infected root canals: An in vivo study. *Iranian Endodontic J.* 2010;5(3):101-6.
 - [6] Khademi A, Ehsan Usefian D, Mahboobe Feizianfard D. Tissue dissolving ability of several endodontic irrigants on bovine pulp tissue. *Iranian Endodontic J.* 2007;2(2):65-8.
 - [7] Bryce G, O'Donnell D, Ready D, Ng YL, Pratten J, Gulabivala K. Contemporary root canal irrigants are able to disrupt and eradicate single- and dual-species biofilms. *J Endod.* 2009;35(9):1243-8.
 - [8] Prabhakar J, Senthilkumar M, Priya MS, Mahalakshmi K, Sehgal PK, Sukumaran VG. Evaluation of antimicrobial efficacy of herbal alternatives (Triphala and green tea polyphenols), MTAD, and 5% sodium hypochlorite against *Enterococcus faecalis* biofilm formed on tooth substrate: an in vitro study. *J Endod.* 2010;36(1):83-6.
 - [9] Nosrat A, Bolhari B, Sharifian MR, Aligholi M, Mortazavi MS. The effect of Carvacrol on *Enterococcus faecalis* as a final irrigant. *Iranian Endodontic J.* 2009;4(3):96-100.
 - [10] Spangberg L, Engstrom B, Langeland K. Biologic effects of dental materials. 3. Toxicity and antimicrobial effect of endodontic antiseptics in vitro. *Oral Surg Oral Med Oral Pathol.* 1973;36(6):856-71.
 - [11] Goldman LB, Goldman M, Kronman JH, Lin PS. The efficacy of several irrigating solutions for endodontics: a scanning electron microscopic study. *Oral Surg Oral Med Oral Pathol.* 1981;52(2):197-204.
 - [12] Goldberg F, Abramovich A. Analysis of the effect of EDTAC on the dentinal walls of the root canal. *J Endod.* 1977;3(3):101-5.
 - [13] Baumgartner JC, Mader CL. A scanning electron microscopic evaluation of four root canal irrigation regimens. *J Endod.* 1987;13(4):147-57.
 - [14] Khedmat S, Shadi A. A scanning electron microscopic comparison of the cleaning efficacy of endodontic irrigants. *Iranian Endodontic J.* 2008;2(3):95-100.
 - [15] Singla MG, Garg A, Gupta S. MTAD in endodontics: an update review. *Oral Surg Oral Med Oral Pathol Oral Radiol Endod.* 2011;112(3):e70-6.
 - [16] Krause TA, Liewehr FR, Hahn CL. The antimicrobial effect of MTAD, sodium hypochlorite, doxycycline, and citric acid on *Enterococcus faecalis*. *J Endod.* 2007;33 (1):28-30.
 - [17] Davis JM, Maki J, Bahcall JK. An in vitro comparison of the antimicrobial effects of various endodontic medicaments on *Enterococcus faecalis*. *J Endod.* 2007;33 (5):567-9.
 - [18] Ahangari Z, Mohammad Samiee D, Yolmeh MA. Antimicrobial activity of three root canal irrigants on *Enterococcus Faecalis*: An in vitro study. *Iranian Endodontic J.* 2008;3(2):33-7.
 - [19] Masillamoni CR, Kettering JD, Torabinejad M. The biocompatibility of some root canal medicaments and irrigants. *Int Endod J.* 1981;14(2):115-20.
 - [20] Zhang W, Torabinejad M, Li Y. Evaluation of cytotoxicity of MTAD using the MTT-tetrazolium method. *J Endod.* 2003;29 (10):654-7.
 - [21] Ring KC, Murray PE, Namerow KN, Kuttler S, Garcia-Godoy F. The comparison of the effect of endodontic irrigation on cell adherence to root canal dentin. *J Endod.* 2008;34(12):1474-9.
 - [22] Pappen FG, Souza EM, Giardino L, Carlos IZ, Leonardo MR, de Toledo Leonardo R. Endodontic chelators induce nitric oxide expression by murine-cultured macrophages. *J Endod.* 2009;35(6):824-8.
 - [23] Yasuda Y, Tatematsu Y, Fujii S, Maeda H, Akamine A, Torabinejad M, Saito T. Effect of MTAD on the differentiation of osteoblast-like cells. *J Endod.* 2010;36(2):260-3.
 - [24] ISO 7405. Dentistry- Preclinical evaluation of biocompatibility of medical devices used in dentistry. Test methods for dental materials; 1997. British Standard ISO 6876.
 - [25] Yesilsoy C, Whitaker E, Cleveland D, Phillips E, Trope M. Antimicrobial and toxic effects of established and potential root canal irrigants. *J Endod.* 1995;21(10):513-5.