



Multiple Microsurgery Intervention with Apicoectomy Guidance in Single Session: A Case Report

Warley Luciano Fonseca Tavares^{a*} , Vinícius de Carvalho Machado^a , Francielen Oliveira Fonseca^a ,
Lucas Moreira Maia^a , Nelson Renato França Alves Silva^a , Antônio Paulino Ribeiro Sobrinho^a 

^a Department of Restorative Dentistry, Faculty of Dentistry, Federal University of Minas Gerais, Belo Horizonte, MG, Brazil

ARTICLE INFO

Article Type: Case Report

Received: 07 May 2021

Revised: 24 May 2021

Accepted: 10 Jun 2021

Doi: 10.22037/iej.v16i3.30842

*Corresponding author: Warley Luciano Fonseca Tavares, Av. Antônio Carlos 6627, Campus Pampulha, Belo Horizonte, MG, 31270-901, Brazil.

Tel: +55 31 3409-2843

E-mail: warleyt@hotmail.com

ABSTRACT

The aim of this manuscript is to describe and discuss the advantages and obstacles of using a guided implant system adapted for endodontic microsurgery in the execution of a case with indication of multiple endodontic microsurgery intervention in a single appointment. Cone-beam computed tomography (CBCT) scans were aligned and processed with the planning software, complementing the Straumann® guided instruments. The drill handles of the system employed directed milling cutters and guided drills based on the sleeve-in-sleeve concept used in the osteotomy and apical resection of teeth #13, #14, #23 and #24. The root-ends were retro-prepared and sealed with putty bioceramic sealer. The patient was completely asymptomatic at the 12 months follow up visit and CBCT revealed complete tissue healing of the involved teeth. The protocol demonstrated to be reliable and reproducible. Its applicability can be extended to other anatomical complex scenarios. The reproducibility of the technique would encourage the maintenance of teeth in patients with indication to multiple endodontic surgery and permitted the conclusion of this case with precision and comfort to both patient and operator.

Keywords: Apicoectomy; Endodontically-treated Teeth; Periapical Periodontitis

Introduction

The digital workflow has gained traction in endodontics in the last few years. The development of specific computed software matched to cone-beam computed tomographic (CBCT) and three-dimensional (3D) scanning allowed the raise of 3D planning and endodontic guidance [1-3].

The use of prefabricated 3D printed templates has been linked to the treatment outcome improvement of root calcification in endodontics and retreatment cases [4-6]. The 3D printed templates technology also brought the possibility to perform conservative access of complex cases of *dens invaginatus* [7] and to remove fiber posts with more predictable results [8]. In implantology, this technology permitted the reduction of surgical intervention time and postoperative complications during treatment [9, 10].

The success rate of endodontic surgery and postoperative complications such as pain and swelling are intimately associated

with the extension of bone defect caused by the resorption process or osteotomy [11]. In cases of multiple apical surgeries or when the buccal plate is intact, the exact localization of the root apex is more difficult, which may influence the clinician to enlarge the size of osteotomy [12].

The application of 3D guidance was introduced in endodontic surgery to perform guided osteotomy, apex localization, and root-end resection [13]. Non-specific instruments as trephine burs have been reported in cases with anatomical complex scenarios [14] in an attempt to facilitate the surgical precision [15]. It is worth to note that we are facing the emerging need to develop and improve specific instruments and 3D templates directed to apicoectomy aiming at reaching the maximum precision as recommended by the guidelines of modern surgical endodontic treatment. Recently, the use of a guided implant system was recommended for the resolution of a case of endodontic microsurgery associated with complex anatomy [16].



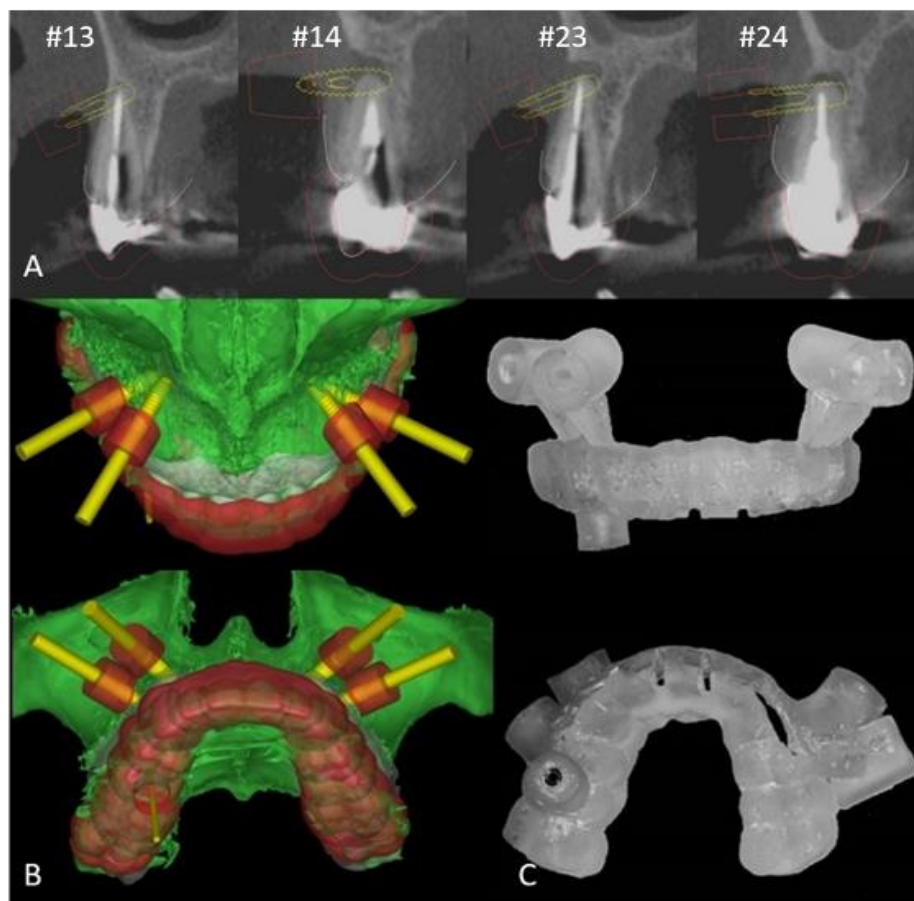


Figure 1. A, B) Digital planning of guided endodontic microsurgery of teeth #13, #14, #23, #24, and endodontic treatment of tooth #15; C) 3D printed guide

This manuscript aims to describe and discuss the advantages and obstacles of using a guided implant system adapted for endodontic microsurgery in the execution of a case with indication of multiple endodontic microsurgery intervention in a single appointment.

Case Report

A 64-year-old male patient was referred to a private clinic with a history of bilateral pain in the maxilla. Percussion and palpation tests revealed tenderness in the teeth #13, 14, 23, 24 and 15. The CBCT showed the presence of unsatisfactory endodontic treatment in teeth #13, 14, 23, 24, and apical radiolucency in the non-endodontically treated tooth #15 (Figures 1 and 3). A prosthetic rehabilitation was present, and the patient asked for its maintenance. After orientation and discussion of risks and benefits with the patient, apicoectomy was indicated for teeth #13, 14, 23 and 24, and guided surgery was chosen as the most appropriate treatment choice. The tooth #15 was indicated to go under root canal treatment, for which opening access was digitally

planned to demonstrate the reliability of the digital flow. The patient received and signed an informed consent form.

The whole maxillary arch was scanned (3 Shape Trios 3 Color Intra-oral Scanner; Holmes Kanal, Copenhagen, Denmark). A high-resolution CBCT image was taken using the following settings: 0.2-mm voxel, gray scale, 14 bits, 26.9-second x-ray exposure, 120 kV, and 37 mA (iCAT; Imaging Sciences International, Hatfield, PA, USA). After that, CBCT and teeth scans were aligned and processed with the planning software, complementing the Straumann® guided instruments (CoDiagnostiX™ by Dental Wings Inc. Basel, Switzerland) (Figure 1).

The drill handles of the system employed (Straumann® Guided Surgery, Straumann, Basel, Switzerland) direct milling cutters and guided drills based on the sleeve-in-sleeve concept. The cylinder of the drill handle is inserted into the sleeve (5 mm) fixed to the surgical template. For each instrument diameter, 2.2 mm, 2.8 mm, 3.5 mm and 4.2 mm, an ergonomic drill handle is available. Every drill handle featured one cylinder with an additional height of +1 mm at one end and a second cylinder

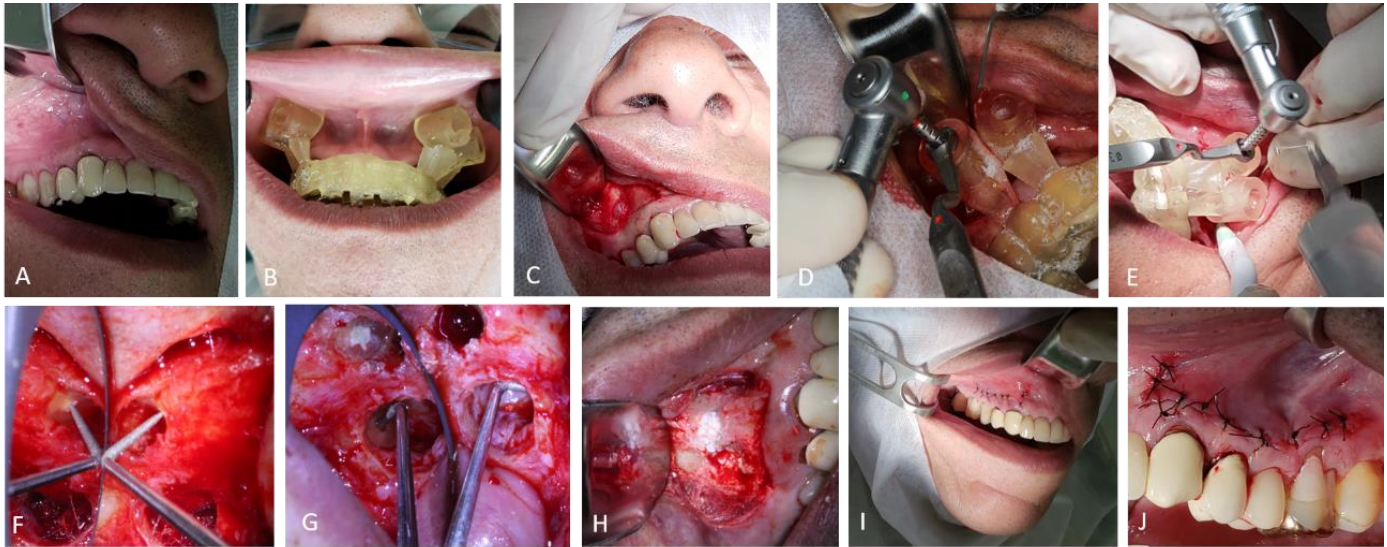


Figure 2. A) Pre-operative clinical aspect of the case; B) The 3D guide fit was checked in the mouth; C) Submarginal incision was performed and the flap was elevated; D, E) Guided osteotomy and apical resection were performed with the auxiliary of the 3D template. F, G) Retro-preparation was performed with an ultrasonic diamond tip followed by the retro-filling with putty bioceramic sealer; H) Bovine bone was utilized as bone graft; I, J) The clinical aspect after suture can be observed

with an extra cylinder height of +3 mm at the other end. In this case, a 3.5 mm diameter instrument was used associated with a +3 mm extra cylinder in the osteotomy and apical resection of teeth #13, 14, 23 and 24.

The position of the drill was checked to cut precisely the portion of the roots involving the apical periodontitis. The opening access of tooth #15 was digitally planned with a #1014 diamond round bur. A specific 3D guide was built for that purpose and exported as stereolithography (STL) files that were sent to a 3D printer (Formlabs2, Formlab Inc., Somerville, MA, USA).

The printed 3D template comprised the 4 teeth involved in apicoectomy and the opening access of tooth #15. It was positioned in the mouth and checked for the fit. In the first appointment, the endodontic treatment of tooth #15 was performed in a single session.

In a second appointment, the apical microsurgeries of teeth #13, 14, 23 and 24 were performed (Figure 2). The teeth #13 and #14 were anesthetized with 2% lidocaine with epinephrine (1:100,000) and incision was performed followed by a full-thickness flap reflection using a curette. After that the 3D template designed for the drilling was positioned for initial osteotomy. The first Milling Cutter, 3.5 mm diameter drill was inserted in the guide with the aid of the drill handle and the osteotomy was performed at 980 RPM under copious irrigation with saline. A second Twist Drill PRO 3.5 mm was used at the same speed and under irrigation until it reached the bed of the drill handle and ensured the apical resection as planned. A #6

spherical surgical carbide bur was used in the boundaries of the cryptal bone to enlarge its diameter from 3.5 mm to at least 4 mm and ensure the access for instrument manipulation. The apical lesions were removed with a curette and the surgery sites were cleaned with saline irrigation.

The localization of the root canals of the involved teeth were confirmed with the aid of a micromirror under the use of the operating microscope under 20× magnification. The root-ends were retro-prepared with an ultrasonic diamond tip at a 3 mm level under copious irrigation with saline. The prepared root-ends cavities were dried and sealed with putty bioceramic sealer (Bio-C Repair, Ângelus, Londrina, Brazil). An epinephrine-impregnated cotton pellet was left at the depth of the osteotomy to maintain hemostasis as well as to prevent particles of the root-end filling material from falling at the surgical site [16]. The bone crypts were cleaned and checked for the presence of any exceeded material and then filled with bone graft cement (4Matrix MIS, Augma Biomaterials, Israel). The flap was repositioned, and incision was closed with 5-0 monocryl (Figure 2). The same protocol described was performed for teeth #23 and #24 in the same appointment. A post-operative Rx exam revealed the absence of any foreign material and the correct position of the retro-filled material in the treated teeth. The patient was post medicated with ibuprofen (600 mg q8h) for 3 days.

The patient was completely asymptomatic at the 1 week and 1 month follow-up visits. A new CBCT was performed at 12 months after surgery and revealed complete tissue healing of the involved teeth (Figure 3).

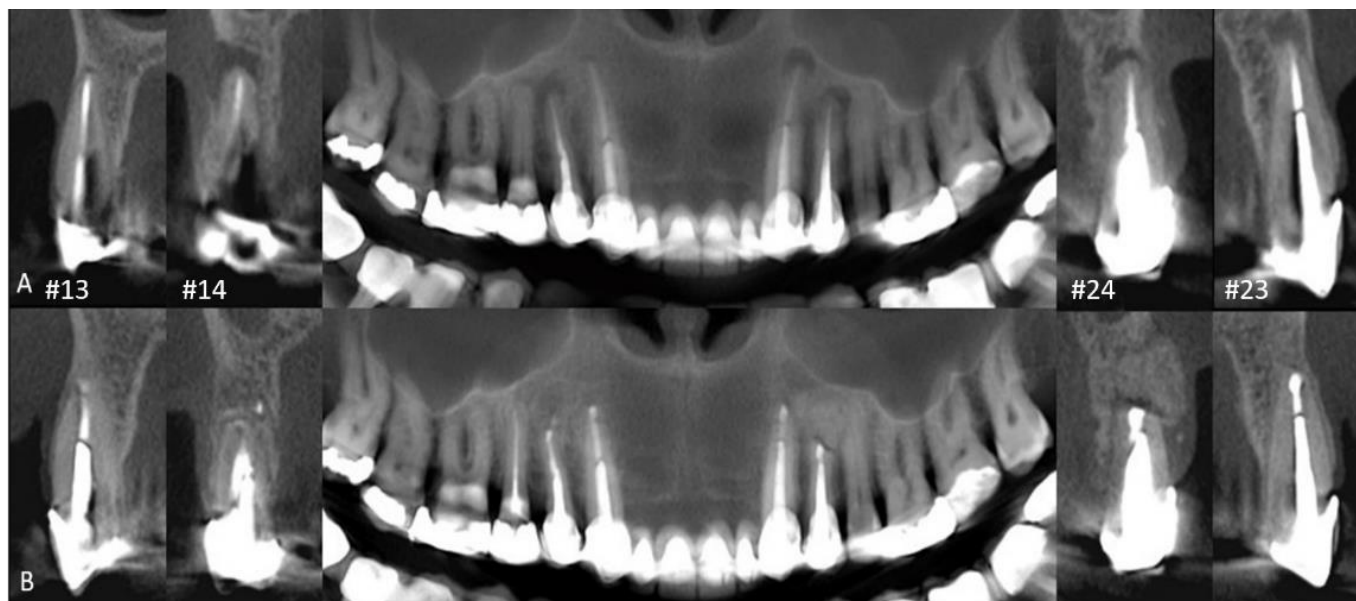


Figure 3. A) Pre-operative CBCT of teeth #13, #14, #23, #24 and #15 demonstrates the presence of apical periodontitis; B) In the twelve-month control CBCT it can be observed complete repair of the referred teeth

Discussion

A reproducible ultra-conservative 3D guided apicoectomy surgery concept was reported in this case. In this technique, guided implant drills commonly available worldwide were utilized to perform the osteotomy and apicoectomy, resulting in a precise removal of contaminated tissue. Hence, the reliability and simplicity of the technique can be easily reproduced by other professionals. The extra costs to the patients are related to CBCT and intraoral scanning associated to the 3D printing, which can be performed in a radiologic center.

The use of the 3D printed surgical template has significantly reduced the time spent in the microsurgeries in the case here presented. The entire steps of osteotomy and apical resection took less than 3 min for each tooth. The less time consuming protocol compared to conventional endodontic surgery permitted the conclusion of the case in the same appointment without patient and professionals' fatigue. This was reflected in an asymptomatic post-operative follow up.

Anatomic difficulties such as thick buccal bone plate in maxillary teeth and the proximity with maxillary sinus and adjacent root apices raise the difficulty of endodontic surgery [15, 16]. In the case presented, the performance of surgical intervention in four teeth in the same appointment increased the degree of difficulty of the procedure. Under this circumstance, less experienced dental professionals could mistakenly perform erroneous or exaggerated osteotomy if exerting the conventional free hand surgery and spend an excessive time during the

intervention. The presented technique permitted a very conservative osteotomy. The removal of tissue was limited to that strictly necessary to reach and resect the apical root and remove completely the granulation periapical tissue as previously demonstrated [16].

The diameter of the bony crypt after the use of the drill in this case was 3.5 mm which limited the access for instrument manipulation [17]. To contour this limitation, it was necessary to enlarge the crypt diameter with a spherical bur as a refinement of osteotomy to at least 4 mm. In this manner, the approach permitted the access to the micro-surgical site without the risk of unnecessary tissue removal and reduced the human limiting in identifying surgical boundaries.

In the case presented and in other cases of our archives, the drill used in the root resection with this protocol did not cause any damage in the apex structure of the teeth, which were maintained intact without microcracks. The drills utilized are available in different diameters, which permits that the instrument utilized in root resection can be chosen according to the diameter of the targeted tissue. The root apices were inspected with high magnification under the operative microscope in the beginning and at the end of the root-end preparation in the presented case. This step aims to remove the filling material, irritants, necrotic tissue, and remnants from the canals as well as the isthmus in case this is present and to create a cavity that can be properly filled [18]. In the case presented here, an ultrasonic diamond tip was utilized under copious irrigation in this step to avoid microcracks. The class I cavity was

dried and cleaned and inspected to avoid the presence of debris, tissue remnants or any filling material left on the axial walls. The quality of the retro-preparation is paramount to guarantee the achievement of a high success rate, and the dentin walls should be parallel to and within the anatomic outline of the root canal space [18, 19]. The use of the guided technique did not interfere in those steps, which could properly be performed and permitted the objectives of modern endodontic microsurgery to be achievable.

Conclusions

The protocol demonstrated in this study was reliable and reproducible. Its applicability can be extended to other anatomical complex scenarios. The reproducibility of the technique would encourage the maintenance of teeth in patients with indication to multiple endodontic microsurgery and permitted the conclusion of this case with precision and comfort to both patient and operator. However, development of more appropriate instruments and drills directed to the apicoectomy procedures are strongly advised.

Acknowledgments

The authors thank the postgraduate program at the School of Dentistry of Universidade Federal de Minas Gerais (UFMG) and Pró-Reitoria de Pesquisa da UFMG (PRPq). The authors deny any conflicts of interest related to this study.

Conflict of Interest: 'None declared'.

References

- Krastl G, Zehnder MS, Connert T, Weiger R, Kühl S. Guided Endodontics: a novel treatment approach for teeth with pulp canal calcification and apical pathology. *Dent Traumatol.* 2016;32(3):240-6.
- Zehnder MS, Connert T, Weiger R, Krastl G, Kühl S. Guided endodontics: accuracy of a novel method for guided access cavity preparation and root canal location. *Int Endod J.* 2016;49(10):966-72.
- Connert T, Zehnder MS, Amato M, Weiger R, Kühl S, Krastl G. Microguided Endodontics: a method to achieve minimally invasive access cavity preparation and root canal location in mandibular incisors using a novel computer-guided technique. *Int Endod J.* 2018;51(2):247-55.
- Tavares WLF, Lopes RCP, Henriques LCF, de Menezes GB, Paulino ribeiro sobrinHo A. Modern endodontic microsurgery treatment improves the outcome of challenging cases: A series report. *Dental Press Endod.* 2011;1(2):81-8.
- Tavares WLF, de Carvalho Machado V, Fonseca FO, Vasconcelos BC, Magalhães LC, Viana ACD, Henriques LCF. Guided Endodontics in Complex Scenarios of Calcified Molars. *Iran Endod J.* 15(1):50-6.
- Moreira ML, Toubes KM, Júnior GM, Tonelli SQ, Carvalho MVd, Silveira FF, Nunes E. Guided Endodontics in Nonsurgical Retreatment of a Mandibular First Molar: A New Approach and Case Report. 2020.
- Zubizarreta Macho Á, Ferreiroa A, Rico-Romano C, Alonso-Ezpeleta L, Mena-Álvarez J. Diagnosis and endodontic treatment of type II dens invaginatus by using cone-beam computed tomography and splint guides for cavity access: a case report. *J Am Dent Assoc.* 2015;146(4):266-70.
- Maia LM, Moreira Júnior G, Albuquerque RC, de Carvalho Machado V, da Silva N, Hauss DD, da Silveira RR. Three-dimensional endodontic guide for adhesive fiber post removal: A dental technique. *J Prosthet Dent.* 2019;121(3):387-90.
- Jung RE, Schneider D, Ganeles J, Wismeijer D, Zwahlen M, Hämmerle CH, Tahmaseb A. Computer technology applications in surgical implant dentistry: a systematic review. *Int J Oral Maxillofac Implants.* 2009;24 Suppl:92-109.
- D'Haese J, Van De Velde T, Komiyama A, Hultin M, De Bruyn H. Accuracy and complications using computer-designed stereolithographic surgical guides for oral rehabilitation by means of dental implants: a review of the literature. *Clin Implant Dent Relat Res.* 2012;14(3):321-35.
- Sisk AL, Hammer WB, Shelton DW, Joy ED, Jr. Complications following removal of impacted third molars: the role of the experience of the surgeon. *J Oral Maxillofac Surg.* 1986;44(11):855-9.
- Gutmann JL, Harrison JW. Posterior endodontic surgery: anatomical considerations and clinical techniques. *Int Endod J.* 1985;18(1):8-34.
- Strbac GD, Schnappauf A, Giannis K, Moritz A, Ulm C. Guided Modern Endodontic Surgery: A Novel Approach for Guided Osteotomy and Root Resection. *J Endod.* 2017;43(3):496-501.
- Giacomino CM, Ray JJ, Wealleans JA. Targeted Endodontic Microsurgery: A Novel Approach to Anatomically Challenging Scenarios Using 3-dimensional-printed Guides and Trephine Burs-A Report of 3 Cases. *J Endod.* 2018;44(4):671-7.
- Ahn SY, Kim NH, Kim S, Karabucak B, Kim E. Computer-aided Design/Computer-aided Manufacturing-guided Endodontic Surgery: Guided Osteotomy and Apex Localization in a Mandibular Molar with a Thick Buccal Bone Plate. *J Endod.* 2018;44(4):665-70.
- Tavares WLF, Fonseca FO, Maia LM, de Carvalho Machado V, França Alves Silva NR, Junior GM, Ribeiro Sobrinho AP. 3D Apicoectomy Guidance: Optimizing Access for Apicoectomies. *J Oral Maxillofac Surg.* 2020;78(3):357.e1-e8.
- Abedi HR, Van Mierlo BL, Wilder-Smith P, Torabinejad M. Effects of ultrasonic root-end cavity preparation on the root apex. *Oral Surg Oral Med Oral Pathol Oral Radiol Endod.* 1995;80(2):207-13.
- Floratos S, Kim S. Modern Endodontic Microsurgery Concepts: A Clinical Update. *Dent Clin North Am.* 2017;61(1):81-91.
- Fonseca Tavares WL, Diniz Viana AC, de Carvalho Machado V, Feitosa Henriques LC, Ribeiro Sobrinho AP. Guided Endodontic Access of Calcified Anterior Teeth. *J Endod.* 2018;44(7):1195-9.

Please cite this paper as: Tavares WLF, de Carvalho Machado V, Fonseca FO, Maia LM, Alves Silva NRF, Sobrinho APR. Multiple Microsurgery Intervention with Apicoectomy Guidance in Single Session: A Case Report. *Iran Endod J.* 2021;16(3): 193-7. *Doi:* 10.22037/iej.v16i3.30842.