



Root and Canal Morphology of Maxillary Teeth in an Iranian Subpopulation Residing in Western Iran Using Cone-Beam Computed Tomography

Nafiseh Nikkardar ^a , Mohammad Asnaashari ^b , Atena Karimi ^{c*} , Solmaz Araghi ^d ,
Shahin Seifitabar ^e , Amin Golshah ^f

^a Department of Oral and Maxillofacial Radiology, Kermanshah University of Medical Sciences, Kermanshah, Iran; ^b Laser Application in Medical Sciences Research Center, Shahid Beheshti University of Medical Sciences, Tehran, Iran; ^c Department of Oral and Maxillofacial Radiology, Kermanshah University of Medical Sciences, Kermanshah, Iran; ^d Department of Endodontics, Dental Branch, Islamic Azad University, Tehran, Iran; ^e Research Committee, Kermanshah University of Medical Sciences, Kermanshah, Iran; ^f Department of Orthodontic, Kermanshah University of Medical Sciences, Kermanshah, Iran

ARTICLE INFO

Article Type: Original Article

Received: 06 Aug 2019

Revised: 23 Nov 2019

Accepted: 16 Dec 2019

Doi: 10.22037/iej.v15i1.25386

*Corresponding author: Atena Karimi, Department of Oral and Maxillofacial Radiology, Kermanshah University of Medical Sciences, Kermanshah, Iran.

Tel: +98 912 779 4870

E-mail: atenakarimi83@yahoo.com

This work is licensed under the terms of the Creative Commons Attribution-NonCommercial-ShareAlike 4.0 International.

ABSTRACT

Introduction: Accurate information regarding the morphology of roots and canals is a prerequisite for successful endodontic treatment. This study aimed to assess the number of roots and canals and canal type of maxillary teeth according to the Vertucci's classification in an Iranian subpopulation residing in Western Iran using cone-beam computed tomography (CBCT). **Methods and Materials:** In this cross-sectional study, a total of 1750 teeth were evaluated on CBCT scans taken for purposes other than this study. For each tooth, 250 axial, sagittal and coronal sections with 1 mm slice thickness were evaluated using NNT Viewer software. The number of roots and canals and canal type according to the Vertucci's classification were determined and reported. Data were analyzed using descriptive and analytical statistics *via* Fisher's exact test and Chi square test. All data analyses were performed using SPSS version 18. **Results:** All of the maxillary anterior teeth were single-rooted, and Vertucci's type I was the most common canal type. Maxillary premolars were mostly single-rooted and Vertucci's type I was the most common type except for the first maxillary premolars, in which type V had the highest frequency. Maxillary molars mostly had three roots and two canals in the mesiobuccal root and one canal in the distobuccal and palatal roots. **Conclusion:** Although the number of roots in this cross-sectional study was similar to the findings of previous studies, canal type was significantly different from the results of previous studies. The result of this study can help clinicians in efficient root canal treatment of teeth.

Keywords: Cone-Beam Computed Tomography; Maxilla; Root Canal Morphology

Introduction

In root canal therapy, proper treatment planning, endodontic procedures and their outcome are directly influenced by the complexities of the root canal system and its internal morphology [1, 2]. Thus, dental clinicians should be well aware of the anatomical variations of teeth according to race, gender and genetics. For instance, Rouhani *et al.* [3] showed that the maxillary second molars had three roots in 96.6% of the cases

while this rate was 82.7% in the study by Kim *et al.* [4]. The prevalence of single-rooted second molars was 4.63% in the study by Kim *et al.* [4] while Rouhani *et al.* [3] did not find any case of single-rooted second molars. The prevalence of double-rooted second molars was 0.8% in the study by Rouhani *et al.* [3] and 10.72% in the study by Kim *et al.* [4] which highlight the variability in tooth anatomy among different populations and the need for in-depth studies on this topic in different geographical locations.

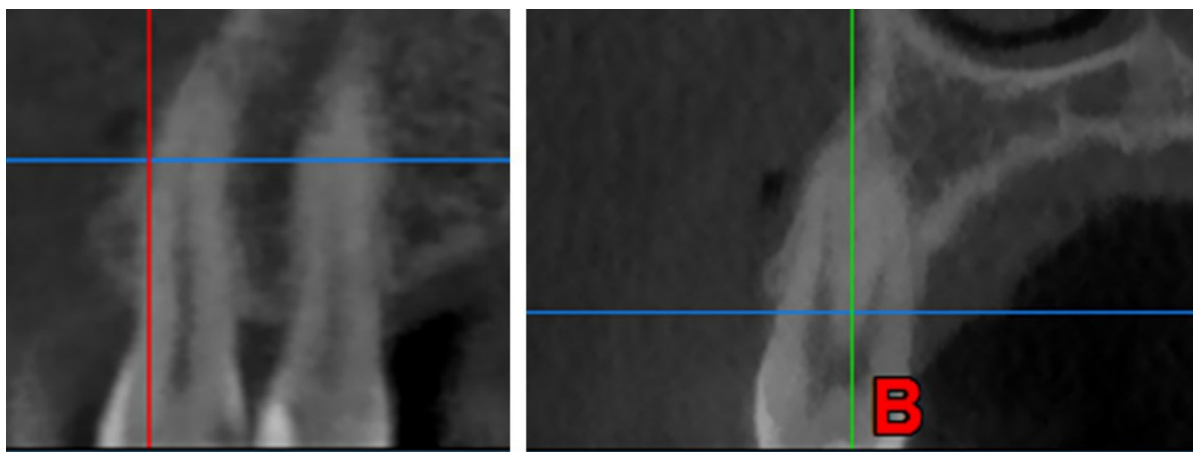


Figure 1. Determination of canal type: A) on coronal views; B) on sagittal views

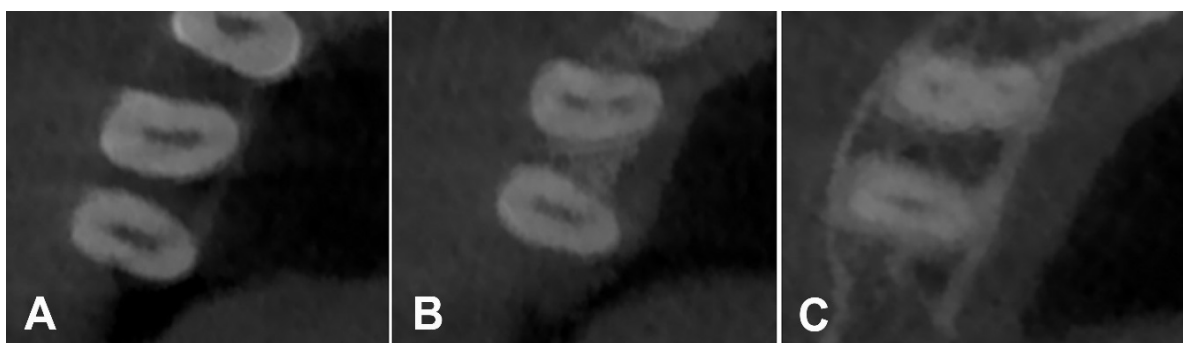


Figure 2. Determination of canal type on axial views: A) maxillary premolar at the orifice (one canal can be seen); B) the same tooth at the mid-root (main canal is divided into two branches); C) the same tooth at the apex (two canals can be seen)

Several techniques are available for assessment of morphological characteristics of the root canal system including canal staining and clearing technique [5], serial sectioning [6], radiographic examination [7], dentin assessment under magnification [8], use of clinical operating microscope [9], scanning electron microscopy [10], ultrasound [11], micro-computed tomography [12] and cone-beam computed tomography (CBCT) [2]. Of the above-mentioned techniques, those requiring tooth extraction and sectioning are not suitable due to their invasiveness. Radiography is an efficient tool in endodontic treatment. It is extensively used for endodontic diagnosis, during the procedure and for the follow-up assessments [13]. But, data obtained from the conventional two-dimensional radiographic modalities such as periapical radiography have limitations since these modalities provide two-dimensional images of three-dimensional structures. These limitations include superimposition in the buccolingual plane and image distortion. Computed tomography (CT) and particularly CBCT are three-dimensional radiographic

modalities suitable for assessment of the maxillofacial complex in the axial, sagittal and coronal planes [14, 15]. CT has high patient radiation dose, high cost, low resolution and limited availability; also, interpretation of CT findings is complicated [16]. CBCT is an extra-oral radiographic modality that provides three-dimensional images of the maxillofacial complex with much lower patient radiation dose than CT [17]. Also, different sizes of field of view can be used in CBCT. The field of view in CBCT can be large to include the entire maxillofacial skeleton or small to include only a small portion of the mandible or maxilla or even two or three teeth [17].

Considering the morphological variations in the roots and canals according to gender, race and genetics and gap of information regarding tooth morphology of the Iranians residing in Western part of Iran, this study aimed to assess the number of roots and canals and root canal type of maxillary teeth in an Iranian subpopulation residing in the Western part of Iran using CBCT. No similar study was performed in Iranian population with this sample size and includes different types of teeth.

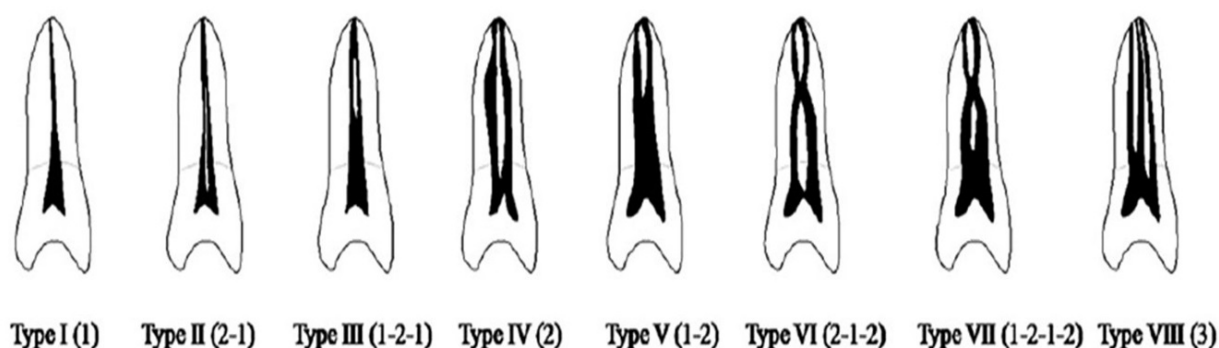


Figure 3. The Vertucci's classification to determine the root canal morphology and canal type

Materials and Methods

In this cross-sectional study, a total of 1750 teeth ($n=250$ for maxillary central incisors, lateral incisors, canines, first premolars, second premolars, first molars and second molars) were evaluated on CBCT scans taken for purposes other than this study. Minimum sample size was calculated to be 241 teeth according to a previous study by Zhengyan *et al.* [15] assuming the effect size of 0.0866, $\alpha=0.05$, $\beta=0.1$ and power of 90%. Thus, 250 teeth of each type were included.

The inclusion criteria were fully erupted maxillary permanent teeth with closed apices and high quality of radiographs.

The exclusion criteria were root canal treatment, deep carious lesions in the crowns or roots, odontogenic lesions, presence of intracanal post, root resorption or calcification, open apex teeth, immature roots, root fracture extensive restorations and unclear root canal morphology on CBCT scans.

CBCT scans of male and female patients presenting to oral and maxillofacial radiology clinics in Kermanshah city taken for purposes other than this study such as implant treatment, diagnosis of bone fracture, *etc.* and met the inclusion criteria were collected using convenience sampling. All CBCT scans had been taken in private office in Kermanshah city in west of Iran with using New Tom VGi CBCT system (QR SRL Co., Verona, Italy) with the exposure settings of 110 kVp, 10 mA, 5.4 s exposure time, 0.15 mm voxel size and 120×80 mm field of view.

To determine the morphology of root canals, CBCT images in axial, sagittal and coronal planes were morphologically evaluated using NNT Viewer version 7.2 software on a 12.5-inch laptop (Asus) with 1080×1920 p resolution (Figures 1 and 2). The total number of canals in each tooth, number of canals in

each root and canal morphology in each root were determined. To determine the root canal morphology and canal type, the Vertucci's classification [18] was used (Figure 3). According to the observation of the teeth and roots in different planes (specially in axial) the number of roots (fused or separated roots) was precisely determined. Root fusion was considered to present when there was no evidence of periodontal ligament.

All assessments were made by two oral and maxillofacial radiologists and confirmed by one calibrated endodontist. For reliability test 300 teeth were analyzed by two oral and maxillofacial radiologists. Reliability between radiologists was assessed by kappa test. For intra-observer agreement, one observer re-analyzed of the sample, after two weeks and compared it with the previous result.

Statistical analysis

Data were analyzed using descriptive and analytical statistics via Fisher's exact test and Chi square test. All data analyses were performed using SPSS version 18.

Results

All the maxillary central and lateral incisors and canine teeth were single-rooted in 100% of the patients (Tables 1). Vertucci's type I was the most common canal type in these teeth. The maxillary first and second premolars were single-rooted in 72.4% and 93.2% of the cases, respectively (Table 2). The most common canal type was type V in the maxillary first premolars (40.8%) and type I in the maxillary second premolars (50.8%). Maxillary first and second molars had three roots in 97.6% and 96% of the cases, respectively. The mesial canal of the maxillary first molar had one root canal in 48.8% of the cases; a second mesiobuccal canal was noted in 51.2% of the cases. Mesial root

of the maxillary second molar had one canal in 66% of the cases and a second canal in 34% of the cases (Table 3).

The results showed no significant correlation between the number of roots of maxillary teeth and quadrant ($P>0.05$). Number of roots in the maxillary teeth was not correlated with gender ($P>0.05$). No significant correlation was found between the number of root canals of maxillary teeth and quadrant ($P>0.05$). The number of root canals of the maxillary central incisors ($P=0.05$), canines ($P=0.005$) and first molars ($P=0.006$) was significantly correlated with gender.

Correlation between age and number of root canals

A significant association was found between age and the number of root canals of maxillary central incisors ($P=0.005$), maxillary lateral incisors ($P=0.004$) and maxillary first premolars ($P=0.002$). The correlation between age with the number of root canals was not significant in any other tooth ($P>0.05$).

Correlation between canal type and quadrant

A significant correlation existed between the quadrant and type of canal of maxillary second premolars ($P=0.017$). Other correlations were not significant ($P>0.05$).

Correlation between type of canal and gender

A significant correlation was found between gender and type of canal of maxillary central incisors ($P=0.05$) and maxillary canines ($P=0.005$). Other correlations were not significant ($P>0.05$).

Correlation between canal type and age

Age was significantly correlated with the type of canal of maxillary central incisors ($P=0.004$), maxillary lateral incisors ($P=0.002$), maxillary canines ($P=0.015$) and maxillary first premolars ($P=0.001$). Other correlations were not significant ($P>0.05$).

Table 1. Number and percentage of canal type, number of roots, in maxillary central and lateral and canine

	Type of canal	Count	Number of Root	Count
Maxillary canine	Type I	119 (95.4%)	1	125
	Type II	0		
	Type III	3 (2.4%)		
Maxillary lateral	Type I	121 (96.8%)	1	125
	Type II	0		
	Type III	4 (3.2%)		
Maxillary central	Type I	123 (98.4%)	1	125
	Type II	0		
	Type III	2 (1.6%)		

Table 2. Number and percentage of canal type, number of roots of the maxillary first and second premolars

	type of canal	Count	Number of Root	Count
Maxillary premolar2	Type I	57 (45.6%)	1	119
	Type II	12		
	Type III	35		
	Type IV	5		
	Type V	16	2	6
Maxillary premolar1	Type I	23	1	94
	Type II	3		
	Type III	25		
	Type IV	12		
	Type V	50 (40.0%)	2	31
	Type VI	12		

Table 3. Number and percentage of canal type, number of roots of the maxillary molars

	Type of canal MB	Count	Type of canal DB	Count	type of canal P	Count	Number of Root
Maxillary molar 2	Type I	86	Type I	12	Type I	125	1
	Type II	0	Type II	0	Type II	0	
	Type III	21	Type III	0	Type III	0	
	Type IV	16	Type IV	0	Type IV	0	2
Maxillary molar 1	Type I	63	Type I	12	Type I	126	1
	Type II	2	Type II	0	Type II	0	
	Type III	33	Type III	0	Type III	0	
	Type IV	24	Type IV	0	Type IV	0	2

The type of mesiobuccal canal of maxillary first and second molars had no significant correlation with the quadrant ($P>0.05$). The type of mesiobuccal canal of maxillary first molars had a significant correlation with gender ($P=0.033$) but not with age ($P>0.05$). The type of mesiobuccal canal of maxillary second molars had no significant correlation with age ($P>0.05$). No significant correlation was noted between the type of distobuccal canal of maxillary first and second molars and the quadrant ($P>0.05$) but a significant correlation existed between the type of distobuccal canal of maxillary first molar and gender ($P=0.03$). Type of distobuccal canal of maxillary first and second molars had no significant correlation with age ($P>0.05$). Type of palatal canal of maxillary first and second molars had no significant correlation with the quadrant ($P>0.05$). Type of palatal canal of maxillary first molars had a significant correlation with gender ($P=0.03$) but not with age ($P>0.05$). Type of palatal canal of maxillary second molars had no significant correlation with age ($P>0.05$). Only one patient (70-year-old female) had midbuccal in her maxillary right second molar, which was Vertucci's type I. Another 62-year-old female had a single-rooted maxillary right second molar, which was Vertucci's type I.

Discussion

Knowledge about the anatomical variations of the root canal system plays an important role in success of root canal treatment [19, 20]. In the current study, CBCT was used for assessment of root canal morphology, which was similar to the methodology adopted by Kim *et al.* [4] Wang *et al.* [16] Bulut *et al.* [14] Altunsoy *et al.* [21] and Lee *et al.* [22]. Abuabara *et al.* [23] reported that CBCT was as accurate as ultrasound and assessment under a microscope for detection of accessory canals. Blattner *et al.* [24] compared CBCT with the gold standard of assessment of root canal morphology *i.e.* clinical sectioning of teeth and revealed that CBCT yielded the same results as the gold standard in detection of second mesiobuccal canal in 80% of the cases.

Our results showed that all 250 maxillary central incisors were single-rooted; 249 were single-canal and Vertucci's type I while 4 teeth had two canals and were Vertucci's type III. Canal type of maxillary central incisors in males was type I while it was type I in 96.6% and type III in 3.4% of females. Altunsoy *et al.* [21] in their study on Turkish population showed that 99.6% of maxillary central incisors were type I, 0.19% were type III and 0.12% were type IV. Jain *et al.* [25] in their study in India showed that all maxillary central incisors were single-rooted and single canal, which was almost similar to our findings.

Maxillary lateral incisors in our study were all single-rooted; 244 were single canal and type I while 6 teeth had two canals and were type III (in two males and four females). In the study by Altunsoy *et al.* [21] 97.5% of maxillary lateral incisors had one canal and it was Vertucci's type I; 2.5% had two canals and were type II. In the study by Jain *et al.* [25] in India, all maxillary lateral incisors were single-rooted; 98% were single-canal and type I and 2% had two canals and were type II. Their findings were in agreement with ours. In the study by Altunsoy *et al.* [21] the frequency of lateral incisors with two canals among men was higher than that among women. However, in our study, greater number of females had lateral incisors with two canals compared to males (4 *versus* 2).

All maxillary canine teeth in our study were single-rooted; 239 (95.6%) had one single canal and were type I while 11 (4.4%) had two canals [5 (2%) were type III and 6 (2.4%) were type V]. One male patient had one canine with two canals (type III) and 10 females had canine teeth with two canals [type III in 4 (3.3%) and type V in 6 (4.9%)]. In the study by Jain *et al.* [25] all maxillary canine teeth were single-rooted and 96% were type I, 3% were type II and 1% were type III. The results of the aforementioned studies were almost similar to our findings. However, Amardeep *et al.* [26] reported that canine teeth with two canals had a much higher prevalence among a particular race in India (18.4%).

Regarding the maxillary first premolars, our study showed that 72.4% of maxillary first premolars had one single root while this rate was 46% in a study by Abella *et al.* [27] in Spain. The prevalence of maxillary second premolars with two and three roots was 51.4% and 2.6%, respectively in their study while in our study, this rate was 27.6% and 0%, respectively. Tian *et al.* [28] in China reported the prevalence of maxillary first premolars with one, two and three roots to be 66%, 33% and 1%, respectively, which were closer to our values. In the study by Abella *et al.* [27] the most common canal type in maxillary first premolars was type IV (52.8%) followed by type I (25.1%) and type II (10.2%); whereas, in our study, type V with 40.8% frequency was the most common canal type followed by type III and type I with 22.4% and 16.8% frequency values, respectively.

Regarding the maxillary second premolars, Abella *et al.* [27] reported that 82.9% of maxillary second premolars were single-rooted, 15.5% had two and 1.6% had three roots. Yang *et al.* [29] in China reported that 86.5% of maxillary second premolars had one root and 13.5% had two roots. In our study, 93.2% of maxillary second premolars had one and 6.8% had two roots. Maxillary second premolars with three roots were not found in our study. In both studies by Abella *et al.* [27] and Yang *et al.* [29] the prevalence

of maxillary second premolars with more than one canal was higher than those with one canal (60.7% and 54.6%) while in our study, 50.8% of maxillary second premolars had one canal (type I). Regarding maxillary first molars, Rouhani *et al.*, [3] in their study in Iran showed that 98.4% of maxillary first molars had three roots, which was close to the rate in our study (97.6%). Neelakantan *et al.*, [20] in India reported that 97.6% of maxillary first molars had three roots; this rate was 98.5% in the study by Kim *et al.*, [4] in Korea. These values were in agreement with our results. In the studies by Rouhani *et al.* [3] and Neelakantan *et al.*, [20], 1.6% and 0.9% of maxillary first molars had four roots, respectively; whereas, no case of maxillary first molar with four roots was found in our study or that of Kim *et al.* [4]. Rouhani *et al.* [3] did not find maxillary first molars with two roots while in our study and those of Neelakantan *et al.* [20] and Kim *et al.* [4], 1.3% and 1.23% of teeth had two roots, respectively. Single-rooted maxillary first molars were not found in our study and that of Rouhani *et al.* [3], while Kim *et al.*, [4] and Neelakantan *et al.* [20], reported the prevalence of single-rooted maxillary first molars to be 0.25% and 0.9%, respectively. The most common type of mesiobuccal canal was type I followed by type VI in the study by Rouhani *et al.* [3], while it was type I followed by type IV in the study by Neelakantan *et al.* [20]. Type I followed by type III were the most common canal types in our study. In the study by Kim *et al.* [4] type IV was the most common type, and type I ranked second.

The most common distobuccal canal type was type I in our study (100% of the cases), similar to the findings of Rouhani *et al.* [3] (96%), Neelakantan *et al.* [20] (90.4%), and Kim *et al.* [4] (98.75%). The most common palatal canal type was type I in our study (99.2% of the cases), similar to the findings of Rouhani *et al.* [3] (98.4%), Neelakantan *et al.* [20] (87.8%), and Kim *et al.* [4] (100%).

Regarding maxillary second molars, Rouhani *et al.* [3] showed that 96.6% of maxillary second molars had three roots; this rate was 93.1% in the study by Neelakantan *et al.* [20], 96% in our study and 82.7% in the study by Kim *et al.* [4]. The prevalence of single-rooted was 0.4% in our study, and 4.63% in the study by Kim *et al.* [4]. Rouhani *et al.* [3] found no case of single-rooted maxillary second molars.

The prevalence of double-rooted maxillary second molars was 0.8% in the study by Rouhani *et al.* [3], 5.8% in the study by Neelakantan *et al.* [20], 10.72% in the study by Kim *et al.* [4], and 3.2% in our study. The prevalence of maxillary second molars with four roots was 1.6% in the study by Rouhani *et al.* [3], 1.95% in the study by Kim *et al.* [4], 0.8% in our study, and 0% in the study by Neelakantan *et al.* [20].

The most common mesiobuccal canal type was type I (80.8%) followed by type III (4%) in the study by Rouhani *et al.* [3]. The most common mesiobuccal canal type was type I (63.9%) followed by type IV (24.4%) in the study by Neelakantan *et al.* [20]. Kim *et al.* [4] reported the most common mesiobuccal canal type to be type I (65.6%) followed by type II (16.21%). In our study, type I (65.9%) followed by type III (20.4%) had the highest frequency. The most common distobuccal canal type was type I in the study by Rouhani *et al.* [3] (96%), Kim *et al.* [4] (100%), our study (100%), and that of Neelakantan *et al.* [20] (84.9%). The most common palatal canal type was type I in the study by Rouhani *et al.* [3] (99.2%), Kim *et al.* [4] (100%), our study (100%), and that of Neelakantan *et al.* [20] (92.7%). According to the aforementioned studies, not finding the second mesiobuccal canal is the most common procedural error during endodontic treatment [4]. Considering the high prevalence of second mesiobuccal canal in our study, clinicians must pay more attention to this issue. Also, our findings pointed to the possibility of presence of a second canal in distobuccal and palatal roots, which should be kept in mind during endodontic treatment of these teeth.

Conclusion

Our results revealed significant differences in canal type of teeth in our study population compared to the data reported from other countries and other regions of Iran. These differences can be due to sample size, study design, methodology, race of patients and genetics. The results of this study can help clinicians in efficient root canal treatment of teeth.

Acknowledgment

I would like to express my very great appreciation to MOJTABA AMIRI for his valuable and constructive suggestions during the planning and development of this research work. His willingness to give his time so generously has been very much appreciated.

Conflict of Interest: 'None declared'.

References

1. Yu X, Guo B, Li KZ, Zhang R, Tian YY, Wang H, et al. Cone-beam computed tomography study of root and canal morphology of mandibular premolars in a western Chinese population. *BMC Med Imaging*. 2012;12:18.
2. Plotino G, Tocci L, Grande NM, Testarelli L, Messineo D, Ciotti M, et al. Symmetry of root and root canal morphology of maxillary and mandibular molars in a white population: a cone-beam computed tomography study in vivo. *J Endod*. 2013;39(12):1545-8.

3. Rouhani A, Bagherpour A, Akbari M, Azizi M, Nejat A, Naghavi N. Cone-beam computed tomography evaluation of maxillary first and second molars in Iranian population: a morphological study. *Iran Endod J.* 2014;9(3):190-4.
4. Kim Y, Lee SJ, Woo J. Morphology of maxillary first and second molars analyzed by cone-beam computed tomography in a Korean population: variations in the number of roots and canals and the incidence of fusion. *J Endod.* 2012;38(8):1063-8.
5. Weng XL, Yu SB, Zhao SL, Wang HG, Mu T, Tang RY, et al. Root canal morphology of permanent maxillary teeth in the Han nationality in Chinese Guanzhong area: a new modified root canal staining technique. *J Endod.* 2009;35(5):651-6.
6. Kulild JC, Peters DD. Incidence and configuration of canal systems in the mesiobuccal root of maxillary first and second molars. *J Endod.* 1990;16(7):311-7.
7. Thompson SA, al-Omari AO, Dummer PM. Assessing the shape of root canals: an in vitro method using microradiography. *Int Endod J.* 1995;28(2):61-7.
8. Yoshioka T, Kikuchi I, Fukumoto Y, Kobayashi C, Suda H. Detection of the second mesiobuccal canal in mesiobuccal roots of maxillary molar teeth ex vivo. *Int Endod J.* 2005;38(2):124-8.
9. Baldassari-Cruz LA, Lilly JP, Rivera EM. The influence of dental operating microscope in locating the mesiolingual canal orifice. *Oral Surg Oral Med Oral Pathol Oral Radiol Endod.* 2002;93(2):190-4.
10. Gilles J, Reader A. An SEM investigation of the mesiolingual canal in human maxillary first and second molars. *Oral Surg Oral Med Oral Pathol.* 1990;70(5):638-43.
11. Alacam T, Tinaz AC, Genc O, Kayaoglu G. Second mesiobuccal canal detection in maxillary first molars using microscopy and ultrasonics. *Aust Endod J.* 2008;34(3):106-9.
12. Plotino G, Grande NM, Pecci R, Bedini R, Pameijer CH, Somma F. Three-dimensional imaging using microcomputed tomography for studying tooth macromorphology. *J Am Dent Assoc.* 2006;137(11):1555-61.
13. Patel S, Dawood A, Ford TP, Whaites E. The potential applications of cone beam computed tomography in the management of endodontic problems. *Int Endod J.* 2007;40(10):818-30.
14. Bulut DG, Kose E, Ozcan G, Sekerci AE, Canger EM, Sisman Y. Evaluation of root morphology and root canal configuration of premolars in the Turkish individuals using cone beam computed tomography. *Eur J Dent.* 2015;9(4):551-7.
15. Zhengyan Y, Keke L, Fei W, Yueheng L, Zhi Z. Cone-beam computed tomography study of the root and canal morphology of mandibular permanent anterior teeth in a Chongqing population. *Ther Clin Risk Manag.* 2016;12:19-25.
16. Wang Y, Zheng QH, Zhou XD, Tang L, Wang Q, Zheng GN. Evaluation of the root and canal morphology of mandibular first permanent molars in a western Chinese population by cone-beam computed tomography. *J Endod.* 2010;36(11):1786-9.
17. Patel S. New dimensions in endodontic imaging: Part 2. Cone beam computed tomography. *Int Endod J.* 2009;42(6):463-75.
18. Vertucci FJ. Root canal anatomy of the human permanent teeth. *Oral Surg Oral Med Oral Pathol.* 1984;58(5):589-99.
19. Ng YL, Aung TH, Alavi A, Gulabivala K. Root and canal morphology of Burmese maxillary molars. *Int Endod J.* 2001;34(8):620-30.
20. Neelakantan P, Subbarao C, Ahuja R, Subbarao CV, Gutmann JL. Cone-beam computed tomography study of root and canal morphology of maxillary first and second molars in an Indian population. *J Endod.* 2010;36(10):1622-7.
21. Altunsoy M, Ok E, Nur BG, Aglarci OS, Gungor E, Colak M. A cone-beam computed tomography study of the root canal morphology of anterior teeth in a Turkish population. *Eur J Dent.* 2014;8(3):302-6.
22. Lee JH, Kim KD, Lee JK, Park W, Jeong JS, Lee Y, et al. Mesiobuccal root canal anatomy of Korean maxillary first and second molars by cone-beam computed tomography. *Oral Surg Oral Med Oral Pathol Oral Radiol Endod.* 2011;111(6):785-91.
23. Abuabara A, Baratto-Filho F, Aguiar Anele J, Leonardi DP, Sousa-Neto MD. Efficacy of clinical and radiological methods to identify second mesiobuccal canals in maxillary first molars. *Acta Odontol Scand.* 2013;71(1):205-9.
24. Blattner TC, George N, Lee CC, Kumar V, Yelton CD. Efficacy of cone-beam computed tomography as a modality to accurately identify the presence of second mesiobuccal canals in maxillary first and second molars: a pilot study. *J Endod.* 2010;36(5):867-70.
25. Jain P, Balasubramanian S, Sundaramurthy J, Natanasabapathy V. A Cone Beam Computed Tomography of the Root Canal Morphology of Maxillary Anterior Teeth in an Institutional-Based Study in Chennai Urban Population: An In vitro Study. *J Int Soc Prev Community Dent.* 2017;7(Suppl 2):S68-S74.
26. Somalinga Amardeep N, Raghu S, Natanasabapathy V. Root canal morphology of permanent maxillary and mandibular canines in Indian population using cone beam computed tomography. *Anat Res Int.* 2014;2014:731859.
27. Abella F, Teixido LM, Patel S, Sosa F, Duran-Sindreu F, Roig M. Cone-beam Computed Tomography Analysis of the Root Canal Morphology of Maxillary First and Second Premolars in a Spanish Population. *J Endod.* 2015;41(8):1241-7.
28. Tian YY, Guo B, Zhang R, Yu X, Wang H, Hu T, et al. Root and canal morphology of maxillary first premolars in a Chinese subpopulation evaluated using cone-beam computed tomography. *Int Endod J.* 2012;45(11):996-1003.
29. Yang L, Chen X, Tian C, Han T, Wang Y. Use of cone-beam computed tomography to evaluate root canal morphology and locate root canal orifices of maxillary second premolars in a Chinese subpopulation. *J Endod.* 2014;40(5):630-4.
30. De Carlo Bello M, Tibúrcio-Machado C, Dotto Londero C, Branco Barletta F, Cunha Moreira CH, Pagliarin CML. Diagnostic Efficacy of Four Methods for Locating the Second Mesiobuccal Canal in Maxillary Molars. *Iran Endod J.* 2018;13(2):204-208.
31. Khademi A, Zamani Naser A, Bahreinian Z, Mehdizadeh M, Najarian M, Khazaei S. Root Morphology and Canal Configuration of First and Second Maxillary Molars in a Selected Iranian Population: A Cone-Beam Computed Tomography Evaluation. *Iran Endod J.* 2017;12(3):288-292.

Please cite this paper as: Nikkarder N, Asnaashari M, Karimi A, Araghi S, Seifitabar SH, Golshah A. Root and Canal Morphology of Maxillary Teeth in an Iranian Subpopulation Residing in Western Iran Using Cone-beam Computed Tomography. *Iran Endod J.* 2020;15(1): 31-7. Doi: 10.22037/iej.v15i1.25386.