



## Bilateral Presence of Two Distobuccal Canals in Maxillary First Molars: A Case Report

Eshaghali Saberi<sup>a</sup> , Mahboobe Ahmadi<sup>b\*</sup>

<sup>a</sup> Oral and Dental Diseases Research Center, Department of Endodontics, Dental School, Zahedan University of Medical Sciences, Zahedan, Iran; <sup>b</sup> Department of Endodontics, Dental School, Zahedan University of Medical Sciences, Zahedan, Iran

### ARTICLE INFO

Article Type: Case Report

Received: 11 Apr 2019

Revised: 01 Jun 2019

Accepted: 10 Jun 2019

Doi: 10.22037/iej.v14i3.24708

\*Corresponding author: Mahboobe Ahmadi, Department of Endodontics, Dental School, Zahedan University of Medical Sciences, Zahedan, Iran. Tel: +98-913 5726608

E-mail: mahboobeahmadi66@yahoo.com



© The Author(s). 2018 Open Access This work is licensed under the terms of the Creative Commons Attribution-NonCommercial-ShareAlike 4.0 International.

### ABSTRACT

This article describes the diagnosis and treatment of bilaterally maxillary first molars with two canals in their distobuccal roots. A 13-year-old male came to the clinic with a severe pain of tooth #14. In the first session, after access and finding the main canals and the second mesio-buccal (MB2) canal, another canal was noticed in the distobuccal root. All teeth were examined and a severe decay was observed in the left maxillary first molar. After preparing the access cavity, another orifice was found between the palatal and distobuccal canals. The presence of the second distobuccal canal was confirmed using an apex locator and radiography.

**Keywords:** Anatomic Variation; Maxillary First Molar; Root Canal System; Second Distobuccal Canal

### Introduction

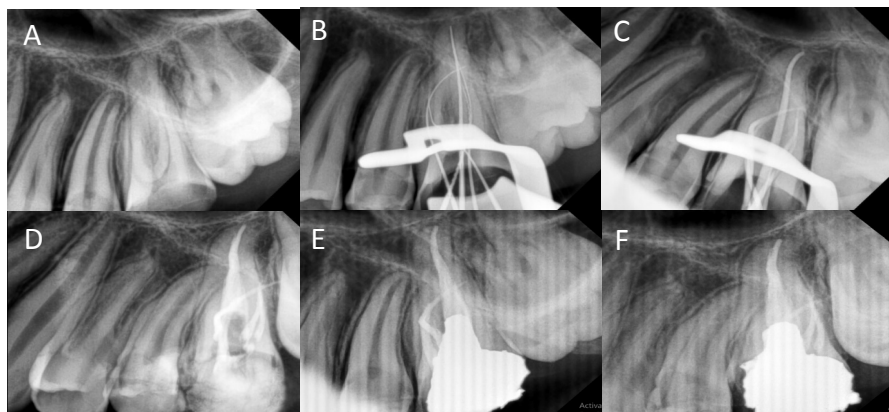
Identification of the root canal and diversity is essential for endodontic treatment [1]. According to published results, the most commonly known morphology for the maxillary first molar is 3 roots and 4 canals [2]. The methods used to evaluate the root canal include sectioning teeth [3], staining and clearing [4, 5], modified canal staining and clearing [5], conventional radiography [6], contrast media enhanced digital radiography [7], computed tomography (CT) [8], cone-beam computed tomography (CBCT) imaging [1, 2], micro-computed tomographic imaging (micro-CT) [9], and microscopic examination [3]. In a review article by Cleghorn *et al.* [10], a total of 14 studies and 2576 permanent maxillary first molars were examined, and the prevalence of  $\geq 2$ -canal in the distobuccal root was 1.7% [10]. Other articles reported the prevalence of the second distobuccal canal as 1.2% -11.1% [1, 2, 5, 9, 11, 12]. The second distobuccal canal in the upper molar is rare. This article describes the diagnosis and treatment of bilaterally maxillary first molars with two canals in their distobuccal.

### Case Report

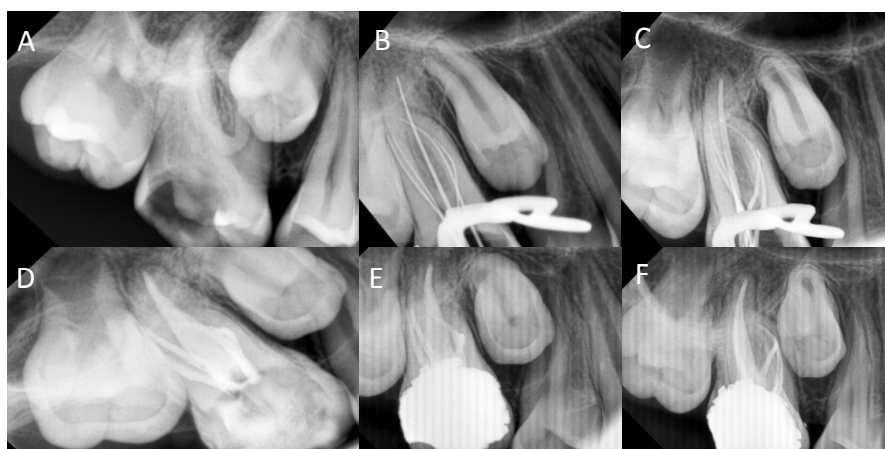
A 13-year-old male was presented to Zahedan University of Medical Sciences with the chief complaint of a toothache in left maxilla. His medical history was unremarkable. On intra-oral and preoperative preapical radiograph examination, the left maxillary first molar (tooth #14) was carious (Figure 1A). The tooth mobility was in normal limits and the probing depths were less than 3 mm. After vitality tests, palpation and percussion tests in tooth #14, a diagnosis of symptomatic irreversible pulpitis and symptomatic apical periodontitis was made.

Following anesthesia with 2% lidocaine and 1:80000 epinephrine, the access cavity was prepared and the rubber dam was placed. After finding the main canal, the second mesio-buccal (MB2) canal was found near the palatal orifice which varied slightly with its routine position, then the first file #15 (Mani, Tochigi, Japan) was placed in the canals; the radiography revealed the wider distobuccal (DB) root dimension, therefore a search radiography was performed.

The working lengths of second DB canal was estimated by means of an electronic apex locator (Root ZX; Morita, Tokyo,



**Figure 1.** Radiographic sequence of treatment of maxillary left first molar (#14); A) The preoperative image; B) The working length image; C) The master cone image; D and E) The postoperative and post restoration images showing 2 canals in the distobuccal root that joining together (Weine type II); F) Post restoration follow-up



**Figure 2.** Radiographic sequences of treatment of the maxillary right first molar (#3); A) The preoperative image, B) The working length image, C) Master cone radiograph, D and E) The postoperative and post restoration images showing 2 separate canals in the distobuccal root (Weine type III); F) Post restoration follow-up

Japan) and then confirmed by a radiography (Figure 1B). The canals were prepared with ProTaper system (Dentsply Maillefer, Ballaigous, Switzerland), and after taking master cone radiograph (Figure 1C), obturation was carried out through the vertical technique for the palatal canal and through the lateral technique for other canals using gutta-percha (Gapadent, Co. Ltd, Tianjin, China) and AH-26 sealer (Dentsply, Tulsa Dental, Tulsa, OK, USA). The postoperative and post restoration images showed 2 canals in the DB root that join together (Weine type II) (Figure 1D and E) [14]. Moreover, intra-oral and preoperative preapical radiograph examination of the tooth #3 revealed a severe decay with symptomatic irreversible pulpitis which needed endodontic treatment (Figure 2A). In the next visit, after anesthesia, all decays were removed, the access cavity was prepared, the rubber dam was placed, and the main canals were instantly found. Since additional canal was expected, the groove between the first DB and palatal canals was searched and the K-file #8 was inserted into the orifice and checked by an apex locator, preapical radiography was performed, and the presence of 5 canals was confirmed (Figure 2B).

Then, cleaning, shaping and taking master cone radiograph were performed similar to the other tooth (Figure 2C). Obturation was carried out through the vertical technique for the palatal canal and through the lateral technique for other canals. The postoperative and post restoration images showed 5 separate canals. There were 2 separate canals in the DB root (Weine type III) the same as its paired contralateral tooth (Figures 2D and E) [14]. The normal condition of both teeth was seen in post restoration follow-up radiographs (Figures 1F and 2F).

## Discussion

The maxillary first molars includes 3 roots and 4 canals in the most common form. The DB roots of maxillary molars is usually not broad in their buccolingual and contains one canal. The most common forms reported in various studies are Vertucci type I (single canal extends from the pulp chamber to the apex) followed by Vertucci type II (two separate canals leave the pulp chamber and join short of the apex to form one canal). Other types are less

frequent [1, 4, 5, 11, 13]. Fogel *et al.* [14] studied 8 maxillary molars with two canals at the distobuccal root; out of 8 teeth, four case of (Weine type II) (2 canals in the DB root that join together) and 4 case of Weine type III (2 separate canals in the DB root) [14]. In this case, a tooth was Weine type III and the other was Weine type II. Weller and Hartwel [15] showed that detection rate of 4 canals in maxillary first molar increases by exploration of the chamber pulp floor groove and its search with ultrasound [15]. On the other hand, magnification facilitates the detection of additional canals [16]. Modified access cavity can be useful in cases where an extra canal exists [17].

Conventional radiography is amongst the most common methods to evaluate tooth anatomy but not completely reliable method. Recently, techniques such as CBCT, or computed tomography, are used for negotiation of the extra canals [1, 8].

Loupes and dental operating microscope (DOM) increase opportunity for the dentist to detect canal orifices and very helpful for show the presence of additional roots or canal [18]. CBCT is useful in overcoming the limitation of intra oral radiography and more predictable for treatment of complex endodontic cases compared to using intra-oral radiographs alone [19]. However, this technique is not feasible at all locations and is associated with the potential of increased dose effect.

In the present case, the patient was young and we found the second distobuccal canal through extension of the access cavity and performing radiography with different angles.

However, finding the canal gets harder with increasing age [20] and use of magnification and CBCT is useful especially for elderly patients.

## Conclusion

Anatomic variation in the number of canals can occur in maxillary first molar. The clinicians should be aware that variations in the shape of the tooth and anatomy of root canal system can occur bilaterally.

## Acknowledgement

The authors thank the patient for giving permission for publishing this case.

Conflict of Interest: 'None declared'.

## References

1. Neelakantan P, Subbarao C, Ahuja R, Subbarao CV, Gutmann JL. Cone-beam computed tomography study of root and canal morphology of maxillary first and second molars in an Indian

2. population. *J Endod.* 2010;36(10):1622-7.
3. Silva EJNL, Nejaim Y, Silva AI, Haiter-Neto F, Zaia AA, Cohenca N. Evaluation of root canal configuration of maxillary molars in a Brazilian population using cone-beam computed tomographic imaging: an in vivo study. *J Endod.* 2014;40(2):173-6.
4. Kulid JC, Peters DD. Incidence and configuration of canal systems in the mesiobuccal root of maxillary first and second molars. *J Endod.* 1990;16(7):311-7.
5. Alavi A, Opananon A, Ng YL, Gulabivala K. Root and canal morphology of Thai maxillary molars. *Int Endod J.* 2002;35(5):478-85.
6. Weng X-L, Yu S-B, Zhao S-L, Wang H-G, Mu T, Tang R-Y, Zhou X-D. Root canal morphology of permanent maxillary teeth in the Han nationality in Chinese Guanzhong area: a new modified root canal staining technique. *J Endod.* 2009;35(5):651-6.
7. Pineda F, Kuttler Y. Mesiodistal and buccolingual roentgenographic investigation of 7,275 root canals. *Oral Surg Oral Med Oral Pathol.* 1972;33(1):101-10.
8. Patel S, Dawood A, Whaites E, Pitt Ford T. New dimensions in endodontic imaging: part 1. Conventional and alternative radiographic systems. *Int Endod J.* 2009;42(6):447-62.
9. Sberna M, Rizzo G, Zacchi E, Cappare P, Rubinacci A. A preliminary study of the use of peripheral quantitative computed tomography for investigating root canal anatomy. *Int Endod J.* 2009;42(1):66-75.
10. Briseño-Marroquín B, Paqué F, Maier K, Willershausen B, Wolf TG. Root canal morphology and configuration of 179 maxillary first molars by means of micro-computed tomography: an ex vivo study. *J Endod.* 2015;41(12):2008-13.
11. Cleghorn BM, Christie WH, Dong CC. Root and root canal morphology of the human permanent maxillary first molar: a literature review. *J Endod.* 2006;32(9):813-21.
12. Ng YL, Aung T, Alavi A, Gulabivala K. Root and canal morphology of Burmese maxillary molars. *Int Endod J.* 2001;34(8):620-30.
13. Kim Y, Lee S-J, Woo J. Morphology of maxillary first and second molars analyzed by cone-beam computed tomography in a Korean population: variations in the number of roots and canals and the incidence of fusion. *J Endod.* 2012;38(8):1063-8.
14. Kim H-C, Kwak S-W, Cheung GS-P, Ko D-H, Chung S-M, Lee W. Cyclic fatigue and torsional resistance of two new nickel-titanium instruments used in reciprocation motion: Reciproc versus WaveOne. *J Endod.* 2012;38(4):541-4.
15. Fogel HM, Cunha RS. Maxillary First Molars with 2 Distobuccal Canals: A Case Series. *J Endod.* 2017;43(11):1925-8.
16. Weller RN, Hartwell GR. The impact of improved access and searching techniques on detection of the mesiolingual canal in maxillary molars. *J Endod.* 1989;15(2):82-3.
17. Görduysus MÖ, Görduysus M, Friedman S. Operating microscope improves negotiation of second mesiobuccal canals in maxillary molars. *J Endod.* 2001;27(11):683-6.
18. Velmurugan N, Parameswaran A, Kandaswamy D, Smitha A, Vijayalakshmi D, Sowmya N. Maxillary second premolar with three roots and three separate root canals. *Aust J Endod.* 2005;31(2):73-5.
19. Del Fabbro M, Taschieri S. Endodontic therapy using magnification devices: a systematic review. *Journal of dentistry.* 2010;38(4):269-75.
20. Patel S, Kanagasingam S, Mannocci F. Cone beam computed tomography (CBCT) in endodontics. *Dental update.* 2010;37(6):373-9.
21. Ghodduji J, Javidi M, Vatanpour M. Two symmetrical maxillary first molars with two disto-buccal root canals. *Iran Endod J.* 2006;1(2):73.

Please cite this paper as: Saberi EA, Ahmadi M. Bilateral Presence of two Distobuccal Canals in Maxillary First Molars. *Iran Endod J.* 2019;14(3): 232-234. Doi: 10.22037/iej.v14i3.24708.