



## A Mandibular First Molar with Three Distal Canals: A Case Report and Literature Review

Reza Beyraghshamshir<sup>a</sup> , Mina Zarei<sup>a</sup> , Salehe Sekandari<sup>b\*</sup>

<sup>a</sup> Department of Endodontics, Dental School, Mashhad University of Medical Sciences, Mashhad, Iran; <sup>b</sup> Department of Restorative Dentistry, School of Dentistry, Mashhad University of Medical Sciences, Mashhad, Iran

### ARTICLE INFO

Article Type: Case Report

Received: 11 Jan 2019

Revised: 22 Feb 2019

Accepted: 03 Mar 2019

Doi: 10.22037/iej.v14i3.24400

\*Corresponding author: Salehe Sekandari, Department of Restorative Dentistry, Dental School, Mashhad University of Medical Sciences, Azadi Square, Mashhad, Iran.

Tel: +98-935 8133083

E-mail: salehesekandari@yahoo.com



© The Author(s). 2018 Open Access This work is licensed under the terms of the Creative Commons Attribution-NonCommercial-ShareAlike 4.0 International.

### ABSTRACT

For a successful root canal treatment, it is critical for a clinician to have complete knowledge of the root canal morphology. There are numerous cases in literature concerning the unusual anatomy of mandibular first molars. This report presents a case of a mandibular first molar with three distal canals. An overview of the types and numbers of the common anatomic forms of this tooth also is presented, as is a summary of published anomalies.

**Key words:** Distal Root; Mandibular First Molar; Root Canal Anatomy

### Introduction

The primary objective of root canal therapy is to fill the debrided canals with an obturation material; in order to eliminate a source of injury from residual organic materials or from apical percolation into voids in the restored canals [1].

Two main causes of endodontic failure are a) incomplete obturation, and b) imperfect instrumentation. Therefore, thorough knowledge of pulp-space morphology would help reduce endodontic failures caused by incomplete obturation [2].

The current concept of the root canal morphology of mandibular first molars is based on the work of Hess [3]; who made vulcanite casts so as to duplicate the anatomy of pulp cavities. Of 512 first and second mandibular molars, he found 0.3% with one canal, 17.7% with two canals, 78.0% with three canals, and 4.0% with four canals.

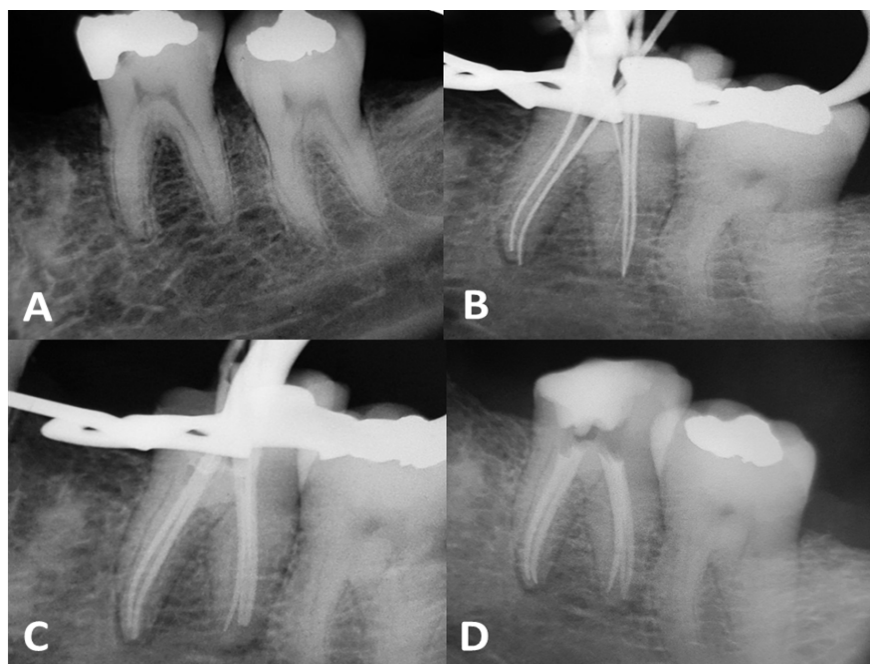
There are reports of unusual canal anatomy in relation to all teeth, and mandibular molars are not excluded [4-7]. Berthiaume [8] reported a mandibular first molar with five canals that had

three distinct distal canals. The third distal canal converged with the disto-lingual canal in its apical third, and with the disto-buccal canal in its coronal third. A case of five separate root canals in a mandibular first molar was also reported by Stroner *et al.* [9]. Their case described a molar that had two canals in the mesial root and three canals in two distal roots. The disto-buccal root had two canals, and the disto-lingual root had a single canal.

When a clinician wants to treat a mandibular first molar with three distal canals, it is his responsibility to be aware that such teeth may have variations and might require special shaping and obturating techniques. This study reports the root canal treatment of a mandibular first molar with an atypical canal system.

### Case Report

A 39-year-old female patient was referred to the Department of Endodontics, Mashhad Dental Faculty, with severe spontaneous pain in tooth #19. Her medical history was non-contributory. Radiographic examination (Figure 1A) revealed a recurrent



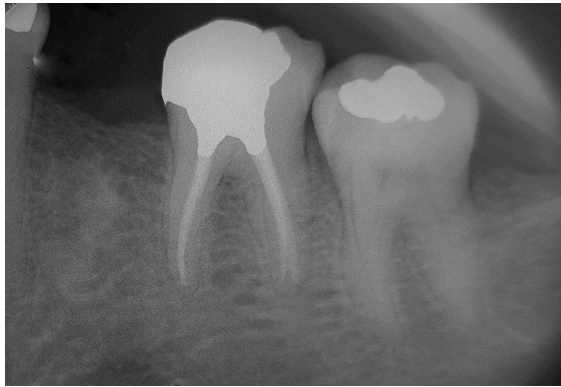
**Figure 1.** Periapical radiographs of tooth #19; A) Diagnostic periapical radiograph; B) Periapical radiograph shows an endodontic file in the third distal canal; C) Master-cone-confirmation periapical radiograph; D) Final radiograph; 5 canals were obturated

carious lesion involving the mesial pulp horn and widening of the periodontal ligament space. The periodontal status was normal (probing depth < 3mm) with physiologic mobility. Exaggerated response was observed during pulp testing with electric pulp tester and lingering pain was observed with the cold pulp test compared with contralateral teeth. The tooth was moderately tender on vertical percussion. Pretreatment examinations revealed irreversible pulpitis and chronic apical periodontitis, thus non-surgical root canal therapy was scheduled. The treatment plan was explained to the patient, and informed consent was obtained for the endodontic treatment of the involved tooth.

After administration of inferior alveolar and long buccal nerve block using 2% lidocaine and 1:100,000 epinephrine (Darupakhsh, Tehran, Iran), the tooth was isolated with a rubber dam, and then, an endodontic access cavity was prepared. Examination of the pulp chamber floor revealed four distinct root canal orifices: two were detected mesially (mesiobuccal and mesiolingual); and, two distally (distobuccal and distolingual). After finding the orifices of the canals, ProTaper SX rotary file (Dentsply Maillefer, Ballaigues, Switzerland) was used for cervical preflaring. The working length was determined with a #8 K-type file, coupled to Root ZX II apex locator (J. Morita, Irvine, CA, USA), and then, confirmed by radiographic examination. The first initial file radiograph was taken with two instruments in the mesial and

two instruments in the distal roots. After establishing a glide path in each canal with #10 and #15 K-type files, mesial canals were instrumented with Mtwo (VDW, Munich, Germany) rotary files to size 25/0.06 using a crown-down technique. The crown-down technique was also used to prepare distal canals for a size #30 K-file, which was considered the master apical file. Master-cone-confirmation radiograph was then taken. Exploring the latter radiograph, and due to the lateral placement of the found canals, we hypothesized that one additional canal might be present in the distobuccal root. After searching the floor of the pulp chamber with a pre-curved size #8 K-file, an additional canal was discovered (Figure 1B).

Instrumentation was performed in the third canal using a K-file (Maillefer, Dentsply, Ballaigues, Switzerland). The crown-down technique was used to prepare canals for a size #30 K-file. The canals were irrigated with 5.25% sodium hypochlorite during the treatment and eventually with normal saline. Then, the master-cone-confirmation radiograph was again taken (Figure 1C). The canals were dried with paper points and obturated with laterally condensed gutta-percha and AH-26 sealer (De Trey, Dentsply, Zurich, Switzerland). A radiograph was taken to evaluate the quality of obturation (Figure 1D) and the patient was referred to an operative dentist for a coronal restoration. The tooth was clinically and radiographically asymptomatic at the recall appointment after six months (Figure 2).



**Figure 2.** Periapical radiograph of tooth #19 in the second appointment (after six months)

## Discussion

Complicated and diverse root canal systems pose a challenge to successful diagnosis and treatment. The most common root canal morphology of mandibular first molars is the presence of 2 roots with either 3 or 4 root canals [10]. In addition to Hess's study [3] on the morphology of the root canal of mandibular first molars, Skidmore and Bjorndal [1] reviewed the anatomy of 45 plastic casts made from root canal systems of mandibular first molars. They found that 6.7% of the teeth had two root canals, 64.4% had three root canals, and 28.9% had four root canals. Furthermore, Vande *et al.* [11] reviewed the number of root canals in 318 consecutively treated mandibular first molars and found that 31% of the studied molars had four canals. Vertucci and Williams [12], using dye infusion followed by a clearing process that rendered the teeth transparent, saw the entire dyed root canal systems of 100 mandibular first molars. They found that 60% of the mesial roots had two canals and 40% had one at the apex. However, 5% of the distal roots had two canals and 85% had one at the

apex. Recently, 14 new additional canal types have been reported [13]. The incidence of a third canal in distal root, itself, is a rare occurrence with a prevalence rate of 0.2% to 3% in different ethnic groups [14]. The presented case demonstrated a rare anatomical configuration and supported previous reports of the existence of such configuration in mandibular first molars. Detailed review of the case reports with three or more canals in the distal root/roots are summarized in Table 1 [15].

It is important to know when to suspect abnormality. We know to look for more canals if files, as they protrude from the canal orifice, are not well centered in the canal, either radiographically or clinically. Additional off-angle radiographs and even multiple views of a tooth can help locate canals. Looking at the pulpal "footprint" and other adjunctive techniques helps improve the likelihood of finding additional canals. The pulpal footprint is the lines and shadows on the floor of the pulp chamber that guides us to areas where additional canals might be located. Transillumination can help identify suspect areas and reduce the chance of perforation [16]. Additionally, there are multiple concepts, armamentaria and instruments that are useful to find such unusual canals. These include use of micro-openers, proper designation of access cavities, use of piezoelectric ultrasonics, seeking rules of symmetry, red line test, white line test, and perio-probing [2]. Performing the sodium hypochlorite "champagne bubble test," and visualizing canal bleeding points are also important aids in locating root canal orifices [17]. In the present case, initial radiography illustrated the presence of more than one canal, and tactile examination helped the clinician to find the third distal canal.

A significant constraint in conventional radiography is that it produces a 2D image of a 3D object, resulting in the

**Table 1.** A review of the case reports with the discovery of three or more canals in distal root/roots of mandibular first molars

Investigator	Year	No. of mesial roots	No. of distal roots	No. of mesial canals	No. of distal canals	Distribution of canals in distal root
Stroner <i>et al.</i> [9]	1984	1	2	2	3	Distobuccal 1&2and distolingual
Beatty and Interian[18]	1985	1	2	2	3	Distobuccal, mid-distal, distolingual
Friedman <i>et al.</i> [19]	1986	1	3	2	3	Distobuccal, distal center, distolingual
Reh [16]	1998	1	1	4	3	Distobuccal, mid-distal, distolingual
Kimura and matsumoto[20]	2000	1	2	2	3	Distobuccal and distolingual 1&2
Lee <i>et al.</i> [21]	2006	1	3	2	3	Distobuccal, distal center, distolingual
Ghoddusi <i>et al.</i> [6]	2007	1	2	2	4	Distobuccal 1&2, mid-distal, distolingual
Bareletta <i>et al.</i> [22]	2008	1	2	2	3	Distobuccal and distolingual 1&2
Chandra <i>et al.</i> [23]	2009	1	1	2	3	Distobuccal, mid-distal, distolingual
Kottoor <i>et al.</i> [14]	2010	1	1	2	3	Distobuccal, mid-distal, distolingual
Mushtag <i>et al.</i> [24]	2011	1	1	2	3	Distobuccal, mid-distal, distolingual

superimposition of the overlying structures. Therefore, such radiographs are of limited value in cases with complex root canal anatomy. Cone-beam computed tomography (CBCT) is designed to provide non-invasive 3D information from root canal anatomy. An advantage of the computed tomography (CT) scanning over conventional radiography is that it permits the operator to look at multiple sections of the roots and their canals [25].

An *ex vivo* investigation using digital radiography concluded that endodontists failed to locate at least one canal in 40% of teeth [26]. Recent studies [27, 28] have reported a much higher detection of extra roots in the mandibular first molars by CBCT in comparison with conventional radiography. It is recommended to apply and utilize technology advancements, *e.g.* CBCT, to efficiently identify, disinfect, and obturate root canals.

## Conclusion

Usually, a thorough examination of pulp chamber leads dentists to discovering additional canals. Accurate instrumentation is a key factor in achieving success in endodontic therapy. Therefore, dentists should be fully aware of possible additional canals in mandibular first molars. With advanced diagnostic aids, such as CBCT, these challenges can be overcome.

## Acknowledgement

The authors thank the patient for giving permission for publishing this case.

Conflict of Interest: 'None declared'.

## References

- Skidmore AE, Bjorndal AM. Root canal morphology of the human mandibular first molar. *Oral Surg Oral Med Oral Pathol.* 1971;32(5):778-84.
- Ingle JI, Baumgartner JC. *Ingle's endodontics: PMPH-USA;* 2008.
- Hess W. The anatomy of the root-canals of the teeth of the permanent dentition. *Anatomy of the root canals.* 1925.
- Prabhu NT, Munshi A. Additional distal root in permanent mandibular first molars: Report of a case. *Quintessence Int.* 1995;26(8).
- Lu T-Y, Yang S-F, Pai S-F. Complicated root canal morphology of mandibular first premolar in a Chinese population using the cross section method. *J Endod.* 2006;32(10):932-6.
- Ghoddusi J, Naghavi N, Zarei M, Rohani E. Mandibular first molar with four distal canals. *J Endod.* 2007;33(12):1481-3.
- Rice RT, Gilbert BO. An unusual canal configuration in a mandibular first molar. *J Endod.* 1987;13(10):513-5.
- Berthiaume J. Five canals in a lower first molar. *J Mich Dent Assoc.* 1983;65(4-5):213-4.
- Stroner WF, Remeikis NA, Carr GB. Mandibular first molar with three distal canals. *Oral Surg Oral Med Oral Pathol.* 1984;57(5):554-7.
- Vertucci FJ. Root canal anatomy of the human permanent teeth. *Oral Surg Oral Med Oral Pathol.* 1984;58(5):589-99.
- Vande VH, Odendahl D, Davis J. Molar 4th canals: frequent cause of endodontic failure? *Ill Dent J.* 1975;44(12):779.
- Vertucci F, Williams R. Root canal anatomy of the mandibular first molar. *J N J Dent Assoc.* 1974;45(3):27.
- Sert S, Bayirli GS. Evaluation of the root canal configurations of the mandibular and maxillary permanent teeth by gender in the Turkish population. *J Endod.* 2004;30(6):391-8.
- Kottoor J, Sudha R, Velmurugan N. Middle distal canal of the mandibular first molar: a case report and literature review. *Int Endod J.* 2010;43(8):714-22.
- Jain S. Mandibular first molar with three distal canals. *J Conserv Dent.* 2011;14(4):438.
- Reeh ES. Seven canals in a lower first molar. *J Endod.* 1998;24(7):497-9.
- Vertucci FJ. Root canal morphology and its relationship to endodontic procedures. *Endodontic Topics.* 2005;10(1):3-29.
- Beatty RG, Interian CM. A mandibular first molar with five canals: report of case. *J Am Dent Assoc.* 1985;111(5):769-71.
- Friedman S, Moshonov J, Stabholz A. Five root canals in a mandibular first molar. *Dent Traumatol.* 1986;2(5):226-8.
- Kimura Y, Matsumoto K. Mandibular first molar with three distal root canals. *Int Endod J.* 2000;33(5):468-70.
- Lee S-J, Jang K-H, Spangberg LS, Kim E, Jung I-Y, Lee C-Y, Kum K-Y. Three-dimensional visualization of a mandibular first molar with three distal roots using computer-aided rapid prototyping. *Oral Surg Oral Med Oral Pathol Endod.* 2006;101(5):668-74.
- Barletta FB, Dotto SR, Reis MdS, Ferreira R, Travassos RMC. Mandibular molar with five root canals. *Aust Endod J.* 2008;34(3):129-32.
- Chandra SS, Rajasekaran M, Shankar P, Indira R. Endodontic management of a mandibular first molar with three distal canals confirmed with the aid of spiral computerized tomography: a case report. *Oral Surg Oral Med Oral Pathol Endod.* 2009;108(4):e77-e81.
- Mushtaq M, Farooq R, Rashid A, Robbani I. Spiral computed tomographic evaluation and endodontic management of a mandibular first molar with three distal canals. *J Conserv Dent.* 2011;14(2):196.
- Patel S, Dawood A, Whaites E, Pitt Ford T. New dimensions in endodontic imaging: part 1. Conventional and alternative radiographic systems. *Int Endod J.* 2009;42(6):447-62.
- Matherne RP, Angelopoulos C, Kulild JC, Tira D. Use of cone-beam computed tomography to identify root canal systems in vitro. *J Endod.* 2008;34(1):87-9.
- Tu M-G, Huang H-L, Hsue S-S, Hsu J-T, Chen S-Y, Jou M-J, Tsai C-C. Detection of permanent three-rooted mandibular first molars by cone-beam computed tomography imaging in Taiwanese individuals. *J Endod.* 2009;35(4):503-7.
- Nance R, Tyndall D, Levin L, Trope M. Identification of root canals in molars by tuned-aperture computed tomography. *Int Endod J.* 2000;33(4):392-6.

Please cite this paper as: Beyraghshamshir R, Zarei M, Sekandari S. A Mandibular First Molar with Three Distal Canals: A Case Report and Literature Review. *Iran Endod J.* 2019;14(3): 216-9. Doi: 10.22037/iej.v14i3.24400.